

## Persistent Inflammatory Activity in Blood Cells and Artery Tissue from Patients with Previous Bare Metal Stent

Pedro Silvio Farsky,<sup>1</sup> Mario H. Hirata,<sup>2</sup> Renato Tambellini Arnoni,<sup>1</sup> Antonio Flavio Sanches Almeida,<sup>1</sup> Mario Issa,<sup>1</sup> Paula Helena Ortiz Lima,<sup>1</sup> Maria de Lourdes Higuchi,<sup>3</sup> Hui T Lin-Wang<sup>2</sup>

Instituto Dante Pazzanese de Cardiologia,<sup>1</sup> São Paulo, SP - Brazil

Laboratório de Investigação Molecular em Cardiologia,<sup>2</sup> Instituto Dante Pazzanese de Cardiologia, São Paulo, SP – Brazil

Instituto do Coração (InCor) do Hospital das Clínicas da Faculdade de Medicina da Universidade de São Paulo,<sup>3</sup> São Paulo, SP - Brazil

### Abstract

**Background:** Studies have pointed out a higher mortality after coronary artery bypass surgery (CABG) in patients with stent.

**Objective:** To evaluate inflammatory markers in peripheral blood cells and in coronary artery tissue samples obtained during CABG in patients with stent compared to controls.

**Methods:** The case series consisted of two groups, one with previous stent implantation (n = 41) and one control (n = 26). The expression of the LIGHT, IL-6, ICAM, VCAM, CD40, NFKB, TNF, IFNG genes was analyzed in peripheral blood cells collected preoperatively. The coronary artery was evaluated for: interleukin-6, ICAM, VCAM, CD40, NFKB, TNF-alpha and IFN-gamma by immunohistochemistry. A total of 176 tissue samples were grouped for analysis in: A1- arteries with stent (n = 38); A2- native arteries from patients with stent in another artery (n = 68); and A3- arteries without stent from controls undergoing routinely CABG surgery (n = 70). A significance level of 0.05 was adopted.

**Results:** Patients with stent showed higher TNF (p = 0.03) and lower CD40 gene expression (p = 0.01) in peripheral blood cells than controls without stent. In coronary artery samples, the TNF-alpha protein staining was higher in the group A1, not only in the intima-media layer (5.16 ± 5.05 vs 1.90 ± 2.27; p = 0.02), but also in the adipose tissue (6.69 ± 3.87 vs 2.27 ± 4.00; p < 0.001). Furthermore, group A1 had a higher interleukin-6 protein staining in adipose tissue than group A3 (p = 0.04).

**Conclusion:** We observed a persistently higher systemic TNF expression associated with exacerbated TNF-alpha and interleukin-6 local production in patients with stents. This finding may contribute to a worse clinical outcome. (Arq Bras Cardiol. 2018; 111(2):134-141)

**Keywords:** Percutaneous Coronary Intervention; Blood Cells; Inflammation; Stents; Polymerase Chain Reaction; Immunohistochemistry; Tumor Necrosis Factor-alpha; Interleukin-6.

### Introduction

Retrospective studies have suggested that coronary artery bypass grafting (CABG) surgery after percutaneous coronary intervention (PCI) can impair short and long-term outcomes.<sup>1-7</sup> Previous studies have demonstrated that PCI is associated with higher in-hospital mortality, despite the lower risk profile of PCI patients,<sup>3</sup> but there is no consensus in the literature.<sup>8</sup> An analysis of the MASS study<sup>9</sup> has shown that patients who underwent PCI treatment were more likely to develop progression in native coronary arteries, than those undergoing CABG or medical treatment.

During PCI, a focal inflammatory reaction occurs with plaque rupture caused by stent implantation, but there

are still controversies if this reaction persists in the long term. There is scarce information about a persistent systemic inflammatory reaction or tissue mediators in coronary artery after stent implantation, as well as about the comparison between coronary arteries with stent, coronary arteries without stent but with stent in another artery and controls patient.

The CABG allows a unique opportunity to collect coronary artery specimen to evaluate local inflammatory reaction long after stent implantation. This study aims to evaluate inflammatory genes expression in peripheral blood cells and inflammatory protein localization in coronary artery tissue obtained during CABG from patients with and without previous stent implantation. It is worth mentioning that CABG represents a unique opportunity to obtain a tiny coronary artery tissue sample to evaluate local inflammatory in humans. Nowadays, patients who receive previous bare metal stent (BMS) implantation and need CABG surgery later represent a significant number of cardiology hospital patients, especially in developing countries. Our results can contribute to clarify the involvement of persistent local and systemic inflammation in the later phase of stent restenosis.

**Mailing Address:** Pedro Silvio Farsky •

Rua Alberto Faria, 248. Postal Code 05459-000, Alto de Pinheiros, São Paulo, SP – Brazil

E-mail: pedro.farsky@gmail.com

Manuscript received August 20, 2017, revised manuscript February 23, 2018, accepted February 23, 2018

**DOI:** 10.5935/abc.20180119

## Methods

### Case series

The patients admitted to elective CABG with previous stent implantation were consecutively included in this study after signing informed consent. The protocol was approved by the Dante Pazzanese Institute of Cardiology ethics committee (Protocol 4059-2011).

This study included 67 patients as follows: 41 patients with previous intracoronary BMS implantation and 26 patients without stent implantation submitted to elective CABG. All patients had stable angina and more than 6 months of the stent implantation, aiming to exclude ongoing restenosis. The exclusion criteria consisted of emergency surgeries, acute coronary syndromes and chronic renal failure in dialysis because of chronic inflammatory reaction.

Peripheral blood sample was collected preoperatively from the antecubital vein, using PAXgene tubes (PreAnalytiX®, BD Company, UK) for systemic gene expression analysis.

During CABG surgery, a tiny fragment of the bypassed coronary artery was obtained at the arteriotomy site, usually 10 mm after the stent implantation site, to evaluate local inflammation markers. All tissue samples were immediately immersed in buffered formalin for further paraffin-embedded block preparation. Some arterial fragments obtained were not adequate for histological analysis, thus, 176 artery samples were included and grouped as follows: A1- arteries with stent (n = 38); A2- native arteries from a patient with a stent in another artery (n = 68); and A3- arteries from patients without previous stent placement (n = 70).

### RNA isolation, reverse transcription and real-time polymerase chain reaction (PCR)

Total RNA was extracted from peripheral blood collected in PAXgene tubes (PreAnalytiX®, BD Company, UK) using PAXgene blood RNA kit (QIAGEN GmbH, Hilden, Germany), being then quantified using Qubit® 2.0 fluorometer (Life Technologies, Inc., Grand Island, NY). The RNA integrity was performed using TapeStation® 2200 and R6K Screen Tape (Agilent Technologies, Inc. UK). The cDNA was transcribed from 200 ng of total RNA using High Capacity RNA-to-cDNA Master Mix (Applied Biosystems, Foster City, USA). Real-time qPCR was carried out in Rotor-Gene® detection system using the TaqMan® Fast Multiplex PCR kit (QIAGEN GmbH, Hilden, Germany) and primers from Applied Biosystem commercially designed for TaqMan® qPCR (Applied Biosystems, Foster, CA, USA).

The expression of the following genes was evaluated: *LIGHT* (Hs00542477\_m1); *IL-6* (Hs00985639\_m1); *ICAM* (Hs00164932\_m1); *VCAM* (Hs00174239\_m1); *CD40* (Hs01002913\_g1); *NFKB* (Hs00231653\_m1); *TNF* (Hs01113624\_g1); *IFNG* (Hs00989291\_m1) and *GAPDH* (Hs00266705\_g1). For all genes, we constructed standard curves and determined the slope to calculate the PCR efficiency. Almost equal efficiency for all primer/probe systems was observed. All samples were tested in duplicate using *GAPDH* as a reference gene, which was previously chosen

between the six most common endogenous myocardium genes using geNorm algorithm.<sup>10</sup> The samples amplified after 40 cycles of PCR were considered negative and excluded from further statistical analysis. The expression of the reference *GAPDH* gene was applied for data normalization, and the relative expression of each mRNA was calculated using the  $2^{-\Delta\Delta CT}$  method.<sup>11</sup>

### Immunohistochemistry staining

Firstly, 4- $\mu$ m-thick formalin-fixed-paraffin-embedded artery samples were sectioned and fixed in silanized slides, followed by dewaxing at 70°C, in the oven, for 1 hour, and immersion in three xylene baths for 10 minutes. They were then rehydrated in decreasing concentrations (100%, 90%, 75%) of ethyl alcohol. Antigen retrieval was performed using the Trilogy® buffer (Cell Marque, California, USA) at a Decloaker equipment at 90°C for 40 minutes (Biocare Medical, CA, USA). The specific blocking reagents (Erviagas EasyPath, DuraEdge, USA) were applied for endogenous peroxidase and protein blocking. In the next step, the slides were incubated with respective primary antibodies previously titrated and diluted in universal thinner (Erviagas EasyPath, DuraEdge, USA). Primary antibodies against interleukin-6 (IL-6) (ab6672), ICAM (ab2213), VCAM (ab106777), TNF-alpha (ab1793), IFN-gamma (ab9657), CD40 (ab58612), and NFKB (ab16502) from Abcam (Cambridge, MA, UK) were used. The immunoperoxidase reaction was detected using Mach4 Kit Universal HRP Polymer + DAB (Biocare Medical, California, USA), and, finally, the slides were stained with Harris hematoxylin (Erviagas EasyPath, DuraEdge, USA) and assembled by synthetic resin Erv-Mount (Erviagas EasyPath, DuraEdge, USA). The positive control of immunohistochemistry reaction was performed using tissues that have the same constructive antigens as the antigen of interest. After immunohistochemistry processing, the slides were scanned through a Scanscope CS System unit (Aperio Technologies, Inc., CA, USA), with an objective 20x Olympus UPlanSApo with specifications 20x/0.75 attached to the scanner, generating image files in svx format. Scanned images were analyzed using the Aperio ImageScope viewing software (Aperio Technologies, Inc., CA, USA) that reports the percentage of positively stained area in relation to the total tissue area.

### Statistical analysis

Continuous variables are reported as mean and standard deviation or median and interquartile interval, depending on the assumption of normality. Categorical variables are reported as absolute and relative frequency. Values between groups were compared by unpaired Student *t* test after testing for normal distribution by KS test; otherwise, nonparametric Mann-Whitney U tests were used. Fisher exact or chi-square test was used for categorical variables with nominal scales. For comparison of artery tissue markers, Kruskal-Wallis test (or ANOVA, assumption of normality) was used, and, for non-parametric multiple comparisons, Tukey's test. A p-value lower than 0.05 was considered statistically significant. The SPSS version 19 was used.

To detect 3 units with standard deviation of 4, 80% test power, and 5% alpha, the sample size calculation is 105 cases.

## Results

### Clinical characteristics of study group

The frequencies of clinical characteristics (Table 1), such as sex, diabetes, dyslipidemia, smoking, previous stroke and heart attack, are similar in both groups. However, the stent group was younger and had a higher prevalence of ventricular dysfunction, characterized by an ejection fraction lower than 50%. The control group had a higher blood platelet count ( $269,560 \pm 74,461$ ) than the stent group ( $237,355 \pm 70,831$ ), but with no statistical significance ( $p = 0.12$ ). All patients were on statins and acetylsalicylic acid treatment.

The time between stent implantation and CABG was over 6 months. Nine patients (22%) had stent implanted within 6 and 12 months, 25 patients (61%) had only one stent, and 16 patients (39%) had two or more stents implanted.

### Gene expression in peripheral blood cells by real-time PCR

Total RNA from peripheral blood cells was obtained and the expression of the following genes was evaluated: *LIGHT*, *IL-6*, *ICAM*, *VCAM*, *CD40*, *NFKB*, *TNF*, *IFNG* and *GAPDH*. Of eight genes, the expression of only two differed between the stent and control groups: the expression of *TNF* was significantly higher ( $p = 0.0308$ ) in the stent group (Figure 1-f) and that of *CD40* was higher in the control group ( $p = 0.0106$ ) (Figure 1-a). No difference was detected in the expression of *IL-6*, *IFNG*, *LIGHT*, *NFKB*, *ICAM* and *VCAM* genes (Figure 1).

### Quantitative analysis by immunohistochemistry

The quantification of proteins staining by immunohistochemistry is presented in Table 2 and illustrated in Figures 2 and 3. The TNF-alpha staining in the arteries of the adipose tissue

was higher in group A1 than in group A2 ( $6.69 \pm 3.87$  vs  $2.27 \pm 4.00$ ;  $p < 0.001$ ) (Figure 2-a). In addition, group A1 had higher TNF-alpha staining in the intima-media region than group A3 did ( $5.16 \pm 5.05$  vs  $1.90 \pm 2.27$ ;  $p = 0.023$ ) (Figure 2-b). A large amount of TNF-alpha was detected in the cytoplasm of inflammatory cells and around the lipid core (Figure 3-C and D).

Higher IL-6 was detected in arteries of the adipose tissue of group A1 than in those of group A3 ( $2.29 \pm 1.96$  vs  $0.28 \pm 0.33$ ;  $p = 0.048$ ) (Figure 2-c), also observed under the microscope (Figure 3-E and F). There was no difference between groups in the quantification of the CD40, ICAM, VCAM, NFKB and IFN-gamma staining.

On histological examination, we identified major histocompatibility complex class II (MHCII) positive cells surrounding the lipid core, probably macrophages (Figure 3-A and B). These infiltrate cells also stained for TNF-alpha, being detected in adipose tissue and in intima layer (Figure 3-C and D). Fewer IL-6-positive infiltrate cells were also observed in the same layer of artery tissue (Figure 3-E and F).

## Discussion

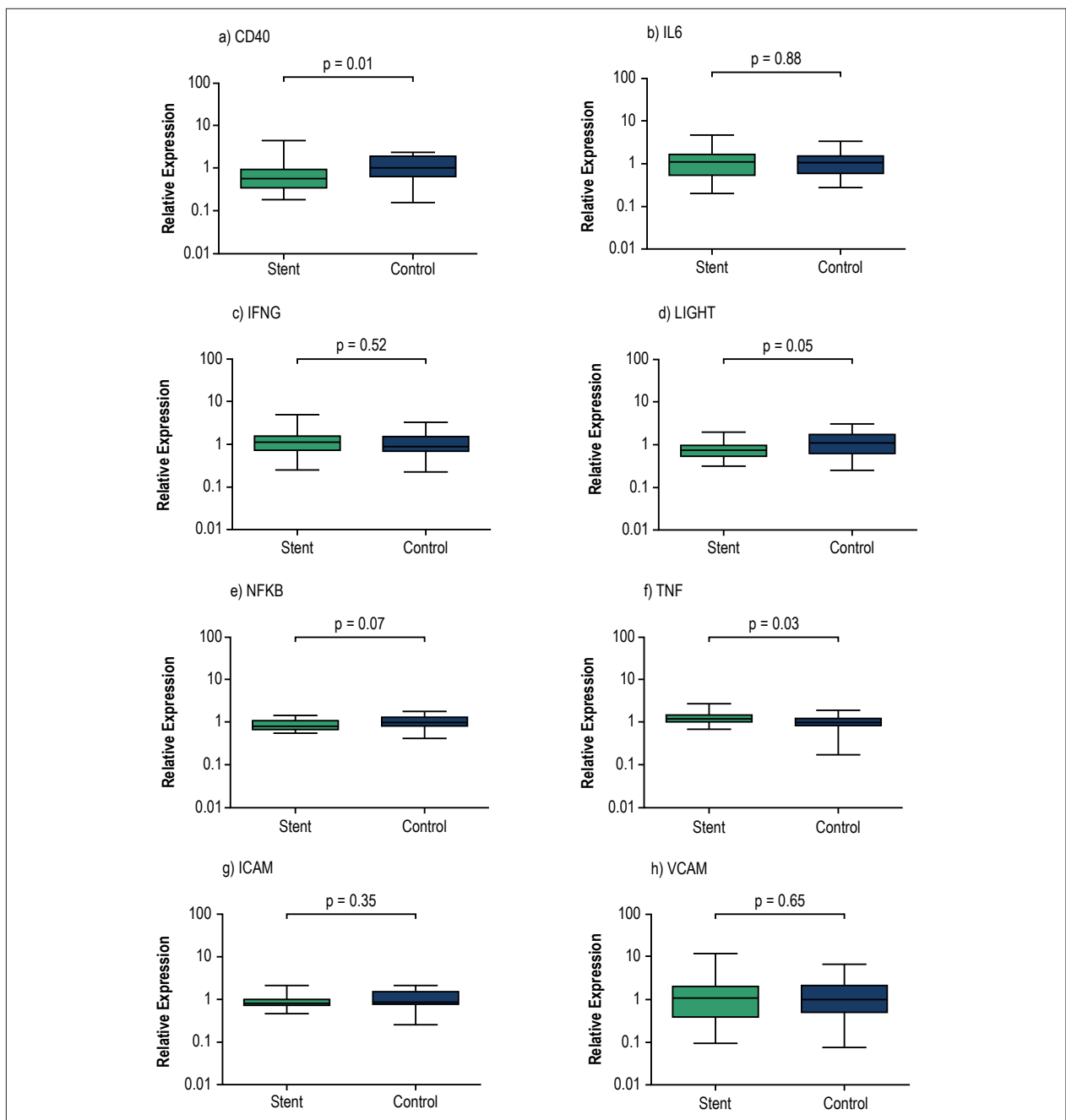
This study analyzed both the gene expression in peripheral blood cells and the protein localization in coronary artery tissues, to evaluate simultaneous systemic and local inflammation. A persistently higher *TNF-alpha* systemic expression was observed in peripheral blood cells, in addition to a local exacerbated TNF-alpha and IL-6 production in coronary arteries.

Our study evaluated, in stable patients, local coronary and systemic inflammation after stent implantation as compared to controls. All patients included had undergone PCI more than 6 months before and had CABG indication. Regarding stent implantation time, 9 of 41 patients (22%) were within one year

**Table 1 – Biodemographic data of the studied groups: with previous stent implantation and controls**

Variables	Stent Group	Control Group	p value
Cases	41	26	
Age (years)	$60.2 \pm 7.1$	$6.3 \pm 8.69$	0.004
Female (%)	13 (31.3)	8 (30.8)	0.58
Blood platelet count	$237.355 \pm 70.831$	$269.560 \pm 74.461$	0.12
Hypertension (%)	35 (85.4)	22 (84.6)	0.60
Diabetes (%)	17 (42.5)	8 (36.4)	0.42
Current smoking (%)	4 (10.5)	3 (14.3)	0.48
Stroke (%)	2 (5.3)	0	0.43
CKD (%)	2 (5.3)	0	0.43
Dyslipidemia (%)	25 (62.5)	16 (64)	0.56
MI (%)	14 (35.9)	5 (22.7)	0.22
LVEF < 50% (%)	14 (41.2)	2 (9.1)	0.009
ASA (%)	41 (100)	26 (100)	1.00
Statins (%)	41 (100)	26 (100)	1.00

CKD: chronic kidney disease; MI: myocardial infarction; LVEF: left ventricular ejection fraction; ASA: acetylsalicylic acid. Age and blood platelet count were expressed as mean  $\pm$  standard deviation. Sex, hypertension, diabetes, smoking, stroke, CKD, dyslipidemia, MI, LVEF < 50%, ASA use, and statin use are expressed in numbers and percentages of the patients studied. The statistical significance level adopted was  $p < 0.05$ .



**Figure 1** – Expression of inflammatory genes in peripheral blood. The expression of the genes CD40 (a), IL-6 (b), IFNG (c), LIGHT (d), NFKB (e), TNF (f), ICAM (g) and VCAM (h) was evaluated by real-time PCR using GAPDH gene as internal control to calculate relative expression ( $2^{-\Delta\Delta CT}$ ). The patients with coronary stent implantation ( $n = 35$ ) were compared with controls ( $n = 25$ ) using nonparametric Mann-Whitney U test. The difference is considered significant for  $p$ -values  $< 0.05$ .

from PCI, and 32 patients (78%) had it more than one year before. A former study showed that the inflammatory reaction inherent to PCI no longer exists in this period.<sup>12</sup> No patient with drug-eluted stent (DES) was enrolled in the present study. On the basis of previous literature, a higher number of T lymphocytes and macrophages is observed in DES lesions than in BMS lesions, suggesting the mechanism of restenosis after DES implantation may be different from that observed after BMS implantation.<sup>13</sup>

In this study, the gene expression in peripheral blood cells and the protein localization in coronary artery tissues were carried out to evaluate systemic and local inflammation, respectively. It is worth mentioning that CABG surgery represents a rare opportunity to obtain coronary tissue samples for research without harm to patients, that is why few previous studies worked with this kind of biological sample. In most of them, samples were obtained from the atherosclerotic plaque by endarterectomy.<sup>14,15</sup>

**Table 2 – Quantification of CD40, ICAM, VCAM, MHC-II, TNF-alpha, NFKB, IL-6 and IFN-gamma proteins in arterial intima-media layer, adventitia and adipose tissue by immunohistochemistry**

Protein	Artery layers	Group A1			Group A2			Group A3			p value ( $\alpha = 0.05$ )			
		n	mean	Std. dev	n	mean	Std. dev	n	mean	Std. dev	3 groups	1 vs 2	1 vs 3	2 vs 3
CD40	intima-media	16	1.37	2.02	27	1.51	1.73	23	1.11	1.56	0.55	ns	ns	ns
	Adventitia	13	0.70	0.77	26	0.82	0.71	19	1.27	1.66	0.58	ns	ns	ns
	Adipose tissue	3	0.73	0.12	6	0.62	0.58	9	0.58	0.74	0.45	ns	ns	ns
ICAM	intima-media	18	3.27	3.00	27	3.47	3.77	20	2.81	4.23	0.16	ns	ns	ns
	Adventitia	14	4.07	3.67	25	4.22	4.82	19	3.99	5.39	0.76	ns	ns	ns
	Adipose tissue	1	5.93	-	7	1.99	1.37	5	1.52	1.64	0.22	ns	ns	ns
VCAM	intima-media	14	11.88	16.01	24	10.33	9.64	23	7.88	6.12	0.76	ns	ns	ns
	Adventitia	11	4.69	8.39	19	4.09	4.74	21	2.56	2.26	0.68	ns	ns	ns
	Adipose tissue	2	4.31	5.28	4	1.76	1.22	4	0.32	0.36	0.10	ns	ns	ns
MHC II	total area	7	0.74	0.59	8	0.47	0.12	30	0.75	0.52	0.307	ns	ns	ns
	intima-media	15	5.16	5.05	24	3.11	3.01	21	1.90	2.27	0.03	ns	0.023	ns
TNF-alpha	Adventitia	14	4.05	2.82	21	2.28	2.24	20	3.57	5.95	0.10	ns	ns	ns
	Adipose tissue	4	6.69	3.88	4	1.27	0.84	9	2.27	4.00	0.05	0.001	ns	ns
	intima-media	14	1.11	1.14	24	0.93	0.88	20	0.92	1.07	0.96	ns	ns	ns
NFKB	Adventitia	14	0.64	0.61	21	0.83	0.78	19	0.76	0.55	0.65	ns	ns	ns
	Adipose tissue	2	1.18	0.87	6	0.52	0.44	6	1.63	2.58	0.66	ns	ns	ns
	intima-media	16	1.15	1.12	23	1.27	1.61	21	0.66	0.88	0.17	ns	ns	ns
Interleukin-6	Adventitia	15	1.65	2.04	20	1.65	2.02	21	0.91	0.74	0.69	ns	ns	ns
	Adipose tissue	4	1.12	1.03	3	2.29	1.96	11	0.28	0.33	0.01	ns	0.061	0.048
	intima-media	14	0.67	0.70	25	0.66	0.69	22	0.56	0.84	0.36	ns	ns	ns
IFN-gamma	Adventitia	12	0.52	0.41	20	0.59	0.54	21	0.40	0.46	0.36	ns	ns	ns
	Adipose tissue	3	0.54	0.53	4	0.14	0.10	7	0.10	0.11	0.13	ns	ns	ns

The comparison was performed among groups (Kruskal-Wallis test or ANOVA): A1 (arteries with stent), A2 (native arteries from patients with a stent in another artery), and A3 (control, patients without previous stent placement). The statistical significance level adopted was  $p < 0.05$ .

### Blood Analysis

The analysis of mRNA expression from circulating blood cells pointed out a significant higher expression of the *TNF* gene in the group with previous stent implantation than in controls (Figure 1-f), suggesting a greater activation of this gene in leukocytes from stented patients. This gene encodes a pleiotropic cytokine involved in a broad range of biological activities, including inflammation, cell survival, cell proliferation, and, paradoxically, cell death.<sup>16</sup>

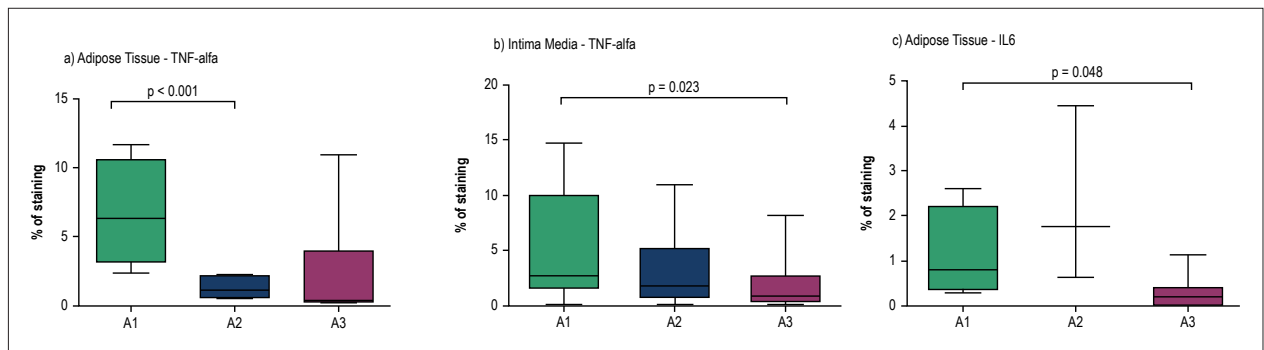
We also observed a significantly lower *CD40* gene expression in blood cells from the stent group than from controls (Figure 1-a). The *CD40* is the receptor for *CD40L*, being present in platelets. Gerdes et al.<sup>17</sup> have demonstrated in knockout mice for *CD40* and *ApoE* that platelet plays a crucial role in inflammation by stimulating leukocyte and endothelial cells activation, thereby promoting atherosclerosis.

### Coronary artery tissue samples

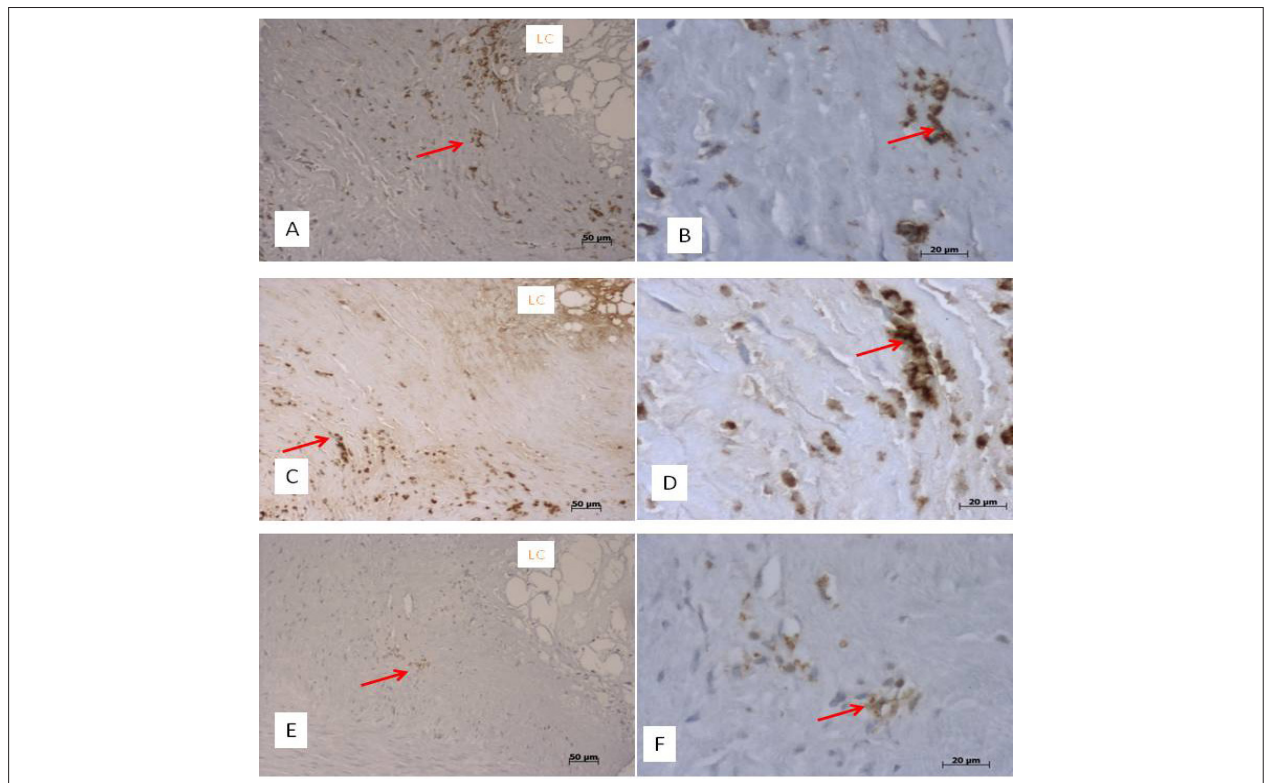
We analyzed the arterial tissue separated in three layers (adventitia, intima-media and adipose tissue) by *hematoxylin-eosin*

and immunohistochemistry staining. It is worth pointing that, although only few samples collected contained adipose tissue, due to the difficulty to obtain all layers in such small fragments, we could discriminate a greater amount of *TNF-alpha* and *IL-6* proteins in the adipose tissue from groups A1 and A2 than in that from controls (Figure 2-a and 2-c). The white adipose tissue is considered to be an endocrine gland, and the main feature is insulin and leptin resistance, as well as the production of inflammatory cytokines (*TNF-alpha* and *IL-6*) and monocyte chemoattractant protein,<sup>18,19</sup> which are involved in atherogenesis.<sup>20,21</sup> Interestingly, on the histological study, we observed activated immune cells, with *MHCII* expressed in membrane (Figure 3), surrounding the lipid core. Furthermore, these cells were colocalized with *TNF-alpha* and *IL-6* staining, suggesting a greater inflammatory response in the adipose tissue around the artery from individuals with previous stent placement.

The *TNF-alpha* protein was also expressed in higher quantity in intima-media layer from group A1 than from groups A2 and A3 (Figure 2-b). Probably immune cells migrated from circulation to that layer, mainly macrophages, which



**Figure 2** – Comparison of the staining of TNF-alpha and IL-6 proteins in different layers of arterial tissue. The analysis was performed comparing three groups: A1 (arteries with stent), A2 (native arteries from patient with a stent in another artery) and A3 (control, patients without previous stent placement). TNF-alpha protein staining was higher in the adipose tissue of group A1 ( $6.69 \pm 3.87$  vs  $2.27 \pm 4.00$ ;  $p < 0.001$ ) (a), as well as in the intima-media layer ( $5.16 \pm 5.05$  vs  $1.90 \pm 2.27$ ;  $p = 0.02$ ) (b). The IL-6 protein staining was also higher in the adipose tissue from group A1 than that from group A3 ( $2.29 \pm 1.96$  vs  $0.28 \pm 0.33$ ;  $p = 0.048$ ) (c). The Kruskal-Wallis test and nonparametric Tukey's multiple comparisons test were used for statistical analysis. The difference is considered significant for p-values  $< 0.05$ .



**Figure 3** – Panoramic (left side) and high-power view (right side) of immunostained arterial intima-media layer from individuals with previous stent implantation. Panels A and B show MHCII-positive cells, with morphology of macrophages (arrows), surrounding the lipid core (LC). Panels C and D show a large amount of TNF-alpha in the cytoplasm of inflammatory cells (arrows) and in the lipid core (LC). Panels E and F exhibit fewer inflammatory cells positive for IL-6 protein in similar sites (arrows).

are responsible for the production of that cytokine. Those are also MHCII-positive cells, primarily responsible for presenting antigenic peptides to T cells of the immune system.

Interleukin-6 is a multifunctional cytokine playing a central role in inflammation and tissue injury.<sup>22</sup> Interleukin-6 activates platelet receptor GPIIb/IIIa and leukocyte-platelet interaction, thus favoring the prothrombotic and atherogenic formation. Previous studies have shown that the increased circulating IL-6

is associated with the risk of coronary restenosis and *de novo* coronary artery lesions,<sup>23</sup> as well as the severity of stenosis.<sup>24</sup> The increase in IL-6 mRNA and protein has been observed in human arterial atherosclerotic wall. In this study, our data showed a significant higher amount of IL-6 protein in the coronary tissue of patients with previous stent placement than in that of controls, suggesting that local arterial inflammation is intensified by stent placement.

Our finding indicated the presence of persistent systemic and local chronic inflammation in individuals with previous stent implantation and can probably contribute to the worst outcome described in a previous meta-analysis study.<sup>7</sup>

It is known that persistent inflammatory response may result in several complications, such as atherosclerotic plaque formation in arterial vessels. In a substudy of the MASS II Trial,<sup>9</sup> consecutive angiographic results were compared with the progression of coronary artery atherosclerosis in medical treatment (MT), CABG and angioplasty. The authors have observed a greater progression in at least one native vessel in angioplasty patients than in CABG and MT patients, concluding that angioplasty treatment has the worst progression in native coronary arteries, especially in the left anterior descending territories. Our result also showed inflammation process in native arteries from individuals with previous stent implantation.

### Limitations

This study was limited to BMS. We had very few DES with restenosis and CABG indication. Because of the tiny size of the samples, only a small number of adipose tissue samples was obtained in group A2. Unfortunately, because of the tiny size, many samples collected were inadequate for analysis, and some had insufficient material for analysis. It is worth mentioning that the surgeon primarily ensures the patient's safety.

The arterial sample was collected at the least affected segment, for best surgical results in graft implantation, distal to the stent, place of possible less inflammation and less affected by the stent.

Restenosis is associated with a local and systemic inflammatory reaction that could be related to obstructive lesions in stented arteries. However, only nine patients were operated upon in less than 365 days, and the arterial samples were taken at least 10 mm after the stent implantation, which reduces its influence on the results.

Statin, which has known anti-inflammatory activity, can influence partially on this result, but it was minimized because all patients were under this therapeutic procedure that has a class I indication.

## References

1. Gaudino M, Cellini C, Pragliola C, Trani C, Burzotta F, Schiavoni G, et al. Arterial versus venous bypass grafts in patients with in-stent restenosis. *Circulation*. 2005;112(9 Suppl):I265-9.
2. Gomes WJ, Buffolo E. Coronary stenting and inflammation: implications for further surgical and medical treatment. *Ann Thorac Surg*. 2006;81(5):1918-25.
3. Hassan A, Buth KJ, Baskett RJ, Ali IS, Maitland A, Sullivan JA, et al. The association between prior percutaneous coronary intervention and short-term outcomes after coronary artery bypass grafting. *Am Heart J*. 2005;150(5):1026-31.
4. Rao C, Stanbridge Rde L, Chikwe J, Pepper J, Skapinakis P, Aziz O, et al. Does previous percutaneous coronary stenting compromise the long-term efficacy of subsequent coronary artery bypass surgery? A microsimulation study. *Ann Thorac Surg*. 2008;85(2):501-7.
5. Thielmann M, Leyh R, Massoudy P, Neuhäuser M, Aleksic I, Kamler M, et al. Prognostic significance of multiple previous percutaneous coronary interventions in patients undergoing elective coronary artery bypass surgery. *Circulation*. 2006;114(1 Suppl):I441-7.

## Conclusion

In conclusion, the persistently higher systemic expression of *TNF* in association with the local exacerbated *TNF*-alpha and *IL-6* production in coronary arteries with previous BMS implantation may contribute to worse clinical outcomes after CABG surgery.

## Author contributions

Conception and design of the research: Farsky PS, Hirata MH, Lima PHO, Lin-Wang HT; Acquisition of data: Farsky PS, Arnoni RT, Almeida AFS, Issa M, Lima PHO, Higuchi ML, Lin-Wang HT; Analysis and interpretation of the data: Farsky PS, Hirata MH, Arnoni RT, Almeida AFS, Issa M, Lima PHO, Higuchi ML, Lin-Wang HT; Statistical analysis: Lin-Wang HT; Obtaining financing: Farsky PS, Lima PHO; Writing of the manuscript: Farsky PS, Lin-Wang HT; Critical revision of the manuscript for intellectual content: Farsky PS, Hirata MH, Arnoni RT, Almeida AFS, Issa M, Lin-Wang HT.

## Potential Conflict of Interest

No potential conflict of interest relevant to this article was reported.

## Sources of Funding

This study was funded by FAPESP.

## Study Association

This article is part of the thesis of Post-Doctoral submitted by Pedro Silvio Farsky, from Instituto Dante Pazzanese de Cardiologia / Universidade de São Paulo.

## Ethics approval and consent to participate

This study was approved by the Ethics Committee of the Instituto de Cardiologia Dante Pazzanese under the protocol number 4059-2011. All the procedures in this study were in accordance with the 1975 Helsinki Declaration, updated in 2013. Informed consent was obtained from all participants included in the study.

6. Thielmann M, Neuhauser M, Knipp S, Kottenberg-Assenmacher E, Marr A, Pizanis N, et al. Prognostic impact of previous percutaneous coronary intervention in patients with diabetes mellitus and triple-vessel disease undergoing coronary artery bypass surgery. *J Thorac Cardiovasc Surg.* 2007;134(2):470-6.
7. Ueki C, Sakaguchi G, Akimoto T, Shintani T, Ohashi Y, Sato H. Influence of previous percutaneous coronary intervention on clinical outcome of coronary artery bypass grafting: a meta-analysis of comparative studies. *Interact Cardiovasc Thorac Surg.* 2015;20(4):531-7.
8. Yap CH, Yan BP, Akowuah E, Dinh DT, Smith JA, Shardey GC, et al. Does prior percutaneous coronary intervention adversely affect early and mid-term survival after coronary artery surgery? *JACC Cardiovasc Interv.* 2009;2(8):758-64.
9. Borges JC, Lopes N, Soares PR, Góis AF, Stolf NA, Oliveira SA, et al. Five-year follow-up of angiographic disease progression after medicine, angioplasty, or surgery. *J Cardiothorac Surg.* 2010 Oct 26;5:91.
10. Vandesompele J, De Preter K, Pattyn F, Poppe B, Van Roy N, De Paep A, et al. Accurate normalization of real-time quantitative RT-PCR data by geometric averaging of multiple internal control genes. *Genome Biol.* 2002 June 18;3(7):RESEARCH0034.
11. Livak KJ, Schmittgen TD. Analysis of relative gene expression data using real-time quantitative PCR and the 2(-Delta Delta C(T)) Method. *Methods.* 2001;25(4):402-8.
12. Wu M, Gu X, Li X, Li Y, Zhou H, Lu G, et al. C-reactive protein and inflammatory cytokines during percutaneous coronary intervention. *J Vasc Res.* 2016;53(1-2):39-48.
13. Yoneda S, Abe S, Kanaya T, Oda K, Nishino S, Kageyama M, et al. Late-phase inflammatory response as a feature of in-stent restenosis after drug-eluting stent implantation. *Coron Artery Dis.* 2013;24(5):368-73.
14. Kim WJ, Kang YJ, Suk K, Park JE, Kwon BS, Lee WH. Comparative analysis of the expression patterns of various TNFSF/TNFRSF in atherosclerotic plaques. *Immunol Invest.* 2008;37(4):359-73.
15. Depre C, Ribichini F, Wijns W. Morphological analysis of atherosclerotic plaque retrieved by coronary atherectomy. *Semin Interv Cardiol.* 2000;5(4):175-84.
16. Aggarwal BB. Signalling pathways of the TNF superfamily: a double-edged sword. *Nat Rev Immunol.* 2003;3(9):745-56.
17. Gerdes N, Seijkens T, Lievens D, Kuijpers MJ, Winkels H, Projahn D, et al. Platelet CD40 exacerbates atherosclerosis by transcellular activation of endothelial cells and leukocytes. *Arterioscler Thromb Vasc Biol.* 2016;36(3):482-90.
18. Wang P, Mariman E, Renes J, Keijer J. The secretory function of adipocytes in the physiology of white adipose tissue. *J Cell Physiol.* 2008;216(1):3-13.
19. Kuryszko J, Slawuta P, Sapikowski G. Secretory function of adipose tissue. *Pol J Vet Sci.* 2016;19(2):441-6.
20. Lee WH, Kim SH, Lee Y, Lee BB, Kwon B, Song H, et al. Tumor necrosis factor receptor superfamily 14 is involved in atherogenesis by inducing proinflammatory cytokines and matrix metalloproteinases. *Arterioscler Thromb Vasc Biol.* 2001;21(12):2004-10.
21. Schuett H, Luchtefeld M, Grothusen C, Grote K, Schieffer B. How much is too much? Interleukin-6 and its signalling in atherosclerosis. *Thromb Haemost.* 2009;102(2):215-22.
22. Hartman J, Frishman WH. Inflammation and atherosclerosis: a review of the role of interleukin-6 in the development of atherosclerosis and the potential for targeted drug therapy. *Cardiol Rev.* 2014;22(3):147-51.
23. Kazmierczak E, Grajek S, Kowal J, Chmara E, Grygier M, Pyda M, et al. Prognostic usefulness of IL-6 and VEGF for the occurrence of changes in coronary arteries of patients with stable angina and implanted stents. *Eur Rev Med Pharmacol Sci.* 2014;18(15):2169-75.
24. Szkodzinski J, Blazelonis A, Wilczek K, Hudzik B, Romanowski W, Gasior M, et al. The role of interleukin-6 and transforming growth factor-beta1 in predicting restenosis within stented infarct-related artery. *Int J Immunopathol Pharmacol.* 2009;22(2):493-500.

