

RESEARCH PAPER

Two vascular variations in one patient of the hepatogastric trunk and retro-aortic left renal vein

Guler Ibrahim, Mehmet Tugrul Yilmaz, Suat Keskin, Alpay Aribas, Dondu Akin, Mustafa Akcan, Ahmet Salbacak

Address for Correspondence:

Mehmet Tugrul Yilmaz

Meram Faculty of Medicine, Necmettin Erbakan University, Turkey

Email: mehmet_tugruly@yahoo.com

<http://dx.doi.org/10.5339/qmj.2013.15>

Submitted: 6 May 2013

Accepted: 15 December 2013

© 2013 Ibrahim, Yilmaz, Keskin, Aribas, Akin, Akcan, Salbacak, licensee Bloomsbury Qatar Foundation Journals. This is an open access article distributed under the terms of the Creative Commons Attribution license CC BY 3.0, which permits unrestricted use, distribution and reproduction in any medium, provided the original work is properly cited.

Cite this article as: Ibrahim G, Yilmaz MT, Keskin S, Aribas A, Akin D, Akcan M, Salbacak A. Two vascular variations in one patient of the hepatogastric trunk and retro-aortic left renal vein, Qatar Medical Journal 2013;15 <http://dx.doi.org/10.5339/qmj.2013.15>

ABSTRACT

This study reports the case of a 61-year-old man with right upper quadrant pain who underwent abdominal computed tomography examination. A solid lesion originating from the biliary tract was detected on the images. While evaluating the vascular structures, the splenic artery was seen to directly originate from the abdominal aorta. Retro-aortic left renal vein was also seen on computerised tomography. Splenic artery originating from the abdominal aorta is a rare variation. The retro-aortic left renal vein is a malformation characterized by the presence of a vessel that drains the left renal blood up to the inferior vena cava crossing behind the aortic artery. Such anatomical variations are important for surgeons to be aware of.

Keywords: variation, hepatogastric trunk, retro-aortic left renal vein, anatomic radiologic study

INTRODUCTION

The coeliac trunk (CT) is the first ventral branch of the abdominal aorta (AA). Just after passing through the aortic hiatus it arises from the AA at the level of T12-L1 vertebrae. It has a length of 1.5-2 cm and runs horizontally. It then divides into three branches – gastric artery (LGA), splenic artery (SA) and common hepatic artery (CHA). This trifurcation structure was defined by Haller for the first time in 1756 and is therefore called "Tripus Halleri". This definition of trifurcation made by Haller is still accepted today.⁽¹⁻²⁾ Renal veins are thick and are located in front of renal arteries. Both renal veins drain into the inferior vena cava (IVC) at the level of L1. The left renal vein (LRV) is longer than the right and has a more complex embryonic development and is thus anatomically

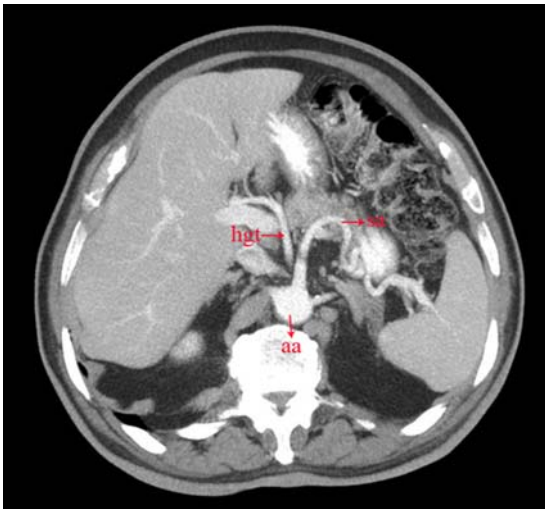


Figure 1. Hgt: Hepatogastric trunk; sa; splenic artery, aa; abdominal aorta. Splenic artery directly arises from the abdominal artery and hepatogastric trunk arises from the abdominal artery as seen in the CT image.

more complex than the right renal vein (RRV). Three anatomic variants of the LRV are present: pre-aortic, retro-aortic and circumaortic. Retro-aortic LRV route is oblique and opens to the IVC.⁽³⁻⁴⁾

CASE

A 61-year-old male patient who presented to the Meram Medical Faculty Hospital of Necmettin Erbakan University with abdominal complaints in the right upper quadrant underwent computerized tomography and was found to have a solid lesion originating from the biliary tract. Branch variation of the CT and route variation of the LRV was also seen while trifurcation of the CT was not observed. The CHA and LGA were as one root and formed the branch structure of the hepatogastric trunk (HGT) (Figure 1). The SA was seen to originate directly from the AA. The LRV was seen to have a retro-aortic route (Figure 2).

DISCUSSION

Having the knowledge of arterial variations is gaining importance in the improvement of surgical techniques, organ transplantations, diagnosis and treatment of various cancer cases. Therefore, knowing the variations of the coeliac trunk which supplies blood to a wide organ area is important. The CT is a thick vessel arising from the anterior face of the AA at the level of T11-12. Its distribution as the LGA, CHA and SA that was first

described by Heller, is still accepted as being the normal branch pattern of the CT. These branches however can originate from different arteries separately or, in combinations that originate from the CT.⁽¹⁻³⁾

Vandamme and Bonte⁽⁵⁾ reported the trifurcation structure of the CT as being 86% and bifurcation structure as 12% in cadavers. Prakash et al.,⁽⁶⁾ also reported this as 86% in their recent study, while Chen et al.,⁽⁷⁾ reported it as 89.8%. Although these studies report the classic trifurcation structure of the CT, some studies report cases where this does not occur.⁽⁷⁻¹¹⁾ Chen et al.⁽⁷⁾ studied the anatomic variations of the CT and hepatic artery in 974 cadavers. They reported the hepatosplenic trunk in 4.4% of cases and the gastrohepatic trunk in 0.3%. CHA was found to originate from the superior mesenteric artery in 3.5% of the cases, 0.5% originating directly from the AA and a hepatospleno-mesenteric and celiacomesenteric trunk in 0.7% respectively.

Salve and Ratanprabha⁽⁸⁾ reported the variations of branches of the AA in a middle-aged male cadaver. The CT was found to give off three branches, the first being the left inferior phrenic artery, then the LGA and lastly the SA and CHA as one root. In 1000 donor livers, Hiatt et al.⁽⁹⁾ reported the CHA originating from the CT in 75.7% of cases, the CHA originating from the LGA in 2.3% and the CHA originating directly from the AA in 0.2%. Lezzi et al.⁽¹⁰⁾ analyzed computerized tomography images for variations of the CT in 555 patients. They reported a normal anatomic structure

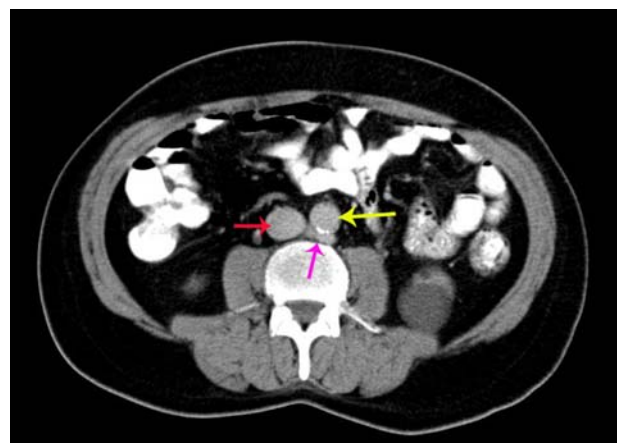


Figure 2. Red arrow: inferior vena cava; yellow arrow: abdominal aorta; pink arrow: retro-aortic left renal vein. Retro-aortic left renal vein passing behind the aorta to drain the inferior vena cava.

in 72.1% of cases with the CT giving off the CHA, LGA and SA branches. In 2.7% of the cases, it was observed that the hepatosplenic trunk existed with the LGA originating directly from the AA. HGT was reported as 5%, hepato-splenic-mesenteric trunk as 0.4% and spleno-gastric trunk as 3.6%.

In the current study, there was a route variation of the renal vein as well as variation of the CT branches. The course of the LRV was retro-aortic which opened to the IVC as it completed its route obliquely. Being aware of the existence of LRV anomalies is very important in planning retroperitoneal surgery, vascular interventions and differential diagnosis of retroperitoneal lymphadenopathies. The presence of the LRV that opens to the IVC by passing in front of the aorta (normal pre-aortic route), opens to the IVC by crossing the aorta posteriorly (retro-aortic renal vein), opens to the IVC from different levels by crossing the aorta both anteriorly and posteriorly and forming a venous circle (circumaortic renal vein), has been previously defined in the literature.^(11–16)

The variation in the percentage findings of the retro-aortic LRV route could be attributed to different

methods used in studies to detect its presence. Dilli et al.⁽¹³⁾ reported it as being 0.4% among 2644 patients through MRI evaluation, Kulkarni et al.⁽¹⁴⁾ as 1% in their studies on 102 MDCT images and Koç et al.⁽¹⁵⁾ as 5.9% among 324 MDCT images. Satyapal et al.⁽¹⁶⁾ analysed a total of 1008 cases by cadaveric and clinical studies and reported 0.5% retro-aortic LRV anomalies and 0.3% circumaortic LRV anomalies. Karazincir et al.⁽¹⁷⁾ reported retro-aortic LRV as 9.3% in their ultrasonographic study, which stands out as a much higher percentage compared to the above mentioned studies conducted on patients with varicocele.

CONCLUSION

We believe that knowing the route and branch variations of the vessels we mentioned in our study can be beneficial, particularly for making vessel anastomoses during liver and kidney transplantations, improvement of diagnosis and treatment of various cases of cancer, planning of radiologic catheter replacements, preventing vascular injuries during surgical interventions and also for educational purposes.

REFERENCES

1. Hemanth K, Garg S, Yadav TD, Sahni D, Singh R. Hepato-gastro-phrenic trunk and hepato-spleno-mesenteric trunk: a rare anatomic variation. *Trop Gastroenterol*. 2011;32(1):56–59.
2. Antony Sylvan D'Souza, Vijayalakshmi, Hemalatha, Pugazhandhi, Mamatha H. Anatomical variations in the branches of the coeliac trunk. *JCDR*. 2012;6(3):333–335.
3. Standring S. *Gray's Anatomy, anatomical basis of clinical practice*. 40 edn: Elsevier Churchill livingstone; 2008.
4. Yesildag A, Adanir E, Koroglu M, Baykal B, Oyar O, Gulsoy UK. Incidence of left renal vein anomalies in routine abdominal CT scans. *Tani Girisim Radyol*. 2004;10(2):140–143.
5. Vandamme JP, Bonte J. The branches of the celiac trunk. *Acta Anatomica*. 1985;122:110–114.
6. Prakash RT, Mokhasi V, Geethanjali BS, Sivacharan PV, Shashirekha M. Coeliac trunk and its branches: anatomical variations and clinical implications. *Singapore Med J*. 2012;53(5):329–331.
7. Chen H, Yano R, Emura S, Shoumura S. Anatomic variation of the celiac trunk with special reference to hepatic artery patterns. *Ann Anat*. 2009;191(4):399–407.
8. Salve VM, Ratanprabha C. Multiple variations of branches of abdominal aorta. *Kathmandu Univ Med J (KUMJ)*. 2011;9(33):72–76.
9. Hiatt JR, Gabbay J, Busuttill RW. Surgical anatomy of the hepatic arteries in 1000 cases. *Ann Surg*. 1994;220(1):50–52.
10. Lezzi R, Cotroneo AR, Giancristofaro D, Santoro M, Storto ML, Multidetector-row CT. angiographic imaging of the celiac trunk: anatomy and normal variants. *Surg Radiol Anat*. 2008 Jun;30(4):303–310.
11. Parikh SJ, Peters JC, Kihm RH. The anomalous left renal vein: CT appearance and clinical implications. *J Comput Tomogr*. 1981 Dec;5(6):529–533.
12. Kumar D, Kumar S. Case report. Circumaortic left renal vein. *J Comput Tomogr*. 1981;5(6):914–916.
13. Dilli A, Ayaz UY, Karabacak OR, Tatar IG, Hekimoglu B. Study of the left renal variations by means of magnetic resonance imaging. *Surg Radiol Anat*. 2012;34(3):267–270.

14. Kulkarni S, Emre S, Arvelakis A, Asch W, Bia M, Formica R, Israel G, Multidetector CT. angiography in living donor renal transplantation: accuracy and discrepancies in right venous anatomy. *Clin Transplant*. 2011;25(1):77–82.
15. Koc Z, Ulsan S, Oguzkurt L. Association of left renal vein variations and pelvic varices in abdominal MDCT. *Eur Radiol*. 2007;17(5):1267–1274.
16. Satyapal KS, Kalideen JM, Haffejee AA, Singh B, Robbs JV. Left renal vein variations. *Surg Radiol Anat*. 1999;21(1):77–81.
17. Karazincir S, Balci A, Gorur S, Sumbas H, Kiper AN. Incidence of the retroaortic left renal vein in patients with varicocele. *J Ultrasound Med*. 2007;26(5):601–604.