


# Sagittal Deformity Correction in a Patient Suffering From Diffuse Idiopathic Skeletal Hyperostosis Who Previously Underwent a Total Hip and Bilateral Knee Replacement

Geriatric Orthopaedic Surgery  
& Rehabilitation  
Volume 12: 1-5  
© The Author(s) 2021  
Article reuse guidelines:  
sagepub.com/journals-permissions  
DOI: 10.1177/2151459321992745  
journals.sagepub.com/home/gos



Victor Garcia-Martin, MD<sup>1</sup> , Ana Verdejo-González, MD<sup>2</sup>,  
David Ruiz-Picazo, MD<sup>2</sup>, and José Ramírez-Villaescusa, PhD<sup>2</sup>

## Abstract

**Introduction:** Physiological aging frequently leads to degenerative changes and spinal deformity. In patients with hypolordotic fusions or ankylosing illnesses such as diffuse idiopathic skeletal hyperostosis or ankylosing spondylitis, compensation mechanisms can be altered causing severe pain and disability. In addition, if a total hip replacement and/or knee replacement is performed, both pelvic and lower limbs compensation mechanisms could be damaged and prosthetic dislocation or impingement syndrome could be present. Pedicle subtraction osteotomy has proven to be the optimal correction technique for spinal deformation in patients suffering from a rigid spine. **Case Presentation:** A 70-year-old male patient with diffuse idiopathic skeletal hyperostosis criteria and a rigid lumbar kyphosis, who previously underwent a total hip and knee replacement, had severe disability. We then performed corrective surgery by doing a pedicle subtraction osteotomy. The procedure and outcomes are presented here. **Conclusion:** In symptomatic patients with sagittal imbalance and a rigid spine, pedicle subtraction osteotomy can indeed correct spinal deformity and re-establish sagittal balance.

## Keywords

diffuse idiopathic skeletal hyperostosis, pedicle subtraction osteotomy, sagittal imbalance, total hip arthroplasty, total knee arthroplasty

Submitted August 12, 2020. Revised January 09, 2021. Accepted January 14, 2021.

## Introduction

The presence of spinal sagittal deformity related to degenerative changes has been linked to the presence of pain and severe impairment in different life quality scores, such as the Visual Analog Scale (VAS) and the Oswestry Disability Index (ODI). The spinal and pelvic-spinal items, which are appraised by standing X-rays, allow us to evaluate the characteristics of the deformity, as well as the possible compensation mechanisms.<sup>1</sup>

Severe pain and impairment in the elderly can be reduced by adopting sitting or supine positions. Nevertheless, in patients with a rigid deformity due to ankylosing spondylitis (AS) or to diffuse idiopathic skeletal hyperostosis (DISH),<sup>2</sup> functional limitation can be increased since compensation mechanisms may be limited. Furthermore, it usually happens also in patients who have undergone a total hip (THA) or knee (TKA) arthroplasty, which can affect both pelvic retroversion and knee flexion as compensatory mechanisms.

Pedicle subtraction osteotomy (PSO) has shown to be effective as a sagittal deformity corrective technique in symptomatic patients with a rigid spine. However, this technique has been linked to important risks, such as mechanical ones, blood loss and neurological damage.<sup>3</sup>

## Case Report

A 70-year-old male patient reported suffering from lumbosacral pain and walking difficulty for several months.

<sup>1</sup> Hospital Universitario HM Montepríncipe, Madrid, Spain

<sup>2</sup> Complejo Hospitalario Universitario de Albacete, Albacete, Spain

### Corresponding Author:

Victor Garcia-Martin, MD, Hospital Universitario HM Montepríncipe, Av. de Montepríncipe, 25, 28660 Boadilla del Monte, Madrid 28660, Spain.  
Email: vgmcot@gmail.com



From his personal medical history, he had arterial hypertension disturbance and he had undergone a bilateral total knee replacement and a total right hip replacement several years ago. He did not refer claudication and nor neurological damage was found during the clinical examination. The patient referred important impairment since he found it difficult to maintain an upright position, presenting a limitation to keep the horizontal field of vision, and needing a walking stick to stand still and to walk.

A standing full spine X-ray assessment showed rigid spine signs with anterior spinal osteophytes due to the calcification of the anterior longitudinal ligament (ALL), which is compatible with DISH. The sagittal vertical axis (SVA) C7-S1 was 22 cm, the lumbar lordosis (LL) was 10°, and the spinopelvic parameters showed a pelvic incidence (PI) of 46°, a sacral slope (SS) of 23° and a pelvic tilt (PT) of 23° (Figure 1). In the pelvic and lower limbs X-Ray images, both pelvic and knee replacements were adequately positioned. The acetabular component inclination angle was 59° and anteversion cup angle of 24.6°. Measurements were performed following Lewinnek method using Surgimap (Nemaris) software. The magnetic resonance (MR) revealed a decrease of LL and signs of moderate lumbar spinal stenosis, mostly at the L3-L4 level. Supine decubitus with bolster in the apex of the deformity X-Ray image was done to check for deformity's flexibility (Figure 2).

Information about the different surgical and non-surgical options was provided to the patient. After trying medical treatment with no clinical response, a surgical procedure by a spinal osteotomy was agreed with the patient.

Positioning the patient in prone, using somatosensory evoked potentials (SSEP), motor evoked potential (MEP) and electromyography (EMG) monitoring, a posterior approach was performed, which began with the subperiosteal dissection of paravertebral muscles and bilateral T11-S1 pedicle (except from L3) and iliac screws were used. This was followed by an L2 partial inferior and an L4 partial superior laminectomy, with the facetectomy of both L2 inferior facet joints, were performed. Then, an L3 pedicle subtraction osteotomy was performed. At the L4-L5 levels, a circumferential arthrodesis via transforaminal interbody fusion (TLIF) with interbody Polyetheretherketone (PEEK) implants and autologous bone from the posterosuperior iliac spine (PSIS) was performed. Finally, a T11-S1 postero-lateral arthrodesis with autologous bone from the surgical field was executed to prevent mechanical failure.

In the immediate postoperative period, surgical wound drainage was observed, with the microbiological confirmation of an infection by *Klebsiella oxytoca*, *Enterococcus faecalis*, *Corynebacterium amycolatum* and *Fingoldia magna*, which was treated and resolved after debridement, irrigation and antibiotics, without any further complications.

Two years after the surgery, good clinical assessment was observed, not referring any lumbosacral pain or neurological damage and not needing the use of a walking stick. The X-ray images showed improvement presenting the following and in comparison to the previous 2 years as follows: a SVA of 64 mm

(from a SVA of 22 cm), a LL of 30° (from 10°), PI of 46°, a SS of 18° (from 23°) and a PT of 28° (from 23°). Postoperative inclination angle of acetabular cup was 59° and anteversion of 27.7°. Complications related to THA such as impingement or luxation were not observed (Figure 3).

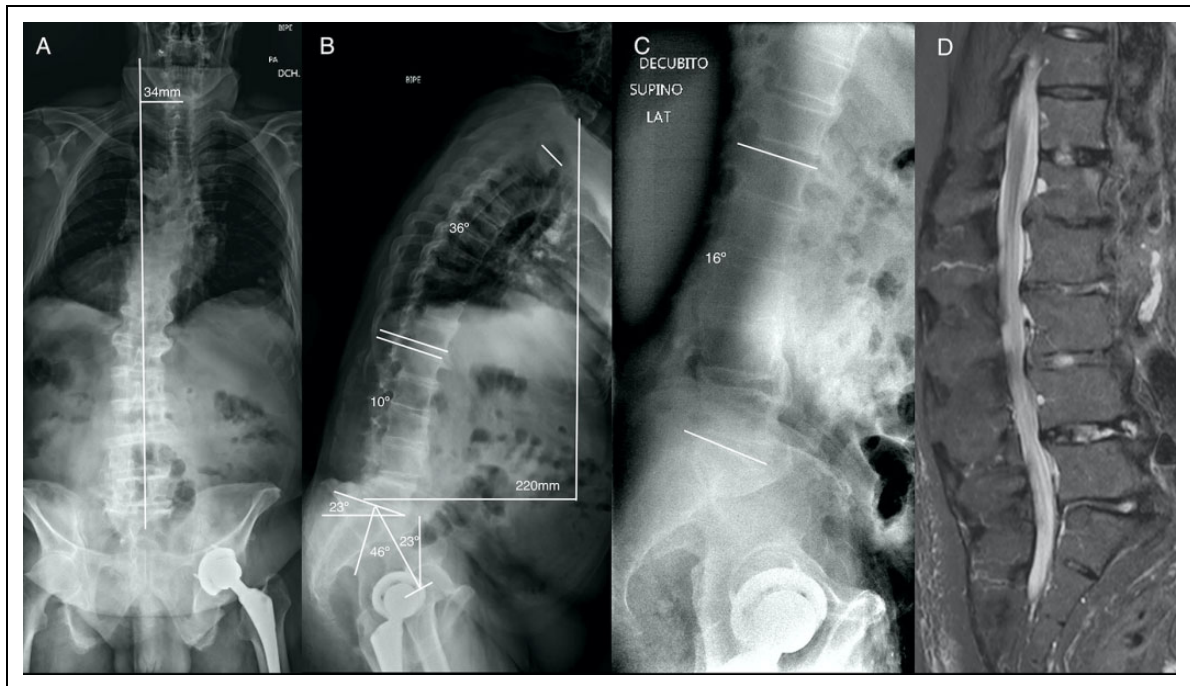## Discussion

Changes determining the loss of normal relationship between spinal curves are common in adults due to degenerative changes associated with aging, which can alter both sagittal and coronal planes. Coronal and mostly sagittal deformities are evaluated by the loss of the relation between spinal and pelvic parameters and have been linked to the development of pain and functional limitation, producing severe disability. This has been described in different life quality scores (VAS and ODI).<sup>1</sup>

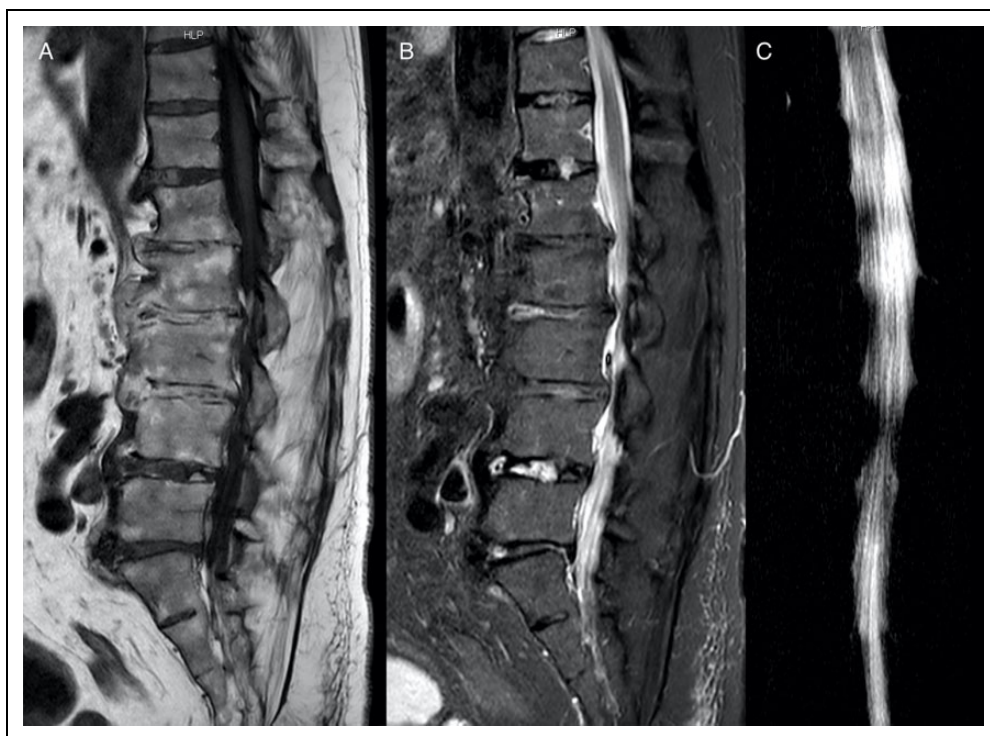
DISH is a common disease that can lead to rigidity in the elderly, having a multifactorial origin and a varying prevalence depending on the criteria used. Even though there is not a unified diagnosis, Resnick and Niwayama criteria are commonly accepted: calcification along the ALL of at least 4 contiguous vertebral bodies, the absence of apophyseal joint bony ankylosis without sacroiliac joint affection, and the relative preservation of intervertebral discs.<sup>2</sup> Finally, the ossification of the ALL is responsible for the stiffness of the affected segments.

Although DISH does not usually produce symptoms, spinal location in these patients can produce pain, stiffness and a higher risk of suffering hyperextension vertebral body fractures.<sup>4</sup> The thoracic spine is the most commonly affected area (76%) and the symptoms include difficult breathing. The affection of the cervical spine can produce dysphagia due to compression of the esophagus by osteophytes.<sup>5</sup> When it affects the lumbar spine, the restriction of multiple mobile segments can limit the increase of lumbar lordosis as the first compensatory mechanism of the sagittal deformity. Moreover, as it is in this case, compensatory hypermobility of the mobile segments associated to previous degenerative changes leads to lumbar canal stenosis, increasing disability.<sup>6</sup> Furthermore, DISH patients frequently suffer from aging-related hip and knee changes, aging-related and associated to hypermobility, needing a joint replacement. The presence of THA and/or TKA in patients with rigid and unbalanced spine deformity spine, which is frequent in an ankylosing condition such as DISH, can compromise the compensation mechanism of pelvic retroversion and knee flexion. Patients who have unbalanced and rigid spine should preferentially consider some spinal realignment technique prior to THA thus converting to a rigid and balanced orientation.

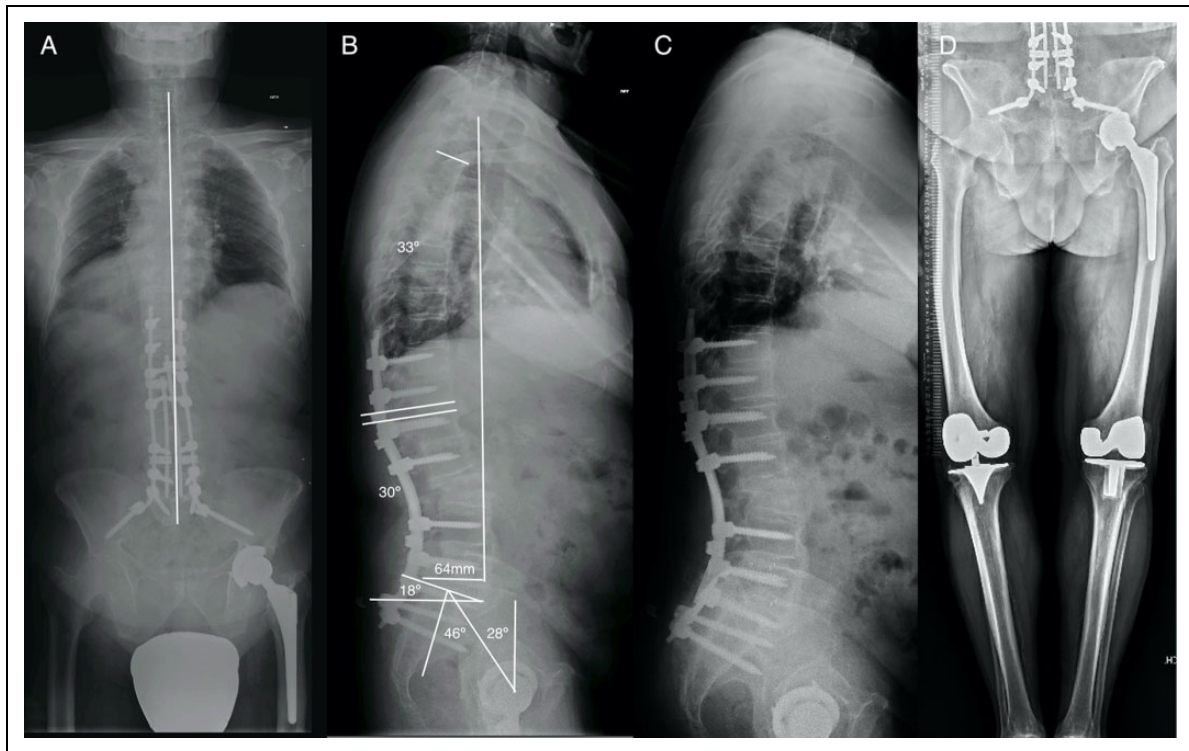
In our patient, the loss of lumbar lordosis had caused a rigid lumbar kyphosis limiting the first compensation mechanism in spine lumbar location (hyperlordosis). The stiffness of lumbar segments was evaluated by X-ray in supine decubitus with bolster support in the apex of the deformity, as part of the preparation for the procedure, although it could be seen indirectly in sagittal MR. If sagittal deformity still persists after



**Figure 1.** Standing full spine x-ray preoperative antero-posterior and sagittal view. A: Coronal imbalance of 34 mm is shown in PA view drawing central vertical line sacral (CLVS). B: In sagittal view, the presence of calcification and ossification along the anterior aspects of at least 4 contiguous vertebral bodies. Pelvic parameters: Pelvic incidence (PI) of 46°, Sacral slope (SS) of 23° and a Pelvic tilt (PT) of 23°. Spinal parameters: Thoracic kyphosis (TK) 36° and Lumbar lordosis (LL) was 10°. The sagittal vertical axis (SVA) C7-S1 was 22 cm. C: Lumbar lordosis (LL) in sagittal x-ray lateral decubitus and sagittal view of MR images don't change regarding standing position indicating rigid deformity.



**Figure 2.** Magnetic resonance (MR). A/B/C: T1, T2-weighted and STIR sequences. The relative preservation of disc height in the evolved areas and the absence of extensive radiographic changes of degenerative disc disease (intervertebral osteochondrosis) were observed. No changes were observed in sagittal view in lumbar lordosis (standing) suggest rigid deformity. D: Mielography-RM: Moderate lumbar canal stenosis was seen at level L3-L4.



**Figure 3.** Full spine standing X-Ray postoperative study. A: Coronal view. An adequate coronal balance is shown drawing CSVL (Central Sacral Vertical Line). B: Sagittal view. Lumbar lordosis (LL) 30°, a PT of 28°, a PI of 46°, and a SS of 18° and also improved SVA of 64 mm. C: Sagittal x-ray images at 2-years of follow-up. D: Full lower limbs standing x-ray shows no length discrepancy and bilateral total TKA and right THA well positioned.

increased lordosis as the first compensation mechanism, an increase in pelvic retroversion occurs with an increase in the pelvic tilt. However, this is a strenuous mechanism and the increase of the posterior tilt plus the presence of a THA, change the acetabulum position with an anterior opening of the acetabular cup<sup>7</sup> and the risk of an anterior dislocation, as well as a posterior crush (impingement syndrome) could limit the compensatory effect.<sup>8</sup>

The above events did not occur in our patient. However, they should be taken into account. The acetabulum and anteversion varying as a part of the pelvis and will change in standing (anteversion) or sitting (retroversion) position. The first procedure in patients with coxarthrosis and rigid and disbalanced spine with pelvic tilt  $>25^\circ$  or PI-LL  $>10^\circ$  (kyphotic “flat black-spine”) would be to undergo spinal realignment and secondly placing the acetabular component in a position that replicates the balanced spine, as patients who proceed to THA in unbalanced spine may require revision of the acetabular component.<sup>9</sup> Moreover, in case of PI  $>40^\circ$ , PI-LL mismatch and abnormal C7 plumb line with severe sagittal imbalance (spine-hip relation uncompensated staged), anti-dislocation modern high tolerant implants with large head and head-neck ratio such as dual mobility implants, lower the risk of articular impingement and edge loading. Finally, in these cases, an adjustment of the cup orientation with more anteversion and inclination would probably reduce the risk.<sup>10</sup>

Surgical treatment is considered to be the best option when there is an important functional limitation that responds to neither medical nor physical treatment. Spinal osteotomy, as an alignment technique, tries to correct sagittal deformity by increasing lumbar lordosis, although it is not free of risks. The selection of corrective osteotomy depends on the type of sagittal imbalance, mobile or marked and rigid deformity patterns, location of deformity, prior surgeries or residual implants and patient characteristics. The type of osteotomy resection has been described depending on the grade of the angular correction.<sup>11</sup> In patients with a sagittal deformity due to a rigid spine with a decrease of lumbar kyphosis or lordosis, posterior Smith-Petersen osteotomies (SPO) do not enable an adequate correction because of the absence of mobile segments. Three-column PSO has been selected as the technique of choice when there is a rigid spine, the need to correct more than  $25^\circ$  and an SVA larger than 10 cm.<sup>12</sup> PSO technique has a high number of major complications (29.4%) such as dural tears (5.9%), neurologic deficit (3.8%), wound infection (3.8%), wound or epidural hematoma (3%), and pseudoarthrosis or implant failure (1.7%)<sup>13</sup>. In patients with a rigid spine, vertebral subluxations have been described as an immediate complication.<sup>14</sup>

Our patient was suffering from a rigid spine with a lumbar lordosis of  $0^\circ$  and a SVA of 22 cm. He underwent an L3 PSO in the apical region of the deformity improving the LL by  $30^\circ$ ,



although a pelvic tilt reduction is greater when the osteotomy is performed at more caudal levels.<sup>15</sup> There was a minimal blood loss during the procedure, so blood transfusion was not needed, and no neurological alteration was caused. A minimal vertebral subluxation was observed after the closure of the osteotomy, without any further consequences. During the postoperative period, the patient had a surgical wound infection that was resolved after antibiotic treatment. On the other hand, the use of interbody implants in lower levels and the use of 2 supplementary rods have proven to be useful to prevent mechanical failure that could lead to implant break.<sup>16</sup> In the postoperative X-Rays, a slight under-correction was observed (LL 30°, PI 48°), which was well tolerated by the patient and remained stable after 2 years of follow-up.

## Conclusions

We report a successful sagittal deformity correction surgery in a 70-year-old patient who presented diffuse idiopathic skeletal hyperostosis and had previously undergone a total hip and bilateral knee replacement.

In symptomatic patients with sagittal imbalance and a rigid spine, pedicle subtraction osteotomy can indeed correct spinal deformity and re-establish sagittal balance.

## Declaration of Conflicting Interests

The author(s) declared no potential conflicts of interest with respect to the research, authorship, and/or publication of this article.

## Funding

The author(s) received no financial support for the research, authorship, and/or publication of this article.

## ORCID iD

Victor Garcia-Martin, MD  <https://orcid.org/0000-0003-1643-8886>

## References

- Schwab F, Patel A, Ungar B, Farcy J-P, Lafage V. Adult spinal deformity-postoperative standing imbalance: how much can you tolerate? An overview of key parameters in assessing alignment and planning corrective surgery. *Spine*. 2010;35(25):2224-2231.
- Resnick D, Niwayama G. Radiographic and pathologic features of spinal involvement in diffuse idiopathic skeletal hyperostosis (DISH). *Radiology*. 1976;119(3):559-568.
- Barrey C, Perrin G, Michel F, Vital J-M, Obeid I. Pedicle subtraction osteotomy in the lumbar spine: indications, technical aspects, results and complications. *Eur J Orthop Surg Traumatol Orthop Traumatol*. 2014;24(1):S21-30.
- Caron T, Bransford R, Nguyen Q, Agel J, Chapman J, Bellabarba C. Spine fractures in patients with ankylosing spinal disorders. *Spine*. 2010;35(11):E458-464.
- Karaarslan N, Gürbüz MS, Çalışkan T, Simsek AT. Forestier syndrome presenting with dysphagia: case report of a rare presentation. *J Spine Surg*. 2017;3(4):723-726.
- Yamada K, Toyoda H, Terai H, Takahashi S, Nakamura H. Spinopelvic alignment of diffuse idiopathic skeletal hyperostosis in lumbar spinal stenosis. *Eur Spine J Off Publ Eur Spine Soc Eur Spinal Deform Soc Eur Sect Cerv Spine Res Soc*. 2014;23(6):1302-1308.
- Buckland AJ, Vigdorichik J, Schwab FJ, et al. Acetabular anteversion changes due to spinal deformity correction: bridging the gap between hip and spine surgeons. *J Bone Jt Surg-Am Vol*. 2015;97(23):1913-1920.
- Lazennec JY, Brusson A, Rousseau MA. Lumbar-pelvic-femoral balance on sitting and standing lateral radiographs. *Orthop Traumatol Surg Res OTSR*. 2013;99(1 Suppl):S87-103.
- Phan D, Bederman SS, Schwarzkopf R. The influence of sagittal spinal deformity on anteversion of the acetabular component in total hip arthroplasty. *Bone Jt J*. 2015;97-B(8):1017-1023.
- Rivière C, Lazennec J-Y, Van Der Straeten C, Auvinet E, Cobb J, Muirhead-Allwood S. The influence of spine-hip relations on total hip replacement: a systematic review. *Orthop Traumatol Surg Res*. 2017;103(4):559-568.
- Schwab F, Blondel B, Chay E, et al. The comprehensive anatomical spinal osteotomy classification. *Neurosurgery*. 2014;74(1):112-120; discussion 120.
- Gupta S, Gupta MC. The nuances of pedicle subtraction osteotomies. *Neurosurg Clin N Am*. 2018;29(3):355-363.
- Smith JS, Sansur CA, Donaldson WF, Perra JH, Mudiyan R, Choma TJ, et al. Short-term morbidity and mortality associated with correction of thoracolumbar fixed sagittal plane deformity: A Report from the Scoliosis Research Society Morbidity and Mortality Committee. *Spine*. 2011;36(12):958-64.
- Qian B-P, Mao S-H, Jiang J, Wang B, Qiu Y. Mechanisms, predisposing factors, and prognosis of intraoperative vertebral subluxation during pedicle subtraction osteotomy in surgical correction of thoracolumbar kyphosis secondary to ankylosing spondylitis. *Spine*. 2017;42(16):E983-990.
- Lafage V, Schwab F, Vira S, et al. Does vertebral level of pedicle subtraction osteotomy correlate with degree of spinopelvic parameter correction? Clinical article. *J Neurosurg Spine*. 2011;14(2):184-191.
- Berjano P, Xu M, Damilano M, et al. Supplementary delta-rod configurations provide superior stiffness and reduced rod stress compared to traditional multiple-rod configurations after pedicle subtraction osteotomy: a finite element study. *Eur Spine J Off Publ Eur Spine Soc Eur Spinal Deform Soc Eur Sect Cerv Spine Res Soc*. 2019;28(9):2198-2207.