

Received: 2018.03.04
Accepted: 2018.04.23
Published: 2018.09.07

Effect of Immunosuppressive Therapy on the Occurrence of Atypical Hemolytic Uremic Syndrome in Renal Transplant Recipients

Authors' Contribution:
Study Design A
Data Collection B
Statistical Analysis C
Data Interpretation D
Manuscript Preparation E
Literature Search F
Funds Collection G

ABCDEF 1,2 **Rupesh Raina**
ABCDEF 3 **Abigail Chauvin**
ABCDEF 4 **Kelli Fox**
ABCDEF 3 **Natasha Kesav**
ABCDEF 5 **Mustafa Ascha**
ABCDEF 6 **Tushar J. Vachharajani**
ABCDEF 2 **Vinod Krishnappa**

1 Department of Nephrology, Cleveland Clinic Akron General and Akron Children Hospital, Akron, OH, U.S.A.
2 Akron Nephrology Associates/Cleveland Clinic Akron General, Akron, OH, U.S.A.
3 Northeast Ohio Medical University, Rootstown, OH, U.S.A.
4 Lake Erie College of Osteopathic Medicine, Brandenton, FL, U.S.A.
5 Center for Clinical Investigation, Department of Epidemiology and Biostatistics, Case Western Reserve University, Cleveland, OH, U.S.A.
6 Division of Nephrology and Hypertension, Salisbury VA Health Care System, Salisbury, NC, U.S.A.

Corresponding Author: Rupesh Raina, e-mail: rrain@akronchildrens.org and raina@akronnephrology.com
Source of support: None

Background: Atypical hemolytic uremic syndrome (aHUS), a rare thrombotic microangiopathy, is characterized by hemolytic anemia, thrombocytopenia, and acute renal failure. Caused by genetic mutations in the alternative complement cascade, aHUS often will culminate in end-stage renal disease and occasionally death. Renal transplantation in aHUS patients has been contraindicated in the past due to the recurrence risk, with certain immunosuppressive regimens being commonly attributed. In this study, we analyzed the association between aHUS and immunosuppressive agents so as to offer evidence for the use of certain immunosuppressive regimens in renal transplant recipients.

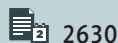
Material/Methods: Our study is a retrospective analysis using data from the United States Renal Data System from 2004 to 2012. A cohort of renal transplantation patients diagnosed with aHUS were identified to include in the study. The primary endpoint was the determination of aHUS incidence in renal transplant recipients due to various immunosuppressive agents. The secondary endpoints were to check the relationship between the drug type as well as the demographic variables that increase the risk for aHUS.

Results: It was found that there was a higher usage of sirolimus ($P=0.015$) and corticosteroids ($P=0.030$) in the aHUS patients compared to patients in other diagnoses group.

Conclusions: There was a higher usage of sirolimus and corticosteroids in renal transplantation patients diagnosed with aHUS. Unfortunately, due to the rarity of this disease, the sample size was small ($n=14$). Despite the small sample size, this data analysis throws light on the relationship between aHUS and immunosuppressive agents in renal transplant recipients, although we still have much to learn.

MeSH Keywords: Hemolytic-Uremic Syndrome • Immunosuppression • Kidney Transplantation • Thrombotic Microangiopathies

Full-text PDF: <https://www.annalsoftransplantation.com/abstract/index/idArt/909781>



2630



2



—



34



Background

Thrombotic microangiopathy (TMA) is defined by small vasculature wall thickening, intraluminal platelet thrombosis, and partial or complete obstruction of the vessel lumen [1]. Clinical manifestations of TMA include microangiopathic hemolytic anemia (MAHC), thrombocytopenia, and organ injury [2]. TMA has 2 pathologically indistinguishable subtypes, thrombotic thrombocytopenic purpura (TTP) and hemolytic uremic syndrome (HUS). Hemolytic uremic syndrome (HUS), which is characterized by MAHC, thrombocytopenia, and predominantly acute renal failure, can be further classified into typical HUS and atypical HUS (aHUS) [3]. Typical HUS is marked by bloody diarrhea that is frequently secondary to an infectious etiology, commonly Shiga toxin-producing enterohemorrhagic *Escherichia coli* (STEC) or *Streptococcus pneumoniae* [3,4]. Whereas aHUS is an “ultra rare” condition with an incidence of 0.5/million/year [5]. It is called primary aHUS in 50% of patients due to inherited or acquired complement abnormality resulting in alternative pathway dysregulation or secondary aHUS when latent complement defects are triggered by drugs, pregnancy, solid organ transplantations, autoimmune disorders, and infections such as *Streptococcus pneumoniae*, human immunodeficiency virus (HIV), cytomegalovirus, Epstein-Barr virus, influenza H1N1 and hepatitis A and C [5,6]. Nonetheless, some of these secondary aHUS patients will not have complement abnormality [5]. In addition, aHUS is also caused by mutations in diacylglycerol kinase ϵ (*DGKE*) and defects in cobalamin C [5,6]. Genetic mutations in genes that encode complement regulatory proteins such as CFH, CFI, MCP, C3, CFB, or thrombomodulin (THBD), or the presence of anti-CFH antibody can result in the activation of the complement system [6,7]. In addition, aHUS manifests during childhood in 67% of patients with these genetic mutations and most patients under 16 years of age with autoantibody formation [3]. Approximately 60% to 70% of those with CFH, CFI, and C3 mutations and 30% of those with anti-CFH autoantibodies lose renal function during the initial presentation [3]. Extrarenal manifestation of aHUS involving cardiovascular, pulmonary, gastrointestinal and central nervous system have been reported in up to 20% of patients [5].

Until the recent introduction of eculizumab, aHUS carried poor prognosis with up to 50% to 80% of patients having end-stage renal disease (ESRD) or death [3,5]. Chemotherapeutic or immunosuppressive drugs implicated in the pathophysiology of aHUS include bleomycin, cisplatin, gemcitabine, mitomycin C, tacrolimus, cyclosporine, anti-vascular endothelial growth factor (VEGF) drugs, and interferon. [3,6,8]. In 0.8% to 14% of all kidney transplantation patients, the development of aHUS has been suspected to be a result of post-transplantation immunosuppressive drugs, particularly calcineurin inhibitors [7]. Due to multiple triggers for aHUS in post-renal transplantation patients, the nature of the disease varies from that of

non-transplantation patients [9]. In this study, we retrospectively analyzed the data from the United States Renal Data System (USRDS) with the goal to better understand how immunosuppressive therapy affects the incidence of aHUS in renal transplant recipients. By evaluating the association between aHUS and immunosuppressive therapy on a large scale, we hope that this study could offer evidence for the use of selective immunosuppressive agents in patients at risk for aHUS.

Material and Methods

Database, study population and methods

The USRDS is a national database, funded by the National Institute of Diabetes and Digestive and Kidney Diseases [10]. USRDS collaborates and compiles data from the United Network for Organ Sharing, ESRD networks, and Medicare and Medicaid services, representing a significant proportion of claims for ESRD patients. USRDS claims data from 2004 to 2012 were used to identify a cohort of renal transplantation patients diagnosed with aHUS. Identification of aHUS patients was done using any inpatient or outpatient claim associated with an International Classification of Diseases, Ninth Revision, Clinical Modification (ICD-9-CM) code for TMA (ICD-9-CM: 446.6) and HUS (ICD-9-CM: 283.1) along with a corresponding procedure code for the administration of eculizumab (HCPCS code: J1300) as eculizumab is used only in aHUS patients. Unfortunately, genetic testing was not documented in the database to confirm aHUS diagnosis. A history of previous kidney transplantation, transplantation after the year 2012 or transplantation before the year 2004 were exclusion criteria. The primary endpoint of our study was the determination of aHUS incidence in renal transplant recipients due to various immunosuppressive agents. The secondary endpoints were to check the relationship between drug type and HCPCS codes as well as the demographic variables that increase the risk for aHUS. With the inclusion criteria of a coded diagnosis of TMA and HUS and treatment with eculizumab, 14 of 179 140 patients fit the criteria. Originally, we planned to exclude individuals with clotting disorders, patients with immune system disorders (i.e., HIV, complement system disorders), and pre-existing HUS patients awaiting renal transplantation. However, due to the low baseline number (n=14), we decided to use only the inclusion criteria. It is of note that those conditions could play a role in the results.

Security and patient privacy

All the data used in this study was de-identified, stored on password-protected HIPAA-compliant drives, and only accessed by individuals qualified and approved to participate in the project.

Statistical analysis

Recipient and donor characteristics such as age, race, body mass index (BMI), and number of HLA mismatches were calculated, and statistically significant differences determined by the Wilcoxon rank-sum test and Fisher's exact tests as appropriate. Odds ratios and associated 95% confidence intervals were calculated for individual variables. *P* values and inferential calculations are suppressed where fewer than 5 observations are available in a categorical variable of the aHUS cohort. Prespecified predictors of interest were used for univariable logistic regression predicting occurrence of aHUS. *P* values for these comparisons were suppressed where any category had fewer than five observations of that category; confidence intervals are presented to illustrate estimates' variances. All analyses were performed using R Statistical Computing Language version 3.3.0.

Results

Demographics and patient characteristics are summarized in Table 1. Out of 179 140 subjects, 14 fit the criteria of TMA and HUS coded diagnosis with concurrent eculizumab treatment. Due to this very low sample size, *P* values were evaluated with a high level of caution due to the unpredictable statistics in such a test of small numbers. However, some potential associations to note from the study are: 1) the median recipient age was 35 years (27.00, 49.00) for the aHUS patients versus 52 years (39.00, 61.00) for other patients ($P=0.002$). 2) Out of the 14 patients with aHUS, 28.6% were male and 71.4% were female. Thus, the majority of aHUS patients were female, versus a majority of male patients in the other diagnoses group (61%). 3) Of the 14 patients with aHUS, 35.7% of patients used sirolimus in their maintenance immunosuppressive regimen versus 11.5% in the other diagnoses group ($P=0.015$). 4) All of the patients with aHUS used corticosteroids for maintenance immunosuppression, while only 69.8% of patients in other diagnoses group used corticosteroids ($P=0.030$). Other immunosuppressive agents used by most of the aHUS patients were tacrolimus ($n=12$, 85%) and mycophenolate mofetil ($n=13$, 92.9%), while 81.3% and 84.7% of patients in the other diagnoses group used these medications for maintenance immunosuppression respectively ($P=0.938$, $P=0.635$). 5) Although it was not significant, most commonly used immunosuppressive agents for induction in aHUS patients were cyclosporine (57.1% vs. 41%, $P=0.339$), sirolimus (85.7% vs. 76.4%, $P=0.611$), tacrolimus (28.6% vs. 8.7%), cyclophosphamide (78.6% vs. 62.6%) and alemtuzumab (100% vs. 92.8%). No potential associations were found regarding recipient BMI, recipient or donor race, or donor gender.

Table 2 shows odds ratios and confidence intervals for various predictors. Note that if these had wide confidence intervals

or high *P* values, then it was not reasonable to draw any conclusions. The most notable test observed from the univariate analysis was the age of the recipient, with an odds ratio of 0.9597, and 2.5% to 97.5% confidence interval of 0.9325–0.9883 ($P=0.005115$). Additionally, the "1 or 2 HLA mismatches" likely had an unreliable *P* value since the confidence interval was quite large.

Discussion

Atypical HUS (aHUS) is a disease marked by systemic TMA that has the potential to cause vital organ damage with special predilection to renal vasculature in which endothelium damage results in the development of fibrin thrombi. It has been speculated that various chemotherapeutic and immunosuppressive drugs, particularly calcineurin inhibitors, such as cyclosporin and tacrolimus, in renal transplantation patients could trigger the development of aHUS [11]. Calcineurin inhibitors have been associated with the emergence of aHUS in post-transplantation patients, theorized to be due to drug-induced endothelial injury [12]. Renal vasoconstriction is induced by cyclosporine and tacrolimus due to elevated angiotensin II, thromboxane A₂, and endothelin expression. Additionally, vasodilatory prostacyclin and nitric oxide expression is reduced, exacerbating ischemia and endothelial damage [12]. Calcineurin inhibitors can also induce a hypercoagulable state by stimulating plasminogen activator inhibitor and increased platelet aggregation. Furthermore, mTOR inhibitors contribute to post-transplantation TMA by decreasing VEGF expression and inducing endothelial progenitor cell death [13]. Some chemotherapeutic drugs, such as bleomycin and gemcitabine, may also cause endothelial damage directly and release von Willebrand factor (vWF) multimers resulting in platelet aggregation and fibrin deposition [8,14].

Recurrence has also been attributed to the use of immunosuppressive agents, especially calcineurin inhibitors and mTOR inhibitors [15]. Literature suggests these findings endorse clinical trials to assist in aHUS prevention strategies such as avoidance of certain immunosuppressive agents [9,15,16]. Other studies, however, discourage withdrawal of calcineurin inhibitors due to risks of acute rejection. Seitz et al. reported that avoidance of calcineurin inhibitors had no effect on reduction of the TMA recurrence rates; HUS recurrence in patients with CFH, MCP, or CFI mutations occurred despite receiving non-calcineurin inhibitors immunosuppression [17]. Previous studies have shown that mTOR inhibitors, such as sirolimus, have a negative impact on renal function and aHUS recurrence, likely due to VEGF inhibition [18]. In a case of post-transplantation *de novo* aHUS which was reported by Ashman et al., 60% to 100% of drug-related nephrotoxic insults was attributed to switching from calcineurin inhibitors to sirolimus [19].

Table 1. Demographics and clinical characteristics of patients.

	aHUS patients		Other diagnoses		P
n	14		179126		
Donor age in years (median [IQR])	46.00 [35.50, 54.00]		40.00 [27.00, 51.00]		0.199
Donor sex n (%)					
Unknown	N≤10	(57.1)	64983	(36.3)	
Female	N≤10	(35.7)	45190	(25.2)	
Male	N≤10	(7.1)	68953	(38.5)	
Donor race n (%)					
Native American	N≤10	(0)	887	(0.5)	
Asian	N≤10	(0)	4977	(2.8)	
Black	N≤10	(0)	24026	(13.4)	
White	14	(100)	148225	(82.7)	
Unknown	N≤10	(0)	1011	(0.6)	
Living donor n (%)	N≤10	(57.1)	64983	(36.3)	0.178
Recipient age in years (median [IQR])	35.00 [27.00, 49.00]		52.00 [39.00, 61.00]		0.002
Recipient BMI (median [IQR])	27.08 [22.40, 28.83]		27.02 [23.33, 31.28]		0.427
Recipient most recent creatinine (median [IQR])	8.50 [6.25, 11.50]		7.10 [5.10, 9.60]		0.162
Recipient race n (%)					
Native American	N≤10	(0)	1652	(0.9)	
Asian	N≤10	(0)	9783	(5.5)	
Black	N≤10	(21.4)	45117	(25.2)	
White	11	(78.6)	121227	(67.7)	
Unknown	N≤10	(0)	1347	(0.8)	
Recipient – Male n (%)	N≤10	(28.6)	109181	(61.0)	
One or two HLA mismatches n (%)	N≤10	(42.9)	35297	(19.7)	0.066
Peak PRA (median [IQR])	37.00 [12.75, 69.50]		32.00 [10.00, 77.00]		0.993
Induction immunosuppression n (%)					
Cyclosporin	N≤10	(57.1)	73455	(41.0)	0.339
Tacrolimus	N≤10	(28.6)	15568	(8.7)	
Sirolimus	12	(85.7)	136794	(76.4)	0.611
Everolimus	N≤10	(0)	3716	(2.1)	
Azathioprine	N≤10	(0)	81	(0.0)	
Mycophenolate mofetil	N≤10	(14.3)	28780	(16.1)	
Corticosteroids	N≤10	(0)	180	(0.1)	
Cyclophosphamide	11	(78.6)	112145	(62.6)	

Table 1 continued. Demographics and clinical characteristics of patients.

	aHUS patients		Other diagnoses		P
Methotrexate	N≤10	(0)	40	(0.0)	
Antilymphocyte globulin	N≤10	(0)	1632	(0.9)	
Antithymocyte globulin	N≤10	(0)	3223	(1.8)	
IL2-receptor antagonists	N≤10	(0)	4	(0.0)	
Nucleotide synthesis inhibitors	N≤10	(14.3)	8428	(4.7)	
Anti-CD3 antibody	N≤10	(0)	56	(0.0)	
Anti-IL2 antibody	N≤10	(35.7)	92431	(51.6)	0.357
Rituximab	N≤10	(0)	81	(0.0)	
Alemtuzumab	14	(100)	166265	(92.8)	
Other antibody	N≤10	(0)	3127	(1.7)	
Other IL2 antibody	N≤10	(0)	13	(0.0)	
Other	N≤10	(57.1)	40138	(22.4)	0.005
Maintenance immunosuppression (n (%))					
Cyclosporin	N≤10	(21.4)	27478	(15.3)	
Tacrolimus	12	(85.7)	145677	(81.3)	0.938
Sirolimus	N≤10	(35.7)	20593	(11.5)	0.015
Everolimus	N≤10	(0)	1501	(0.8)	
Azathioprine	N≤10	(28.6)	13079	(7.3)	
Mycophenolate mofetil	13	(92.9)	151767	(84.7)	0.635
Corticosteroids	14	(100)	125087	(69.8)	0.030
Cyclophosphamide	N≤10	(0)	204	(0.1)	
Methotrexate	N≤10	(0)	133	(0.1)	
Antilymphocyte globulin	N≤10	(0)	318	(0.2)	
Antithymocyte globulin	N≤10	(0)	5650	(3.2)	
IL-1R agents	N≤10	(0)	25	(0.0)	
Nucleotide synthesis inhibitors	N≤10	(0)	3421	(1.9)	
Anti-CD3 antibody	N≤10	(0)	2136	(1.2)	
Anti-IL2 antibody	N≤10	(0)	540	(0.3)	
Rituximab	N≤10	(7.1)	1458	(0.8)	
Alemtuzumab	N≤10	(0)	259	(0.1)	
Other antibody	N≤10	(0)	65	(0.0)	
Other IL2	N≤10	(0)	51	(0.0)	
Other	N≤10	(35.7)	7452	(4.2)	<0.001

Table 2. Odds ratios and univariate analysis.

	OR	2.5%	97.5%	P
Age	0.9597	0.9325	0.9883	0.005115
BMI	0.9434	0.8429	1.009	0.2934
Most recent creatinine	1.116	0.9768	1.253	0.08185
Recipient race				
Asian	1	2.994E-34	3.34E+33	
Black	1141286	3.161E-60	NA	
White	1557424	4.314E-60	NA	
Unknown	1	5.403E-47	1.851E+46	
Recipient Male	0.2563	0.07029	0.7661	
One or two HLA mismatches	3.056	1.006	8.788	0.03861
CMV Serostatus				
Negative	219485	2.875E-95	NA	
Not Done	1	4.408E-92	2.269E+91	
Pending	65116	2.481E-142	NA	
Unknown	1	0	Inf	
Positive	1	4.432E-80	2.256E+79	
Donor age	1.006	0.9714	1.043	0.7546
Donor Male	0.1178	0.00635	0.642	
Donor race				
Asian	1	2.666E-76	3.751E+75	
Black	1	1.265E-71	7.903E+70	
White	4406711	2.472E-141	NA	
Unknown	1	4.012E-96	2.492E+95	
Living donor	2.342	0.8145	7.114	0.1151

Additionally, a study performed by Quintrec et al. demonstrated that mTOR inhibitors were associated with a significant risk of aHUS recurrence [20]. With regards to use of corticosteroids in post-transplantation immunosuppressive regimens, it has been shown in multiple case reports that post-transplantation aHUS recurrence has been attributed to steroid resistant cellular rejection [21,22]. However, corticosteroids have been successfully utilized in regimens following the induction of immunosuppression with IL-2 receptor antagonists, such as basiliximab [23,24]. Our study findings support these earlier findings that mTOR inhibitors such as sirolimus and corticosteroids are associated with the occurrence of aHUS in renal transplant recipients. In addition, although not significant, our study revealed other drugs that are more commonly used in aHUS patients for maintenance immunosuppression were tacrolimus, azathioprine, and mycophenolate mofetil;

and cyclosporine, tacrolimus, sirolimus, cyclophosphamide, and alemtuzumab were used for induction immunosuppression. In patients with CFH, CFI, or C3 mutations, aHUS will recur in up to 50% of post-renal transplantation and 9 out of 10 patients will have graft failure [23]. This emphasizes the importance of genotyping of all aHUS patients before kidney transplantation.

The diagnosis of immunosuppression-induced aHUS can be difficult because of myelosuppression from immunosuppressive therapy itself, which can present with similar findings of anemia and thrombocytopenia. However, signs of hemolysis (schistocytes, burr cells, raised reticulocyte count, and increased LDH) and a negative Coombs test favor aHUS diagnosis [25]. Other laboratory findings include elevated serum creatinine, proteinuria, microscopic hematuria, and decreased

haptoglobin [14]. Fragmented red blood cells (schistocytes), burr cells and microspherocytes can be seen on peripheral smears [14]. Investigations to exclude TTP (ADAMTS13 activity <10% indicates TTP) and STEC associated HUS (stool culture, Shiga toxin serology/PCR) should be done immediately for all patients [5]. Evidence suggest that aHUS is highly suspect when serum creatinine >2.26 mg/dL and platelet count $\geq 30 \times 10^9/L$, and TTP is more likely if serum creatinine <2.26 mg/dL and platelet count < $30 \times 10^9/L$ [26,27]. Since aHUS is a highly fatal disease, this approach may help to identify aHUS cases early and initiate treatment while awaiting results of ADAMTS13 activity, and when Shiga-toxin is absent [26]. Also, in all suspected aHUS patients, comprehensive evaluation for complement system should be done that includes serum/plasma levels of C3, CFH, CFI, CFB, and anti-CFH antibodies [5]. Flow cytometry for MCP (CD46), and genetic testing for CFH, CFI, CFB, C3, MCP, DGKE, and THBD gene mutations should also be considered in all patients [5]. Renal biopsy shows thickened glomerular capillary walls with fibrin deposition, giving the characteristic tram-track appearance [14]. IgM and C3 deposits in the mesangium will be seen on immunofluorescence and electron microscopic shows endothelial injury [28].

Treatment of aHUS involves management of acute kidney injury and systemic complications, packed red blood cells for severe anemia, platelet transfusions if counts <10 000/cu mm, or active bleeding, fluid and electrolyte management and dialysis for uremia, fluid overload or electrolyte imbalance [29,30]. Plasma exchange and eculizumab, a complement inhibitor, offer specific forms of treatment for aHUS. While plasma exchange has been the standard of care for aHUS, it does not address the underlying cause of complement dysfunction [23]. While plasma exchange is effective for removal of antibodies from patient's blood, further evidence, however, is lacking [23]. Eculizumab is a monoclonal antibody, which prevents cleavage of C5 to C5a and C5b, thus inhibiting the formation of C5b-9 (MAC) [30]. Evidence suggest that eculizumab is also effective in patients with aHUS recurrence post-renal transplantation and transplantation-associated aHUS [31,32]. In a study involving 12 renal transplantation patients with a history of aHUS, 10 patients received eculizumab as prophylaxis for recurrence and 2 patients were given eculizumab for aHUS recurrence [31]. None of the patients had aHUS recurrence [31]. Limited information is known about the role for eculizumab in pre-transplantation desensitization for aHUS recurrence; yet, there is some evidence that it may be effective in preventing antibody mediated rejection and thus recurrence of aHUS [33]. One study showed that pretreatment with eculizumab could reduce the incidence of antibody mediated renal allograft injury within

the first 3 months, with an incidence rate of 7.2% in the eculizumab group versus 41.2% in the control group [34]. A case study conducted by Davin et al. reports success with prophylactic eculizumab in maintenance of kidney function after a third kidney transplantation for aHUS [21]. Their findings imply a strategy for prophylaxis of recurrences in patients with complement gene abnormalities.

Due to the extremely small sample size (n=14) in our study, it was impossible to do a multivariate analysis that would be worthy of statistical integrity. Additionally, the univariate analysis results and *P* values for all the tests must be approached cautiously due to the small sample size. Interestingly, it was found that there was a higher usage of sirolimus (35.7%) within the aHUS population. Although the statistical power of this study was not strong enough to determine true association, it presents an initiative for future studies to explore the relationship between immunosuppressive agents and aHUS occurrence. As our understanding of aHUS evolves in this regard, new immunosuppressive regimens can be considered to prevent incidence and recurrence of this fatal disease.

Conclusions

The molecular understanding of the way by which aHUS develops provides an avenue for exploration of therapies and strategies that will prevent the occurrence of aHUS in patients post-renal transplantation. This study highlighted the prevalence of sirolimus and corticosteroid usage in patients with aHUS who had undergone renal transplantation. Although the study was limited by a small sample size due to the rarity of the disease, the data analysis is one of the first of its kind and addresses the paucity of research dedicated to the topic. Due to the inherent nature of a retrospective analysis of a rare disease, further studies with larger sample size will be difficult but is warranted nonetheless.

Conflict of interest

None.

Disclaimer

The data reported here have been supplied by the United States Renal Data System (USRDS). The interpretation and reporting of these data are the responsibility of the author(s) and in no way should be seen as an official policy or interpretation of the U.S. government.

References:

- Ruggenenti P, Noris M, Remuzzi G: Thrombotic microangiopathy, hemolytic uremic syndrome, and thrombotic thrombocytopenic purpura. *Kidney Int*, 2001; 60(3): 831–46
- George JN, Nester CM: Syndromes of thrombotic microangiopathy. *N Engl J Med*, 2014; 371(7): 654–66
- Noris M, Remuzzi G: Atypical hemolytic-uremic syndrome. *N Engl J Med*, 2009; 361(17): 1676–87
- Karpman D, Loos S, Tati R, Arvidsson I: Haemolytic uraemic syndrome. *J Intern Med*, 2017; 281(2): 123–48
- Goodship TH, Cook HT, Fakhouri F et al: Atypical hemolytic uremic syndrome and C3 glomerulopathy: conclusions from a “Kidney Disease: Improving Global Outcomes” (KDIGO) Controversies Conference. *Kidney Int*, 2017; 91(3): 539–51
- Fakhouri F, Zuber J, Frémeaux-Bacchi V, Loirat C: Haemolytic uraemic syndrome. *Lancet*, 2017; 390(10095): 681–96
- Brodsky RA: Complement in hemolytic anemia. *Blood*, 2015; 126(22): 2459–65
- Krishnappa V, Gupta M, Shah H et al: The use of eculizumab in gemticitabine induced thrombotic microangiopathy. *BMC Nephrol*, 2018; 19(1): 9
- Alasfar S, Alachkar N: Atypical hemolytic uremic syndrome post-kidney transplantation: two case reports and review of the literature. *Front Med (Lausanne)*, 2014; 1: 52
- USRDS Database. 2016; Available from: <https://www.usrds.org/>
- Nava F, Cappelli G, Mori G et al: Everolimus, cyclosporine, and thrombotic microangiopathy: Clinical role and preventive tools in renal transplantation. *Transplant Proc*, 2014; 46(7): 2263–66.
- Said T, Al-Otaibi T, Al-Wahaib S et al: Posttransplantation calcineurin inhibitor-induced hemolytic uremic syndrome: single-center experience. *Transplant Proc*, 2010; 42(3): 814–16
- Ponticelli C: *De novo* thrombotic microangiopathy. An underrated complication of renal transplantation. *Clin Nephrol*, 2007; 67(6): 335–40
- van der Heijden M, Ackland SP, Deveridge S: Haemolytic uraemic syndrome associated with bleomycin, epirubicin and cisplatin chemotherapy – a case report and review of the literature. *Acta Oncol*, 1998; 37(1): 107–9
- Greenbaum LA: Atypical hemolytic uremic syndrome. *Adv Pediatr*, 2014; 61(1): 335–56
- Zuber J, Le Quintrec M, Morris H et al: Targeted strategies in the prevention and management of atypical HUS recurrence after kidney transplantation. *Transplant Rev (Orlando)*, 2013; 27(4): 117–25
- Seitz B, Albano L, Vocila F et al: Recurrence of hemolytic uremic syndrome after renal transplantation. *Transplant Proc*, 2007; 39(8): 2583–85
- Salvadori M, Bertoni E: Update on hemolytic uremic syndrome: Diagnostic and therapeutic recommendations. *World J Nephrol*, 2013; 2(3): 56–76
- Ashman N, Chapagain A, Dobbie H et al: Belatacept as maintenance immunosuppression for postrenal transplant *de novo* drug-induced thrombotic microangiopathy. *Am J Transplant*, 2009; 9(2): 424–27
- Le Quintrec M, Zuber J, Moulin B et al: Complement genes strongly predict recurrence and graft outcome in adult renal transplant recipients with atypical hemolytic and uremic syndrome. *Am J Transplant*, 2013; 13(3): 663–75
- Davin JC, Gracchi V, Bouts A et al: Maintenance of kidney function following treatment with eculizumab and discontinuation of plasma exchange after a third kidney transplant for atypical hemolytic uremic syndrome associated with a CFH mutation. *Am J Kidney Dis*, 2010; 55(4): 708–11
- Cruzado JM, de Córdoba SR, Melilli E et al: Successful renal transplantation in a patient with atypical hemolytic uremic syndrome carrying mutations in both factor I and MCP. *Am J Transplant*, 2009; 9(6): 1477–83
- Waters AM, Licht C: aHUS caused by complement dysregulation: New therapies on the horizon. *Pediatr Nephrol*, 2011; 26(1): 41–57
- Zaza G, Tomei P, Granata S et al: Monoclonal antibody therapy and renal transplantation: focus on adverse effects. *Toxins (Basel)*, 2014; 6(3): 869–91
- Fung MC, Storniolo AM, Nguyen B et al: A review of hemolytic uremic syndrome in patients treated with gemticitabine therapy. *Cancer*, 1999; 85(9): 2023–32
- Asif A, Vachharajani T, Salman L, Nayer A: A simplified approach to the diagnosis of atypical HUS: Clinical considerations and practical implications. *Open Urology & Nephrology Journal*, 2014; 7: 91–94
- Coppo P, Schwarzingner M, Buffet M et al: Predictive features of severe acquired ADAMTS13 deficiency in idiopathic thrombotic microangiopathies: The French TMA reference center experience. *PLoS One*, 2010; 5(4): e10208
- Flombaum CD, Mouradian JA, Casper ES et al: Thrombotic microangiopathy as a complication of long-term therapy with gemticitabine. *Am J Kidney Dis*, 1999; 33(3): 555–62
- Schmidtke J, Peine S, El-Housseini Y et al: Treatment of atypical hemolytic uremic syndrome and thrombotic microangiopathies: A focus on eculizumab. *Am J Kidney Dis*, 2013; 61(2): 289–99
- Loirat C, Frémeaux-Bacchi V: Atypical hemolytic uremic syndrome. *Orphanet J Rare Dis*, 2011; 6: 60
- Levi C, Frémeaux-Bacchi V, Zuber J et al: Midterm outcomes of 12 renal transplant recipients treated with eculizumab to prevent atypical hemolytic syndrome recurrence. *Transplantation*, 2017; 101(12): 2924–30
- Fakhouri F, Hourmant M, Campistol JM et al: Terminal complement inhibitor eculizumab in adult patients with atypical hemolytic uremic syndrome: A single-arm, open-label trial. *Am J Kidney Dis*, 2016; 68(1): 84–93
- Wongsaraj P, Kahwaji J, Vo A, Jordan SC: Modern approaches to incompatible kidney transplantation. *World J Nephrol*, 2015; 4(3): 354–62
- Stegall MD, Diwan T, Raghavaiah S et al: Terminal complement inhibition decreases antibody-mediated rejection in sensitized renal transplant recipients. *Am J Transplant*, 2011; 11(11): 2405–13