

CONSENSUS STATEMENT

International consensus on natural orifice specimen extraction surgery (NOSES) for gastric cancer (2019)

Xu Guan^{1,†}, Zheng Liu^{1,†}, Amjad Parvaiz², Antonio Longo³, Avanish Saklani⁴, Ali A. Shafik⁵, Jian-Chun Cai⁶, Charles Terner⁷, Lin Chen⁸, Cuneyt Kayaalp⁹, Fatih Sumer⁹, Fernanda Nogueira¹⁰, Feng Gao¹¹, Fang-Hai Han¹², Qing-Si He¹³, Ho-Kyung Chun¹⁴, Chang-Ming Huang¹⁵, Hai-Yang Huang¹, Rui Huang¹¹, Zhi-Wei Jiang¹⁶, Jim S Khan¹⁷, Joaquim Manuel da Costa Pereira¹⁰, Joseph W Nunoo-Mensah¹⁸, Jung Tack Son¹⁴, Liang Kang¹⁹, Keisuke Uehara²⁰, Ping Lan¹⁹, Le-Ping Li²¹, Han Liang²², Bing-Rong Liu²³, Juan Liu²⁴, Dan Ma²⁵, Ming-Yin Shen²⁶, Mohammad Rashidul Islam²⁷, Narimantas Evaldas Samalavicius²⁸, Kai Pan²⁹, Petr Tsarkov³⁰, Xin-Yu Qin³¹, Ricardo Escalante³², Sergey Efetov³³, Seung Kyu Jeong³⁴, Suk-Hwan Lee³⁵, Dong-Hui Sun³⁶, Li Sun³⁷, Tatiana Garmanova³⁰, Yan-Tao Tian³⁸, Gui-Yu Wang¹¹, Guo-Jun Wang³⁹, Guo-Rong Wang⁴⁰, Xiao-Qiang Wang⁴⁰, William Tzu-Liang Chen²⁶, Woo Yong Lee⁴¹, Su Yan⁴², Zu-Li Yang⁴³, Gang Yu⁴⁴, Pei-Wu Yu⁴⁵, Dan Zhao³⁷, Yun-Shi Zhong⁴⁶, Jian-Ping Wang^{19,*}, Xi-Shan Wang^{1,*} and The International Alliance of NOSES

¹Department of Colorectal Surgery, National Cancer Center/National Clinical Research Center for Cancer/Cancer Hospital, Chinese Academy of Medical Sciences and Peking Union Medical College, Beijing, P. R. China;

²Poole Hospital NHS Trust, Poole, UK; ³European Center of Coloproctology and Pelvic Diseases-Multimedia Hospital, Milan, Italy; ⁴Department of GI Surgical Oncology, Tata Memorial Hospital, Mumbai, India;

⁵Department of Colorectal Surgery, Cairo University, Cairo, Egypt; ⁶Department of Gastrointestinal Surgery, Zhongshan Hospital of Xiamen University, Xiamen, Fujian, P. R. China; ⁷Section of Colon and Rectal Surgery, Creighton University School of Medicine, Omaha, NE, USA; ⁸Department of General Surgery, Chinese People's Liberation Army General Hospital, Beijing, P. R. China; ⁹Department of Gastrointestinal Surgery, Inonu University, Malatya, Turkey; ¹⁰Department of Surgery, Hospital de Braga, Braga, Portugal; ¹¹Department of Colorectal Cancer Surgery, the Second Affiliated Hospital of Harbin Medical University, Harbin, Heilongjiang, P. R. China; ¹²Department of Gastroenterological Surgery, Sun Yat-sen Memorial Hospital, Sun Yat-sen University, Guangzhou, Guangdong, P. R. China; ¹³Department of General Surgery, Shandong University Qilu

Submitted: 3 November 2019; Revised: 16 November 2019; Accepted: 21 November 2019

© The Author(s) 2020. Published by Oxford University Press and Sixth Affiliated Hospital of Sun Yat-sen University

This is an Open Access article distributed under the terms of the Creative Commons Attribution Non-Commercial License (<http://creativecommons.org/licenses/by-nc/4.0/>), which permits non-commercial re-use, distribution, and reproduction in any medium, provided the original work is properly cited. For commercial re-use, please contact journals.permissions@oup.com

Hospital, Jinan, Shandong, P. R. China; ¹⁴Department of Surgery, Kangbuk Samsung Hospital, Sungkyunkwan University School of Medicine, Seoul, South Korea; ¹⁵Department of Gastric Surgery, Fujian Medical University Union Hospital, Fuzhou, Fujian, P. R. China; ¹⁶Department of General Surgery, Jiangsu Province Hospital of Traditional Chinese Medicine, Nanjing, Jiangsu, P. R. China; ¹⁷Department of Colorectal Surgery, Portsmouth, Hospitals NHS, Trust, Queen Alexandra Hospital, Portsmouth, UK; ¹⁸King's College Hospital, London, UK; ¹⁹Department of Colorectal Surgery, The Sixth Affiliated Hospital of Sun Yat-sen University, Guangzhou, Guangdong, P. R. China; ²⁰Division of Surgical Oncology, Department of Surgery, Nagoya University School of Medicine, Nagoya, Japan; ²¹Department of Gastrointestinal Surgery, Shandong Provincial Hospital Affiliated to Shandong University, Jinan, Shandong, P. R. China; ²²Department of Gastric Cancer, Tianjin Medical University Cancer Institute & Hospital, Tianjin, P. R. China; ²³Department of Gastroenterology, The First Affiliated Hospital of Zhengzhou University, Zhengzhou, Henan, P. R. China; ²⁴Department of Obstetrics and Gynecology, Third Affiliated Hospital of Guangzhou Medical University, Guangzhou, Guangdong, P. R. China; ²⁵Department of General Surgery, Xinqiao, Hospital, Third Military Medical University, Chongqing, P. R. China; ²⁶Department of Surgery, China Medical University Hospital, Taichung, Taiwan, China; ²⁷Department of Surgery, Shaheed Suhrawardy Medical College, Dhaka, Bangladesh; ²⁸Department of Surgery, Klaipeda University Hospital, Klaipeda, Lithuania; ²⁹Department of Gastrointestinal Surgery, Shenzhen People's Hospital & Second Clinical Medical College of Jinan University, Shenzhen, Guangdong, P. R. China; ³⁰Clinic of Colorectal and Minimally Invasive Surgery, Sechenov First Moscow State Medical University, Moscow, Russia; ³¹Department of General Surgery, Zhongshan, Hospital, Fudan University, Shanghai, P. R. China; ³²Universidad Central de Venezuela, Centro, Medico Loira, Caracas, Venezuela; ³³Colorectal Surgery Department, Sechenov First Moscow State Medical University, Moscow, Russia; ³⁴Department of Surgery, Yang Hospital, Seoul, South Korea; ³⁵Department of Surgery, Kyung Hee University Hospital at Gangdong, Kyung Hee University School of Medicine, Seoul, South Korea; ³⁶Department of Gastric and Colorectal Surgery, Jilin University First Hospital, Changchun, Jilin, P. R. China; ³⁷Department of Gynecologic Oncology, National Cancer Center/National Clinical Research Center for Cancer/Cancer Hospital, Chinese Academy of Medical Sciences and Peking Union Medical College, Beijing, P. R. China; ³⁸Department of Pancreatic and Gastric Surgery, National Cancer Center/National Clinical Research Center for Cancer/Cancer Hospital, Chinese Academy of Medical Sciences and Peking Union Medical College, Beijing, P. R. China; ³⁹Department of Gastrointestinal Surgery, The First Affiliated Hospital of Zhengzhou University, Zhengzhou, Henan, P. R. China; ⁴⁰Department of General Surgery, Shanxi, Provincial, People's, Hospital, The, Third Affiliated, Hospital, Medical College, Xi'an Jiao Tong University, Xi'an, Shaanxi, P. R. China; ⁴¹Department of surgery, Samsung Medical Center, Sungkyunkwan University, Seoul, South Korea; ⁴²Department of Gastrointestinal Surgery, Qinghai University Affiliated Hospital, Xining, Qinghai, P. R. China; ⁴³Department of Gastrointestinal Surgery, The Sixth Affiliated Hospital of Sun Yat-sen University, Guangzhou, Guangdong, P. R. China; ⁴⁴Department of General Surgery, Qilu Hospital of Shandong University (Qingdao), Qingdao, Shandong, P. R. China; ⁴⁵Department of General Surgery, Center of Minimal Invasive Gastrointestinal Surgery, Southwest, Hospital, Army Medical University (Third Military Medical University), Chongqing, P. R. China; ⁴⁶Endoscopy Center and Endoscopy Research Institute, Zhongshan, Hospital, Fudan University, Shanghai, P. R. China

*Corresponding authors. Department of Colorectal Surgery, National Cancer Center/National Clinical Research Center for Cancer/Cancer Hospital, Chinese Academy of Medical Sciences and Peking Union Medical College, Beijing 100021, P. R. China. Tel: +86-13552367779; Email: wxshan1208@126.com; Department of Colorectal Surgery, The Sixth Affiliated Hospital of Sun Yat-sen University, Guangzhou, Guangdong 510655, P. R. China. Tel: +86-13808874808; Email: wangjgz@126.com

[†]These authors contributed equally to this work.

Abstract

At present, natural orifice specimen extraction surgery (NOSES) has attracted more and more attention worldwide, because of its great advantages including minimal cutaneous trauma and post-operative pain, fast post-operative recovery, short hospital stay, and positive psychological impact. However, NOSES for the treatment of gastric cancer (GC) is still in its infancy, and there is great potential to improve its theoretical system and clinical practice. Especially, several key points including oncological outcomes, bacteriological concerns, indication selection, and standardized surgical procedures are raised with this innovative technique. Therefore, it is necessary to achieve an international consensus to regulate the implementation of GC-NOSES, which is of great significance for healthy and orderly development of NOSES worldwide.

Key words: gastric cancer; natural orifice specimen extraction surgery; transanal specimen extraction; transvaginal specimen extraction; transoral specimen extraction; consensus

Introduction

Natural orifice specimen extraction surgery (NOSES) has attracted more and more attention because of its great minimally invasive effect. Furthermore, the safety and efficacy of NOSES have also been gradually recognized, especially in the field of gastrointestinal surgery [1–4]. In recent years, laparoscopic and robotic gastric cancer (GC) resection with NOSES has obviously shown an upward trend, but many theoretical and technical issues have failed to reach unification [5–8]. Faced with this situation, the International Alliance of NOSES organized dozens of experts from gastrointestinal surgery, gynecology, endoscopy, and colorectal surgery to draft and formulate this international consensus. This consensus comprehensively elaborates the key issues of GC-NOSES and further provides a significant industry guideline for its clinical practice.

Definition and classification

Definition

The definition of NOSES is as follows. The surgical specimen resection is performed intra-abdominally and the specimen is extracted by opening a hollow organ that communicates with the outside of the body, including the anus, vagina, or mouth. The main features of GC-NOSES involve specimen extraction from a natural orifice and complete intra-abdominal digestive-tract reconstruction, which avoids the additional incision on the abdominal wall [9]. Currently, NOSES can be applied in the fields of gastrointestinal surgery, hepatobiliary surgery, urinary surgery, and gynecologic surgery [10].

Classification

According to different specimen extraction routes, GC-NOSES is divided into three categories including transoral specimen extraction, transanal specimen extraction and transvaginal specimen extraction (Figure 1) [11].

Naming of GC-NOSES

In order to make GC-NOSES more standardized and unified, this consensus systematically proposes nine specific surgical procedures for GC-NOSES, which are mainly based on tumor location and the way of specimen extraction [11]. The specific abbreviations and full names of GC-NOSES are shown in Table 1.

Indications and contraindications

Indications

Compared with conventional laparoscopic surgery, the indications of GC-NOSES are stricter. First, the indications of GC-NOSES should meet the requirements of conventional laparoscopic gastrectomy. Second, surgeons should be capable of performing total laparoscopic digestive reconstruction of the gastrectomy and have a wealth of experience to strictly comply with the basic requirements of aseptic and tumor-free principles [11]. Otherwise, GC-NOSES is not recommended. Meanwhile, GC-NOSES has its specific indications. According to different ways of specimen extraction, the indications are distinguishing. The details are shown in Table 2.

Relative contraindications

Relative contraindications include locally advanced GC, acute bowel obstruction, bleeding and perforation derived from cancer, obese patients (BMI ≥ 30 kg/m²), patients with a history of pelvic surgery, anal stenosis, vaginal malformation, etc. In addition, females who have not completed their family should not be recommended for transvaginal specimen extraction [11].

Surgical devices for GC-NOSES

The basic surgical platform required by GC-NOSES is a conventional 2D laparoscopic platform [6]. Therefore, for surgeons with experience of laparoscopic surgery, the learning curve of GC-NOSES will be obviously reduced. In addition to the 2D laparoscopic platform, GC-NOSES can be performed by using

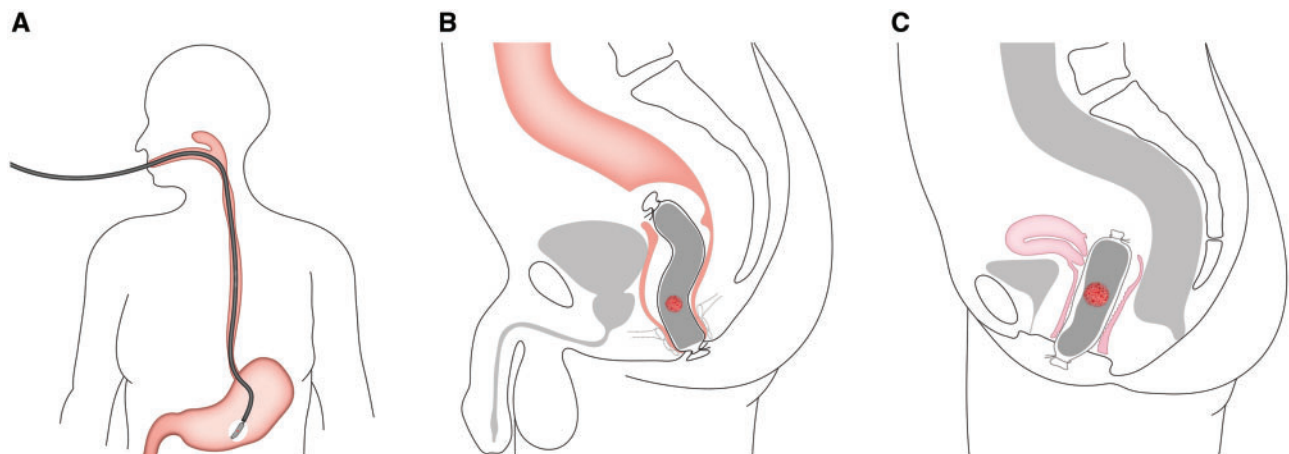


Figure 1. Specimen-extraction routes for gastric cancer. (A) Transoral specimen extraction; (B) transanal specimen extraction; (C) transvaginal specimen extraction.

Table 1. The abbreviations and full names of natural orifice specimen extraction surgery for gastric cancer (GC-NOSES)

Abbreviation	Full name	Orifice
GC-NOSES I	Laparoscopic distal gastrectomy (Billroth I) with transrectal specimen extraction	Rectum
GC-NOSES II	Laparoscopic distal gastrectomy (Billroth I) with transvaginal specimen extraction	Vagina
GC-NOSES III	Laparoscopic distal gastrectomy (Billroth II) with transrectal specimen extraction	Rectum
GC-NOSES IV	Laparoscopic distal gastrectomy (Billroth II) with transvaginal specimen extraction	Vagina
GC-NOSES V	Laparoscopic proximal gastrectomy with transrectal specimen extraction	Rectum
GC-NOSES VI	Laparoscopic proximal gastrectomy with transvaginal specimen extraction	Vagina
GC-NOSES VII	Laparoscopic total gastrectomy with transrectal specimen extraction	Rectum
GC-NOSES VIII	Laparoscopic total gastrectomy with transvaginal specimen extraction	Vagina
GC-NOSES IX	Laparoscopic partial gastrectomy with transoral specimen extraction	Mouth

Table 2. Indications for gastric cancer natural orifice specimen extraction surgery (GC-NOSES)

Specimen extraction route	Indications
Transoral specimen extraction	(i) Benign or T1 tumor cannot be completely resected under endoscopy; (ii) the maximum diameter of the specimen should be <2 cm; and (iii) T2/T3 tumor [11]
Transrectal specimen extraction	(i) Benign or malignant tumor cannot be extracted through the mouth (male patient); (ii) T2/T3 tumor; (iii) the maximum diameter of the specimen should be <3 cm; and (iv) BMI <30 kg/m ² [11]
Transvaginal specimen extraction	(i) Benign or malignant tumor cannot be extracted through the mouth (female patient); (ii) T2/T3 tumor; (iii) the maximum diameter of the specimen should be from 3 to 5 cm; and (iv) BMI <30 kg/m ² [11]

BMI, body mass index.

other minimally invasive devices, such as high-definition 3D laparoscopy and the da VinciVR robotic platform [9]. The high-definition 3D laparoscope makes the operation field clearer, which helps the surgeon to perform complex surgical operations much more easily. The da VinciVR robot manipulator provides a more stable operation environment, avoiding the subtle jitters of human hands during a delicate and fine surgical dissection [12].

Furthermore, a protective tool is recommended during specimen extraction to avoid direct contact between the specimen

and the natural orifice in order to ensure that the operation is aseptic and tumor-free. In current clinical practice, specimen extraction tools are mainly divided into soft and hard devices. The former includes double-ringed wound-protective devices, self-made plastic sleeves, and sterile specimen bags, whereas the latter include anoscope and transluminal endoscopic operation ports [9].

Gastrectomy and digestive-tract reconstruction

The gastrectomy and gastrointestinal reconstruction of GC-NOSES should follow the basic principles of open surgery and conventional laparoscopic surgery [13]. First, the resection range of gastrectomy cannot be intentionally reduced because of specimen extraction through a narrow orifice. Second, based on different tumor locations, the methods of gastrectomy and reconstruction should be carefully selected to preserve gastrointestinal function. Finally, the anastomosis should be provided with sufficient blood supply, no tension, and no stenosis.

Aseptic operation and tumor-free operation

Bacteriological concerns have been raised because of the breach in peritoneal sterility in some procedures of GC-NOSES [5]. Previous studies have fully confirmed the potential of bacterial contamination during NOSES by examining the bacterial-positive rate of intraoperative pelvic-fluid culture. In order to solve this problem, this consensus recommends that prophylactic-antibiotics administration, mechanical bowel preparation, intraoperative peritoneal irrigation, and placement of pelvic or abdominal drains should be applied to reduce the bacterial load of NOSES.

The oncological safety is another major concern in procedures of GC-NOSES. Tumor dissemination mainly arises from compression between the specimen and the narrow natural orifice, with the potential for compromise in oncological safety [14]. In clinical practice, lots of clinical-experience techniques have been summarized to prevent tumor dissemination, including the use of sterile protection devices when taking the specimen, avoiding over-pulling, and compression of lesions during specimen extraction. Previous findings have shown that transluminal specimen extraction provides the same degree of protection as transabdominal specimen extraction by comparison using the peritoneal tumor cytology test [15].

Requirements of surgical procedures for specimen extraction

The principles of specimen extraction

Specimen extraction is the most characteristic surgical procedure in NOSES. The requirements for technical skills of NOSES are obviously higher for specimen extraction than for open surgery and conventional laparoscopic surgery. The main principles of specimen extraction recommended in this consensus include: (i) strict adherence to the indications of GC-NOSES; (ii) full compliance with the aseptic and tumor-free principles during the specimen extraction; (iii) comprehensive preoperative assessments for the anatomy and physiology of the natural orifice; and (iv) prompt conversion to transabdominal specimen extraction if the specimen is difficult to extract from the natural orifice [11].

Requirements for transoral specimen extraction procedures

The transoral route is considered to be the most ideal way for specimen extraction for GC. However, due to the narrow lumen and poor elasticity of the esophageal tract, the transoral route is only appropriate for highly selected patients with small tumors [16].

Preoperative preparation

An endoscope should be preoperatively used to exam whether there are varices or stenosis in the esophageal wall. Transoral specimen extraction should be forbidden if varices or abnormal stenoses are detected in the esophagus.

Operative essentials

It is essential that aseptic and tumor-free principles should be strictly followed during the specimen extraction. Here, this consensus recommends that the gastric specimen should be completely sealed within a retrieval bag intraperitoneally before transoral extraction, so as to avoid direct exposure of the tumor to the natural orifice. Furthermore, the whole process of specimen extraction should be guided under close observation using the endoscope.

Complication prevention and therapy

The most common complications of transoral specimen extraction are rupture and bleeding of the esophageal wall. The esophagus is characterized by a narrow lumen and poor elasticity, which increase the difficulty of the specimen extraction as well as the risk of esophageal-wall injury. In order to avoid the injury during specimen extraction, this consensus recommends that full assessments should be carried out preoperatively. If esophageal rupture or bleeding occurs during the specimen extraction, timely endoscopic therapy is needed.

Requirements for transvaginal specimen extraction procedures

The transvaginal route is only performed in female patients with larger specimens that cannot be extracted through the transoral route. This route is currently the most common way in GC-NOSES [12].

Preoperative preparation

Before transvaginal specimen extraction, the accessibility and elasticity of vagina should be carefully assessed. It is essential to make clear whether there is pelvic inflammation or adhesions around the posterior fornix for patients who have a history of pelvic surgery.

Operative essentials

Transvaginal specimen extraction consists of the following four steps. (i) *Intracorporeal specimen transfer*: the gastric specimen is located at the upper abdomen after resection and it needs to be transferred to the pelvic cavity, from which the specimen will be extracted out of the body. Before specimen transfer, the specimen should be completely sealed within a retrieval bag in order to avoid intraperitoneal tumor dissemination. (ii) *Opening the posterior fornix*: the posterior fornix can be clearly exposed under laparoscopy. Because of its good elasticity and healing ability, the posterior fornix is considered the preferred site for vaginal incision [17]. Opening the vaginal incision can be performed either intracorporeally or extracorporeally. The length

of the vaginal incision is recommended to be 3–5 cm; vaginal incision should be made transversely from the middle to both sides. (iii) *Transvaginal specimen extraction*: after opening the posterior fornix, the specimen is transvaginally extracted from the pelvic cavity and is gently extracted extracorporeally. The transvaginal specimen extraction should be performed under close observation using a laparoscope. (iv) *Closing the posterior fornix*: the vaginal incision can be closed either intracorporeally or extracorporeally with absorbable sutures. A knotless suture is often sewn from one side of the incision to the other side using a continuous stitch. Alternatively, the vaginal incision can be stitched extracorporeally using an interrupted full-thickness suturing technique. After closure, it is necessary to perform a digital examination to check that the vaginal incision is intact.

Complication prevention and therapy

Making an incision in the posterior fornix may increase the risks of chronic dyspareunia and affect sexual function and quality of life, although this may not occur very frequently. Therefore, this consensus recommends careful evaluation for these patients with appropriate quality of life and validated sexual function during follow-up. In addition, transvaginal specimen extraction may increase the risks of secondary pelvic infection and incisional tumor dissemination. Hence, it is necessary to fully comply with aseptic and tumor-free principles during the extraction.

Requirements for transrectal specimen extraction procedures

Although transrectal specimen extraction has not yet been widely accepted in GC-NOSES, this measure is only recommended for male patients who can fully accept the risk of this procedure.

Preoperative preparation

Before transrectal specimen extraction, it is necessary to check the anatomical structure of the rectum so as to evaluate the feasibility of this operation.

Operative essentials

The transrectal specimen extraction consists of the following four steps. (i) *Intracorporeal specimen transfer*: the specimen should be sealed within a retrieval bag in order to avoid intraperitoneal tumor dissemination during the specimen transfer; the specimen is transferred from the upper abdominal cavity to the pelvic cavity. (ii) *Proctotomy*: the location of the rectal incision is recommended to be 5–10 cm above the peritoneal reflection, which may facilitate specimen extraction and incision closure. A 3- to 5-cm longitudinal incision is recommended to be made in the anterior wall of the rectal wall. Here, use of hook monopolar cautery is advised for the rectal incision to minimize injury. (iii) *Transrectal specimen extraction*: after the specimen is transferred to the pelvic cavity, the specimen is extracted through the rectal incision and is gently withdrawn extracorporeally. Violent withdrawal will cause the specimen to get stuck outside the rectal incision. The whole operation should be performed under laparoscopic guidance. (iv) *Closure of the rectal incision*: the rectum should be closed longitudinally and a knotless suture should be made from the distal end to the proximal end with a continuous full-thickness suture, followed by inversion of the suture line with seromuscular stitches. After stitching, an air test is required to detect

whether the sutured incision is intact. The endoscopic examination may be conducted, if necessary.

Complication prevention and therapy

The main complications of the transrectal specimen extraction are anal-sphincter injury and proctotomy leak. In recent years, there has been a gradual increase in reports of transrectal NOSES, but anal dysfunction or sphincter injury is rarely reported. This consensus suggests that the anus should be fully expanded before specimen extraction to reduce the risk of sphincter injury. Proctotomy leak is another serious complication. Once proctotomy leak is detected, adequate drainage should be performed as early as possible. As for patients with delayed healing or non-healing, a diverting colostomy or ileostomy should be considered. Alternatively, a re-resection followed by anastomosis would still be an option.

Clinical research and technical training

At present, the research related to GC-NOSES is mostly single-centered, small-sampled, and retrospective, with a poor-quality and low evidence level [12–16, 18]. Therefore, large-sampled, multicentered, randomized clinical trials comparing NOSES vs transabdominal specimen extraction for GC are very necessary, which will address the risks and benefits in GC-NOSES, especially abdominal infection, anastomotic leak, and natural orifice injury and dysfunction, etc. In addition, in consideration of the potential advantages of NOSES, it is recommended that assessment and research be carried out on the quality of life and social-psychological and health-economic effects among patients undergoing GC-NOSES. More importantly, in order to ensure the healthy and orderly development of GC-NOSES, standardized procedures should be established in clinical practice. It is, therefore, essential that NOSES-oriented academic organizations should be established, and academic activities and surgeon training for GC-NOSES should be done to further standardize the clinical practice of GC-NOSES in the future.

Conflicts of interest

None declared.

References

1. Wolthuis AM, de B, van OA, D'Hoore A. Laparoscopic natural orifice specimen extraction-colectomy: a systematic review. *World J Gastroenterol* 2014;20:12981–92.
2. Guan X, Wang GY, Zhou ZQ et al. Retrospective study of 718 colorectal neoplasms treated by natural orifice specimen extraction surgery in 79 hospitals. *Chin J Colorec Dis (Electronic Edition)* 2017;6:469–77.
3. Park JS, Choi GS, Kim HJ et al. Natural orifice specimen extraction versus, conventional laparoscopically assisted right hemicolectomy. *Br J Surg* 2011;98:710–5.
4. China Natural Orifice Specimen Extraction Surgery Alliance. Expert consensus of natural orifice specimen extraction surgery in colorectal neoplasm (2017 edition). *Chin J Colorec Dis (Electronic Edition)* 2017;6:266–72.
5. Sumer F, Kayaalp C, Karagul S. Laparoscopic gastrectomy and transvaginal specimen extraction in a morbidly obese patient with gastric cancer. *J Gastric Cancer* 2016;16:51–3.
6. Sumer F, Karakas S, Gundogan E et al. Totally laparoscopic resection and extraction of specimens via transanal route in synchronous colon and gastric cancer. *G Chir* 2018;39:82–6.
7. Stanek M, Major P, Wierdak M et al. Laparoscopic gastric resections with per oral specimen extraction in treatment of intramural gastric tumors. *Pol Przegl Chir* 2017;89:16–21.
8. Hüscher CG, Lirici MM, Ponzano C. NOSE laparoscopic gastrectomies for early gastric cancer may reduce morbidity and hospital stay: early results from a prospective nonrandomized study. *Minim Invasive Ther Allied Technol* 2017;26:71–7.
9. Guan X, Liu Z, Longo A et al. International consensus on natural orifice specimen extraction surgery (NOSES) for colorectal cancer. *Gastroenterol Rep (Oxf)* 2019;7:24–31.
10. Wang XS. *Natural Orifice Specimen Extraction Surgery—Abdominal Pelvic Tumor*. PMPH: Beijing, 2019.
11. China Natural Orifice Specimen Extraction Surgery Alliance. Consensus of Natural Orifice Specimen Extraction Surgery in Gastric Cancer (2019). *Zhonghua Wei Chang Wai Ke Za Zhi* 2019;22:711–4 [in Chinese].
12. Zhang S, Jiang ZW, Wang G et al. Robotic gastrectomy with transvaginal specimen extraction for female gastric cancer patients. *World J Gastroenterol* 2015;21:13332–8.
13. Jeong SH, Lee YJ, Choi WJ et al. Trans-vaginal specimen extraction following totally laparoscopic subtotal gastrectomy in early gastric cancer. *Gastric Cancer* 2011;14:91–6.
14. Sumer F, Kayaalp C, Ertugrul I et al. Total laparoscopic subtotal gastrectomy with transvaginal specimen extraction is feasible in advanced gastric cancer. *Int J Surg Case Rep* 2015;16:56–8.
15. Leroy J, Costantino F, Cahill RA et al. Laparoscopic resection with transanal specimen extraction for sigmoid diverticulitis. *Br J Surg* 2011;98:1327–34.
16. Huscher CG, Mingoli A, Sgarzini G et al. Transoral extraction of a laparoscopically resected large gastric GIST. *J Laparoendosc Adv Surg Tech A* 2013;23:707–9.
17. Franklin ME, Jr, Liang S, Russek K. Natural orifice specimen extraction in laparoscopic colorectal surgery: transanal and transvaginal approaches. *Tech Coloproctol* 2013;17:63–7.
18. Lirici MM, Romeo V, Simonelli L et al. Minimizing the access trauma of laparoscopic sleeve gastrectomy: the transoral specimen extraction technique. *Obes Surg* 2016;26:229–33.