

# Extracranial-intracranial bypass of the bilateral anterior cerebral circulation using a thoracodorsal axis artery-graft

Abhilash Jain, Kevin O'Neill<sup>1</sup>, Maneesh C. Patel<sup>2</sup>, Niall Kirkpatrick, Niroshan Sivathasan, Jagdeep Nanchahal<sup>1</sup>

Department of Plastic and Reconstructive Surgery and the Kennedy Institute of Rheumatology, <sup>1</sup>Kennedy Institute of Neurosurgery, <sup>2</sup>Kennedy Institute of Neuroradiology, Charing Cross Hospital Campus of Imperial College London, Fulham Palace Road, London, W6 8RF, U.K.

## ABSTRACT

Bilateral extracranial-intracranial (EC-IC) bypass-grafting of the cerebral circulation is uncommon. We report a case of anterior cerebral artery EC-IC bypass using the thoracodorsal axis artery-graft. The bifurcation of the thoracodorsal axis allows bypass of both anterior hemispheres, while matching appropriate small-vessel dimensions.

**Key words:** Artery-graft, bilateral EC-IC bypass, thoracodorsal graft, unclippable intracranial aneurysm

## Introduction

Intracranial aneurysms can present in many ways, including cerebral infarction and its consequential neurological deficits, epilepsy, and symptoms of the mass-effect, such as diplopia and abnormal extraocular movements. Aneurysmal rupture is uncommon in younger patients, probably because the vessels are less diseased with atheromatous-change, and have reduced disruption of the internal elastic lamina and thus lower intimal hyperplasia. Current treatment techniques include either/ or a combination of, endovascular- and surgical- approaches.

## Case Report

A 19-year-old man was referred to the regional neurosurgical center, having suffered two subarachnoid hemorrhages in the previous two months. A cerebral angiogram demonstrated a large aneurysm affecting the anterior communicating artery and the proximal ends of both the right and left anterior cerebral arteries [Figure 1]. Due to the aneurysm's size and

position, trapping it was unlikely to preserve the anterior circulation. Furthermore, perforating vessels involved in the trapped segment would likely be sacrificed, although from angiography this was estimated to be relatively unlikely. Bilateral bypass-grafting was, therefore, considered.

His past medical history included treatment for B-cell non-Hodgkin's lymphoma, with subsequent marked bronchiectasis.

Prior to surgery, he was drowsy with a headache, and had Glasgow coma scale (GCS) score of 15; purposeful movements of all limbs to command, spontaneous eye-opening, and conversing normally. At surgery, bicoronal incisions allowed elevation of a pericranial flap and exposure of the left temporalis muscle. A large craniotomy was performed with the bone-flap pedicled on the left temporalis muscle [Figure 2]. The dura was incised preserving the sagittal sinus, allowing bilateral dural flaps to be opened like the pages of a book. Segments of both the left and right anterior cerebral arteries were prepared for the end-to-side anastomoses. The vessels at this level had an external diameter of approximately 1 mm.

A thoracodorsal axis artery-graft was harvested with an extensive intramuscular dissection, allowing both the latissimus dorsi and serratus anterior branches of the appropriate calibre to be harvested [Figure 3]. The proximal stem of the thoracodorsal axis artery-graft was of insufficient length to permit direct anastomosis onto the external carotid (ECA) and, therefore, an interpositional vein-graft was harvested from the forearm [Figure 4]. The vein-graft was used to bridge the deficit in length between the thoracodorsal axis artery-graft and the left ECA and passed anterior to the left ear.

### Access this article online

#### Quick Response Code:



#### Website:

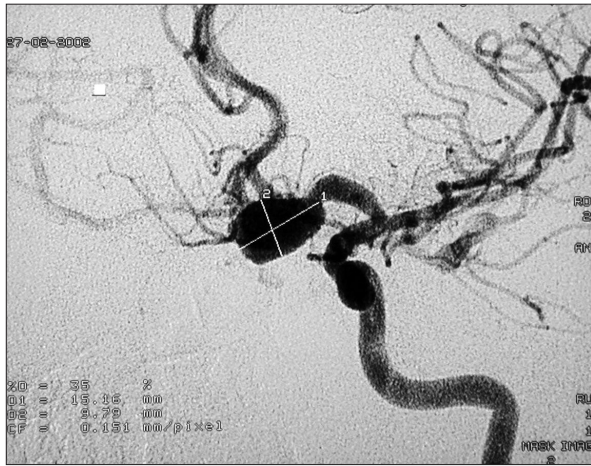www.asianjns.org

#### DOI:

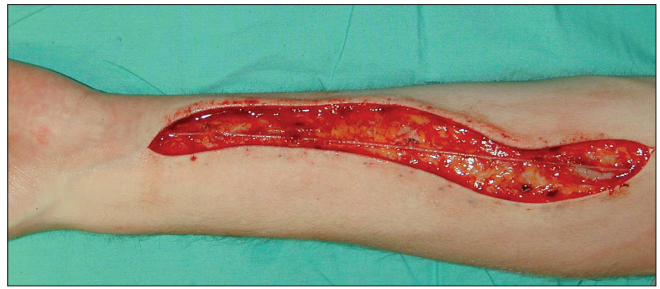10.4103/1793-5482.106654

### Address for correspondence:

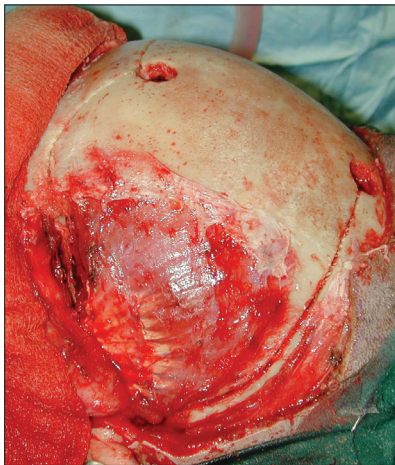Dr. Niroshan Sivathasan, LPMA (London Private Medical Associates), Chaucer House, 130 Church Road, London, United Kingdom. E-mail: niroshan.s@virgin.net



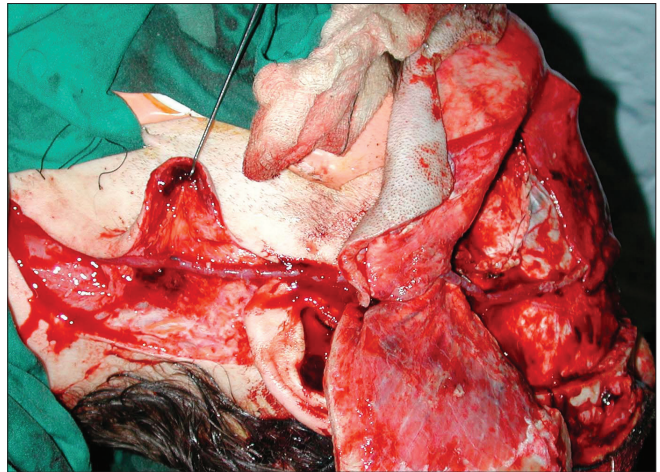
**Figure 1:** Cerebral angiogram shows the large aneurysm (1.5x1 cm) affecting the anterior communicating artery and proximal stems of anterior cerebral arteries



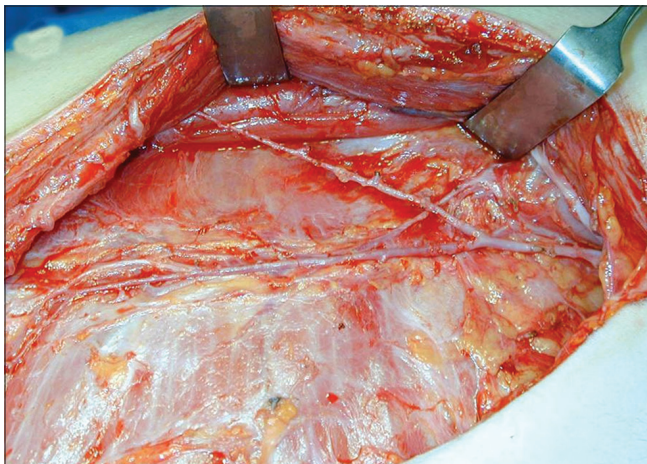**Figure 4:** Harvesting of a vein graft from the forearm. The short proximal stem of the thoracodorsal axis graft did not allow it to be attached to the external carotid artery. Thus, a vein-graft was harvested from the forearm for interpositional-use



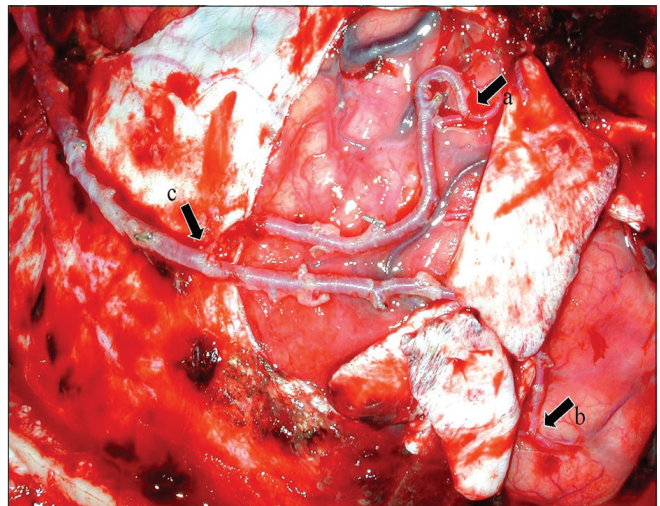
**Figure 2:** A pericranial flap was raised using bicoronal incisions and the left temporalis muscle exposed. A large craniotomy was performed to allow 'pedicling' of the bone flap on the left temporalis muscle. A large craniotomy was performed to allow 'pedicling' of the bone flap on the left temporalis muscle



**Figure 5:** Anastomosing the vein-graft to the external carotid artery and thoracodorsal axis artery-graft, and avoidance of vascular compromise. The vein-graft was used to bridge the deficit in length between the thoracodorsal axis graft and the left external carotid artery, and was passed anterior to the left ear. The vein-graft was passed through a slit in the temporalis muscle so that it would not be compressed upon replacing the bone



**Figure 3:** The thoracodorsal axis artery-graft harvested with an extensive intramuscular dissection allowing both the latissimus dorsi and serratus anterior branches to be obtained



**Figure 6:** Bifurcation of the thoracodorsal axis arterial graft (c) allowing anastomoses onto both left (a) and right (b) anterior cerebral arteries. Once the anastomoses were completed, the aneurysm was then clipped, and the pericranial flap was replaced to cover the anastomoses and seal any dural leaks

The graft was tunneled through a slit in the temporalis muscle so that it would not be compressed when the bone flap was replaced [Figure 5]. End-to-side anastomoses were then performed onto each of the anterior cerebral vessels [Figure 6] and the aneurysm subsequently clipped. The pericranial-flap raised earlier was used to cover the anastomoses and seal any dural leaks, and the bone-flap replaced.

Postoperatively, he was kept intubated as a neuroprotective measure to prevent excessive demand on the re-perfused cerebrum and allow for better control of the blood-pressure. Due to his pre-existing lung-disease, he required a prolonged period of ventilation due to repeated episodes of chest-infection. He did, however, wake-up and respond neurologically, moving all limbs to command and spontaneously opening his eyes, but due to the necessity for continued intubation, could not speak. He was able to communicate clearly in writing. A single photon emission computed tomography (SPECT) perfusion scan performed 48 hours postoperatively demonstrated perfusion of the frontal lobes of the brain, and a CT scan taken one week postoperatively showed no evidence of infarction. Unfortunately, three weeks following surgery the patient died due to overwhelming sepsis secondary to his pre-existing lung-disease.

## Discussion

The purpose of extracranial to intracranial (EC-IC) bypass is to augment cerebral blood-flow. In 1977, an international, randomized, prospective study was instituted to assess the safety and efficacy of the procedure. The study was initiated to determine whether EC-IC bypass could reduce stroke and stroke-related death, but the negative results, published in 1985,<sup>[1]</sup> resulted in a dramatic reduction in the number of bypass procedures performed. Notwithstanding the results of the EC-IC bypass study, this technique still has a role. It is indicated in selected cases of hemodynamic hypoperfusion syndromes and in patients requiring therapeutic occlusion of the internal carotid, for example for unclippable intracranial aneurysms.

Traditionally, a low-flow superficial temporal artery to middle cerebral artery, or occipital artery to posterior cerebral circulation bypass, is performed. The need to bypass the anterior cerebral circulation bilaterally is uncommon. EC-IC bypass, using a saphenous vein or radial artery-graft connecting the external carotid to the cerebral circulation, has been described in cases of bilateral disease.<sup>[2]</sup> Failure rates of 1-1.5% have been reported after the first year with the use of saphenous vein-grafts.<sup>[3]</sup> Artery-grafts have been shown to have better long-term patency rates than vein-grafts in the cardiothoracic literature.<sup>[4]</sup>

We performed bilateral anterior cerebral artery EC-IC bypass using a thoracodorsal axis artery-graft to bypass the anterior cerebral artery circulation to both hemispheres. This is the first report of the use of this graft in the context of EC-IC bypass. The thoracodorsal axis has previously been used in coronary artery bypass-grafting.<sup>[5]</sup> Bifurcated artery-grafts such as the one we describe offer several advantages to vein-grafts. We needed to bypass to both anterior cerebral arteries, and therefore a long Y-shaped graft connected to the carotid would be ideal. Furthermore, the traditional method of using a long saphenous vein or radial artery-graft would result in a significant mismatch in vessel-size at the anastomotic sites. An extensive intramuscular dissection allowed us to obtain vessels with a narrow lumen, which reduced the vessel-mismatch at the distal anastomoses. Although we obtained a narrow-lumen graft, we still encountered a discrepancy in thickness of the vessel walls, as the cerebral vessels are very thin. This, along with the pulsations of the brain, added to the technical difficulty in performing the end-to-side anastomoses.

A collateral circulation is likely to become established over time, leaving the bypass-grafts redundant. However, in the interim, the bypass-grafts prevent ischemic damage. At the time of surgery, the anastomoses were clinically patent and in the early postoperative period, single photon emission scanning demonstrated satisfactory frontal lobe perfusion. Subsequent CT scanning did not show ischemic changes and neurological assessment suggested that the bypass had been successful.

## References

1. Failure of extracranial - intracranial arterial bypass to reduce the risk of ischemic stroke. Results of an international randomized trial. The EC/IC bypass study group. *N Engl J Med* 1985;313:1191-200.
2. Mohit AA, Sekhar LN, Natarajan SK, Britz GW, Ghodke B. High-flow bypass grafts in the management of complex intracranial aneurysms. *Neurosurgery* 2007;60 (2 Suppl 1):105-22.
3. Regli L, Piepgras DG, Hansen KK. Late patency of long saphenous vein bypass grafts to the anterior and posterior cerebral circulation. *J Neurosurg* 1995;83:806-11.
4. Raja SG, Haider Z, Ahmad M, Zaman H. Saphenous vein grafts: To use or not to use? *Heart Lung Circ* 2004;13:403-9.
5. Simić O, Zambelli M, Zelić M, Pirjavec A. Thoracodorsal artery as a free graft for coronary artery bypass grafting. *Eur J Cardiothorac Surg* 1999;16:94-6.

**How to cite this article:** Jain A, O'Neill K, Patel MC, Kirkpatrick N, Sivathasan N, Nanchahal J. Extracranial-intracranial bypass of the bilateral anterior cerebral circulation using a thoracodorsal axis artery-graft. *Asian J Neurosurg* 2012;7:203-5.

**Source of Support:** Nil, **Conflict of Interest:** None declared.