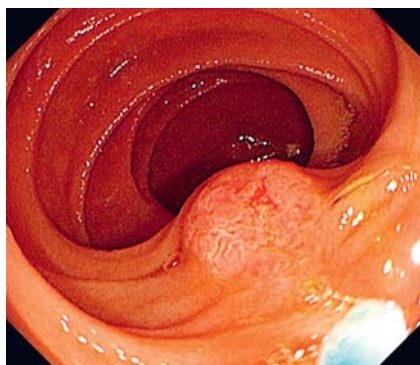
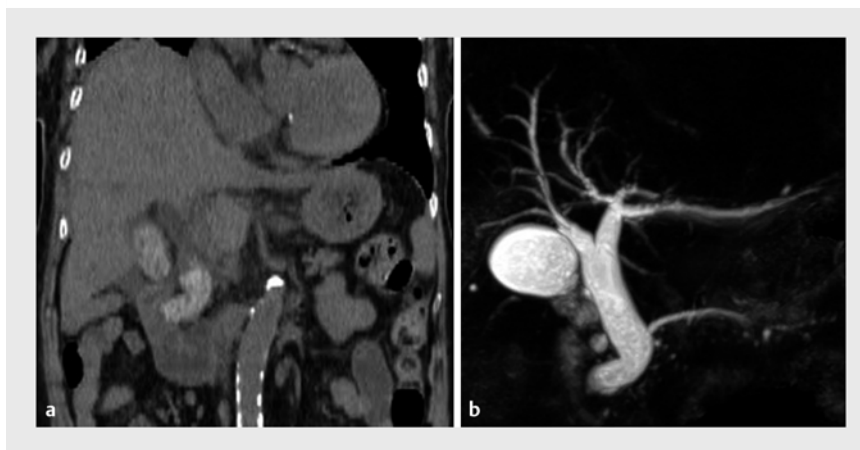


## A traction device to aid the intubation of a surgically altered bile duct during ERCP

OPEN  
ACCESS



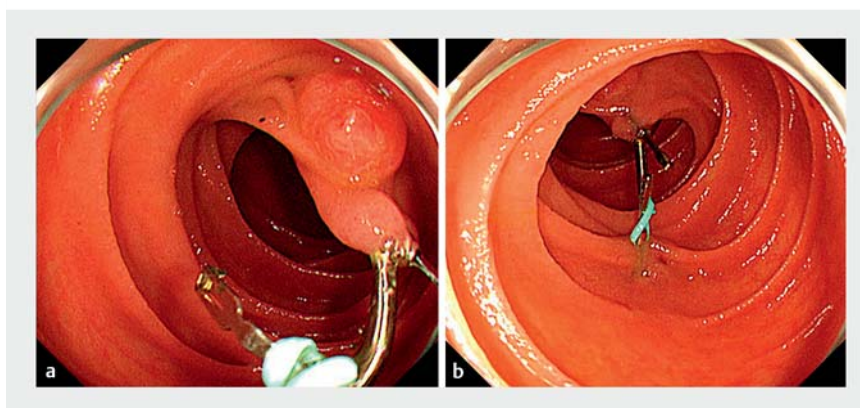
► **Fig. 1** Intubating the common bile duct was not possible with conventional methods.



► **Fig. 2** Images showing kinking of the end of the common bile duct due to postoperative effects. **a** Computed tomography. **b** Magnetic resonance cholangiopancreatography.

A 92-year-old woman was admitted for acute cholangitis with multiple common bile duct (CBD) stones. We performed endoscopic retrograde cholangiopancreatography (ERCP) using a front-viewing endoscope (PCF-Q260AZI; Olympus, Tokyo, Japan) because she had undergone distal gastrectomy with Billroth II reconstruction. However, the ampulla of Vater was not fixed in front, making it difficult to intubate the CBD (► **Fig. 1**). Computed tomography and magnetic resonance cholangiopancreatography showed kinking of the lower end of the CBD due to surgical manipulation (► **Fig. 2**). Thus, traction was applied via a traction device (S-O clip; Zeon Medical Inc., Tokyo, Japan), which was connected to the oral side of the ampulla of Vater; the loop of the clip was grasped (► **Fig. 3 a**) and secured proximally for traction (► **Fig. 3 b**). As a result, the torsion of the CBD resolved, and the ampulla of Vater could be viewed from the front (► **Fig. 4 a**). The CBD was then easily intubated (► **Fig. 4 b**) and a plastic stent was placed for drainage.

Later, we attempted to remove the CBD stones via ERCP using a short-type single-balloon enteroscope (SIF-Q260; Olympus, Tokyo, Japan). Unfortunately, the traction on the S-O clip was lost.



► **Fig. 3** Application of the traction device. **a** An S-O clip (Zeon Medical Inc., Tokyo, Japan) was connected to the oral side of the ampulla of Vater and the loop of the clip was grasped. **b** The clip was secured proximally for traction.

Thus, the traction device technique was repeated (► **Video 1**), and the CBD was easily intubated on the first attempt. Complete removal of stones was achieved via endoscopic papillary large-balloon dilation.

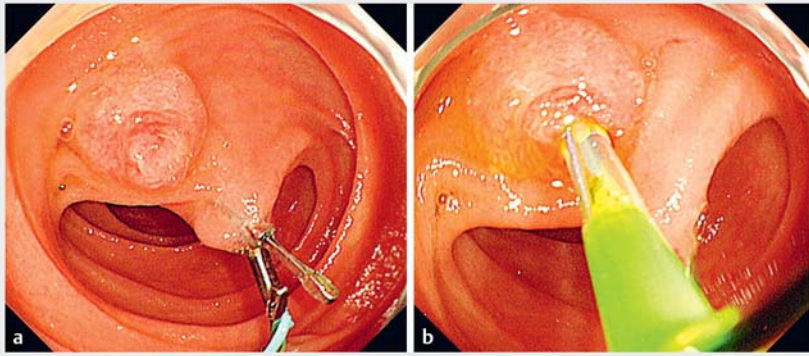
Cases of difficult CBD intubation during ERCP have been reported [1]. The traction device (S-O clip) can also be used in complex cases with diverticular papillae during conventional ERCP [2]. CBD intubation using this device for diverticular papilla in Roux-en-Y reconstruction has

also been reported [3]. However, our patient had a postoperative bile duct flexure rather than a diverticular papilla, distinct from the previous case. The traction device technique used in our case is summarized in ► **Fig. 5**.

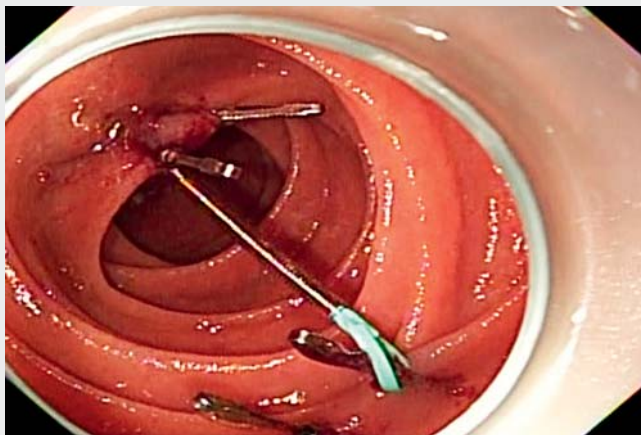
Endoscopy\_UCTN\_Code\_TTT\_1AR\_2AK

### Acknowledgment

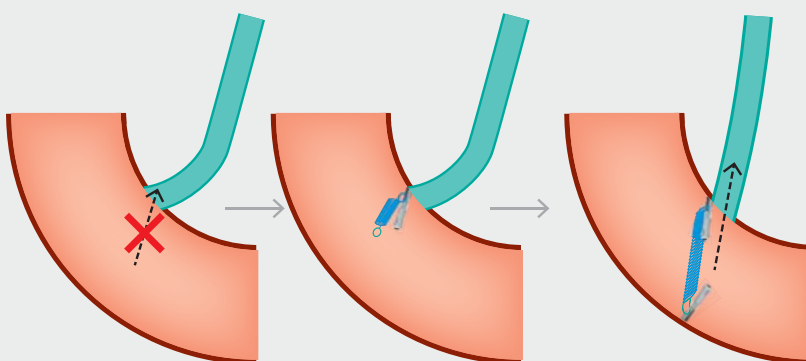
We are grateful to Mr. Noriaki Okada (Zeon Medical Inc.) for creating the schema.



► **Fig. 4** Effect of the traction device on the common bile duct (CBD). **a** The torsion of the CBD was resolved, and the ampulla of Vater was fixed at the front. **b** Intubation of the CBD was then easily performed.



► **Video 1** The S-O clip traction technique. First, an S-O clip (Zeon Medical Inc., Tokyo, Japan) was connected to the oral side of the ampulla of Vater and its loop was grasped. Next, the clip was secured proximally for traction. The torsion of the common bile duct (CBD) was resolved, and the ampulla of Vater was fixed at the front. The CBD was then easily intubated.



The lower end of CBD was kinking. It was difficult to intubate the CBD.

A traction device (S-O clip) was applied. The torsion of the CBD resolved.

The CBD was easily intubated.

► **Fig. 5** A summary of the traction technique used in our patient.

## Competing interests

The authors declare that they have no conflict of interest.

## The authors

**Tsuyoshi Suda**  **Masahiro Yanagi, Naoki Oishi, Eiki Matsushita**

Department of Gastroenterology, Kanazawa Municipal Hospital, Kanazawa, Ishikawa, Japan

## Corresponding author

**Tsuyoshi Suda, MD**

Department of Gastroenterology, Kanazawa Municipal Hospital, 3-7-3, Heiwamachi, Kanazawa, Ishikawa 921-8105, Japan  
t.suda1112@gmail.com

## References

- [1] Freeman ML, Guda NM. ERCP cannulation: a review of reported techniques. *Gastrointest Endosc* 2005; 61: 112–125
- [2] Inoue R, Kawakami H, Kubota Y et al. Endoscopic biliary intervention using traction devices for periampullary diverticulum. *Intern Med* 2019; 58: 2797–2801
- [3] Takeshita K, Asai S, Fujimoto N et al. Usefulness of the S-O clip in balloon enteroscopy-assisted endoscopic retrograde cholangiopancreatography. *Endoscopy* 2021; 53: E372–E373

## Bibliography

*Endoscopy* 2022; 54: E900–E901

DOI 10.1055/a-1847-7609

ISSN 0013-726X

published online 1.7.2022

© 2022. The Author(s).

This is an open access article published by Thieme under the terms of the Creative Commons Attribution-NonDerivative-NonCommercial License, permitting copying and reproduction so long as the original work is given appropriate credit. Contents may not be used for commercial purposes, or adapted, remixed, transformed or built upon. (<https://creativecommons.org/licenses/by-nc-nd/4.0/>)

Georg Thieme Verlag KG, Rüdigerstraße 14, 70469 Stuttgart, Germany

