

Access this article online

Quick Response Code:



Website:

<http://www.braincirculation.org>

DOI:

10.4103/bc.bc\_37\_20

# Management of a ruptured and unruptured pial arteriovenous fistula during and after pregnancy

Clayton H. Gerndt, Dylan J. Goodrich, Dinesh Ramanathan,  
Brian C. Dahlin<sup>1</sup>, Ben Waldau

## Abstract:

We present the case of a 16-week pregnant 19-year-old female who presented with hemiplegia due to a ruptured right frontal pial arteriovenous fistula (PAVF). She was also found to have an unruptured right temporal PAVF and a family history of brain hemorrhage. The patient was managed with Onyx embolization of the ruptured fistula, followed by surgical excision and hematoma evacuation. At 35 weeks gestation, she underwent cesarean section to prevent rupture of the second fistula in the setting of peripartum hypervolemia and increasing headaches. The child was delivered healthy. Subsequently, the right temporal AV fistula, supplied by a middle cerebral artery and posterior cerebral artery branch, underwent staged embolization resulting in complete occlusion. The patient recovered to a modified Rankin score of two, with a left foot drop as only persistent significant motor deficit.

## Keywords:

Arteriovenous fistula, onyx embolization, pregnancy

## Introduction

Pial arteriovenous fistulae (PAVF) are rare vascular lesions of the brain, representing 1.6%–4.7% of all brain arteriovenous malformations (BAVM).<sup>[1]</sup> PAVFs distinguish themselves from BAVMs through the absence of a nidus resulting in a direct connection between artery, or arteries, and vein(s). We present the rare case of a PAVF rupture during pregnancy in a patient with two PAVFs. This case shows that DMSO (dimethyl sulfoxide)/Onyx embolization in pregnancy is safe for both the mother and child. It also shows that it is safe to sequentially manage multiple PAVFs in pregnancy, addressing ruptured PAVFs first during pregnancy, and waiting for obliteration of the nonruptured PAVFs until after delivery.

This is an open access journal, and articles are distributed under the terms of the Creative Commons Attribution-NonCommercial-ShareAlike 4.0 License, which allows others to remix, tweak, and build upon the work non-commercially, as long as appropriate credit is given and the new creations are licensed under the identical terms.

For reprints contact: WKHLRPMedknow\_reprints@wolterskluwer.com

## Case Report

### Presentation

A 19-year-old pregnant female at approximately 17 weeks gestation presented to the emergency department with headache, nausea, and emesis while at school. Initial neurosurgical evaluation in the ED demonstrated an awake and drowsy patient with Glasgow Coma Scale of 12 with a breakdown of E2 M6 V4 and plegia of her left upper and lower extremities. Initial computed tomography (CT) scan [Figure 1] demonstrated a right-sided frontal-parietal intra-cerebral hemorrhage (ICH) measuring 5.5 cm × 7.7 cm with intraventricular extension and 8 mm of leftward midline shift. There was also a 2.5 cm × 3.5 cm partially calcified high attenuation lesion concerning for a varix or aneurysm. CT angiogram [Figure 1] demonstrated a right fronto-parietal PAVF with dilated venous angioma and superficial cortical drainage in

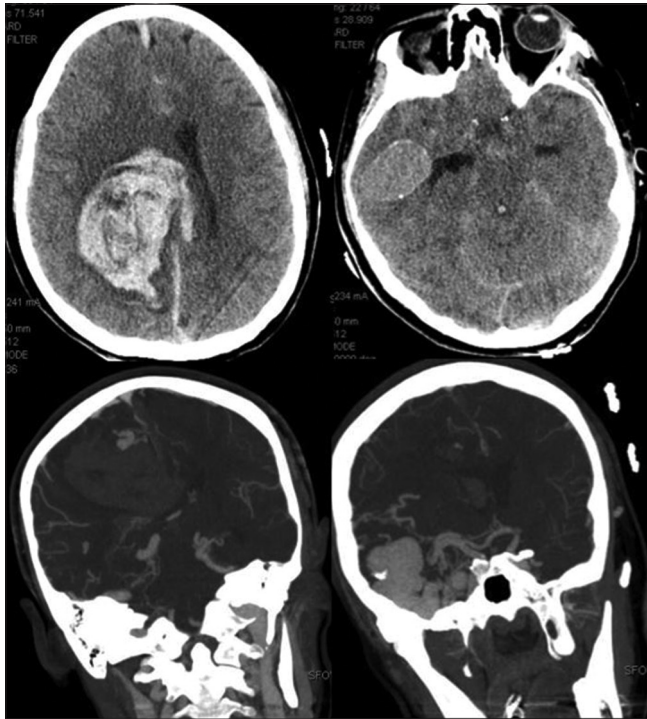
**How to cite this article:** Gerndt CH, Goodrich DJ, Ramanathan D, Dahlin BC, Waldau B. Management of a ruptured and unruptured pial arteriovenous fistula during and after pregnancy. *Brain Circ* 2021;7:124-7.

UC Davis Department  
of Neurological Surgery,  
<sup>1</sup>UC Davis Department of  
Neurological Interventional  
Radiology, University of  
California Davis Medical  
Center, Sacramento,  
California, Clayton, USA

### Address for correspondence:

Dr. Ben Waldau,  
4860 Y Street, Suite 3740  
Sacramento, CA 95817  
(916) 734-4300, USA.  
E-mail: [bwaldau@ucdavis.edu](mailto:bwaldau@ucdavis.edu)

Submission: 13-08-2020  
Revised: 22-01-2021  
Accepted: 27-03-2021  
Published: 29-05-2021



**Figure 1:** Top row: Noncontrast computed tomography scans demonstrating large right fronto-parietal intra-cerebral hemorrhage and right temporal partially calcified hyperdense lesion. Bottom row: Computed tomography angiogram in coronal plane show a right frontal arteriovenous fistula and right temporal arteriovenous fistula with venous varix and dilated tortuous feeding vessels

the parafalcine area with no discrete nidus. In the right temporal lobe, there was a suspected PAVF along the right M3 division of the middle cerebral artery (MCA) with a large venous varix with both superficial and deep drainage into the basal veins of Rosenthal and right sphenoparietal sinus and right transverse sinus.

The patient developed persistent vomiting and was intubated for airway protection prior to being brought to the endovascular suite for diagnostic digital subtraction angiogram (DSA). DSA confirmed the CTA findings and showed that the right fronto-parietal PAVF feeding vessels were from the left pericallosal artery and draining into the superior sagittal sinus along with a steal phenomenon with retrograde flow through the right anterior cerebral artery [Figure 2a and b]. The right temporal lesion showed early venous filling of the large varix with no discernible feeding vessel aneurysm [Figure 2c and d]. Vertebrobasilar injection demonstrated additional recruitment through a right posterior cerebral artery P3 segment supplying the right temporal PAVF [Figure 2i].

### Initial treatment

The patient did not require ventriculostomy and continued to follow commands throughout hospitalization and self-extubated without complication 7 days after presentation. On postbleed day 14, she was taken back to the neuroangiography suite for

Onyx embolization of the right fronto-parietal feeding vessels followed by craniotomy for resection of this lesion and hematoma evacuation [Figure 2g, e and f]. During resection, an arterialized vein of Trolard was encountered and this turned blue in color after ligation of the PAVF. She tolerated the procedures well and was extubated on postoperative day one. Postoperative magnetic resonance imaging showed good evacuation of hematoma with reduced mass effect and midline shift [Figure 2h]. She and her fetus continued to be stable and she was discharged to the physical medicine and rehabilitation service on postoperative day five.

During initial DSA as well as treatment angiogram, a lead apron shield was used over the patient's abdomen to reduce the radiation exposure to her fetus. The patient received a total dose of 784.3 mGy (milli-gray) during the DSA and 11 days later 1991.0 mGy during the embolization procedure.

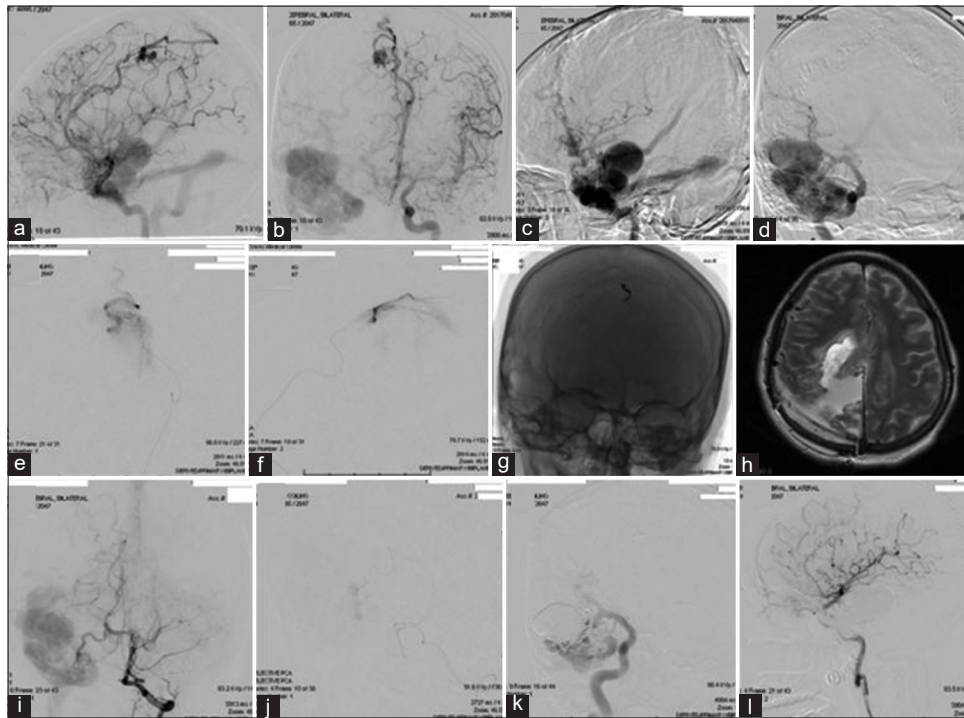
The obstetrics team was involved at the time of admission and followed along with weekly Doppler tones and providing medication recommendations during the initial admission. During outpatient follow-up, we recommended consideration of urgent C-section due to hypervolemia gravidarum and increased headaches after a clinic visit at 33 weeks gestation to prevent rupture of the second PAVF. The patient went on to deliver via low transverse cesarean section at 35 weeks and 3 days gestation to a healthy girl with Apgar scores of 6 and 8 at birth.

### Postpartum treatment

Five months after delivery of her baby, the patient returned for elective staged embolization of the right temporal PAVF [Figure 2i-k]. The procedure required a combination of Onyx embolization of PCA feeding vessel and coil embolization of venous varix from the right MCA branches. No complications occurred and the patient returned the following day for the second stage embolization of the MCA feeding vessels with Onyx. There were no complications after the procedure and she was discharged home after monitoring for 48 h. At 6 months postembolization, an angiogram was performed which showed complete obliteration of the giant right temporal PAVF and the right frontoparietal PAVF [Figure 2l]. She recovered to a modified Rankin score of two and was ambulatory with a left ankle-foot orthosis with a left foot drop as only significant residual motor deficit.

### Discussion

This case report delineates the management of multiple PAVFs in the setting of rupture during pregnancy. There are no data for the re-rupture risk of a PAVF during



**Figure 2:** (a-b) Anteroposterior and lateral projections of left internal carotid artery injections showing pericallosal branches feeding a right fronto-parietal arteriovenous fistula with venous angiomata draining into SSS. (c-d) Right internal carotid artery anteroposterior and lateral projections show large venous varix fed by right middle cerebral artery branches. (e-g) Super selection of left pericallosal artery and onyx injection followed by anteroposterior skull XR of onyx case. (h) T2 axial magnetic resonance imaging after right parietal craniotomy for evacuation of hematoma and arteriovenous fistula resection showing reduced mass effect. (i-j) Left vertebral artery injection anteroposterior projection demonstrating right P3 segment of posterior cerebral artery feeding temporal arteriovenous fistula followed by super-selection and onyx embolization of this branch. (k) Right internal carotid artery injection after coils placed and subsequent onyx embolization of venous varix. (l) 6 month post treatment lateral projection demonstrating complete obliteration of large pial arteriovenous fistula and associated varix

pregnancy, however, the risk of re-bleeding from a ruptured BAVM during pregnancy can be as high as 27%–30%.<sup>[2]</sup> Therefore, we chose Onyx embolization for the ruptured PAVF despite the potential unknown risks associated with DMSO. DMSO is classified as an FDA pregnancy category C drug which means that animal reproduction studies have found an adverse effect on the fetus, and there are no adequate and well-controlled studies in humans. We only found two studies of DMSO/Onyx utilization for ruptured AVMs in the setting of pregnancy in the literature.<sup>[3,4]</sup> No reports of DMSO/Onyx utilization for ruptured PAVFs in pregnancy were found. In a PAVF, DMSO/Onyx may cross over onto the venous side and systemic circulation more easily than in a BAVM because there is no nidus. Acute respiratory distress syndrome has been reported for Onyx embolization of an arteriovenous malformation,<sup>[5]</sup> and the high-flow nature of a PAVF may promote this complication and cause a risk to the fetus. There is also a potential risk of placental vasospasm with DMSO causing abortion or fetal injury. DMSO/Onyx was administered in the second trimester and did not have a toxic or teratogenic effect in our patient.

We decided to manage the unruptured PAVF conservatively during pregnancy. There are no

data on the management of unruptured PAVF in pregnancy. However, the rupture risk may compare to the rupture risk of BAVMs. Whether pregnancy increases the rupture risk of a BAVM remains controversial. While large retrospective clinical studies with 979 and 451 patients have not shown an increased risk of AVM rupture in pregnancy,<sup>[6,7]</sup> other studies with 270, 264, and 54 women have shown an increased risk.<sup>[8-10]</sup> We decided to monitor our patient and proceeded with C-section at 35 weeks and 3 days of gestation. This was recommended after she developed a headache and hypervolemia gravidarum since we were concerned that the large right temporal varix was at imminent risk of rupture.

To shut down the large right temporal varix, we elected a staged approach with Onyx embolization of the PCA feeding vessel followed by coiling of the venous varix during the first procedure. Coiling of the varix slowed down the flow through the fistula so that the residual fistula supplied by the MCA could be safely embolized the next day with DMSO/Onyx without causing respiratory distress syndrome or Onyx propagation into in the superior petrosal sinus/sigmoid sinus.

We recognize that open surgery alone was an option for her first surgery and open or combined approach was an option for her second. Clipping alone for her ruptured fronto-parietal PAVF was a reasonable option and would have avoided any potential complication of DMSO. We felt that risk of DMSO was low and that initial endovascular embolization would decrease the hemorrhage risk during craniotomy and help with precise localization of fistulous point in a deep-seated PAVF. For her unruptured right temporal PAVF, we felt that endovascular treatment alone could be curative and minimize risk of significant hemorrhage given the large venous varix.

### Conclusion

Multiple PAVF resulting in hemorrhage in pregnancy is a very rare clinical scenario, and data on appropriate management are missing. We elected to embolize and resect the ruptured PAVF during pregnancy and waited on curative embolization of the right temporal PAVF after the pregnancy to shield the fetus from radiation and the risk of the procedure. We have shown that Onyx embolization of a ruptured PAVF can be performed safely in the second trimester and that a concurrent unruptured lesion can be safely managed through a cesarean delivery and managed postpartum. Further studies are needed to determine appropriate treatment algorithms.

### Declaration of patient consent

The authors certify that they have obtained all appropriate patient consent forms. In the form the patient(s) has/have given his/her/their consent for his/her/their images and other clinical information to be reported in the journal. The patients understand that their names and initials will not be published and

due efforts will be made to conceal their identity, but anonymity cannot be guaranteed.

### Financial support and sponsorship

Nil.

### Conflicts of interest

There are no conflicts of interest.

### References

1. Lv X, Li Y, Jiang C, Wu Z. Endovascular treatment of brain arteriovenous fistulas. *AJNR Am J Neuroradiol* 2009;30:851-6.
2. Trivedi RA, Kirkpatrick PJ. Arteriovenous malformations of the cerebral circulation that rupture in pregnancy. *J Obstet Gynaecol* 2003;23:484-9.
3. Dashti SR, Spalding AC, Yao TL. Multimodality treatment of a ruptured grade IV posterior fossa arteriovenous malformation in a patient pregnant with twins: Case report. *J Neurointerv Surg* 2012;4:e21.
4. Jermakowicz WJ, Tomycz LD, Ghiassi M, Singer RJ. Use of endovascular embolization to treat a ruptured arteriovenous malformation in a pregnant woman: A case report. *J Med Case Rep* 2012;6:113.
5. Tawil I, Carlson AP, Taylor CL. Acute respiratory distress syndrome after onyx embolization of arteriovenous malformation. *Crit Care Res Pract* 2011;2011:918185.
6. Liu XJ, Wang S, Zhao YL, Teo M, Guo P, Zhang D, *et al.* Risk of cerebral arteriovenous malformation rupture during pregnancy and puerperium. *Neurology* 2014;82:1798-803.
7. Horton JC, Chambers WA, Lyons SL, Adams RD, Kjellberg RN. Pregnancy and the risk of hemorrhage from cerebral arteriovenous malformations. *Neurosurgery* 1990;27:867-71.
8. Porras JL, Yang W, Philadelphia E, Law J, Garzon-Muvdi T, Caplan JM, *et al.* Hemorrhage risk of brain arteriovenous malformations during pregnancy and puerperium in a North American Cohort. *Stroke* 2017;48:1507-13.
9. Zhu D, Zhao P, Lv N, Li Q, Fang Y, Li Z, *et al.* Rupture risk of cerebral arteriovenous malformations during pregnancy and puerperium: A single-center experience and pooled data analysis. *World Neurosurg* 2018;111:e308-15.
10. Gross BA, Du R. Hemorrhage from arteriovenous malformations during pregnancy. *Neurosurg* 2012;71:349-55.