

growth. Therefore, drainage of fluid and removal of the cavity was needed before the infection occurred. For that reason, early detection is important, and knowledge of Morel-Lavallee syndrome and a high index of suspicion are needed.

References

1. Morel-Lavallee M. Decollements traumatiques de la peau et des couches sousjacentes. *Arch Gen Med* 1863;1:20-38, 172-200, 300-32.
2. Letourmel E, Judet R. Fractures of the acetabulum. 2nd ed. Berlin: Springer; 1993.
3. Dawre S, Lamba S, H S, et al. The Morel-Lavallee lesion: a review and a proposed algorithmic approach. *Eur J Plast Surg* 2012;35:489-94.
4. Tseng S, Tornetta P 3rd. Percutaneous management of Morel-Lavallee lesions. *J Bone Joint Surg Am* 2006; 88:92-6.
5. Kottmeier SA, Wilson SC, Born CT, et al. Surgical management of soft tissue lesions associated with pelvic ring injury. *Clin Orthop Relat Res* 1996;(329):46-53.

Extravasation of a Percutaneous Femoral Hepatic Infusion Device

Bommie Florence Seo, Hyunwook Jung, Hyun Ho Han, Suk Ho Moon, Deuk Young Oh, Sang Tae Ahn, Jong Won Rhie

Department of Plastic and Reconstructive Surgery, Seoul St. Mary's Hospital, Catholic University of Korea College of Medicine, Seoul, Korea

Correspondence: Jong Won Rhie
Department of Plastic and Reconstructive Surgery, Seoul St. Mary's Hospital, Catholic University of Korea College of Medicine, 222 Banpo-daero, Seocho-gu, Seoul 137-701, Korea
Tel: +82-2-2258-2842, Fax: +82-2-594-7230
E-mail: rhie@catholic.ac.kr

No potential conflict of interest relevant to this article was reported.

Received: 26 Feb 2014 • Revised: 15 Mar 2014 • Accepted: 17 Mar 2014
pISSN: 2234-6163 • eISSN: 2234-6171
<http://dx.doi.org/10.5999/aps.2015.42.1.93> • Arch Plast Surg 2015;42:93-95

Copyright © 2015 The Korean Society of Plastic and Reconstructive Surgeons
This is an Open Access article distributed under the terms of the Creative Commons Attribution Non-Commercial License (<http://creativecommons.org/licenses/by-nc/3.0/>) which permits unrestricted non-commercial use, distribution, and reproduction in any medium, provided the original work is properly cited.

Using a femoral approach for inserting an intra-arterial percutaneous catheter-port device has recently been introduced for targeted treatment of hepatic tumors

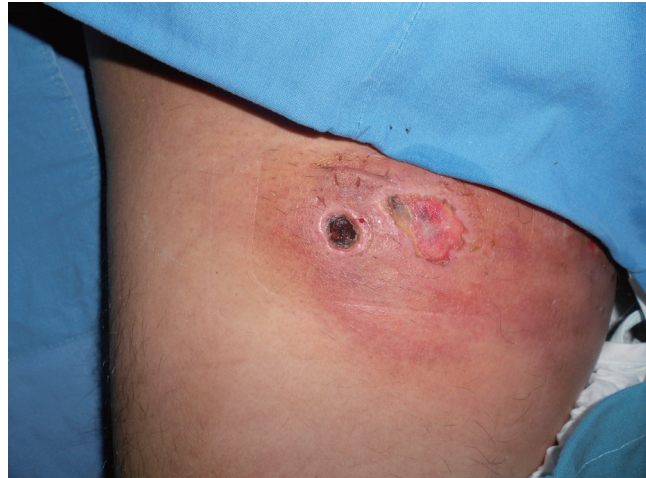

Fig. 1.

The lesion upon consultation. There is dry eschar, edema, and skin color change in the right thigh of the patient.

[1]. Unlike permanent devices that have to be implanted surgically under general anesthesia, percutaneous catheter-ports may be installed under local anesthesia, a benefit for the many cancer patients who have already undergone cancer surgery. The subclavian route is also an option; however, there exists a risk of pneumothorax, reported to be around 4%, and also other complications such as local hematoma and brain infarction [2,3]. Thus, many institutions have been compiling their experience with femoral access and have reported relatively low complication rates [1,2].

Unfortunately, as with any injection device, there is always the possibility of extravasation, the leakage of injection material into tissue other than that targeted. Chemotherapeutic agents are generally cytotoxic and may cause necrosis of the surrounding tissue in the thigh and groin area; therefore, this medical emergency must never be underestimated.

A 29-year-old male patient was referred to the plastic surgery department for infection signs in his right inguinal area (Fig. 1). A hepatitis B carrier through vertical transmission, he had been diagnosed with hepatocellular carcinoma one month previously, and had received his first cycle of chemotherapy by way of a percutaneous intra-arterial catheter port device via his femoral artery.

While being started on his second cycle, he reported pain in the port area, and administration of epirubicin was immediately stopped. An estimated 15 mL of epirubicin had been administered. The port function was tested, and was found to be normal. Inflammation signs increased, and the port device

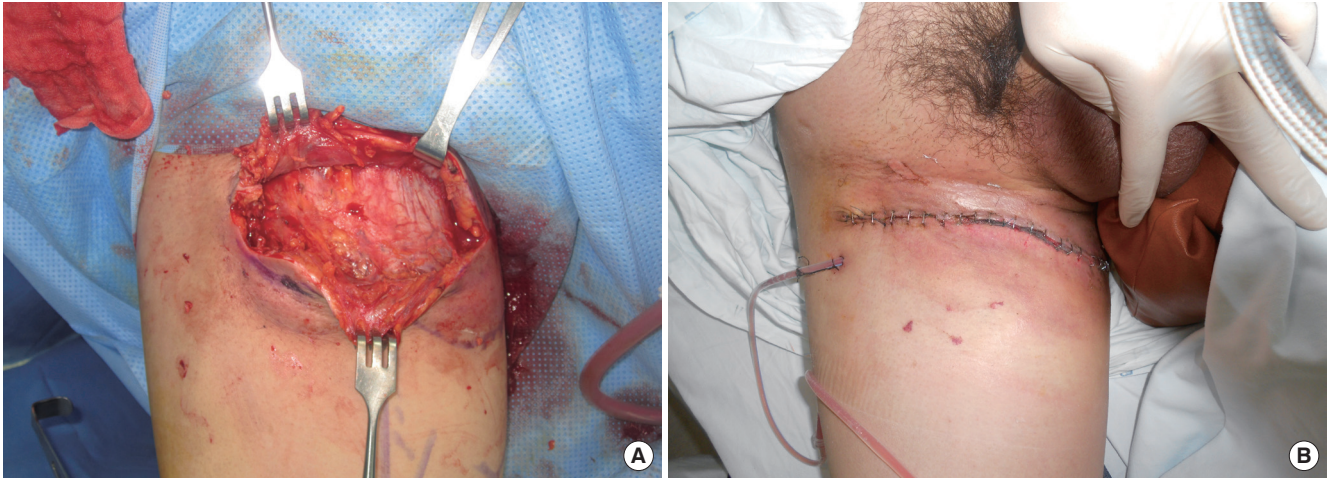


Fig. 2.

Intraoperative views. (A) Necrotic tissue including the skin, subcutaneous layer, and part of the muscle fascia is debrided. (B) Local flap coverage is performed.

was removed three days later. He had developed erythema, induration, and swelling of his right medial thigh with a necrotic skin defect measuring 3 cm in diameter, and was thus referred to the plastic surgery department a week after the incident. Computed tomography revealed diffuse swelling and inflammation of the right femoral area, without any abnormal fluid collection.

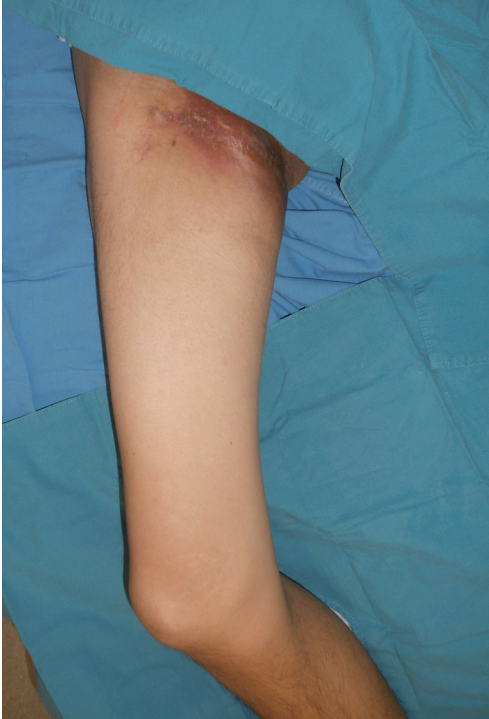The wound was dressed until demarcation, during which an area of erythematous induration 20×10 cm in size developed, with several points of skin necrosis. Excision of the unhealthy skin was performed, and the necrotic soft tissue was debrided until healthy pinpoint bleeding was found at the fascia level. Local flap coverage was performed and negative pressure wound therapy was applied to aid flap approximation and circulation (Fig. 2).

The flap took about 6 weeks to heal completely, with small areas of disruption that were closed by secondary intention (Fig. 3). The patient's low levels of albumin ranging from 2.5 to 3.0 g/dL, anemia with hemoglobin concentrations ranging from 8.2 to 11.0 g/dL, and cycles of chemotherapy were all factors delaying the process of healing. His wound was otherwise uneventful until he expired just over 6 months after diagnosis due to multiorgan failure. Hepatic arterial infusion chemotherapy uses the hepatic artery catheter as a conduit to deliver antineoplastic agents in high concentrations to liver tumors. Permanent intra-arterial catheter systems have to be inserted surgically, either into the gastroduodenal artery or the common hepatic artery. To facilitate long-term administration, percutaneous

implantable catheter-port devices have been developed. Herrmann reported on the use of the femoral artery for percutaneous implantation in 2000, a readily accessible method with which most radiologists are familiar [1]. The procedure may be performed under local anesthesia and provides a subcutaneous port that is available for repeated chemotherapy or prolonged parenteral nutrition. The success rate for implantation has been reported to be 90% to 100%, and the implantation technique has been constantly refined to prevent such technical complications as catheter dislocation or migration, catheter occlusion, or extrahepatic perfusion [3].

Chemotherapy ports, like all other injection devices, carry a risk of extravasation, the leakage of an injection agent into untargeted surrounding tissue. The incidence of implanted port extravasation has been reported to be 0.3% to 4.7% [4]. However, this is probably lower than the actual incidence, as most cases are not reported in the literature. Femoral ports, with their many benefits, are unfortunately located in an area where there is usually an abundance of soft tissue, unlike the subclavian port, which is easily located visually. This increases the risk of missing the target, and also necessitates use of a longer needle, which may be more easily dislodged. This also increases the risk of delayed detection because a significant amount of fluid may extravasate subcutaneously before tissue pressures increase.

Extravasation results in serious necrosis of the surrounding tissue and vasculature, and may require extensive debridement and reconstruction, as in our case. Thus, the authors suggest that several basic

**Fig. 3.**

The wound at 6 weeks' follow-up. The flap healed completely.

precautions be strictly adhered to when implanting and injecting femoral catheter ports. If possible, the port should be located in a more superficial layer so that it is visible externally. Blood withdrawal before injection and saline injection preceding the agent to check for adequate needle placement is mandatory. If in doubt, insertion of the injection needle under ultrasonographic guidance is an option. Patient education and monitoring of the medical team are needed, given the fact that thigh soft tissue is thick and therefore signs of extravasation may be more muted in this area.

Oncology patients in general, not to mention hepatic tumor patients, are in a catabolic state, and consequently have a delayed wound healing prognosis. Extravasation is a devastating medical accident that is detrimental to the patient's quality of life and physical health. The patient in our case spent two months of his remaining six months of life recovering from this injury. The risk of extravasation should always be kept in mind when manipulating femoral catheter ports.

References

1. Herrmann KA, Wagershauser T, Sittek H, et al. Liver

- intraarterial chemotherapy: use of the femoral artery for percutaneous implantation of catheter-port systems. *Radiology* 2000;215:294-9.
2. Yamagami T, Kato T, Iida S, et al. Management of end hole in placement of port-catheter system for continuous hepatic arterial infusion chemotherapy using the fixed catheter tip method. *AJR Am J Roentgenol* 2005;184:1332-9.
3. Deschamps F, Rao P, Teriitehau C, et al. Percutaneous femoral implantation of an arterial port catheter for intraarterial chemotherapy: feasibility and predictive factors of long-term functionality. *J Vasc Interv Radiol* 2010;21:1681-8.
4. Schulmeister L, Camp-Sorrell D. Chemotherapy extravasation from implanted ports. *Oncol Nurs Forum* 2000;27:531-8.

Gemella morbillorum Infection after Acupuncture Therapy

Hyung Rok Cho, Soon Sung Kwon, Seum Chung

Department of Plastic Surgery, National Health Insurance Service Ilsan Hospital, Goyang, Korea

Correspondence: Soon-Sung Kwon
Department of Plastic Surgery, National Health Insurance Service Ilsan Hospital, 100 Ilsan-ro, Ilsandong-gu, Goyang 410-719, Korea
Tel: +82-31-900-0042, Fax: +82-31-900-0038
E-mail: frc22@daum.net

No potential conflict of interest relevant to this article was reported.

Received: 9 Dec 2013 • Revised: 23 Jan 2014 • Accepted: 5 Feb 2014
pISSN: 2234-6163 • eISSN: 2234-6171
<http://dx.doi.org/10.5999/aps.2015.42.1.95> • Arch Plast Surg 2015;42:95-97

Copyright © 2015 The Korean Society of Plastic and Reconstructive Surgeons
This is an Open Access article distributed under the terms of the Creative Commons Attribution Non-Commercial License (<http://creativecommons.org/licenses/by-nc/3.0/>) which permits unrestricted non-commercial use, distribution, and reproduction in any medium, provided the original work is properly cited.

Gemella morbillorum (*G. morbillorum*) is a part of the normal human flora and is an extremely rare cause of infection [1]. However, *Gemellae* are also classified as opportunistic pathogens that are able to cause severe localized and generalized infections [2]. In this case report, we describe an infection of *G. morbillorum* on the chest wall after acupuncture therapy. Our patient was a 74-year-old male who had a thoracic wall contusion because of a bicycle accident. Initially, there were no open wounds or specific symptoms besides bruising and mild pain. The patient underwent acupuncture therapy before the trauma event due to