

## Organizing Thrombus Mimicking a Cardiac Tumor Located at the Mitral-Aortic Intervalvular Fibrosa

Ji Seong Lee, M.D.<sup>1</sup>, Wan Seop Kim, M.D.<sup>2</sup>, Seong Min Ko, M.D.<sup>3</sup>, Je Kyoum Shin, M.D.<sup>1</sup>

Thrombosis at the left ventricular outflow tract occurs without any detectable heart disease or predisposing factors only extremely rarely. A 48-year-old male visited Konkuk University Medical Center with loss of consciousness one month prior to presentation. Before he visited our hospital, he had been diagnosed with a cardiac tumor, which was located between the left atrium and posterior aortic root, and which was adjacent to both the aortic and mitral valves. Cardiac transplantation was recommended at the other hospital because of the high risk of cardiac dysfunction induced by both aortic and mitral valvular dysfunction after surgical resection. Based on preoperative transthoracic echocardiography, cardiac computed tomography, cardiac magnetic resonance imaging, and intra-operative transesophageal echocardiography, we considered it to be a benign tumor. Complete resection was achieved and the pathology confirmed organizing thrombus. We report a case of organizing thrombus mimicking a cardiac tumor, which was located at the mitral-aortic intervalvular fibrosa of the left ventricular outflow tract without any heart disease.

Key words: 1. Thrombosis  
2. False aneurysm  
3. Mitral-aortic intervalvular fibrosa  
4. Left ventricular outflow tract

### CASE REPORT

A 48-year-old man was referred to Konkuk University Medical Center because of a recently diagnosed cardiac tumor. He had no significant medical history and no chest trauma history. He did not present any current symptoms when he visited our hospital, but one month earlier, he had suddenly experienced a loss of consciousness, generalized weakness, and cold sweats. At that time, he visited another hospital, and a cardiac tumor was revealed by cardiac computed tomography (CT), cardiac magnetic resonance imaging (MRI), and transthoracic echocardiography (TTE). Cardiac

transplantation was recommended because of a high risk of cardiac dysfunction induced by both aortic and mitral valvular dysfunction after surgical resection. Results of preoperative evaluations performed at our hospital were as follows. His hemoglobin was 15.4 g/dL. The total white blood count was 10,000/ $\mu$ L. The differential count showed neutrophils at 55.7%, lymphocytes 35.5%, monocytes 6.8%, basophils 0.2%, and eosinophils 1.8%. Cardiac enzymes were normal. Prothrombin time, activated partial thromboplastin time, and platelet count were normal. Homocysteine was normal. On physical examination, he presented clear breath sounds without remarkable cardiac murmurs. A chest X-ray showed nor-

Departments of <sup>1</sup>Thoracic and Cardiovascular Surgery, <sup>2</sup>Pathology, and <sup>3</sup>Radiology, Konkuk University Medical Center, Konkuk University School of Medicine

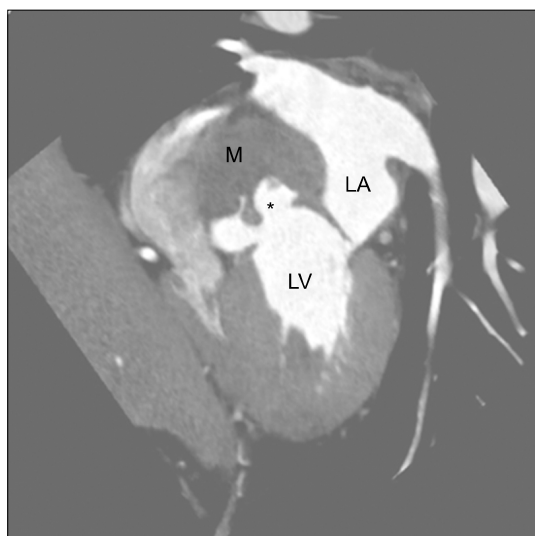
Received: November 11, 2014, Revised: December 7, 2014, Accepted: December 8, 2014, Published online: February 5, 2016

Corresponding author: Je Kyoum Shin, Konkuk University Medical Center, 120-1 Neungdong-ro, Gwangjin-gu, Seoul 05030, Korea

(Tel) 82-2-2-2030-7595 (Fax) 82-2-2030-5009 (E-mail) [jekshin@kuh.ac.kr](mailto:jekshin@kuh.ac.kr)

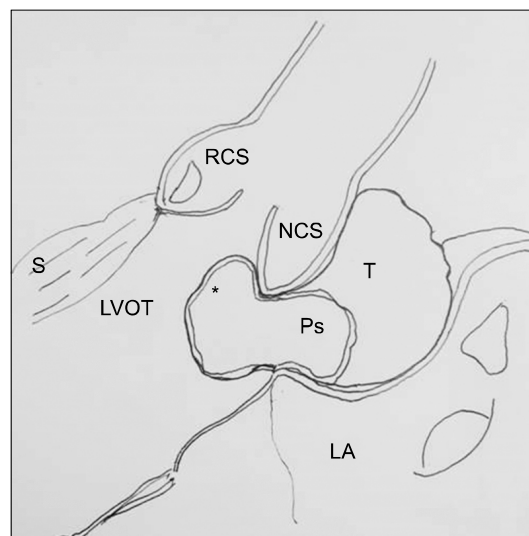
© The Korean Society for Thoracic and Cardiovascular Surgery. 2016. All right reserved.

© This is an open access article distributed under the terms of the Creative Commons Attribution Non-Commercial License (<http://creativecommons.org/licenses/by-nc/4.0>) which permits unrestricted non-commercial use, distribution, and reproduction in any medium, provided the original work is properly cited.



**Fig. 1.** Preoperative cardiac computed tomography with enhancement show a mass partially filled with contrast material from LV during systole. Asterisk (\*) indicates a pseudoaneurysm. LA, left atrium. LV, left ventricle. M, organized thrombus.

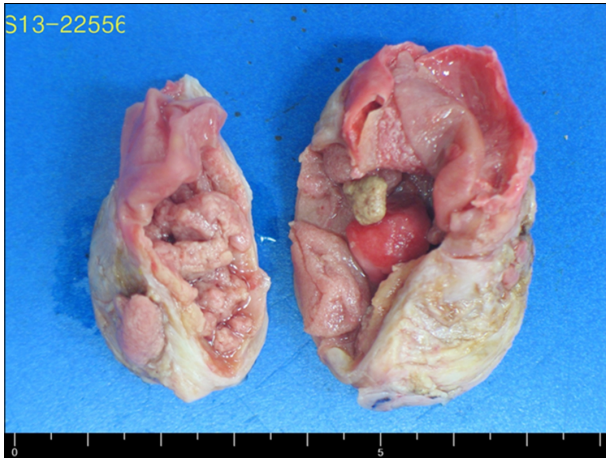mal findings. His blood pressure was 123/79 mmHg with a regular beat of 71 beats/min. Electrocardiography showed sinus rhythm with occasional first-degree atrioventricular block. Two-dimensional TTE showed a normal left ventricular chamber size (left ventricular end diastolic diameter, 4.5 cm; left ventricular end systolic diameter, 2.4 cm), normal systolic function (left ventricular ejection fraction, 75.1%), and normal left ventricular wall thickness without regional wall motion abnormality and well-functioning aortic and mitral valve without structural defects such as atrioseptal defect or ventricular septal defect, while it clearly demonstrated a heterogeneous cystic mass (49×25 mm) composed of two portions. One portion of the mass was moving during cardiac cycles; it protruded into the left ventricular outflow tract during diastole and entered between the left atrium and posterior aortic root during systole. The other portion of the mass stayed between the left atrium and posterior aortic root with little change during the cardiac cycle (Video 1A). Color Doppler flow imaging did not demonstrate definite blood flow between this cystic mass and the left ventricular outflow tract (Video 1B). Preoperative cardiac CT and MRI revealed a dumb-bell-shaped, well-demarcated mass, 5.5×3.5×4.0 cm in size, located at the mitral-aortic intervalvular fibrosa. Cardiac MRI



**Fig. 2.** Schematic diagram of intraoperative findings. LA, left atrium. LVOT, left ventricular outflow tract. NCS, non-coronary sinus of Valsava sinus. Ps, pseudoaneurysm. RCS, right coronary sinus of Valsava sinus. S, interventricular septum. T, organized thrombus. Asterisk (\*) indicates mobile portion of pseudoaneurysm.

showed a multi-septated cystic mass with a fragile thin wall without rupture and presented heterogeneous signal intensity indicating a very proteinaceous fluid. It was noted that a small portion of the mass protruded into the left ventricular outflow tract on diastole. Cardiac CT demonstrated a pseudoaneurysm that was filled with contrast material from the left ventricle during systole (Fig. 1).

The patient underwent surgical treatment. Median sternotomy was performed. After conventional cardiopulmonary bypass was initiated, cardioplegia was induced by infusion of cold blood cardioplegic solution into the aortic root under moderate hypothermia. Transverse aortotomy was performed just above the sinotubular junction. The mass was soft and well-encapsulated. In an extracardiac view, most of the mass was located outside of the heart. A small area of the mass was attached at the outer wall of the non-coronary sinus of Valsalva sinus. In an intracardiac view, a small portion of the mass protruded into the intracardiac cavity at the mitral-aortic intervalvular fibrosa (Fig. 2). After the intracardiac portion of the mass was completely resected, the communication of the left ventricular outflow tract with the remnant mass was found. The defect area of the mitral-aortic intervalvular fi-



**Fig. 3.** A specimen. Two lumps of round and soft masses, measuring 3.5×4.2×2.2 cm.

brosia was directly closed. The outer wall of the non-coronary sinus of Valsalva was reinforced with a bovine pericardial patch after the remnant mass was completely removed. Surgery was completed uneventfully. The pathologic diagnosis of the mass was confirmed as an organizing thrombus by microscopic examination. Histologically, the mass consisted of two lumps of round and soft masses, measuring 3.5×4.2×2.2 cm. The cutting surface of the mass shows a cystic appearance with a multifocal lobulating solid portion (Fig. 3). Mechanical ventilation was applied for one day postoperatively. The patient was transferred to a general ward from an intensive care unit three days after operation. Postoperative TTE and cardiac CT revealed successful removal of a previously noted cardiac mass with a well-functioning aortic and mitral valve. The patient was discharged 11 days after surgery without complications.

## DISCUSSION

In general, left ventricular thrombus formation is extremely rare in the absence of regional wall motion abnormalities or diffuse left ventricular dysfunction. However, several cases of left ventricular thrombus formation have been reported in association with other conditions such as myeloproliferative disorders and eosinophilic endocarditis [1,2]. In addition, there have been a few reports of thrombus formation in the left ventricular outflow tract even though the left ventricular out-

flow tract is a region of high-velocity blood flow. The etiologies in these reports include chest trauma, postseptal myectomy, and heart transplantation [3-5]. However, our patient had no such medical history. In the reported cases, left ventricular thrombus was found at the apex [1,2]. In cases of thrombus formation in the left ventricular outflow tract, a common site was the interventricular septum [3-5], but in our case, the organized thrombus was within a pseudoaneurysm that was located at the mitral-aortic intervalvular fibrosa, known as the 'mitral-aortic curtain.'

The mitral-aortic intervalvular fibrosa is a thin area of fibrous membrane between the aortic and mitral valves where the base of the anterior mitral leaflet becomes continuous with the left half of the noncoronary cusp and the adjacent third of the left coronary cusp of the aortic valve. The anterior edge of the mitral-aortic intervalvular fibrosa is contiguous with the left fibrous trigone, and the posterior edge is contiguous with the right fibrous trigone. Its roof is formed by the pericardium, and inferiorly, it is related to the left ventricular outflow tract and participates in the formation of the posterior wall of the left ventricular outflow tract. The relatively avascular nature of this region is responsible for susceptibility to trauma or infection, which may result in pseudoaneurysms or abscesses [6,7]. Disruption in this region due to any one of blunt chest trauma, surgical trauma, or infection can lead to the formation of a sac. A pseudoaneurysm of mitral-aortic fibrosa develops when this sac communicates inferiorly with the left ventricular outflow tract. A pseudoaneurysm can also communicate with the left atrium, aortic root, or pericardial cavity. Incidence of a pseudoaneurysm of this region is rare, but can often occur in association with endocarditis or aortic valve surgery [6,7].

If echocardiographic features of a lesion located at the mitral-aortic intervalvular fibrosa demonstrate marked pulsatility with systolic expansion and diastolic collapse in communication with the left ventricular outflow tract, these are important in diagnosing a pseudoaneurysm in this region. These distinguish it from abscesses or vegetation, which do not show these characteristics. Because color Doppler flow imaging demonstrates the blood flow into a pseudoaneurysm during systole and the blood flow back into the left ventricular outflow tract during diastole, the utilization of color Doppler

flow imaging is crucial [6,7]. Electrocardiographic gated multi-dimensional CD can enable the diagnosis and dynamic evaluation of a pseudoaneurysm of the mitral-aortic intervalvular fibrosa because this tool demonstrates volume expansion during systole followed by collapse during diastole, and the lumen of a pseudoaneurysm filled with contrast material from the left ventricle outflow tract. Cardiac MRI can also identify and give more detailed information about a pseudoaneurysm of the mitral-aortic intervalvular fibrosa with better resolution [8].

A pseudoaneurysm of the mitral-aortic intervalvular fibrosa that occurred due to either trauma or infection can undergo chronic progression of organization. In such cases, trans-thoracic or transesophageal echocardiography and color Doppler flow imaging have demonstrated characteristic features of a pseudoaneurysm, and cardiac CT and MRI have revealed a pseudoaneurysm filled with contrast material from the left ventricle outflow tract [6-8]. However, in our case, preoperative TTE showed no definite findings. Preoperative color Doppler flow imaging did not demonstrate definite blood flow between the mass and the left ventricular outflow tract. Cardiac MRI did not show definite findings. Cardiac CT only presented a pseudoaneurysm filled with contrast material.

Enlargement of the pseudoaneurysm may compress the left coronary artery and result in angina-like symptoms. Communication of a pseudoaneurysm with the left ventricle or ascending aorta may result in heart failure. A pseudoaneurysm of the mitral-aortic intervalvular fibrosa can very rarely rupture towards the anterior chest wall and produce a fistula. Embolization of thrombotic material in a pseudoaneurysm of the mitral-aortic intervalvular fibrosa may result in stroke [6-8]. Our patient presented loss of consciousness one month prior to surgery. It was suspicious due to obstruction of the left ventricular outflow tract, and there was risk of embolic stroke. Surgical resection was necessary.

A pseudoaneurysm of the mitral-aortic intervalvular fibrosa without infection or history of cardiac surgery is very rare. An organizing thrombus within a pseudoaneurysm of the mitral-aortic intervalvular fibrosa has not been reported previously. Detailed anatomical knowledge and a thorough pre-

operative evaluation of a mass-like lesion of the mitral-aortic intervalvular fibrosa and its surrounding area are necessary before decision making.

## CONFLICT OF INTEREST

No potential conflict of interest relevant to this article was reported.

## SUPPLEMENTARY MATERIALS

Supplementary materials can be found via <http://dx.doi.org/10.5090/kjtc.2016.49.1.42>. Video 1. (A) Parasternal long axis view. (B) Color Doppler flow imaging.

## REFERENCES

1. DeGroat TS, Parameswaran R, Popper PM, Kotler MN. *Left ventricular thrombi in association with normal left ventricular wall motion in patients with malignancy*. Am J Cardiol 1985;56:827-8.
2. Davies J, Spry CJ, Sapsford R, et al. *Cardiovascular features of 11 patients with eosinophilic endomyocardial disease*. Q J Med 1983;52:23-39.
3. Dumesnil JG, Lentini S, Desaulniers D. *Vanishing post-traumatic left ventricular outflow tract thrombi*. Ann Thorac Surg 1994;58:276.
4. Seshadri N, Novaro GM, Lever H, et al. *Myectomy site thrombus formation: an underappreciated source of thromboembolism after septal myectomy*. J Thorac Cardiovasc Surg 2002;123:562-4.
5. Clark VL, Levine TB. *Thrombus causing fatal left ventricular outflow tract obstruction in a heart transplant patient*. Cathet Cardiovasc Diagn 1992;25:132-4.
6. Xie M, Li Y, Cheng TO, et al. *Pseudoaneurysm of the mitral-aortic intervalvular fibrosa*. Int J Cardiol 2013;166:2-7.
7. Sudhakar S, Sewani A, Agrawal M, Uretsky BF. *Pseudoaneurysm of the mitral-aortic intervalvular fibrosa (MAIVF): a comprehensive review*. J Am Soc Echocardiogr 2010;23:1009-18.
8. Ghersin E, Litmanovich D, Agmon Y, Milo S. *Pseudoaneurysm of the mitral-aortic intervalvular fibrosa following aortic valve replacement: diagnosis and dynamic evaluation with multidetector CT and transesophageal echocardiography*. Interact Cardiovasc Thorac Surg 2005;4:502-4.