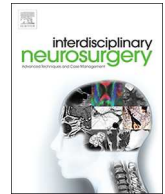




Since January 2020 Elsevier has created a COVID-19 resource centre with free information in English and Mandarin on the novel coronavirus COVID-19. The COVID-19 resource centre is hosted on Elsevier Connect, the company's public news and information website.

Elsevier hereby grants permission to make all its COVID-19-related research that is available on the COVID-19 resource centre - including this research content - immediately available in PubMed Central and other publicly funded repositories, such as the WHO COVID database with rights for unrestricted research re-use and analyses in any form or by any means with acknowledgement of the original source. These permissions are granted for free by Elsevier for as long as the COVID-19 resource centre remains active.



Targeting of renin-angiotensin system in COVID-19 patients affected by stroke: Emerging concerns about detrimental vs. benefit effect



ARTICLE INFO

Keywords:

ACE inhibitors
Angiotensin II receptor blockers
COVID-19
Renin-angiotensin system
SARS-CoV-2
Stroke

ABSTRACT

Objective: The present short report summarizes some clinical characteristics of six patients affected by stroke while being on angiotensin-converting enzyme (ACE)2 inhibitors and angiotensin II receptor blockers (ARBs) before and during COVID-19.

Methods: Medical charts and images of six patients affected by stroke while being on ACE-Is and ARBs therapy before and during COVID-19 outbreak in Lombardy region, Italy, were reviewed.

Results: Three patients had a dural sinus thrombosis, whereas the remaining suffered by an arterial ischemia, which was a middle cerebral artery occlusion in one case, and a posterior-inferior cerebellar artery occlusion in the remaining two. All patients showed clinical features typical of SARS-CoV-2 infection and positive chest CT scan, and were treated with ACE-Is as needed. Hypercoagulability panel was negative in any case. A recovery was achieved in all cases, although in a variable manner.

Conclusions: Whether or not and in which manner the pharmacomodulation of the renin-angiotensin system may had affect the clinical course of the reported six COVID-19 patients affected by stroke has to be still clarified. An urgent need of randomized clinical trials aimed to assess the safety profile and neuroprotective properties of ACE-Is and ARBs in COVID-19 patients diagnosed with stroke does exist.

1. Background

Severe Acute Respiratory Syndrome - Coronavirus – 2 (SARS-CoV-2) is the seventh identified betacoronavirus proved to be able to infect humans causing COronaVirus Disease-2019 (COVID-19). Evidence exists about the neurovirulence of SARS-CoV-2, which penetrates into the central nervous system (CNS) via three different ways, namely a hematogenous route, neuronal retrograde dissemination and transcranial route [1,2]. In a study from Wuhan, China, about a third of the patients diagnosed with COVID-19 had clinical signs of CNS involvement of various degree [3].

Concerns have been raised about a potential increase in mortality rate of the infected patients on therapy with angiotensin-converting enzyme inhibitors (ACE-Is) and angiotensin II receptor blockers (ARBs), both modulating ACE-2 expression.

This short report is targeted to briefly summarize some interesting, although empirical, observations on six neurosurgical patients affected by stroke, which were managed in Lombardy region, north of Italy, during the COVID-19 outbreak. The pathophysiological mechanisms at the base of these emerging arguments are also discussed.

2. Case series

The first patient was diagnosed with a spontaneous thrombosis of the right transverse and sigmoid sinuses, and jugular bulb (Fig. 1a). The patient was comatose, had a GCS of 6, and also developed a late spontaneous left fronto-temporo-parietal subdural hematoma. After a left decompressive hemicraniectomy and anticoagulant therapy, the patient progressively recovered up to be discharged without deficits

46 days later.

The second patient, admitted comatose, had a spontaneous thrombosis of the M2 segment of the right middle cerebral artery (Fig. 1b). The patient was outside the window for mechanical thrombectomy or thrombolysis. His best neurological exam showed bilateral mydriatic pupils with a sluggish reaction to light. Flexion/extension movements and brainstem reflexes were present. He underwent a fronto-temporo-parietal decompressive craniectomy and, after 27 days, his exam improved to a left facio-brachio-crural hemiplegia and was able to be discharged to an acute rehabilitation unit.

The third patient suffered by a left posterior inferior cerebellar artery (PICA) stroke (Fig. 1c) which occurred spontaneously causing coma and non-reactive pupils. Cough reflex was present at admission and the patient underwent a posterior fossa decompressive craniectomy as in our experience young patients with a stunned brainstem tend to recover quite well postoperatively despite the grim neurological exam at presentation. Two weeks later he woke up and progressively became able to swallow and interact but still weak in his extremities, requiring sub-acute rehab. This patient had a heterozygous mutation of methylenetetrahydrofolate reductase (MTHFR).

The fourth and fifth patient were diagnosed with a right and left transverse sinus thrombosis, respectively (Fig. 1d, e). They were paucisymptomatic and came to our attention because of a minor head trauma. MRI was performed because of persistent postural imbalance and dizziness. The clinical course was uneventful and the symptoms disappeared after warfarin anticoagulant therapy.

The sixth patient was admitted comatose (GCS 5). MRI revealed a left cerebellar hemispheric ischemia secondary to a spontaneous and complete PICA occlusion (Fig. 1f). The patient underwent a posterior

<https://doi.org/10.1016/j.inat.2020.100822>

Received 29 June 2020; Accepted 4 July 2020

Available online 10 July 2020

2214-7519/ © 2020 The Author(s). Published by Elsevier B.V. This is an open access article under the CC BY-NC-ND license

(<http://creativecommons.org/licenses/by-nc-nd/4.0/>).

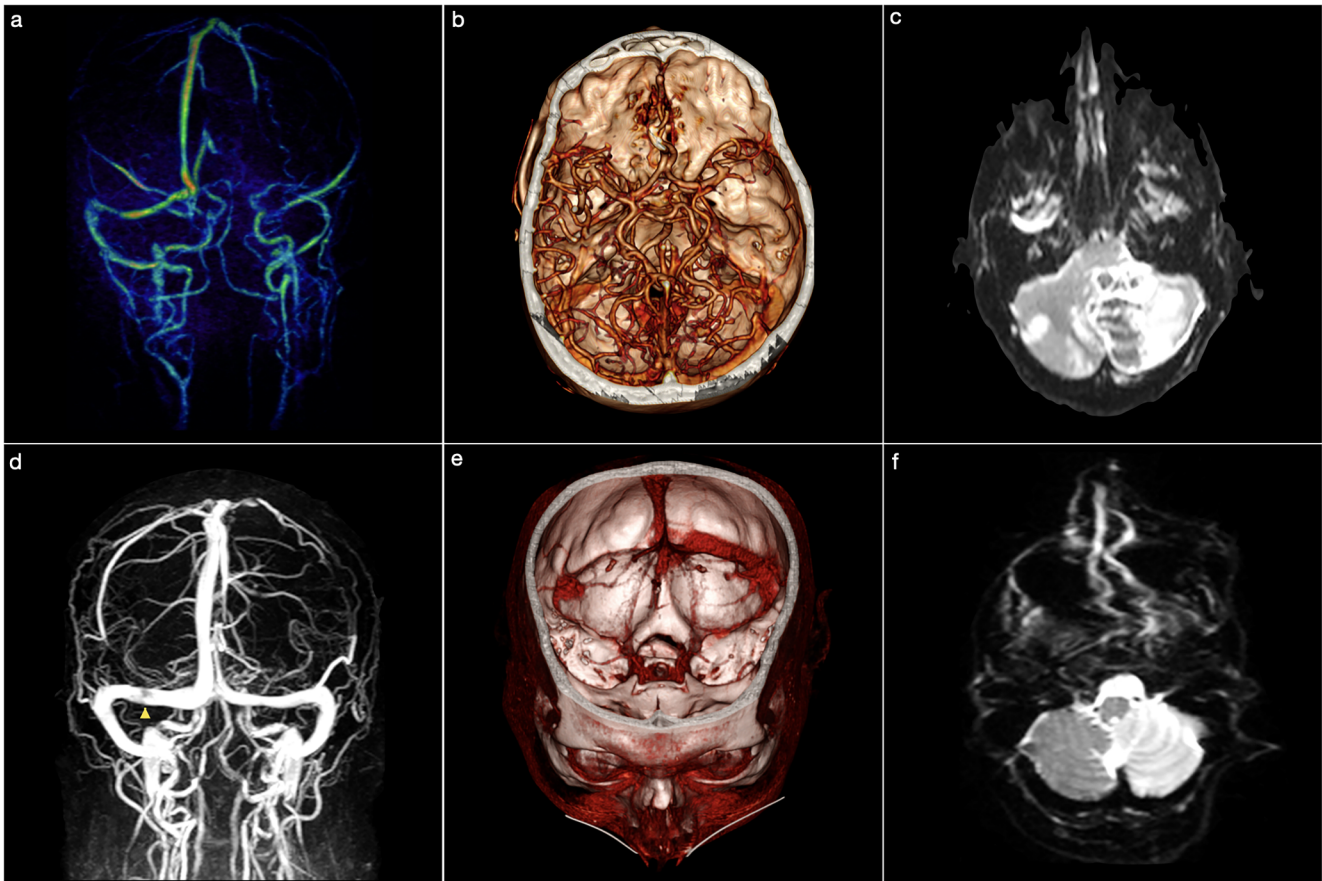


Fig. 1. (a) 3D Time-of-Flight MRI showing a right thrombosis of the transverse and sigmoid sinus, and jugular bulb. (b) 3D CT angiography revealing a right middle cerebral artery occlusion. (c) Axial diffusion-weighted MRI documenting a left cerebellar hemispheric ischemia. (d) 3D Time-of-Flight MRI showing a partial occlusion of the right transverse sinus (yellow arrowhead). (e) 3D CT angiography acquired in venous phase demonstrating a thrombosis of the right transverse sinus. (f) Axial diffusion-weighted MRI showing an ischemia of the right cerebellar hemisphere. (For interpretation of the references to colour in this figure legend, the reader is referred to the web version of this article.)

fossa decompressive craniectomy after which, 42 days later, he progressively recovered the vigilance, becoming able to interact. He was designated for sub-acute neurorehabilitation.

All of them, but one, were on chronic therapy with ACE-Is because of systemic hypertension.

All patients tested negative for the viral nucleic acid on the reverse transcription-PCR (RT-PCR) of the nasopharyngeal swab. Nevertheless, all patients showed clinical features typical of SARS-CoV-2 infection consisting in cough, fever, ground-glass opacities and interlobular septal thickening on CT chest, and laboratory tests consistent with a hypercoagulability state.

Interestingly, the pooled cohort was treated with ramipril as needed in order to manage critical hypertension reactions along their hospital stay or during the perioperative period.

Interstitial pneumonia progressively recovered in 5 cases, despite none of them underwent any therapy, specifically intended as anti-COVID-19 in the light of the negativity of the nasopharyngeal swab. Furthermore, during the hospital stay, they were all treated with enoxaparin, at the prophylactic dose or 40 mg SC daily, or also oral warfarin anticoagulant therapy (target International Normalized Ratio values ranging between 2.0 and 3.0). In all of these patients the angiotensinogen, angiotensin converting enzyme, apolipoprotein E, factor XIII, plasminogen activator inhibitor-1, hemochromatosis gene, and beta-fibrinogen were normal. The search for the mutation of factor V

(Leiden), prothrombin and methylenetetrahydrofolate reductase were also negative.

Table 1 summarizes the main demographic and clinical data of the patients' series here reported (Table 1).

3. Discussion

Despite a very frequent negativity of SARS-CoV-2 polymerase chain reaction (PCR) exam of the cerebrospinal fluid, the neurological findings of the infection entail impairment or loss of smell and taste, Guillain-Barré syndrome, cranial neuropathies, meningitis, encephalitis, impaired consciousness, myopathies, but especially acute cerebrovascular complications, with an incidence ranging between 2 and 6% [2,3]. In the Wuhan series, acute cerebrovascular complications have been reported to have a higher incidence in more severe forms of COVID-19, also characterized by the so-called “cytokine storm”, the reasons for this being however still unknown [3].

SARS-CoV-2 harbours a spike protein that binds the angiotensin-converting enzyme (ACE)-2 receptor expressed on the surface of pulmonary, cardiac, renal, intestinal and endothelial cells. Since 2002, several studies have reported the existence of ACE-2 mRNA also in the glial cells and neurons. Endothelial surface and arterial smooth muscle cells of the cerebral vasculature are additional sites [4–6]. Further proof of the SARS-CoV neurotropism came from the detection of the virus in

Table 1
Demographic and clinical data of the patients' series.

Parameters	Patient 1	Patient 2	Patient 3	Patient 4	Patient 5	Patient 6
Diagnosis	Thrombosis of the transverse and sigmoid sinus, and jugular bulb	MCA occlusion	Hemispheric cerebellar ischemia	Transverse sinus thrombosis	Transverse sinus thrombosis	Hemispheric cerebellar ischemia
Site	Right	Right	Left	Right	Left	Left
Plts ($\times 10^3/\mu\text{L}$)	139	336	246	158	349	288
Prothrombin (%)	111	65	82	107	81	98
INR	0,94	1,26	1,09	0,96	1,11	1,25
PTT-Ratio	0,76	0,61	0,78	0,92	0,87	0,83
aPTT (s)	21,8	17,5	22,2	26,1	24,9	23,5
Fibrinogen (mg/dL)	500	358	694	470	520	437
D-Dimer ($\mu\text{g/L}$)	3218	4561	3106	3467	4213	4432
LDH (mU/mL)	625	694	589	523	612	617
Ferritin (ng/ml)	997	1087	957	967	1012	903
Transferrin (mg/dL)	121	150	113	134	147	1003
Serum Iron (mcg/dL)	35	52	47	64	81	94
Protein C (%)	134	112	84	118	130	98

aPTT: activated Partial Thromboplastin Time; INR: International Normalized Ratio; LDH, Lactate dehydrogenase; MCA: Middle Cerebral Artery; NA: Not Available; Plts: Platelets; PTT: Partial Thromboplastin Time.

the brain of the infected patients, especially in neurons and endothelium [7,8]. Accordingly, during the still ongoing COVID-19 outbreak, several concerns have been raised about the safety of ACE inhibitors (ACE-Is) and angiotensin II receptor blockers (ARBs), both routinely used for the treatment of systemic hypertension, because of their well-known modulatory effects on the ACE-2 expression. ACE-Is and ARBs have been indicated as responsible for a facilitation of the infection spreading during COVID-19, since ACE-2 acts as SARS-CoV-2 receptor. However, contradictory evidences exist about this topic. Chronic use of ACE-Is and ARBs has been reported to increase ACE-2 expression in in-vitro and in-vivo studies [6,9]. By contrast, a down-regulation of the ACE-2 mRNA has been demonstrated in the same group, at least in the kidney and myocardiocytes [10].

Recently, Mehra et al. have exonerated ACE-Is and ARBs from the accuse of being potentially harmful for SARS-CoV-2 infection on the base of the results of an observational multicenter study involving 169 hospitals in Asia, Europe, and North America where they disavowed an increased in-hospital death for COVID-19 patients [11]. While assuming a theoretical role of chronic use of ACE-Is and ARBs in facilitating the CNS spread of SARS-CoV-2, the question is whether the known protective effect of these classes of drugs on the ischemic brain may paradoxically have a therapeutic role in COVID-19 patients affected by stroke. In fact, the protective role of ACE-2 expression after brain ischemic events has been widely proven in the past [9,12,13]. The neuroprotection coming from the ACE-2 expression is mediated by the ACE2/Ang-(1-7)/Mas axis able to balance the detrimental effect of the hyperactivation of the ACE/Ang-II/AT1R system characterizing the stroke [6,14,15].

The management of these particular cases raises some important and still unsolved questions. Should we consider safe or even beneficial the use of ACE-Is and ARBs in COVID-19 patients affected by stroke? Did these drugs really affect the clinical course of these patients? Could have expected a faster recovery in these patients if ACE-Is and ARBs were used as therapy for neuroprotective purposes instead of as needed? Should we consider valid those doses commonly used for the treatment of systemic hypertension also with the aim of neuroprotection?

We think that there is an urgent need to address all of these issues with the implementation of randomized clinical trials aimed at assessing the safety profile and the neuroprotective properties of ACE-Is and ARBs in COVID-19 patients diagnosed with stroke.

Declaration of Competing Interest

The authors declare that they have no known competing financial interests or personal relationships that could have appeared to influence the work reported in this paper.

References

- [1] A.M. Baig, E.C. Sanders, Potential neuroinvasive pathways of SARS-CoV-2: deciphering the spectrum of neurological deficit seen in coronavirus disease 2019 (COVID-19), *J. Med. Virol.* (2020), <https://doi.org/10.1002/jmv.26105> [published Online First: 2020/06/04].
- [2] M. Romoli, I. Jelcic, R. Bernard-Valnet, et al., A systematic review of neurological manifestations of SARS-CoV-2 infection: the devil is hidden in the details, *Eur. J. Neurol.* (2020), <https://doi.org/10.1111/ene.14382> [published Online First: 2020/06/06].
- [3] L. Mao, H. Jin, M. Wang, et al., Neurologic manifestations of hospitalized patients with coronavirus disease 2019 in Wuhan, China, *China JAMA Neurol* (2020), <https://doi.org/10.1001/jamaneuro.2020.1127> [published Online First: 2020/04/11].
- [4] P.E. Gallagher, M.C. Chappell, C.M. Ferrario, et al., Distinct roles for ANG II and ANG-(1-7) in the regulation of angiotensin-converting enzyme 2 in rat astrocytes, *Am. J. Physiol. Cell Physiol.* 290 (2) (2006) C420–C426, <https://doi.org/10.1152/ajpcell.00409.2004> [published Online First: 2005/09/24].
- [5] M.F. Doobay, L.S. Talman, T.D. Obr, et al., Differential expression of neuronal ACE2 in transgenic mice with overexpression of the brain renin-angiotensin system, *Am. J. Physiol. Regul. Integr. Comp. Physiol.* 292 (1) (2007) R373–R381, <https://doi.org/10.1152/ajpregu.00292.2006> [published Online First: 2006/09/02].
- [6] H. Xia, E. Lazartigues, Angiotensin-converting enzyme 2 in the brain: properties and future directions, *J. Neurochem.* 107 (6) (2008) 1482–1494, <https://doi.org/10.1111/j.1471-4159.2008.05723.x> [published Online First: 2008/11/05].
- [7] Y. Ding, L. He, Q. Zhang, et al., Organ distribution of severe acute respiratory syndrome (SARS) associated coronavirus (SARS-CoV) in SARS patients: implications for pathogenesis and virus transmission pathways, *J. Pathol.* 203 (2) (2004) 622–630, <https://doi.org/10.1002/path.1560> [published Online First: 2004/05/14].
- [8] J. Gu, E. Gong, B. Zhang, et al., Multiple organ infection and the pathogenesis of SARS, *J. Exp. Med.* 202 (3) (2005) 415–424, <https://doi.org/10.1084/jem.20050828> [published Online First: 2005/07/27].
- [9] J.Y. Choi, H.K. Lee, J.H. Park, et al., Altered COVID-19 receptor ACE2 expression in a higher risk group for cerebrovascular disease and ischemic stroke, *Biochem. Biophys. Res. Commun.* (2020), <https://doi.org/10.1016/j.bbrc.2020.05.203> [published Online First: 2020/06/10].
- [10] C.M. Ferrario, J. Jessup, M.C. Chappell, et al., Effect of angiotensin-converting enzyme inhibition and angiotensin II receptor blockers on cardiac angiotensin-converting enzyme 2, *Circulation* 111 (20) (2005) 2605–2610, <https://doi.org/10.1161/CIRCULATIONAHA.104.510461> [published Online First: 2005/05/18].
- [11] M.R. Mehra, S.S. Desai, S. Kuy, et al., Cardiovascular disease, drug therapy, and mortality in covid-19, *N. Engl. J. Med.* (2020), <https://doi.org/10.1056/NEJMoa2007621> [published Online First: 2020/05/02].
- [12] J. Lu, T. Jiang, L. Wu, et al., The expression of angiotensin-converting enzyme 2-

angiotensin-(1-7)-Mas receptor axis are upregulated after acute cerebral ischemic stroke in rats, *Neuropeptides* 47 (5) (2013) 289–295, <https://doi.org/10.1016/j.npep.2013.09.002> [published Online First: 2013/10/05].

- [13] C. Kaliszewski, L.A. Fernandez, J.D. Wicke, Differences in mortality rate between abrupt and progressive carotid ligation in the gerbil: role of endogenous angiotensin II, *J. Cereb. Blood Flow Metab.* 8 (2) (1988) 149–154, <https://doi.org/10.1038/jcbfm.1988.43> [published Online First: 1988/04/01].
- [14] M.M. Gironacci, M.S. Valera, I. Yujnovsky, et al., Angiotensin-(1–7) inhibitory mechanism of norepinephrine release in hypertensive rats, *Hypertension* 44 (5) (2004) 783–787, <https://doi.org/10.1161/01.HYP.0000143850.73831.9d> [published Online First: 2004/09/24].
- [15] L.K. Becker, R.A. Santos, M.J. Campagnole-Santos, Cardiovascular effects of angiotensin II and angiotensin-(1–7) at the RVLM of trained normotensive rats, *Brain Res.* 1040 (1–2) (2005) 121–128, <https://doi.org/10.1016/j.brainres.2005.01.085> [published Online First: 2005/04/05].

Sabino Luzzi^{a,b,*}, Alice Giotta Lucifero^a, Stefano Marasco^a,
Mattia Del Maestro^{b,c}, Giuseppe Bellantoni^b, Cristian Gragnaniello^d
^a *Neurosurgery Unit, Department of Clinical-Surgical, Diagnostic and
Pediatric Sciences, University of Pavia, Polo Didattico “Cesare Brusotti”,
Viale Brambilla, 74 - 27100 Pavia, Italy*

^b *Neurosurgery Unit, Department of Surgical Sciences, Fondazione IRCCS
Policlinico San Matteo, Viale C. Golgi, 19 - 27100 Pavia, Italy*

^c *School in Experimental Medicine, Department of Clinical-Surgical,
Diagnostic and Pediatric Sciences, University of Pavia, Polo Didattico
“Cesare Brusotti”, Viale Brambilla, 74 - 27100 Pavia, Italy*

^d *Department of Neurological Surgery, University of Illinois at Chicago,
1200 W Harrison St, Chicago, IL 60607, USA
E-mail address: sabino.luzzi@unipv.it (S. Luzzi).*

* Corresponding author at: Neurosurgery Unit, Department of Clinical-Surgical, Diagnostic and Pediatric Sciences, University of Pavia, Polo Didattico “Cesare Brusotti”, Viale Brambilla, 74 - 27100 Pavia, Italy.