




CLINICAL REPORT

Novel *ELN* mutation in a Japanese family with a severe form of supravalvular aortic stenosis

Kaori Sugiyama^{1,2} | Hitoshi Horigome³  | Lisheng Lin⁴ | Takashi Murakami³ |
Junko Shiono⁴ | Yoshito Yamashiro¹  | Hiroyuki Matsuura⁵ | Hitoshi Yoda⁶ |
Hiromi Yanagisawa^{1,7} 

¹Life Science Center for Survival Dynamics, Tsukuba Advanced Research Alliance (TARA), University of Tsukuba, Tsukuba, Japan

²Ph.D. Program in Human Biology, School of Integrative and Global Majors, University of Tsukuba, Tsukuba, Japan

³Department of Child Health, Faculty of Medicine, University of Tsukuba, Tsukuba, Japan

⁴Department of Pediatric Cardiology, Ibaraki Children's Hospital, Mito, Japan

⁵Department of Pediatrics, Toho University School of Medicine, Tokyo, Japan

⁶Department of Neonatology, Toho University School of Medicine, Tokyo, Japan

⁷Division of Biomedical Science, Faculty of Medicine, University of Tsukuba, Tsukuba, Japan

Correspondence

Hitoshi Horigome, Department of Child Health, Faculty of Medicine, University of Tsukuba, Tsukuba, 305-8575, Japan.
Email: hhorigom@md.tsukuba.ac.jp

Hiromi Yanagisawa, Life Science Center for Survival Dynamics, Tsukuba Advanced Research Alliance (TARA), University of Tsukuba, Tsukuba 305-8577, Japan.
Email: hkyanagisawa@tara.tsukuba.ac.jp

Funding information

MEXT KAKENHI and Cooperative Research Project Program of Life Science Center for Survival Dynamics, Tsukuba Advanced Research Alliance, University of Tsukuba.

Abstract

Background: Supravalvular aortic stenosis (SVAS) is one of the congenital cardiovascular diseases characterized by stenosis of the aorta. The stenotic lesions occur anywhere above the aortic valve in the aortic tree as well as pulmonary arteries and eventually leads to circulatory failure. The disease gene has been identified on the elastin gene (*ELN*) and two types of SVAS have been categorized; a familial type and an isolated type with the de novo mutation.

Methods: Fluorescent In situ hybridization (FISH) analysis and gene sequencing were performed in a two-generation family in which severe form of SVAS was diagnosed.

Results: None of the patients tested showed microdeletion of *ELN*, *LIMK1*, and *D7S613*. A novel nonsense mutation of *ELN* (c.160G>T (p.(Gly54*)), RNA not analyzed) was found in exon 3 in three members; two of them died suddenly due to rapid progression of SVAS with possible arrhythmia in early infancy. A point mutation in the 5' untranslated region, which was previously suggested to be associated with SVAS, did not co-segregate with the SVAS phenotype and found to be SNPs.

Conclusion: Our report shows a broad spectrum of clinical features in family members sharing the identical mutations, suggesting a potential contribution of modifier gene(s) or interactions with environmental factors.

KEYWORDS

ELN, modifier gene, pulmonary artery stenosis, sudden death, supravalvular aortic stenosis

1 | INTRODUCTION

Supravalvular aortic stenosis ([SVAS]; OMIM 185500) is a congenital narrowing of the lumen of ascending aorta immediately above the aortic valve. SVAS related to elastin (*ELN*; OMIM 130160) gene mutations frequently affects branch pulmonary arteries (PA) and coronary arteries, whereas descending aorta, cerebral arteries, and renal arteries are usually spared. Narrowed lumens of the aorta and PA provoke increased resistance to systemic and pulmonary blood flow, resulting in hypertrophy of both ventricles. In some cases, life-threatening ventricular arrhythmias in association with myocardial ischemia develop due to coronary stenosis or hypertrophy, leading to sudden death. SVAS is a major clinical manifestation of Williams-Beuren syndrome ([WBS], OMIM 194050), which affects 1 in 20,000 people (Metcalf et al., 2000). In WBS, autosomal dominant mutation is located in chromosome 7q11.23, and *ELN*, which is included in this region, is known to be responsible for SVAS (Curran et al., 1993). SVAS may also be present in a non-syndromic condition, in which frameshift or nonsense mutations are proposed to cause functional haploinsufficiency (Micale et al., 2010).

1.1 | Patients' report

The female proband (III-1) was born at 39w2d of gestation after an uncomplicated pregnancy with birth weight of

3,334 g (Figure 1). When she was delivered, her parents were 29 years old. Heart murmur was pointed out at 6 days of age, and echocardiography revealed SVAS and pulmonary artery stenosis (Figure 2a). She did not have appearance of WBS. At 13 days of age, echocardiography revealed that diameters of the annulus and supravalvular region of the aorta were 6.2 and 3.7 mm, respectively, and that pressure gradient (PG) of the left ventricular outflow tract (LVOT) was estimated at 23 mmHg by continuous wave Doppler echocardiography. The whole PA appeared hypoplastic and PG of the right ventricular outflow tract (RVOT) was estimated at 64 mmHg. Electrocardiogram (ECG) revealed single premature ventricular contractions and slight ST-T changes, followed by non-sustained monomorphic ventricular tachycardia (VT) (ventricular rate, 200 bpm). VT was sensitive to adenosine triphosphate (ATP) and suppressed by beta-blockers. Contrast cardiac computed tomography (CT) conducted at age 32 days showed SVAS and generalized hypoplastic PA (Figure 2b).

The other arterial lesions, including coarctation of the aorta or coronary arterial stenosis, were not observed. Although the patient showed normal growth without apparent symptoms of heart failure or systemic hypertension (blood pressure was 70/33 mmHg) during the first 2 months of life, the LVOT- and RVOT-PG were gradually increased to 58 and 90 mmHg, respectively, LV hypertrophy progressed, and moderate mitral regurgitation appeared. This patient died suddenly at home at age 74 days. Her height was

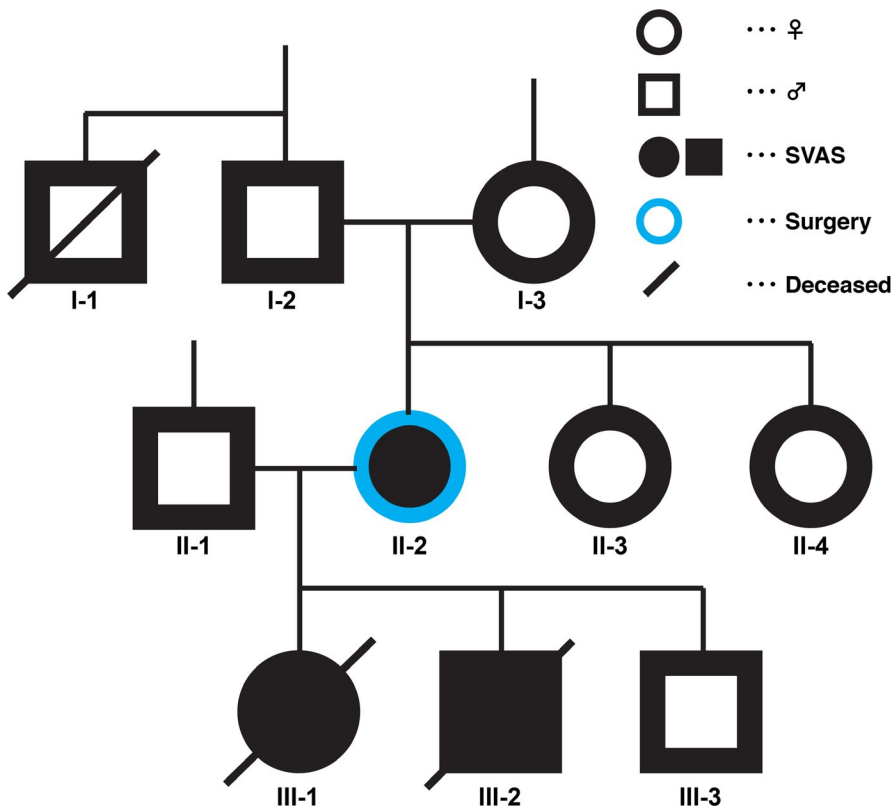


FIGURE 1 Pedigree of the family, showing autosomal dominant inheritance. Circles indicate females and squares indicate males. White indicates healthy individuals, black indicates Supravalvular aortic stenosis (SVAS), and diagonal bar shows deceased. II-2 underwent patch aortoplasty for SVAS at 15 years of age. III-1 and III-2 had sudden death at 2 months old. III-3 did not have a clinical diagnosis of SVAS

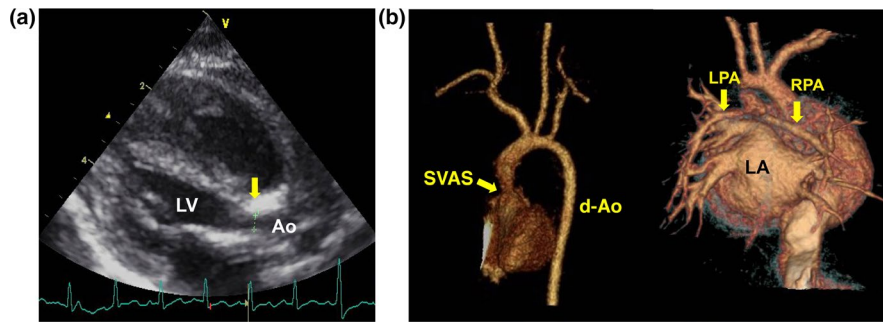


FIGURE 2 Cardiovascular images of the proband (III-1). (a) Left ventricular long-axis view of echocardiogram, showing supravulvar aortic stenosis (arrow). Diameters of aortic annulus and supravulvar portion are 6.2 and 3.7 mm, respectively. (b) Multidetector computer tomographic reconstruction image showing supravulvar aortic stenosis (arrow, Supravulvar aortic stenosis) and slight hypoplasia of whole aorta (left panel). The posterior view demonstrates markedly hypoplastic pulmonary arteries (right panel). Ao, aorta; d-Ao, descending aorta; LA, left atrium; LPA, left pulmonary artery; LV, left ventricle; RPA, right pulmonary artery

55.3 cm and body weight was 4,900 g at the last follow-up prior to death.

Medical history revealed that mother of the proband (II-2) underwent patch aortoplasty for SVAS when she was 15 years old. The hypoplastic pulmonary artery was not reported on her surgery record, and clinical course after the surgery was uneventful. Furthermore, there was the other family member who died young (at age 16, I-1) although details of his clinical course, including the cause of death, were not known.

The mother of proband (II-2) became pregnant after the proband's death. The fetus was screened regularly for possible inheritance of SVAS by fetal echocardiography. No cardiovascular abnormalities were found except that LVOT blood flow was slightly accelerated (2.0 m/s) without an apparent narrowing of the aorta during the 3rd trimester. This baby (III-2) was born at 38w5d of gestation with birth weight of 2,914 g after an uncomplicated pregnancy. At this time, the parents were 31 years old. Auscultation of the chest revealed systolic murmur, but he showed normal growth without signs of heart failure. Systemic hypertension was not noted (blood pressure was 53/34 mmHg). On echocardiography at 38 days of age, diameters of the annulus and supravulvar region of the aorta were 6.5 and 4.5 mm, respectively, and PG of LVOT was estimated at 67 mmHg. Pulmonary arteries were slightly hypoplastic and PG of RVOT was estimated at 43 mmHg. LVOT-PG gradually progressed. Although ECG did not show ST depression, the left ventricle (LV) appeared slightly hypertrophic on echocardiogram at one month of age. Patch aortoplasty for SVAS was considered as a management option, but this baby died suddenly at home at 89 days of age. The baby was 53.5 cm with 4,886 g at the last follow-up prior to death.

The third baby (III-3) was born at 40 weeks of gestation with birth weight of 3,147 g. Echocardiography and contrast cardiac CT confirmed the diagnosis of vascular ring formed by the right aortic arch, and aberrant left subclavian fused with the left common carotid artery, with the Kommerell diverticulum, which had been suspected prenatally by fetal echocardiography.

Since this male infant did not present with dyspnea or esophageal obstruction due to the vascular ring, surgical repair was not indicated. Intracardiac structure was normal, and neither SVAS nor pulmonary arterial stenosis was observed although mild aortic regurgitation was detected. Extracardiac malformations included left cheilognathopalatoschisis, and left accessory auricle. At the last follow-up of 8 months of age, he was 67.6 cm height with 7,660 g weight and growing well.

2 | MATERIALS AND METHODS

2.1 | Ethical compliance

All the family members were Japanese. A written informed consent was obtained. The study protocol was approved by the research ethics committee of Ibaraki Children's Hospital (29A-2).

2.2 | Fluorescent in situ hybridization

Fluorescent In situ hybridization (FISH) analysis using the probe in situ hybridization (ish) 7q11.23 was performed to detect microdeletion of *ELN*, *LIMK1* (OMIM 601329), and D7S613, which has been established for diagnosis of Williams syndrome (Elcioglu, Mackie-Ogilvie, Daker, & Berry, 1998).

2.3 | Gene sequencing

Genomic DNA was extracted from the blood of probands in the respective families (II-2, III-1, III-2, and III-3) and a healthy control according to manufacturer's instructions (QIAGEN). *ELN* exons were amplified by PCR and the PCR product was cleaned up by ExoSAP-IT[®] (Thermo Fisher Scientific) to remove unincorporated dNTPs and primers. The products were subjected to Sanger sequencing with Big Dye[™] Terminator v3.1 Cycle Sequencing Kit (Thermo Fisher Scientific). All 34 exons of *ELN* (NM_000501.2) were examined by 3130xl Genetic Analyzer (Thermo Fisher Scientific). SnapGene Viewer

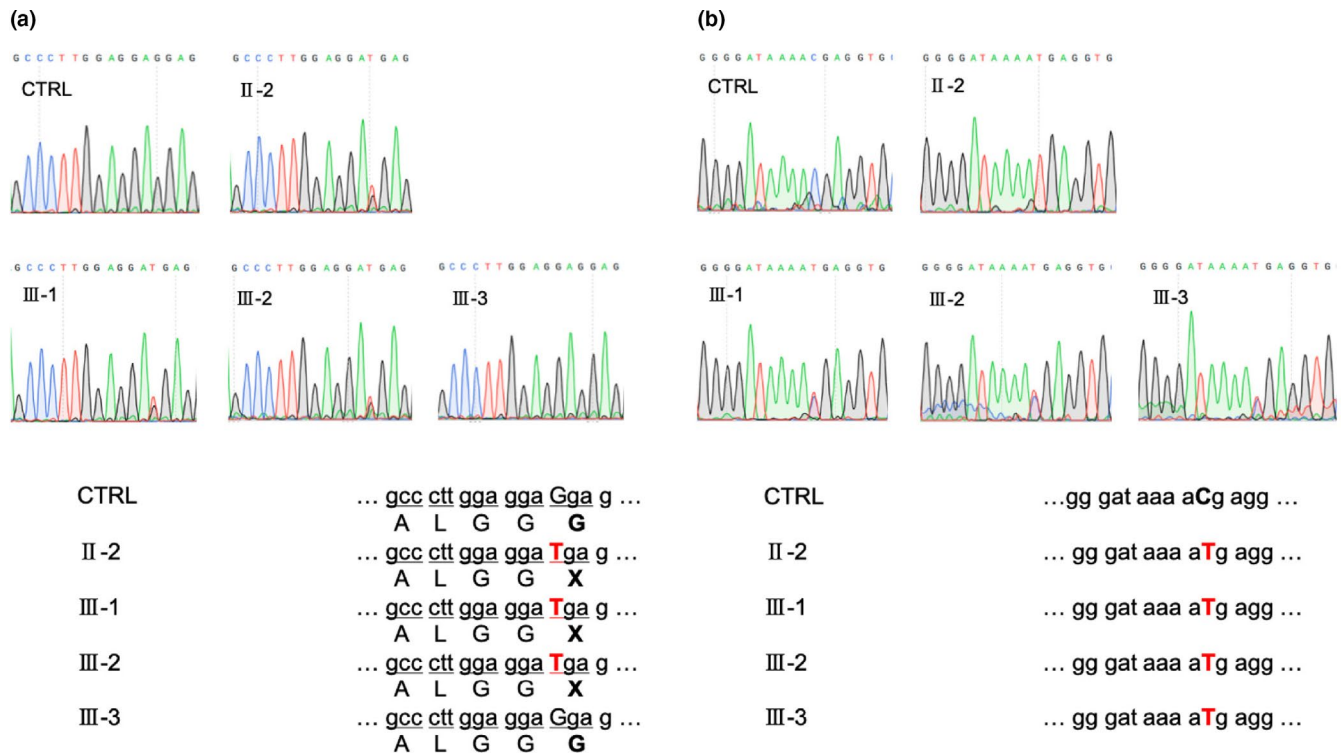


FIGURE 3 (a) DNA sequencing identified mutations in II-2, III-1, and III-2 in comparison to CTRL and III-3. The identified point mutation in exon 3 of *ELN*, which generated a stop codon (c.160G>T (p.(Gly54*)), NM_000501.2). (b) The identified SNPs in 5'-UTR of *ELN* in exon 1 (c.-38C>T). II-2 has homozygous SNPs, while III-1, III-2, and III-3 have heterozygous SNPs

software (Ver.4.2.11) was used to analyze the results and human reference gene (GRCh38/hg38) was obtained from the UCSC Genome Browser. Primer sequences can be provided upon request. The variant was submitted to the Locus Specific Database (variant ID 0000595122).

3 | RESULTS

None of the patients tested showed microdeletion of *ELN*, *LIMK1*, and *D7S613*.

A novel heterozygous nonsense mutation (c.160G>T (p.(Gly54*)), RNA not analyzed) was identified at *ELN* exon 3: chr7:74,036,581 (GRCh38/hg38) among II-2, III-1, and III-2, but not in III-3 (Figures 1 and 3a). This mutation generated a stop codon and suggested a disease-causing mutation for SVAS. A point mutation c.-38C>T in 5' UTR in *ELN* exon1 at chr7:74,028,150 (GRCh38/hg38) was detected in II-2, III-1, III-2, and III-3, irrespective of SVAS phenotype. II-2 had a homozygous mutation while III-1, III-2, and III-3 had heterozygous mutations (Figures 1 and, 3b).

4 | DISCUSSION

To date, 66 types of *ELN* mutations have been reported in familial or sporadic SVAS, which includes point mutations

or microdeletions (Hayano et al., 2019). The family with SVAS presented in this report demonstrates that the affected arteries, severities, and clinical course can be variable among members with the same *ELN* mutation. Although the mother of the proband (II-2) had no life-threatening event until 15 years of age when she underwent patch aortoplasty for SVAS and gave birth to 3 children, the proband (III-1) and her younger brother (III-2) died suddenly in early infancy. Myocardial ischemia caused by coronary artery stenosis due to elastin arteriopathy has been implicated in sudden death in SVAS (Vaideeswar & Regi, 2015). However, no apparent narrowing of the coronary arteries was noted on echocardiography and/or contrast cardiac CT in any of the infants. VT could have been associated with the fatal outcome as VT had actually been demonstrated in the proband.

It is worth noting that the *ELN* mutation identified in this family was associated with a serious clinical course, including rapidly progressive narrowing of supralvalvular portion of the aorta, critically hypoplastic PA, and sudden death in early infancy. In Case III-2, SVAS was suspected as early as in fetal life, supported by fetal Doppler echocardiographic finding of accelerated LVOT flow velocity. In Case III-2, narrowing of the supralvalvular region of the aorta was already observed immediately after birth, which rapidly progressed during the next few months. These findings indicate

that significant narrowing of aortic lumen may develop in fetal or neonatal life, therefore fetal echocardiography might be useful for screening of transmission of the mutated gene in SVAS.

In severe form of SVAS, which is indicated by increased or rapidly progressive PG through outflow tract, patch aortoplasty might be considered. However, it should be recognized that these patients are very sensitive to hypotension and bradycardia induced by anesthesia even for diagnostic imaging. In our two fatal cases, hypoplastic PA could have been a risk factor even with patch aortoplasty for supra aortic lesions. The procedure could have resulted in shift of the interventricular septum and oppression against the LV because of persistent hypertension of the right ventricle. In the present family, the third baby had neither SVAS nor stenosis of the other arteries, including PA. It was interesting that he had complicated aortic arch anomalies, vascular ring, as well as external anomalies. The reason for the development of these rare anomalies and relation to SVAS is unclear. To date, no cases have been reported, in which SVAS and vascular ring develop within the same pedigree.

Genetically, the mutation c.160G>T (p.(Gly54*)) in exon 3 of *ELN* introduced a stop codon in II-2, III-1, and III-2. This mutation is a novel mutation with highly pathogenic truncation. Mechanistically the mutation is anticipated to lead to nonsense-mediated decay and haploinsufficiency in the SVAS proband. Molecular basis of SVAS is still unknown, however, it has been reported that activation of integrin $\beta 3$ caused abnormal accumulation of smooth muscle cells and vascular stenosis (Misra et al., 2016). The c.-38C>T mutation in *ELN* has been previously reported in SVAS with a combination of another mutation; however, its pathological significance was unclear (Metcalf et al., 2000). The c.-38C>T mutation did not segregate with the SVAS phenotype in our case and it was in the list of single nucleotide polymorphisms (SNPs, rs41410045). We concluded that it was not pathogenic. It is of note that even with the identical mutations in *ELN*, II-2 recovered from SVAS after the surgery while III-1 and III-2 resulted in sudden death. One possibility is that homozygous SNPs potentially serve as a protective allele.

ACKNOWLEDGMENTS

This work was partly supported by MEXT KAKENHI (Grant Number JP 17H04289) and the Cooperative Research Project Program of Life Science Center for Survival Dynamics, Tsukuba Advanced Research Alliance (TARA Center), University of Tsukuba.

CONFLICT OF INTEREST

None declared.

ORCID

Hitoshi Horigome  <https://orcid.org/0000-0002-6090-7531>

Yoshito Yamashiro  <https://orcid.org/0000-0002-3556-9585>

Hiromi Yanagisawa  <https://orcid.org/0000-0002-7576-9186>

REFERENCES

- Curran, M. E., Atkinson, D. L., Ewart, A. K., Morris, C. A., Leppert, M. F., & Keating, M. T. (1993). The elastin gene is disrupted by a translocation associated with supravalvular aortic stenosis. *Cell*, 73(1), 159–168. [https://doi.org/10.1016/0092-8674\(93\)90168-P](https://doi.org/10.1016/0092-8674(93)90168-P)
- Elicioglu, N., Mackie-Ogilvie, C., Daker, M., & Berry, A. C. (1998). FISH analysis in patients with clinical diagnosis of Williams syndrome. *Acta Paediatrica*, 87(1), 48–53. <https://doi.org/10.1080/08035259850157868>
- Hayano, S., Okuno, Y., Tsutsumi, M., Inagaki, H., Fukasawa, Y., Kurahashi, H., ... Kato, T. (2019). Frequent intragenic microdeletions of elastin in familial supravalvular aortic stenosis. *International Journal of Cardiology*, 274, 290–295. <https://doi.org/10.1016/j.ijcard.2018.09.032>
- Metcalf, K., Rucka, A. K., Smoot, L., Hofstadler, G., Tuzler, G., McKeown, P., ... Tassabehji, M. (2000). Elastin: Mutational spectrum in supravalvular aortic stenosis. *European Journal of Human Genetics*, 8(12), 955–963. <https://doi.org/10.1038/sj.ejhg.5200564>
- Micale, L., Turturo, M. G., Fusco, C., Augello, B., Jurado, L. A. P., Izzi, C., ... Merla, G. (2010). Identification and characterization of seven novel mutations of elastin gene in a cohort of patients affected by supravalvular aortic stenosis. *European Journal of Human Genetics*, 18(3), 317–323. <https://doi.org/10.1038/ejhg.2009.181>
- Misra, A., Sheikh, A. Q., Kumar, A., Luo, J., Zhang, J., Hinton, R. B., ... Greif, D. M. (2016). Integrin beta3 inhibition is a therapeutic strategy for supravalvular aortic stenosis. *Journal of Experimental Medicine*, 213(3), 451–463. <https://doi.org/10.1084/jem.20150688>
- Vaideeswar, P., & Regi, P. (2015). Supravalvular aortic stenosis with sudden cardiac death. *Annals of Pediatric Cardiology*, 8(2), 134–136. <https://doi.org/10.4103/0974-2069.157027>

How to cite this article: Sugiyama K, Horigome H, Lin L, et al. Novel *ELN* mutation in a Japanese family with a severe form of supravalvular aortic stenosis. *Mol Genet Genomic Med*. 2019;7:e986. <https://doi.org/10.1002/mgg3.986>