

Enterocutaneous fistula due to mesh fixation in the repair of lateral incisional hernia: a case report

Sarath Chandra Sistla*, Rajesh Reddy, Kadambari Dharanipragada and Sadasivan Jagdish

Address: Department of Surgery, Jawaharlal Institute of Postgraduate Medical Education and Research, Pondicherry, India

Email: Sarath Chandra Sistla* - sarathsisla@hotmail.com; Rajesh Reddy - rajesh_jipmer@rediffmail.com; Kadambari Dharanipragada - d_kadambari@yahoo.com; Sadasivan Jagdish - sadasivan.jagdish@gmail.com

* Corresponding author

Published: 2 December 2008

Received: 11 November 2008

Cases Journal 2008, 1:370 doi:10.1186/1757-1626-1-370

Accepted: 2 December 2008

This article is available from: <http://www.casesjournal.com/content/1/1/370>

© 2008 Sistla et al; licensee BioMed Central Ltd.

This is an Open Access article distributed under the terms of the Creative Commons Attribution License (<http://creativecommons.org/licenses/by/2.0>), which permits unrestricted use, distribution, and reproduction in any medium, provided the original work is properly cited.

Abstract

Enterocutaneous fistula following mesh repair of incisional hernia is usually due to mesh erosion of the underlying viscus and presents late. We describe an early enterocutaneous fistula due to an unusual but a potential mode of bowel injury during mesh fixation. This case is reported to emphasize the need for greater attention to the technique of mesh fixation. We suggest laparoscopic guidance to prevent this serious complication in lateral Incisional hernias with ill defined edges of the defect.

Background

Enterocutaneous fistula is a late complication of mesh repair of incisional hernia and is usually due to erosion of intestines by the mesh. Early development of enterocutaneous fistula is usually due to inadvertent and unrecognized enterotomy during separation of adhesions. We present our experience with an enterocutaneous fistula due to anchoring stitch resulting in bowel injury during mesh fixation in an onlay repair of a lateral Incisional hernia. Ill defined edges of the hernial defect and bowel adherent to the sac were the cause of this complication. A simple technical solution to avoid this serious complication is suggested.

Case history

A 50 year old man developed incisional hernia following right lumbar sympathectomy for peripheral vascular disease. The incisional hernia was repaired by onlay mesh-plasty using a polypropylene mesh (6" × 6") and the mesh

was anchored to the aponeurosis beyond the defect with polypropylene sutures. The hernial sac was not opened as he did not have any symptoms of intestinal obstruction. On the 5th postoperative day, patient developed deep surgical site infection with *E. coli* necessitating removal of mesh on 14th postoperative day. No difficulty was encountered in the removal of the mesh as it was done in the early postoperative period. Subsequently the patient developed a persistent discharging sinus at the medial end of the wound (Figure 1). Fistulogram revealed communication with ileum (Figure 2). On exploration by a lower right paramedian incision, a loop of small bowel was found to be adherent to the sac with a small fistulous opening on the antimesenteric border. The anchoring suture was found to have gone through the bowel at the site of the enterocutaneous fistula. The bowel loop was detached from parietes and repaired following which the patient made an uneventful recovery.

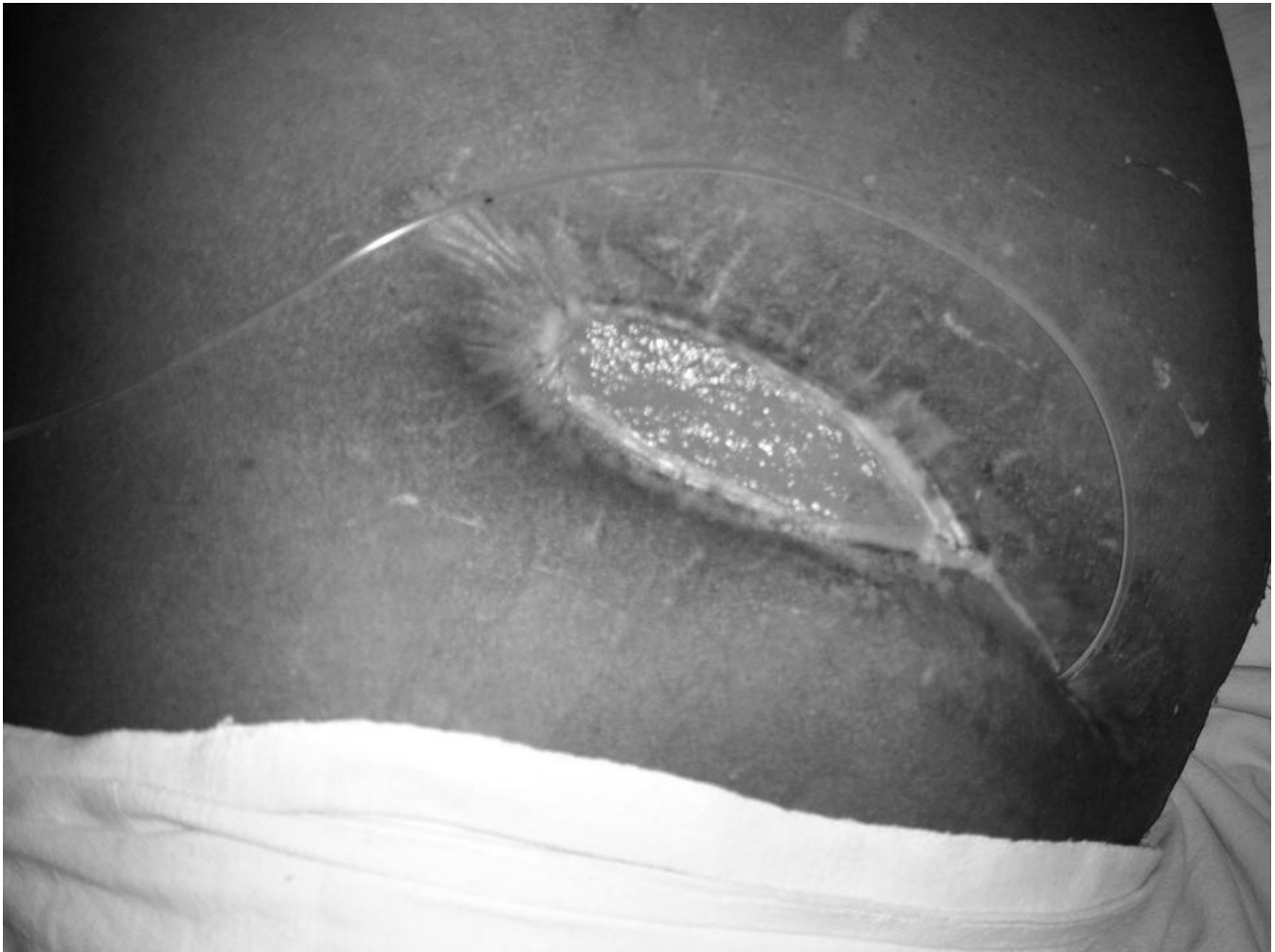

Figure 1
Enterocutaneous fistula at the medial end of the wound.

Discussion

Repair of incisional hernia is done by either suture repair or prosthetic mesh repair. The latter is associated with a lower recurrence rate but a higher incidence of complications. The most serious complication though fortunately rare, is the development of enterocutaneous fistula [1,2].

Enterocutaneous fistula is a late complication of prosthetic mesh repair of incisional hernia and is usually due to chronic erosion of bowel by mesh placed in direct contact with intestinal loops both in open and laparoscopic repairs [3-5].

Unrecognized bowel injury during release of adhesions and thermal or trocar injuries to bowel in laparoscopic repair can also result in fistula. Basoglu emphasized the

need for peritoneal or omentum coverage for prevention of bowel contact with mesh [6].

The incidence of enterocutaneous fistula due to prosthetic mesh is higher in subfascial (5.2%) than in onlay (2.6%) position [7]. In the present case, the patient did not have any symptoms of intestinal obstruction the hernial sac was not opened and it was preserved. Preserving the hernial sac provides a layer of viable autogenous tissue to serve as a barrier between the prosthesis and the intraperitoneal contents, possibly decreasing the risk of adhesions, intestinal obstruction and fistula [8].

The technique described by Khaira et al provides an additional barrier of rectus sheath or aponeurosis between the mesh and the hernial sac and also reduces the risk of

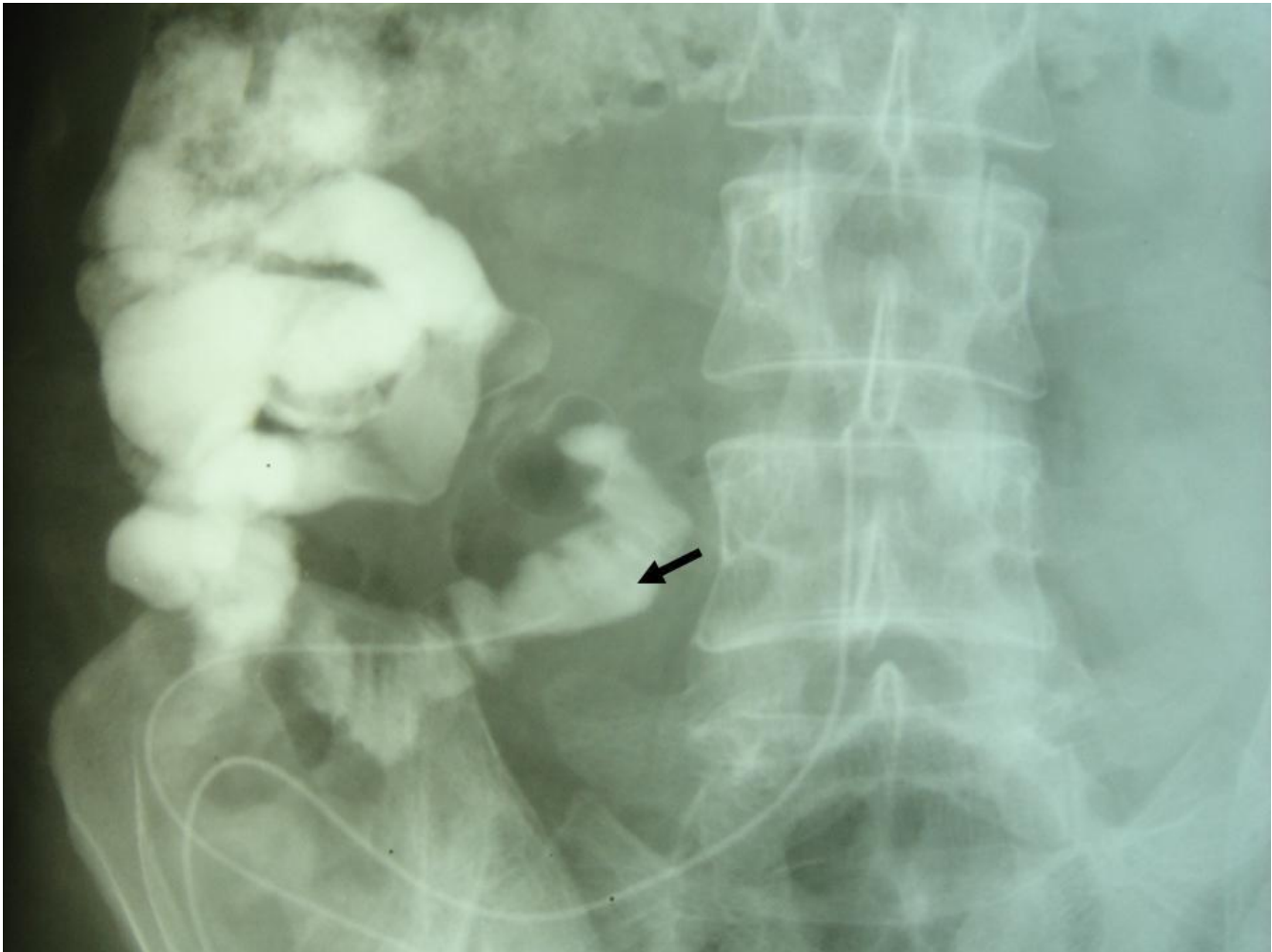


Figure 2
Fistulogram demonstrating communication with the bowel.

bowel injury during mesh fixation [9]. This risk is greater in lateral (transverse or oblique) incisional herniae where the edges of the defect are not as well defined as in mid-line herniae.

In our case the anchoring suture had injured the bowel which was adherent to the sac. The resultant fistula was well localized with no contamination of the peritoneal cavity. The discharge was not feculent as it involved a very small part of the circumference of the bowel. Enterocutaneous fistula in this case was diagnosed by contrast study. A similar case of enterocutaneous fistula was reported by Acar et al [7].

This case is reported to illustrate the potential risk of bowel injury during mesh fixation in onlay mesh repair, especially in lateral incisional herniae with ill defined edges of the hernial defect. The hernial sac need not be

opened routinely in the absence of symptoms of obstruction. Separation of asymptomatic adhesions only increases the risk of bowel injury. We suggest anchoring the mesh under laparoscopic guidance with a 5 mm telescope away from the site of repair. The edges of the defect can be better defined by laparoscopy thereby helping in placing the mesh beyond the defect. Laparoscopic guidance can also prevent accidental injury to bowel during mesh fixation. This also obviates the need for an expensive dual mesh used in laparoscopic repairs.

Consent

Informed consent of the patient was obtained for publication of this case report. The pictures in this manuscript do not reveal the identity of the patient

Competing interests

The authors declare that they have no competing interests.

Authors' contributions

SCS conceived and designed the study. SCS and RR collected the data. SCS drafted the manuscript with the help of KD and JS. SCS, RR, KD and JS were involved in interpretation and analysis of data. All the authors read and approved the manuscript.

References

1. Burger JW, Luijendijk RW, Hop WC, Halm JA, Verdaasdonk EG, Jeekel J: **Long-term Follow-up of a Randomized Controlled Trial of Suture versus Mesh Repair of Incisional Hernia.** *Ann Surg* 2004, **240(4)**:578-585.
2. Leber GE, Garb JL, Alexander AI, Reed WP: **Long-term complications associated with prosthetic repair of incisional hernias.** *Arch Surg* 1998, **133(4)**:378-82.
3. Seelig MH, Kasperk R, Tietze L, Schumpelick V: *Chirurg* 1995, **66(7)**:739-741.
4. Chew DK, Choi LH, Rogers AM: **Enterocutaneous fistula 14 years after prosthetic mesh repair of a ventral incisional hernia: a life-long risk?** *Surgery* 2000, **127(3)**:352-3.
5. Miller k, Junger W: **Ileocutaneous fistula formation following laparoscopic polypropylene mesh hernia repair.** *Surgical endoscopy* 1997, **11(7)**:772-773.
6. Basoglu M, Yildiran MI, Yilmaz I, Balik A, Celebi F, Atamanalp SS, Polat KY, Oren D: **Late Complications of Incisional Hernias Following Prosthetic Mesh Repair.** *Acta chir belg* 2004, **104**:425-428.
7. Acar T, Gömceli I, Taçyildiz R, Sözen S, Karakayali S, Aydın R: **Enterocutaneous fistula due to polypropylene mesh Migration.** *Irish Journal of Medical Science* **171(3)**.
8. Morris-Stiff GJ, Hughes LE: **The outcomes of nonabsorbable Mesh placed within the abdominal cavity: literature review and clinical experience.** *J Am Coll Surg* 1998, **186**:352-67.
9. Khaira Hs, Lall P, Hunter B, Brown JH: **Repair of incisional hernias.** *J R Coll Surg Edinb* 2001, **46**:39-43.

Publish with **BioMed Central** and every scientist can read your work free of charge

"BioMed Central will be the most significant development for disseminating the results of biomedical research in our lifetime."

Sir Paul Nurse, Cancer Research UK

Your research papers will be:

- available free of charge to the entire biomedical community
- peer reviewed and published immediately upon acceptance
- cited in PubMed and archived on PubMed Central
- yours — you keep the copyright

Submit your manuscript here:
http://www.biomedcentral.com/info/publishing_adv.asp

