

## CASE REPORT

# Deep lamellar keratectomy and penetrating scleroplasty using CO<sub>2</sub> laser photoablation and bimodal grafting for the treatment of a limbal melanoma in a dog

Zachary N. Cochrane  | Peter J. Mohoric

Eye Care for Animals, Tampa, Florida

**Correspondence**

Zachary N. Cochrane, Eye Care for Animals, 5406 Hoover Blvd, Tampa, FL 33634.

Email: zcochranedvm@gmail.com

**Abstract**

A novel approach for en bloc resection of a limbal melanoma using a CO<sub>2</sub> laser in a dog. Benefits of this advanced technique include excellent surgical precision, improved hemostasis, and the induction of coagulative necrosis of neoplastic cells.

**KEYWORDS**canine, CO<sub>2</sub> laser, limbal, melanoma

## 1 | INTRODUCTION

Limbal (epibulbar) melanomas are typically benign neoplasms originating from the melanocytes at the corneoscleral junction<sup>1,2</sup> and must be differentiated from uveal melanomas with extrascleral extension. Some debate still exists in the veterinary literature whether the proper nomenclature of “melanocytoma” or “melanoma” is the most appropriate classification of these tumors.<sup>1,3,4</sup> Clinically, canine limbal melanomas are well-circumscribed, slightly raised, heavily pigmented masses most commonly arising from the dorsotemporal limbus that may affect the cornea, conjunctiva, and/or sclera.<sup>5-8</sup>

There appears to be a breed predilection for limbal melanoma development most commonly affecting Golden Retrievers, Labrador Retrievers, and German Shepherds.<sup>7,8</sup> Pedigree analysis suggests limbal melanomas are at least partially heritable in Golden and Labrador Retrievers, while the same study showed no association between tumor formation and coat color, as had been previously postulated.<sup>5</sup> This tumor has a bimodal age distribution affecting younger dogs at a peak age of 2-4 years, then again at 8-11 years of age.<sup>5</sup>

Several management approaches have been described in the case of limbal melanomas with surgical resection generally being regarded as the treatment of choice. Classically, these tumors are slowly progressive, but can be locally invasive, obliterating adjacent structures including infiltration of

the iridocorneal angle.<sup>1,2,5</sup> A number of surgical techniques have been described in the veterinary literature which include lamellar or penetrating sclerokeratoplasty with various replacement grafting procedures, and partial resection modalities combined with cryotherapy, strontium-90β plesiotherapy, and diode laser photocoagulation.<sup>4,6-13</sup> This report describes the surgical treatment of a limbal melanoma in a dog by a deep lamellar keratectomy and penetrating scleroplasty using sharp lamellar dissection and CO<sub>2</sub> laser photoablation, followed by reconstruction of the corneoscleral defect using both a double-layered biosynthetic graft and conjunctival advancement flap.

## 2 | CASE REPORT

### 2.1 | Initial presentation

A three-year-old spayed female Golden Retriever presented to Eye Care for Animals in Tampa, FL for evaluation of a rapidly growing, darkly pigmented, limbal mass affecting the right eye for 1-week duration. General physical examination was unremarkable. Menace response and dazzle reflex were intact in both eyes with normal direct and consensual pupillary light reflexes. There was no resistance to retro-pulsion, and cranial nerve examination was within normal

This is an open access article under the terms of the Creative Commons Attribution-NonCommercial-NoDerivs License, which permits use and distribution in any medium, provided the original work is properly cited, the use is non-commercial and no modifications or adaptations are made.

© 2020 The Authors. *Clinical Case Reports* published by John Wiley & Sons Ltd.

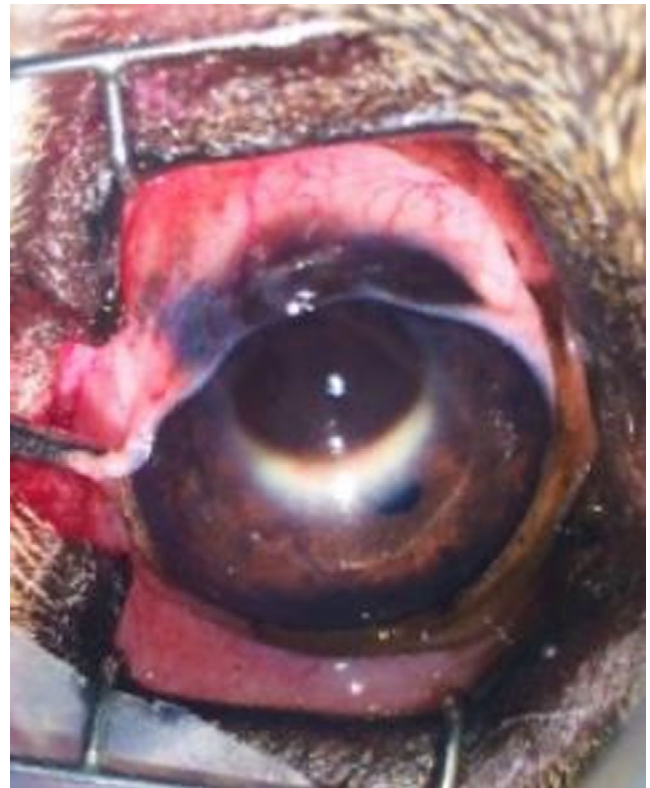limits. Slit lamp biomicroscopy (SL-17 Portable Slit Lamp Biomicroscope, Kowa Co., Ltd) revealed a 4 × 7 mm, pigmented, raised, corneoscleral mass appearing to originate from the dorsal limbus between the 11 o'clock and 1 o'clock positions penetrating the deep corneal stroma and scleral tissues (Figure 1). A dense arc of corneal lipidosis was present at the leading edge of the pigmented mass. The remainder of the slit lamp examination was unremarkable as was the fundic evaluation as determined by indirect ophthalmoscopy.

Direct gonioscopy of the right eye was somewhat obscured by the corneal extension of the mass, but the visible component revealed a darker limbal band with no overt extension into the anterior chamber or pectinate ligaments. Preoperative complete blood cell count and serum biochemistry profile by the referring veterinarian were normal. Based on a high index of suspicion that this mass was a limbal melanoma with generally benign behavior, the owners declined preoperative thoracic radiographs and abdominal ultrasound. Due to the rapidly growing behavior over the course of a week, the owners elected for globe preservation and surgical excision of the limbal mass.

## 2.2 | Surgical procedure

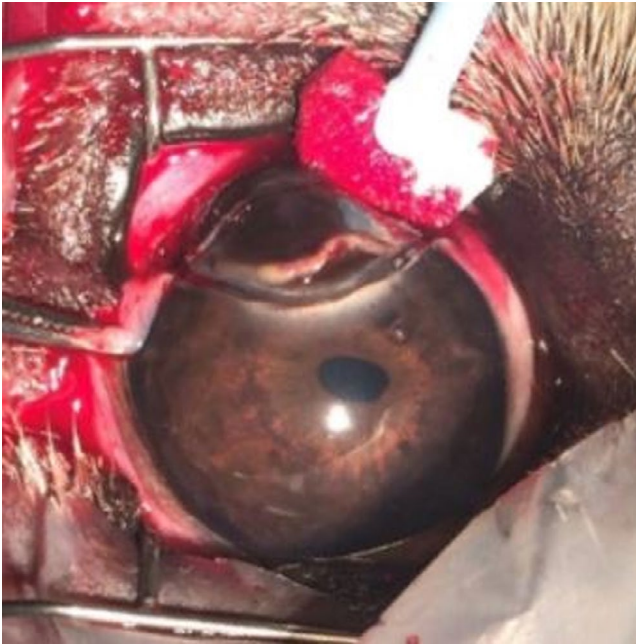
The patient was premedicated with buprenorphine (0.01 mg/kg IV; Par Pharmaceutical). Induction of general anesthesia was achieved with midazolam (0.2 mg/kg IV; Akorn) and alfaxalone (2 mg/kg IV; Jurox) to effect. Following endotracheal tube intubation, general anesthesia was maintained with 1%-2% inhalant isoflurane in oxygen (Isoflo, Abbott Animal Health) and intravenous cefazolin (22 mg/kg IV; Hospira) was administered. Perioperative atracurium besylate (0.1 mg/kg IV; Hospira) was used to maintain central globe position and decrease extraocular forces on the globe.

The patient was positioned in dorsal recumbency, and the right eye was routinely prepared for aseptic surgery. Blepharostats and a lateral canthotomy were used to expose the globe. Prior to making the corneal incision, the conjunctiva above the mass was incised at the limbus and was separated from the episclera below in order to make a fornix-based sliding conjunctival flap. A partial-thickness (~50%) corneal incision was then performed using a 6400 Beaver blade in an arcuate fashion approximately 1-2 mm beyond the edges of the corneal lipid lesions. A Martinez corneal dissector was inserted between the corneal lamellae and advanced to undermine the lesion until there was a gross absence of pigmented corneal stromal tissue (Figure 2). Corneal section scissors were used to complete the keratectomy at its limbal attachment. A CO<sub>2</sub> laser (Aesculight AE-10; LightScalpel) with a 0.4 mm tapered probe on a 2-watt continuous setting was used to sharply dissect and ablate around the scleral portion of the lesion and control hemostasis. Hemostasis was adequately achieved using a combination of the CO<sub>2</sub> laser and an application of 1:10 000 dilution



**FIGURE 1** Perioperative image of limbal melanoma. Note the dense arcuate pattern of corneal lipidosis along the leading edge of the tumor. Lateral canthotomy has been performed. Intraoperative photographs are oriented to portray a normal anatomic standing patient position

of epinephrine (Vet One). The CO<sub>2</sub> laser was also used to gently paint the corneal stroma within the bed of the keratectomy site in the event any microscopic tumor cells were left behind in the cornea. The anterior chamber was entered through the scleral dissection site and was maintained with a viscoelastic substance (CARAvise 1.8% Hyaluronic Acid; CARALife). A cyclodialysis spatula was used to bluntly dissect the iris and pars plicata of the ciliary body from the sclera. The mass was removed en bloc. The CO<sub>2</sub> laser was used to gently ablate the surrounding scleral collagen to cause coagulative necrosis of any remaining neoplastic cells. A four-layered biosynthetic graft using porcine small intestinal submucosa (BioSIS Plus<sup>+</sup> 15 mm Multi-layer Ocular Discs; Vetrix) was placed over the limbal defect (Figure 3). One simple interrupted suture using 7-0 polyglactin 910 (Vicryl; Ethicon) was placed to secure the graft to the sclera. The graft was then trimmed to the appropriate size, and the remaining aspect of the graft was sutured into the sclera and cornea using 7-0 polyglactin 910 in a combined simple interrupted and continuous pattern (Figure 4). For additional tectonic support and to aid in vascularization, the conjunctival flap was advanced over the scleral portion of the BioSIS graft and sutured to the limbus using 9-0 polyglactin 910 (Vicryl; Ethicon). The canthotomy was closed using a figure-8 pattern with one single interrupted suture, and temporary tarsorrhaphy



**FIGURE 2** Intraoperative photograph of corneal lamellar dissection

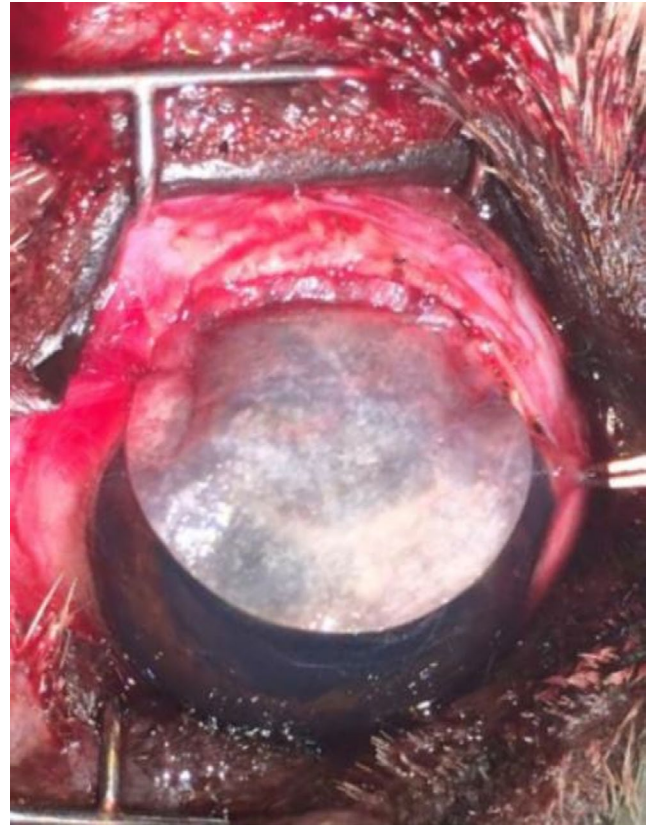
sutures were placed using 5-0 polypropylene (Prolene; Ethicon, Bridgewater, NJ).

### 2.3 | Histopathologic evaluation

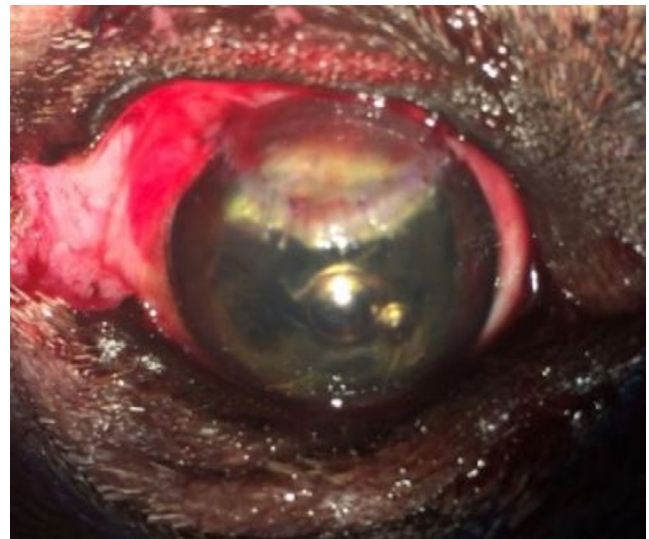The histologic sample was reviewed by the Comparative Ocular Pathology Laboratory of Wisconsin. The scleral collagen and peripheral corneal stroma were infiltrated, expanded, and partially effaced by a heavily pigmented, poorly delineated and moderately cellular mass. The mass was composed of round to fusiform cells arranged in solid sheets. The cellular features of the neoplastic cells were obliterated by the heavy cytoplasmic pigmentation. There was a focally extensive central area of necrosis characterized by a core of tissue eosinophilia and dispersion of melanin pigment surrounded by a rim of epithelioid macrophages. The neoplastic cells extended to the deep corneal margins. No description regarding the corneal lipidosis was provided. The histopathologic diagnosis confirmed clinical suspicion and was reported as a limbal melanocytoma with focally extensive necrosis and a granulomatous reaction with incompletely resected, deep corneal margins (Figure 5).

### 2.4 | Clinical outcome

Postoperative medications included ofloxacin 0.3% right eye q8 hours (Bausch and Lomb, Inc), ketorolac tromethamine 0.5% right eye q8 hours (Akorn, Inc), atropine sulfate 1% right eye q12 hours (Akorn, Inc), cephalexin 750 mg po q12 hours (Lupin Inc), and carprofen 100 mg po q12 hours



**FIGURE 3** BioSIS graft has been placed over limbal defect. Following the placement of an anchoring suture to the sclera, the graft was trimmed to appropriately fit the defect



**FIGURE 4** BioSIS graft sutured into corneal and scleral defect using simple continuous suture pattern. An air bubble is visible within the anterior chamber

(Rimadyl; Zoetis). The day following surgery, the right eye had 3+ aqueous flare with a mydriatic pupil, mild vitreal hemorrhage, and an intact corneoscleral graft. Slit lamp biomicroscopy was used to evaluate and quantify the level of aqueous

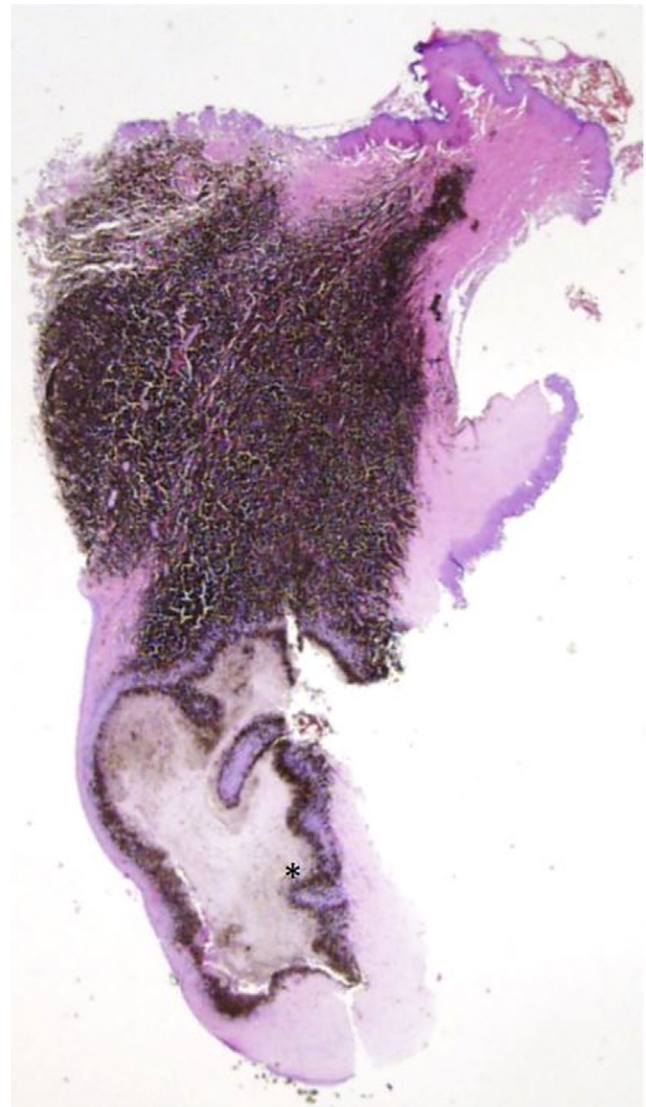flare.<sup>14</sup> Intraocular pressure was 10 mm Hg in the right eye and 11 mm Hg in the left eye. One and 2 weeks after surgery, the conjunctiva was adhering to the graft, there was moderate corneal edema with 1+ aqueous flare and the vitreal hemorrhage was resolved (Figure 6). Pupillary mydriasis was present, and all current treatments were continued. Four weeks following the surgery, the pupil was slightly dyscoric with the dorsal iris base partially entrapped within the incision. The anterior chamber was clear; however, mild granulation was present over the surgical site. The eye was negative for fluorescein stain uptake. Ketorolac was continued twice daily for the mild episclerokeratitis reaction.

Two months after the surgery, the granulation had resolved, and the conjunctival graft remained incorporated in the cornea and sclera. The pupil continued to be mildly dyscoric; however, the remainder of the intraocular examination was unremarkable. The patient was comfortable and visual in the right eye. At the most recent follow-up, seven months after surgery, the patient was re-evaluated and doing well with no evidence of mass regrowth; however, a thin rim of corneal lipidosis had reappeared adjacent to the margins of corneal fibrosis (Figure 7). The patient was lost to follow-up after the 7-month recheck; however, a phone conversation with the owner 13 months following surgery revealed the patient to be comfortable with no gross evidence of tumor regrowth or perilimbal pigmentation.

### 3 | DISCUSSION

Over the last several decades, numerous surgical approaches have been described for the resection of limbal melanomas, including full- or partial-thickness resection and various grafting procedures with or without adjunctive treatments including cryotherapy, plesiotherapy, and diode or Nd:YAG laser photocoagulation.<sup>4,6-13</sup> To the authors' knowledge, this is the first clinical report to describe the surgical resection of a limbal melanoma by way of penetrating scleroplasty using exclusively CO<sub>2</sub> laser photoablation. The deep lamellar keratectomy and conjunctival advancement were routinely performed as described in the literature. Enucleation has been advised for extensive limbal melanomas or those with intraocular invasion.<sup>2,15</sup> Based on this case report, it appears that CO<sub>2</sub> laser photoablation may be used to successfully resect a limbal melanoma while gently treating the surrounding corneoscleral collagen to cause coagulative necrosis<sup>16</sup> of any remaining neoplastic cells.

Early surgical intervention is generally warranted to prevent intraocular extension, which can lead to secondary glaucoma, intractable uveitis or retinal detachment.<sup>5,17</sup> The type of surgical resection should be based on patient selection, equipment availability, and surgeon experience. En bloc resection of limbal melanomas is generally regarded as the ideal surgical technique to most reliably prevent tumor regrowth; however,



**FIGURE 5** Low magnification histopathology section of the resected limbal melanoma. Notice the scleral collagen and peripheral corneal stroma partially effaced by a heavily pigmented mass that extends to the deep corneal margins (bottom of the image). \* Indicates deep corneal margins

this approach requires concurrent grafting procedures and can be associated with more severe complications including marked uveitis, dyscoria, extensive intraocular hemorrhage, and cataract formation.<sup>7,9,18,19</sup> Partial-thickness resection of limbal masses is commonly combined with adjunctive procedures used to cause necrosis of remaining neoplastic cells such as cryotherapy, photocoagulation, and plesiotherapy.<sup>4,6-13</sup>

Cryotherapy and photocoagulation are well-established treatment modalities in veterinary ophthalmology. Cryotherapy induces crystallization of the cellular cytoplasm leading to tissue destruction and cellular necrosis.<sup>9,20,21</sup> Due to a high water content, melanocytes are particularly sensitive to cryonecrosis leading to the recent investigation of this therapeutic in the treatment of limbal melanomas.<sup>11,20,21</sup> A retrospective analysis assessing the efficacy of lamellar resection

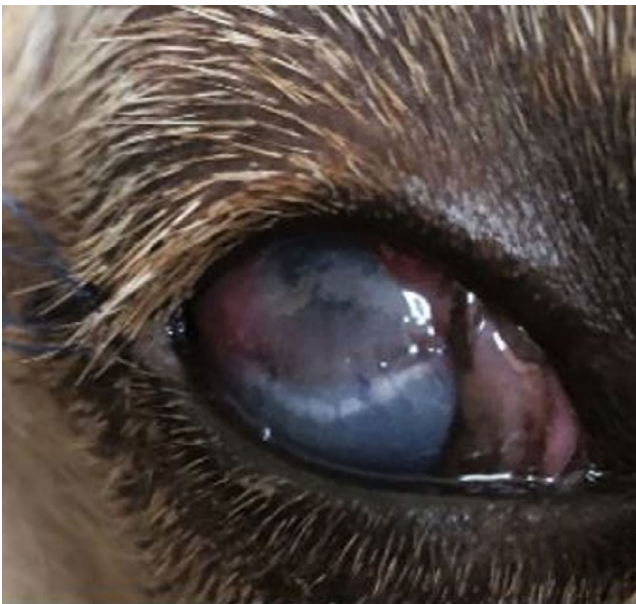combined with cryotherapy reported no tumor regrowth in 14 of 14 eyes with a median follow-up time of 2.1 years.<sup>11</sup> The most common long-term complication was persistent or recurrent corneal lipidosis in 3 of 14 eyes.<sup>11</sup> Another recent report described the combined use of surgical debulking of limbal melanomas and diode laser photocoagulation with 18 of 21 eyes (86%) visual 72 months after surgery and 19 of 21 eyes (90%) showing no signs of discomfort.<sup>9</sup> This procedure resulted in 2 of 21 eyes being affected by persistent corneal lipidosis after surgery. In a limited sample, it may appear as though diode laser photocoagulation can result in corneal degeneration less frequently compared to cryotherapy following partial-thickness resection of limbal melanomas.

Photocoagulation is an effective and common modality used to treat pigmented tissues. Both diode and Nd:YAG lasers are used in the treatment of melanomas, glaucoma and for retinopexy.<sup>16</sup> Both provide energy in the infrared electromagnetic spectrum and are absorbed well by melanin. Each are transmitted through the sclera and clear ocular media allowing direct application to pigmented intraocular structures.<sup>16</sup> The shorter wavelength of the diode (810 nm) compared with the Nd:YAG (1064 nm) allows for better melanin absorption, although the Nd:YAG will have better scleral penetration.<sup>16</sup> Less energy is required to achieve the desired destructive effect with the diode laser; thus, there is generally less risk of collateral damage compared to the Nd:YAG laser.<sup>16,22,23</sup>

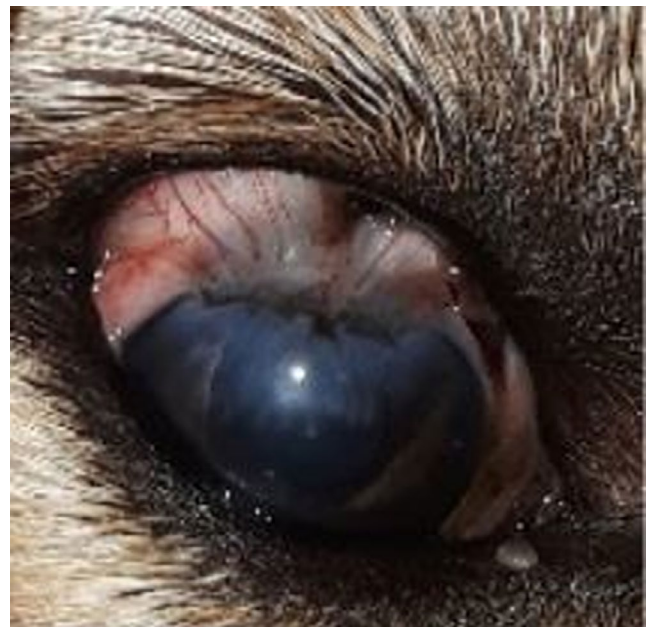
In this study, a CO<sub>2</sub> laser was used to perform the penetrating scleroplasty due to its photoablative effect in addition to causing coagulative necrosis to adjacent neoplastic cells.<sup>16</sup> The CO<sub>2</sub> laser uses a high wavelength (10 600 nm) and is

better absorbed by water rather than pigment.<sup>16</sup> This allows water and tissue to be vaporized within a narrow zone and penetrate to a depth of 0.1 mm, allowing for precise surgical control.<sup>16,24</sup> The CO<sub>2</sub> laser in this case was used with a 0.4 mm tapered probe on a 2-watt continuous setting to sharply dissect and ablate around the scleral portion of the lesion and control hemostasis. Additionally, the CO<sub>2</sub> laser was used to gently paint the corneal stroma within the keratectomy site in the event of getting dirty, deep corneal margins, which was confirmed on histopathology. Based on a 2009 publication by Hoffman et al, it was observed that CO<sub>2</sub> laser photokeratotomy can lead to focal endothelial cell destruction<sup>25</sup>; however, in the authors' opinion, the potential benefits of inducing necrosis of any remaining neoplastic cells following the keratectomy outweighed the potential risks of developing focal areas of corneal edema secondary to endothelial damage. The patient in this case had a rapidly growing tumor with potential to quickly impact vision; thus, a full-thickness sclerotomy using photoablation was considered superior to other partial-thickness debulking procedures previously described.

Postoperative complications included mild anterior uveitis, pupillary distortion, and a delayed episclerokeratitis manifesting as a dense granulation wound bed. Both the uveitis and the granulation quickly resolved with topical nonsteroidal anti-inflammatory therapy while the pupil remained dyscoric 13 months after surgery; however, the patient is visual and comfortable, and there has been no evidence of tumor recurrence.



**FIGURE 6** One-week postoperative. Note the corneal edema and conjunctival hyperemia. Corneal vessels are advancing through the graft approaching the suture line



**FIGURE 7** Seven months following surgery. There remains a thin rim of corneal lipidosis adjacent to the margins of corneal suture tract fibrosis. The incision is fully healed, and the anterior chamber is formed. Note the limbal symblepharon secondary to the conjunctival advancement graft. This resulted in an uneven limbal demarcation, which is of no apparent clinical significance

The limitations not yet described in this case report are highlighted by the fact that this technique describes the surgical outcome in only one patient. While it appears that a CO<sub>2</sub> laser can be used effectively in the surgical management of a limbal melanoma in a dog, greater case numbers are necessary before any data presented here within can be extrapolated to a larger population of patients. Other disadvantages of the current surgical technique include the need of a relatively expensive piece of equipment and the time investment required to become proficient using a novel surgical instrument. However, in the authors' opinion, a CO<sub>2</sub> laser can quickly become a versatile tool for any practitioner and comes with a relatively shallow learning curve.

In summary, the CO<sub>2</sub> laser may be a reasonable approach to performing a full-thickness scleroplasty in combination with lamellar keratectomy and bimodal grafting for the treatment of limbal melanomas. It may be considered as the primary surgical instrument or as an adjunctive therapeutic to en bloc removal of large limbal melanomas that are best suited for full-thickness resection.


## CONFLICT OF INTEREST

None declared.

## AUTHOR CONTRIBUTIONS

Zach Cochrane was involved in manuscript design and conception, written preparation, data acquisition, and editing. Peter Mohoric was the primary surgeon and participated in manuscript design and conception while providing critical revisions for intellectual content.

## ORCID

Zachary N. Cochrane  <https://orcid.org/0000-0002-5954-3320>

## REFERENCES

- Dubielzig RR, Ketring KL, McLellan GJ, et al. Diseases of the cornea and sclera. In: Dubielzig RR, Ketring KL, McLellan GJ, Albert DM, Eds. *Veterinary Ocular Pathology: A Comparative Review*. Edinburgh, UK: Saunders Elsevier; 2010: 201-243.
- Diters RW, Dubielzig RR, Aguirre GD, et al. Primary ocular melanoma in dogs. *Vet Pathol*. 1983;20:379-395.
- Wilcock BP, Peiffer Jr RL. Morphology and behavior of primary ocular melanomas in 91 dogs. *Vet Pathol*. 1986;23:418-424.
- Mathes RL, Moore PA, Ellis AE. Penetrating sclerokeratoplasty and autologous pinnal cartilage and conjunctival grafting to treat a large limbal melanoma in a dog. *Vet Ophthalmol*. 2015;18:152-159.
- Donaldson D, Sansom J, Sease T, et al. Canine limbal melanoma: 30 cases (1992–2004). Part 1. Signalment, clinical and histological features and pedigree analysis. *Vet Ophthalmol*. 2006;9:115-119.
- Donaldson D, Sansom J, Adams V. Canine limbal melanoma: 30 cases (1992–2004). Part 2. Treatment with lamellar resection and adjunctive strontium-90beta plesiotherapy—efficacy and morbidity. *Vet Ophthalmol*. 2006;9:179-185.
- Martin CL. Canine epibulbar melanomas and their management. *J Am Anim Hosp Assoc*. 1981;17:83-90.
- Sullivan TC, Nasisse MP, Davidson MG, et al. Photocoagulation of limbal melanoma in dogs and cats: 15 cases (1989–1993). *J Am Vet Med Assoc*. 1996;208:891-894.
- Andreani V, Guandalini A, D-Anna N, et al. The combined use of surgical debulking and diode laser photocoagulation for limbal melanoma treatment: a retrospective study of 21 dogs. *Vet Ophthalmol*. 2017;20:147-154.
- Norman JC, Urbanz JL, Cavarese ST. Penetrating keratoplasty and bimodal grafting for treatment of limbal melanocytoma in a dog. *Vet Ophthalmol*. 2008;11:340-345.
- Featherstone HJ, Renwick P, Heinrich CL, et al. Efficacy of lamellar resection, cryotherapy, and adjunctive grafting for the treatment of canine limbal melanoma. *Vet Ophthalmol*. 2009;12(suppl 1):65-72.
- Wilkie DA, Wolf ED. Treatment of epibulbar melanocytoma in a dog, using full-thickness eye wall resection and synthetic graft. *J Am Vet Med Assoc*. 1991;198:1019-1022.
- Plummer CE, Kallberg ME, Ollivier FJ, et al. Use of biosynthetic material to repair the surgical defect following excision of an epibulbar melanoma in a cat. *Vet Ophthalmol*. 2008;11:250-254.
- Hogan MJ, Kimura SJ, Thygeson P. Signs and symptoms of uveitis: I. Anterior uveitis. *Am J Ophthalmol*. 1959;47(5-2):155-170.
- Ryan AM, Diters RW. Clinical and pathologic features of canine ocular melanomas. *J Am Vet Med Assoc*. 1984;184:60-67.
- Gilmour MA. Lasers in ophthalmology. *Vet Clin North Am: Small Anim Pract*. 2002;32:649-672.
- Lewin GA. Repair of a full thickness corneoscleral defect in a German shepherd dog using porcine small intestinal submucosa. *J Small Anim Pract*. 1999;40:340-342.
- Bussiers M, Krohne SG, Stiles J, et al. The use of porcine small intestinal submucosa for the repair of full-thickness corneal defects in dogs, cats and horses. *Vet Ophthalmol*. 2004;7:352-359.
- Maggio F, Pizzirani S, Pena T, et al. Surgical treatment of epibulbar melanocytomas by complete excision and homologous corneoscleral grafting in dogs: 11 cases. *Vet Ophthalmol*. 2013;16:56-64.
- Vestre WA. Cryosurgical techniques in veterinary ophthalmology. *The Compendium on Continuing Education* 1984; 6: 481–487. 32.
- Hidayat AA, LaPiana FG, Kramer KK. The effect of rapid freezing on uveal melanomas. *Am J Ophthalmol*. 1987;103:66-80.
- Cook C, Wilkie D. Treatment of presumed iris melanoma in dogs by diode laser photocoagulation: 23 cases. *Vet Ophthalmol*. 1999;2:217-225.
- Cook C, Mike D, Brinkmann M, et al. Diode laser transscleral cyclophotocoagulation for the treatment of glaucoma in dogs: results of six and twelve month follow-up. *Vet Ophthalmol*. 1997;7:148-154.
- Callina TL, Hunts HJ. Applications of CO<sub>2</sub> laser in oculo-plastic surgery. *J Ophthalmic Nurs Tech*. 1999;18(3):95-99.
- Hoffman A, Ownby C, Lehenbauer TW, et al. Light and electron microscopic evaluation of canine corneal endothelium following CO<sub>2</sub> photokeratotomy. *Vet Ophthalmol*. 2009;12:28-34.

**How to cite this article:** Cochrane ZN, Mohoric PJ. Deep lamellar keratectomy and penetrating scleroplasty using CO<sub>2</sub> laser photoablation and bimodal grafting for the treatment of a limbal melanoma in a dog. *Clin Case Rep*. 2020;8:751–756. <https://doi.org/10.1002/ccr3.2750>