

Essential thrombocythemia, hemolytic anemia and hepatic cirrhosis: Could there be an association?

Nata Pratama Hardjo Lugito,¹
Andree Kurniawan,¹

Yohanes Chandra Kurniawan,²
Enny Yacobus,² Edwin Halim²

¹Department of Internal Medicine, Faculty of Medicine, Pelita Harapan University; ²Faculty of Medicine, Pelita Harapan University, Tangerang, Banten, Indonesia

Abstract

Vascular events are the most common clinical complication of essential thrombocythemia, leading to sign and symptoms of this disease. There are various sign and symptoms of essential thrombocythemia, such as thrombosis in artery or vein, and enlarged spleen. Portal hypertension and hepatic cirrhosis could be caused by essential thrombocythemia via intrahepatic thrombus. Anemia in essential thrombocythemia patient treated with hydroxyurea could be the side effect of bone marrow suppression and also hydroxyurea induced hemolytic anemia. Association between autoimmune hemolytic anemia and primary biliary cirrhosis or hepatic cirrhosis has been discussed. This case report presented an patient diagnosed with essential thrombocythemia. He later developed hepatic cirrhosis possibly caused by intra hepatic thrombus in the setting of hypercoagulability in myeloproliferative disorders. He also suffered from anemia due to hydroxyurea induced hemolytic anemia. Association between autoimmune hepatic cirrhosis and autoimmune hemolytic anemia should also be considered in this patient.

Introduction

Myeloproliferative disorders include polycythemia vera (PV), essential thrombocythemia (ET), myelofibrosis. The diagnosis of ET is challenging as it is a diagnosis of exclusion, and there is higher frequency of thrombocythemia caused by other etiologies.^{1,2} In Europe, ET prevalence is approximately 0.38 to 1.7 per 100,000 population per year.³ It is not uncommon that portal hypertension and hepatic cirrhosis

was caused by ET and other myeloproliferative disorders via intrahepatic thrombus. Anemia as side effect of bone marrow suppression in ET therapy using hydroxyurea is also uncommon, but hydroxyurea induced hemolytic anemia is. There were reports about association between autoimmune hemolytic anemia (AIHA) and primary biliary cirrhosis or hepatic cirrhosis. This case report presented an ET patient with intra hepatic thrombus as the possible cause of hepatic cirrhosis, which suffered anemia due to hydroxyurea induced hemolytic anemia. Association between autoimmune hepatic cirrhosis and AIHA should also be considered to explain the pathogenesis of cirrhosis and anemia in this ET patient.

Case Report

A 61-year-old male was admitted to general hospital in Tangerang, due to progression of fatigue since a week before. The patient had history of essential thrombocythemia (ET) and hemolytic anemia since 12 and 7 years ago consecutively. The ET was diagnosed based on bone marrow biopsy done that showed proliferation of megakaryocytes, not meeting other myelodysplastic syndrome. He was treated with hydroxyurea for 5 years and then substituted with azathioprine due to possible of hydroxyurea-induced hemolytic anemia. The patient was diagnosed of hemolytic anemia as the immunoglobulin G (IgG) on Coombs test was positive. Approximately 3 years ago, the patient experienced abdominal enlargement with tenderness on the upper left quadrant of the abdomen. Non-contrast abdominal computed tomography (CT) scan examination was done and the results showed hepatic cirrhosis, splenomegaly, portal hypertension and ascites. He had history of packed red cell transfusion due to anemia 7 years ago. A year before admission, he experienced multiple episodes of hematemesis and melena that caused anemia and series of packed red cell transfusion. He underwent esophagogastroduodenoscopy (EGD), which showed rupture of esophageal varices, which was then ligated (Figures 1 and 2).

At admission, the patient was comatose with vital signs blood pressure of 100/60 mmHg, pulse rate of 96 beats per minute, respiratory rate of 17 times per minute, and temperature 36°C. His body weight was 58 kg, height 173 cm, BMI of 19.3. His skin was icteric, with icteric sclera and pale conjunctiva. In the abdomen, there was schuffner 3 splenomegaly with ascites

Correspondence: Nata Pratama Hardjo Lugito, Department of Internal Medicine, Faculty of Medicine, Pelita Harapan University, Boulevard Jendral Sudirman, Karawaci, Tangerang, Banten, 15811 Indonesia. Tel.: +62.21.54210130 - Fax: +62.21.54210133. E-mail: nata.lugito@uph.edu

Key words: Essential thrombocythemia; hemolytic anemia; hepatic cirrhosis; hydroxyurea.

Contributions: the authors contributed equally.

Conflict of interest: the authors declare no potential conflict of interest.

Received for publication: 2 September 2017.
Accepted for publication: 24 June 2018.

This work is licensed under a Creative Commons Attribution-NonCommercial 4.0 International License (CC BY-NC 4.0).

©Copyright N.P.H. Lugito et al., 2018
Licensee PAGEPress, Italy
Hematology Reports 2018; 10:7394
doi:10.4081/hr.2018.7394

and no palpated liver.

Laboratory results 3 months before admission showed decrease cholinesterase of 3135 U/L, normal albumin of 3.79 mg/dL, decreased globulin of 1.61 mg/dL, increased total/direct and indirect bilirubin of 6.36 mg/dL, 2.86 mg/dL and 4.1 mg/dL, increased alkaline phosphatase of 245 U/L and normal gamma glutamyl transferase of 174 U/L. Upon admission, laboratory results showed microcytic hypochromic anaemia with hemoglobin level of 6.3 g/dL, increased leucocyte of 29,420/ μ L, normal platelet of 402,000/ μ L. Aspartate and alanine aminotransferase were in normal range (9 U/L and 26 U/L), the total, direct and indirect bilirubin was 2.84 mg/dL, 1.06 mg/dL and 1.78 mg/dL. There were an increase in prothrombin and activated partial thromboplastin time of 12.1 and 46.7 seconds, and in D-Dimer of 3.57. Viral hepatitis B and C examination were negative. Stool examination showed positive occult blood. This patient was treated with methylprednisolone 16 mg O.D., azathioprine 50 mg B.I.D, propranolol 10 mg T.I.D, spironolactone 100 mg and furosemide 40 mg O.D.. The patient was discharged with resolution of his fatigue.

Discussion and Conclusions

Essential thrombocythemia (ET) is one of the most prevalent myeloproliferative

neoplasms (MPNs), a group of blood neoplasms characterized by the clonal overproduction of one or more blood cell lines.^{1,2} The World Health Organization (WHO) criteria of diagnosis for ET prerequisites platelet count above 450,000/ μ L, bone marrow biopsy that shows proliferation of megakaryocytes, not meeting other myelodysplastic syndrome, with no causes of reactive thrombocytosis.^{1,2,4-6} Since 2015, the genetic presence of JAK2 is not needed to diagnose ET according to WHO.⁶

Vascular events are the most common clinical complication of ET, including arterial and venous thrombosis, and microvascular occlusion, leading to sign and symptoms of ET.¹ The excessive amount of platelets in the blood caused by increased platelets forming in the marrow, creating thrombus.^{1,2} Less often, the high amount of platelets can also cause bleeding problems.^{1,2} There are various sign and symptoms of ET, such as headache, dizziness, weakness, transient ischemic attacks which is similar to stroke, thrombosis in artery or

vein, unexpected bleeding, enlarged spleen.^{1,2} The patient in this case was diagnosed of ET 12 years before admission after routine medical check up that revealed the high platelet count. He did not have any sign or symptoms of ET complication at the time of diagnosis. There were no causes for reactive thrombocytosis and the bone marrow biopsy confirmed the diagnosis of ET, not meeting other myelodysplastic syndrome.

The patient was treated by hydroxyurea, which is still the mainstay treatment for lowering platelets count in high risk patient ET. As it suppresses bone marrow production of blood cells such as red blood cells, leucocytes and platelets within several weeks, it could also cause anaemia.² The patient experienced anemia 7 years ago after treated with hydroxyurea for 5 years. Anemia in this patient was firstly considered as side effect of suppression of blood cells production. As the Coombs test was positive, hydroxyurea induced hemolytic anemia should be considered as there was one case report on hydroxyurea induced hemolytic anemia.⁵ The anemia then resolved as the hydroxyurea was substituted with azathioprine. Other possibility of anemia in this patient was autoimmune hemolytic anemia, as hydroxyurea and azathioprine was also used to treat autoimmune cases.

As the disease progress overtime, the patient was diagnosed of hepatic cirrhosis 3 years before admission. It was considered that hepatic cirrhosis in this patient was caused by intrahepatic thrombus, due to the hypercoagulability state present in ET and hemolytic anemia shown by the increased D-dimer values. Symptomatic intrahepatic thrombus in the form of cirrhosis, splenomegaly and ascites was known as Budd-Chiari Syndrome, was most commonly caused by myeloproliferative disorders. Other etiologies of hepatic cirrhosis were the chronic viral hepatitis B and C, alcoholic or nonalcoholic fatty liver disease,

chronic biliary disease such as recurrent cholangitis or bile duct stenosis, decompensated cardiovascular system such as cardiac cirrhosis, medications, and autoimmune hepatitis in form of autoimmune hepatitis or primary biliary cirrhosis.⁷⁻¹¹ Those etiologies could be excluded as the patient did not have history of alcohol consumption and heart failure, and was normoweight. Bile duct stenosis was not found on the non-contrast abdominal CT scan although there was chronic cholecystitis and multiple cholelithiasis. Confirmation of intrahepatic thrombus requires visualization of *spider web* pattern through hepatic venography or contrast-enhanced CT scan or magnetic resonance imaging (MRI) scan. There was no signs of intrahepatic thrombus on ultrasonography and non-contrast abdominal CT scan, which prompted further examination.¹⁰ Other etiologies of cirrhosis worth to consider was autoimmune hepatitis or primary biliary cirrhosis, as the there was one case report on patient suffering autoimmune hemolytic anemia and primary biliary cirrhosis.¹² As mentioned above, there was still possibility of AIHA as the anemia resolved as he was treated with azathioprine. Azathioprine could also suppress the progression of autoimmune hepatitis, thus making the diagnosis less likely. A study found few concomitant cases of AIHA and primary biliary cirrhosis, which AIHA developed first before the development of primary biliary cirrhosis, which concluded that there may be no correlation between the AIHA and primary biliary cirrhosis.¹³ The hepatic cirrhosis in this patient occurred after ET and hemolytic anemia thus it could be hypothesized that cirrhosis resulted from ET and hemolytic anemia. Hepatic cirrhosis as the complication of thrombosis, which is common in ET patients, and the anemia was hemolytic anemia induced by hydroxyurea for ET therapy. The anemia was not AIHA as hydroxyurea and azathioprine was the treatment for AIHA, and the anemia resolved after

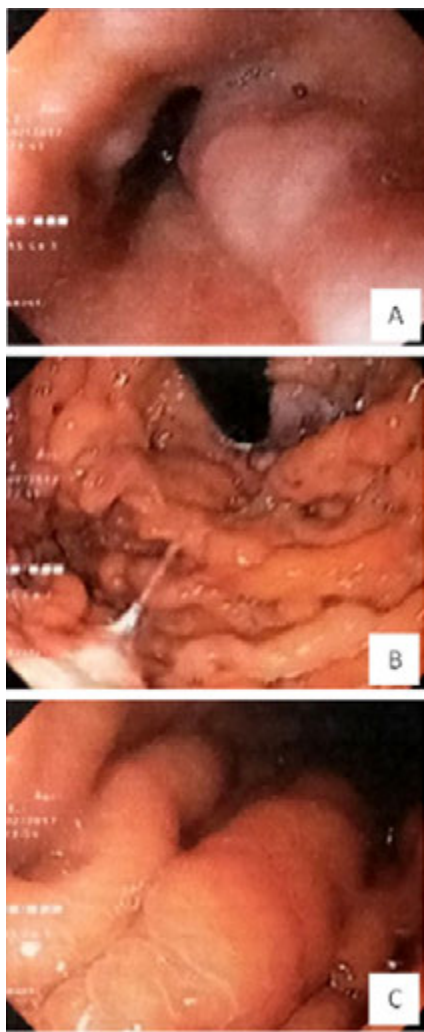


Figure 1. Esophagogastroduodenoscopy showing rupture of esophageal varives.

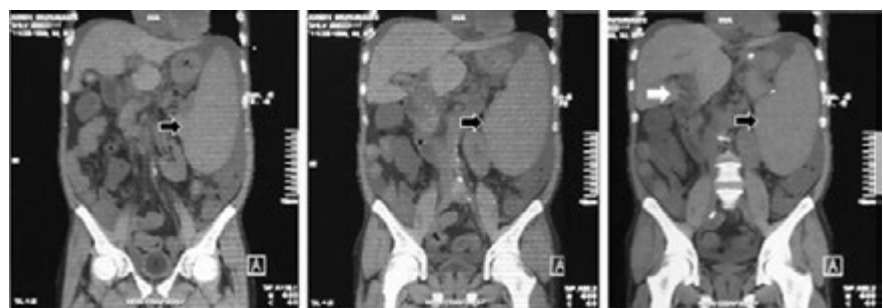

Figure 2. Non-contrast abdominal computed tomographic scan examination.

treated with azathioprine. Other possibility was the hepatic cirrhosis and anemia could be a separate entity of autoimmune disease in this ET patient. Examination to confirm the autoimmune hepatitis or primary biliary cirrhosis is liver biopsy. Examinations to confirm diagnosis of hepatic cirrhosis, the hepatic venography or contrast-enhanced CT or MRI scan and liver biopsy was not available in the health facility.

This case report has discussed ET patient with intra hepatic thrombus as the cause of hepatic cirrhosis, which suffered hydroxyurea induced hemolytic anemia as side effect of ET therapy. Other possibilities of hepatic cirrhosis and anemia was autoimmune in the form of autoimmune hepatitis and AIHA. Further study is needed to make definitive diagnosis of hepatic cirrhosis and anemia, and to explain the association between ET, hepatic cirrhosis and anemia in this patient.

References

1. Keohane C, Harrison C. Essential

thrombocytopenia: new advances in an old disease. *Clin Investig* 2012;2:603-14.

2. Vetstovsek S. Essential thrombocytopenia facts. *Leuk Lymph Soci* 2012;2.
3. Moulard O, Mehta J, Fryzek J, Olivares R, et al. Epidemiology of myelofibrosis, essential thrombocytopenia, and polycythemia vera in the European Union. *Eur J Haematol* 2014;92:289-97.
4. Spivak JL, Silver RT. The revised world health organization diagnostic criteria for polycythemia vera, essential thrombocytopenia, and primary myelofibrosis: an alternative proposal. *Blood* 2008;112:231-9.
5. Jabr F, Shamseddine A, Taher A. Hydroxyurea-induced hemolytic anemia in a patient with essential thrombocytopenia. *Am J Hematol* 2004;77:374-6.
6. Barbui T, Thiele J, Vannuchi A, Tefferi A. Rationale for revision and proposed changes of the WHO diagnostic criteria for polycythemia vera, essential thrombocytopenia and primary myelofibrosis. *Blood Cancer J* 2015;5:337.
7. Schuppan D, Afdhal N. Liver cirrhosis. *Lancet* 2008;371:838-51.
8. Wiegand J, Berg T. The etiology, diagnosis and prevention of liver cirrhosis. *Deutsche Arzteblatt Int* 2013;110:85-91.
9. Hanai T, Naiki T, Takamatsu M, et al. A case of acute autoimmune hepatitis associated with autoimmune haemolytic anemia. *Nihon Shokakibyo Gakkai Zasshi* 2013;110:1814-22.
10. Menon K, Shah V, Kamath P. The Budd-Chiari syndrome. *N Engl J Med* 2004;350:578-85.
11. Ataga KI. Hypercoagulability and thrombotic complications in haemolytic anemia. *Haematologica* 2009;94:1481-3.
12. Meade S, Kotha S, Gera A, Loganayagam A. Autoimmune haemolytic anaemia is a rare association with primary biliary cirrhosis. *Br J Hospital Med* 2016;77:370-1.
13. Shizuma T. Concomitant cases of primary biliary cirrhosis and autoimmune hemolytic anemia: literature review. *Intern Med* 2015;5:189.