



Case Report

Brain abscess in a rheumatoid arthritis patient treated with leflunomide – A case presentation and review

Efthymia Samara¹, Ioannis Siasios², Konstantinos Katsiardanis¹, Eirini Liaptsi¹, Kalliopi Tsoleka², Georgia Deretzi¹

Departments of ¹Neurology, ²Neurosurgery, Papageorgiou Hospital of Thessaloniki, Periferiaki Odos N. Efkarpia, Thessaloniki, Central Macedonia, Greece.

E-mail: *Efthymia Samara - effie.samara82@gmail.com; Ioannis Siasios - siasiosj@yahoo.gr; Konstantinos Katsiardanis - dinosgr@gmail.com; Eirini Liaptsi - liaptsi.eirini@hotmail.com; Kalliopi Tsoleka - kaltso@otenet.gr; Georgia Deretzi - gderetzi@gmail.com



*Corresponding author:

Efthymia Samara,
Department of Neurology,
Papageorgiou Hospital of
Thessaloniki, Periferiaki Odos
N. Efkarpia, Thessaloniki,
Central Macedonia, Greece.

effie.samara82@gmail.com

Received : 08 December 2020

Accepted : 11 February 2021

Published : 17 March 2021

DOI

10.25259/SNI_886_2020

Quick Response Code:



ABSTRACT

Background: Immunosuppression is a significant parameter in the pathogenesis of brain abscesses (BA) and it could be the result of severe infections such as acquired immunodeficiency syndrome or drug-induced, by several medications used for systemic autoimmune diseases. Leflunomide is a pyrimidine synthesis inhibitor that affects the proliferation of lymphocytes and is used as a disease-modifying antirheumatic drug. Mild infections, particularly those of the respiratory tract and herpes zoster, are one of its most common adverse effects. However, atypical and severe infections have also been reported under treatment with leflunomide.

Case Description: A 70-year old female was referred to our hospital with headache, aphasia, and right-sided hemiparesis and a lesion of the left parietal lobe initially interpreted as a malignancy. Her medical history revealed a 12-year old history of rheumatoid arthritis under current treatment with leflunomide. A cerebral magnetic resonance imaging (MRI) revealed typical findings for a BA. She subsequently underwent a left craniotomy, which confirmed the MRI-based diagnosis. The abscess was evacuated and cultures were obtained intraoperatively. In the postoperative examination, the patient showed no neurological deficit.

Conclusion: The differential diagnostic considerations in immunocompromised patients with neurologic deficits should include focal central nervous system infections such as a BA, even in the absence of fever or immunosuppressant-induced leukopenia. It also demonstrates the importance of early neurosurgical intervention for the prevention of sequelae. To the best of our knowledge, this is the second-to-date reported case of a BA under immunomodulatory therapy with leflunomide.

Keywords: Brain abscess, Infections, Leflunomide, Rheumatoid arthritis

INTRODUCTION

Brain abscess (BA) is an intracranial, potentially lethal, space occupying inflammatory lesion with an estimated incidence of 0.3–1.3 per 100,000 people yearly in northern societies.^[3] The non-specificity of the initial symptoms such as fatigue, headache, and dizziness can lead to a significant diagnostic delay. Patient may present with focal neurologic deficits correlated with the area of infection, epileptic seizures, a decreased level of consciousness, and other signs of increased intracranial pressure such as headache, vomiting, and papilledema. Absence of fever is very common (30–76% of all cases) and does not exclude the diagnosis. Meningeal signs, when present, are indicative of intraventricular abscess rupture.^[5] The common diagnostic approach at the emergency department includes a brain computerized tomography (CT) scan with and

This is an open-access article distributed under the terms of the Creative Commons Attribution-Non Commercial-Share Alike 4.0 License, which allows others to remix, tweak, and build upon the work non-commercially, as long as the author is credited and the new creations are licensed under the identical terms.

©2021 Published by Scientific Scholar on behalf of Surgical Neurology International

without contrast as well as a brain magnetic resonance imaging (MRI) with and without gadolinium.^[13]

Trauma or commonly performed neurosurgical procedures have been associated with the emergence of BA by either direct contiguous microbial spread or hematogenous spread, while in almost 40% of the published cases the cause remains unknown.^[11,12] The type of pathogens implicated in a BA can be highly variable and depends mostly on the route of spread as well as patient age, country of residence, previous medical history, and medications such as steroids. In up to 25% of the cases, no pathogen is detected.^[14]

In addition, the literature supports that immunosuppression is also a significant parameter in the pathogenesis of BAs. Immunosuppression could be the result of severe infections such as acquired immunodeficiency syndrome or drug-induced, by several medications used for systemic autoimmune diseases, such as corticosteroids, calcineurin inhibitors, mTOR inhibitors, tumor necrosis factor (TNF) inhibitors, monoclonal antibodies, and antiproliferative agents. Leflunomide is a pyrimidine synthesis inhibitor that acts as an immunomodulator by affecting the proliferation of lymphocytes and is used in the treatment of active Rheumatoid and Psoriatic Arthritis. Susceptibility to infections, particularly those of the respiratory tract and herpes zoster, is one of its most common adverse effects and is mostly associated to leucopenia.

Here, we present the case of a 70-year-old woman with a known history of rheumatoid arthritis (RA) under treatment with leflunomide, who was referred to our hospital of tertiary care with headache, aphasia, right-sided hemiparesis, and a left parietal lesion which was initially misdiagnosed as central nervous system (CNS) malignancy.

CASE PRESENTATION

A 70-year old female was admitted to an outside hospital with a 14-days history of headache, dizziness, and a mild aphasia. A CT scan was performed [Figure 1] revealing a left parietal lesion, which was initially presumed as a tumor. An intravenous therapy with dexamethasone 8 mg IVq8H was initiated and the patient was referred to a tertiary hospital for further treatment.

On admission at the emergency department and later on at the clinic, the patient had a Glasgow Coma Scale of 14/15 (Eyes:4, Verbal: 4, Movement: 6) with a mild aphasia, a right-sided hemiparesis, and neglect.

Her previous medical history revealed that she was diagnosed with RA at the age of 58 years old and was receiving orally 20 mg of leflunomide per day. She had been treated with methotrexate and hydroxychloroquine in the past, under which she had experienced many relapses that required oral

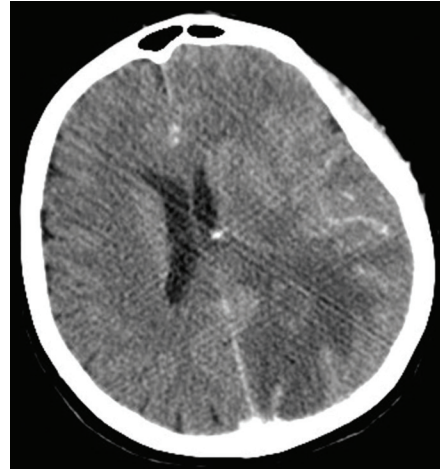


Figure 1: Axial brain CT with contrast demonstrates a poorly defined area of the left parietal lobe, with surrounding edema, and ring-like enhancement.

corticosteroids. It was only when her antirheumatic therapy was switched to leflunomide that she had a long-term remission. The last time she had received oral corticosteroids was 3 years ago for a period of 6 months.

Initial laboratory studies were normal, apart from a slightly elevated C-reactive protein (CRP) (CRP: 4.7 mg/dl, normal range: <0.5 mg/dl) with a normal white blood cell count (WBC: $6,9 \times 10^3/\mu\text{l}$) and no history of fever.

In the next 48 h a single fever wave of 39°C was documented, followed by subfebrile body temperatures, and a slight deterioration of her speech and orientation. A brain MRI demonstrated a left parietal, rim-enhancing collection of fluid with diffusion restriction and dimensions of 48 mm × 25 mm × 19 mm that resembled a BA [Figure 2a-d]. Blood cultures were obtained and a CT scan of the thorax, abdomen and pelvis as well as a transesophageal echocardiogram were performed, to rule out a possible primary location. The initial antibiotic regimen included ceftriaxone, metronidazole, and vancomycin. Due to the suspected BA, dexamethasone was discontinued and a prophylactic therapy with levetiracetam 1000 mgIVq 12H was initiated, given the high risk of seizure. In the next 48 h her hemiparesis improved, as well as her laboratory infection parameters. However, her aphasia deteriorated further and she additionally developed dyscalculia. This deterioration of the neurological status was attributed to the space-occupying effect of the BA during the stage of the early capsule formation, as well as the expansion of the surrounding edema, due to the discontinuation of dexamethasone. Neurosurgery consultation led to patient's immediate surgical treatment. A left craniotomy was performed and an intraparenchymal abscess was detected and evacuated. Cultures for common microbes as well as *Mycobacterium tuberculosis* and *Nocardia* were obtained

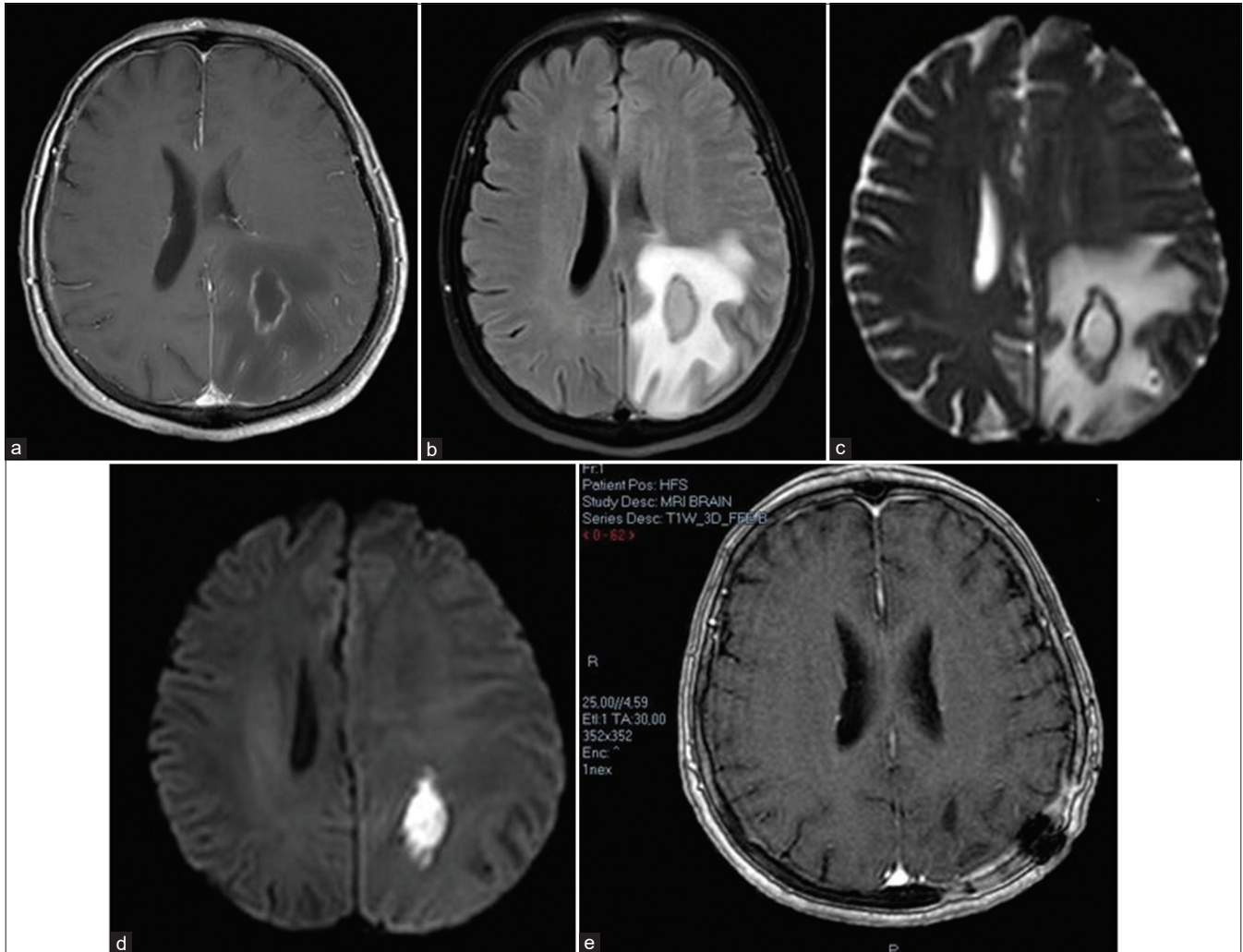


Figure 2: Axial brain MRI images demonstrate a rim-enhancing (a), collection of fluid which does not attenuate on FLAIR (b), with true diffusion restriction (c and d), indicative of a brain abscess. Postoperative image (e) was acquired 2 months after evacuation and demonstrates no signs of fluid collection or gadolinium enhancement.

intraoperatively from both the liquid and the solid part of the BA. The patient was extubated successfully and at her postoperative clinical evaluation she had a significant improvement of her neurological status. The intraoperatively obtained cultures came up negative, probably because of the early start of empirical antibiotic therapy. Histopathology revealed an aggregation of lymphocytes, macrophages, and neutrophils in a loose extracellular matrix, consistent with an abscess. No malignant cells were present.

Seven days postoperatively only a slight paresis of patient's right upper extremity remained. The patient was discharged 6 weeks after her surgery and she continued receiving an oral antibiotic therapy (amoxicillin/clavulanic acid in combination with levofloxacin) for another 4 weeks. At her follow-up examination (1 month postoperative) she did not have any focal neurological deficits and she was able to

resume her daily activities. The postoperative brain MRI demonstrated only the usual postoperative changes of the brain without any sign of fluid collection or gadolinium enhancement [Figure 2e].

Despite this incident, leflunomide was resumed after the termination of the antibiotic therapy, since her RA was refractory to the other antirheumatic therapies.

METHODS

The authors performed a review of the literature considering BA and other severe infections under treatment with leflunomide, published in PubMed, reported up to October 2020. Searching key words included "BA," "RA," "infections," and "leflunomide." A severe infection was defined as an infection requiring intravenous antibiotic therapy and hospitalization.

RESULTS

The results of the search showed a total of five case reports/series, two prospective studies, and one retrospective study in RA patients under treatment with leflunomide. Apart from our case, only one other case of a BA has been reported (Lee and Chang, 2003),^[12] to the best of our knowledge. Tuberculosis reactivation and pneumonia are the most common severe infections that have been associated with the use of leflunomide, followed by herpes zoster, pyelonephritis, and cellulitis.^[8,10,20] However, atypical and rare entities such as progressive multifocal leukoencephalopathy (PML), paravertebral abscess, pyomyositis, septic arthritis, and mediastinal abscess have also been reported.^[1,7,18] These cases are summarized in [Table 1].

DISCUSSION

Our case illustrates that the differential diagnostic considerations in immunocompromised patients with neurologic deficits should include a focal CNS infection such as a BA, even in the absence of fever, and signs of a systemic infection or immunosuppressant-induced leucopenia.

MRI is an indispensable tool in the differential diagnosis of a BA. MRI demonstrates a well-defined T1-weighted images (T1WI) hypointense and T2-weighted images (T2WI) hyperintense lesion with a rim, best seen on T2WI, enhancing intensely on postcontrast T1WI (ring enhancement),^[4,14] resembling the appearance of a malignant tumor. However, the high viscosity and cellularity of an abscess usually results in truly restricted diffusion of the lesion in the diffusion-WI, helping differentiate these two entities, while the inflammation, microhemorrhages, and collagen deposition in the abscess wall lead to the formation of the rim seen on the MRI. Apart from the diffusion restriction, the so-called “dual rim sign” can help distinguish a BA from a brain malignancy; it consists of two concentric rims, an outer one, which is hypointense, and an inner one, which is relatively hyperintense on both T2WI and susceptibility WI. As for the

abscess cavity, its appearance on the MRI depends greatly on the stage of infection. In the initial phase, it may demonstrate a low signal on the T1W1 and a high signal on the T2W1. Later on, the low T1W1 signal becomes better demarcated, while the T2W2 signal remains high. The brain parenchyma surrounding the cavity may also demonstrate a high T2W1 signal.^[16]

Diagnostic delay may be caused by the non-specificity of the initial symptoms, such as dizziness and headache, and the absence of fever. Absence of fever can be seen in 30-76% of the cases,^[6,9] particularly in immunocompromised patients, and it does not exclude a serious infection. Mild CRP elevation may be falsely attributed to the chronic inflammation in patients with RA.

Leflunomide is a pyridine synthesis inhibitor used in the treatment of active RA. Its active metabolite reversely inhibits dihydroorotate dehydrogenase, resulting in the depletion of the pyrimidine supply to support the DNA synthesis and, subsequently, the proliferation of T-lymphocytes. It has also been implicated in the disruption of interleukin-1 and TNF- α pathways as well as in the glycosylation of adhesion molecules, thus reducing cell-cell contact activation during the inflammatory process.^[2,19]

RA is characterized by dysfunctional innate immunity, which increases the risk for infections and infection-related mortality.^[15,17] This risk is exacerbated with the addition of disease-modifying antirheumatic drugs such as leflunomide. To date, only one case of BA in a rheumatoid patient has been previously reported by Lee and Chang in 2003.^[12] [Table 1] summarizes all – to the best of our knowledge – published studies and case reports of serious infections in rheumatoid patients under treatment with leflunomide.

On review of this literature, a direct cause-and-effect relationship between leflunomide and severe infections cannot be verified. Disease activity and duration, age, other comorbidities, and combination therapy with corticosteroids and/or other immunosuppressants also play a significant

Table 1: A summary of all PubMed reported cases of serious infections under treatment with leflunomide.

Author/Year of publication	Type of study	Type of Infection
Lee and Chang 2003	Case report	BA
Grover <i>et al.</i> 2006	Case report	pyomyositis, paravertebral abscess
Hocevar <i>et al.</i> 2006	Case report	tuberculosis
Wolfe <i>et al.</i> 2006	Prospective study	pneumonia
Jenks <i>et al.</i> 2007	Prospective study	liver tuberculosis, herpes zoster, cellulitis, bronchitis, gastroenteritis, pneumonia, infectious endocarditis, abdominal sepsis, mycotic aneurysm
Rahmlow <i>et al.</i> 2008	Case report	PML
Balasanthiran <i>et al.</i> 2010	Case report	septic arthritis, mediastinitis
Yoo <i>et al.</i> 2012	Retrospective study	pneumonia, oral candidiasis, cellulitis, pyelonephritis, pulmonary tuberculosis

PML: Progressive multifocal leukoencephalopathy, BA: Brain abscess

role. Jenks *et al.* imply that infections under leflunomide have the tendency to progress rapidly, therefore a washout with cholestyramine or activated carbon should be considered.^[10]

The successful management of this rare case was not only the result of early identification but also of the cooperation and coordinated exchange of information and expertise of the different medical specialties in a tertiary hospital, including a neurologist, a neuroradiologist, a rheumatologist, an infectiologist, and a neurosurgeon.

Declaration of patient consent

Patient's consent not required as patients identity is not disclosed or compromised.

Financial support and sponsorship

Nil.

Conflicts of interest

There are no conflicts of interest.

REFERENCES

- Balasanthiran A, Vakiligilani T, Darzy K, Axon J. A case of severe staphylococcal septicaemia: Septic arthritis and a mediastinal abscess following leflunomide therapy for rheumatoid arthritis. *BMJ Case Rep* 2010;2010:bcr0720092082.
- Breedveld FC, Dayer JM. Leflunomide: Mode of action in the treatment of rheumatoid arthritis. *Ann Rheum Dis* 2000;59:841-9.
- Brouwer MC, Coutinho JM, van de Beek D. Clinical characteristics and outcome of brain abscess: Systematic review and meta-analysis. *Neurology* 2014;82:806-13.
- Carpenter J, Stapleton S, Holliman R. Retrospective analysis of 49 cases of brain abscess and review of the literature. *Eur J Clin Microbiol Infect Dis* 2007;26:1-11.
- Chuang JM, Lin WC, Fang FM, Huang YJ, Ho JT, Lu CH. Bacterial brain abscess formation in post-irradiated patients: What is the possible pathogenesis? *Clin Neurol Neurosurg* 2015;136:132-8.
- Dorsett M, Liang SY. Diagnosis and treatment of central nervous system infections in the emergency department. *Emerg Med Clin North Am* 2016;34:917-42.
- Grover R, Dhir V, Aneja R, Arya V, Galle A, Marwaha V, *et al.* Severe infections following leflunomide therapy for rheumatoid arthritis. *Rheumatology (Oxford)* 2006;45:918-20.
- Hocevar A, Rozman B, Prapotnik S, Lestan D, Erzen V, Petric M, *et al.* Leflunomide-associated tuberculosis? *Rheumatology (Oxford)* 2006;45:228-9.
- Jameson JL, Kasper DL, Fauci AS. *Harrison's Principles of Internal Medicine*. 20th ed. New York: McGraw-Hill Education; 2018.
- Jenks KA, Stamp LK, O'Donnell JL, Savage RL, Chapman P. Leflunomide-associated infections in rheumatoid arthritis. *J Rheumatol* 2007;34:2201-3.
- Landriel F, Ajler P, Hem S, Bendersky D, Goldschmidt E, Garategui L, *et al.* Supratentorial and infratentorial brain abscesses: Surgical treatment, complications and outcomes--a 10-year single-center study. *Acta Neurochir (Wien)* 2012;154:903-11.
- Lee CS, Chang CK. Brain abscess in rheumatoid arthritis. *Ann Rheum Dis* 2003;62:689-90.
- Lee TH, Chang WN, Su TM, Chang HW, Lui CC, Ho JT, *et al.* Clinical features and predictive factors of intraventricular rupture in patients who have bacterial brain abscesses. *J Neurol Neurosurg Psychiatry* 2007;78:303-9.
- Leuthardt EC, Wippold FJ, Oswood MC, Rich KM. Diffusion-Weighted MR imaging in the preoperative assessment of brain abscesses. *Surg Neurol* 2002;58:395-402; discussion 402.
- Michaud K, Wolfe F. Comorbidities in rheumatoid arthritis. *Best Pract Res Clin Rheumatol* 2007;21:885-906.
- Miranda HA, Castellar-Leones SM, Elzain MA. Brain abscess: Current management. *J Neurosci Rural Pract* 2013;4 Suppl 1:S67-81.
- Naz SM, Symmons DP. Mortality in established rheumatoid arthritis. *Best Pract Res Clin Rheumatol* 2007;21:871-83.
- Rahmlow M, Shuster E, Dominik J, Deen HG, Dickson DW, Aksamit AJ, *et al.* Leflunomide-associated progressive multifocal leukoencephalopathy. *Arch Neurol* 2008;65:1538-9.
- Toh CH, Wei KC, Chang CN, Hsu PW, Wong HF, Ng SH, *et al.* Differentiation of pyogenic brain abscesses from necrotic glioblastomas with use of susceptibility-weighted imaging. *AJNR Am J Neuroradiol* 2012;33:1534-8.
- Wolfe F, Caplan L, Michaud K. Treatment for rheumatoid arthritis and the risk of hospitalization for pneumonia: Associations with prednisone, disease-modifying antirheumatic drugs, and anti-tumor necrosis factor therapy. *Arthritis Rheum* 2006;54:628-34.

How to cite this article: Samara E, Siasios I, Katsiardanis K, Liaptis E, Tsoleka K, Deretzi G. Brain abscess in a rheumatoid arthritis patient treated with leflunomide – A case presentation and review. *Surg Neurol Int* 2021;12:97.