

Functional medicine

## Adrenal hematoma following falling in a 5-year-old boy

Fateme Guitynavard, Seyed Saeed Tamehri Zadeh, Hossein Zabihi Mahmoudabadi,  
Seyed Mohammad Kazem Aghamir\*

Urology Research Center, Tehran University of Medical Sciences, Tehran, Iran



### ARTICLE INFO

#### Keywords:

Adrenal hemorrhage  
Adrenal glands  
Infections  
Abdominal pain

### ABSTRACT

There is scarcity of reports regarding adrenal hemorrhage secondary to blunt abdominal trauma, which is as a result of the location of the adrenal glands. Most adrenal injuries occur in the right gland solitary and they are not life-threatening. Hence, they can be treated with conservative actions. In this case report, we describe the history of a 5-year-old child with the history of falling and was diagnosed with adrenal hemorrhage. He did not need any surgical procedures and the outcome of conservative treatment was satisfactory.

### Introduction

Both adrenal glands, profoundly positioned in the retroperitoneal cavity, are enclosed by fat tissues and the fascia of Gerota, and due to that, adrenal injury following blunt trauma is scarce.<sup>1</sup> Tremendous improvements in computed tomography (CT) scan maintains a mandatory role in adrenal hemorrhage detection, which can be seen in 25% of patients with severe trauma injury.<sup>2</sup> Adrenal hemorrhage following blunt trauma in less than 10% of cases is bilateral and mostly occurred in the right adrenal gland.<sup>3</sup> Even though an injury of the adrenal gland is not necessarily a life-threatening condition itself, but shows that the trauma had a high-energy mechanism, which merits further examination for associated injuries.<sup>3</sup> Albeit adrenal lesions are not clinically of importance themselves, they can act as sources of infections, and also, bilateral adrenal hemorrhage may contribute to adrenal insufficiency.<sup>3</sup> Herein, we reported a case of a child who had referred to our institution with a falling accident and was suspected of adrenal hemorrhage.

### Case presentation

A 5-year-old child was admitted to the emergency department of Sina hospital with a history of falling from a height of about 4 m. Upon admission, no sign of loss of consciousness was detected and two main complaints of the patient were abdominal pain on the right side of the abdomen and high right forearm. The hemodynamic of the patient was virtually stable and no problem was found in his laboratory findings. Multiple fractures in the distal of the right radius were seen. To assess his abdominal pain, first, we performed focused abdominal sonography for

trauma and no signs of free fluid in the abdomen and pelvis, and kidney and bladder injury were discovered. The only finding was heteroechoic mass above the right kidney. Besides, no signs of hemothorax and pneumothorax were detected in the chest X-ray.

In order to evaluate the mass, a contrast-enhanced abdominopelvic CT scan was performed. A 16 mm × 25 mm hyperdense right adrenal mass with fat stranding of right adrenal was detected in the CT scan indicating adrenal hematoma (Figs. 1 and 2). We managed the hematoma conservatively and the response was satisfactory.

### Discussion

The incidence of adrenal hemorrhage following trauma owing to its non-specific symptoms is yet to be known. Since the number of patients with blunt trauma who have undergone CT scan is increasing, it has been shown that the incidence of posttraumatic adrenal gland injury varying from 2% to 3%<sup>3</sup> and also, in autopsy 25% of patients with severe injuries, adrenal hemorrhage was explored.<sup>1</sup> In patients with a history of trauma, hemorrhage in the right adrenal gland takes place twice more than the left one. Right and left adrenal gland injuries mainly accompany by the liver, ipsilateral kidney, pancreas, and spleen, respectively. A high proportion of patients diagnosed with adrenal hemorrhage following trauma are asymptomatic and in symptomatic ones, the symptoms are not specific. While bilateral adrenal hemorrhage is not a common condition, it has detrimental effects on patients' life in adults and may cause adrenal insufficiency, which can be deleterious.<sup>4</sup>

The precise mechanism behind adrenal hemorrhage in patients with trauma is not clear. The possible explanations for that are: 1. Rupture of

\* Corresponding author. Urology Research Center, Sina Hospital, Hassan Abad Sq, Imam Khomeini Ave, Tehran, Iran.

E-mail address: [mkaghmir@tums.ac.ir](mailto:mkaghmir@tums.ac.ir) (S.M. Kazem Aghamir).

<https://doi.org/10.1016/j.eucr.2020.101480>

Received 5 September 2020; Received in revised form 27 October 2020; Accepted 1 November 2020

Available online 2 November 2020

2214-4420/© 2020 Published by Elsevier Inc. This is an open access article under the CC BY-NC-ND license (<http://creativecommons.org/licenses/by-nc-nd/4.0/>).

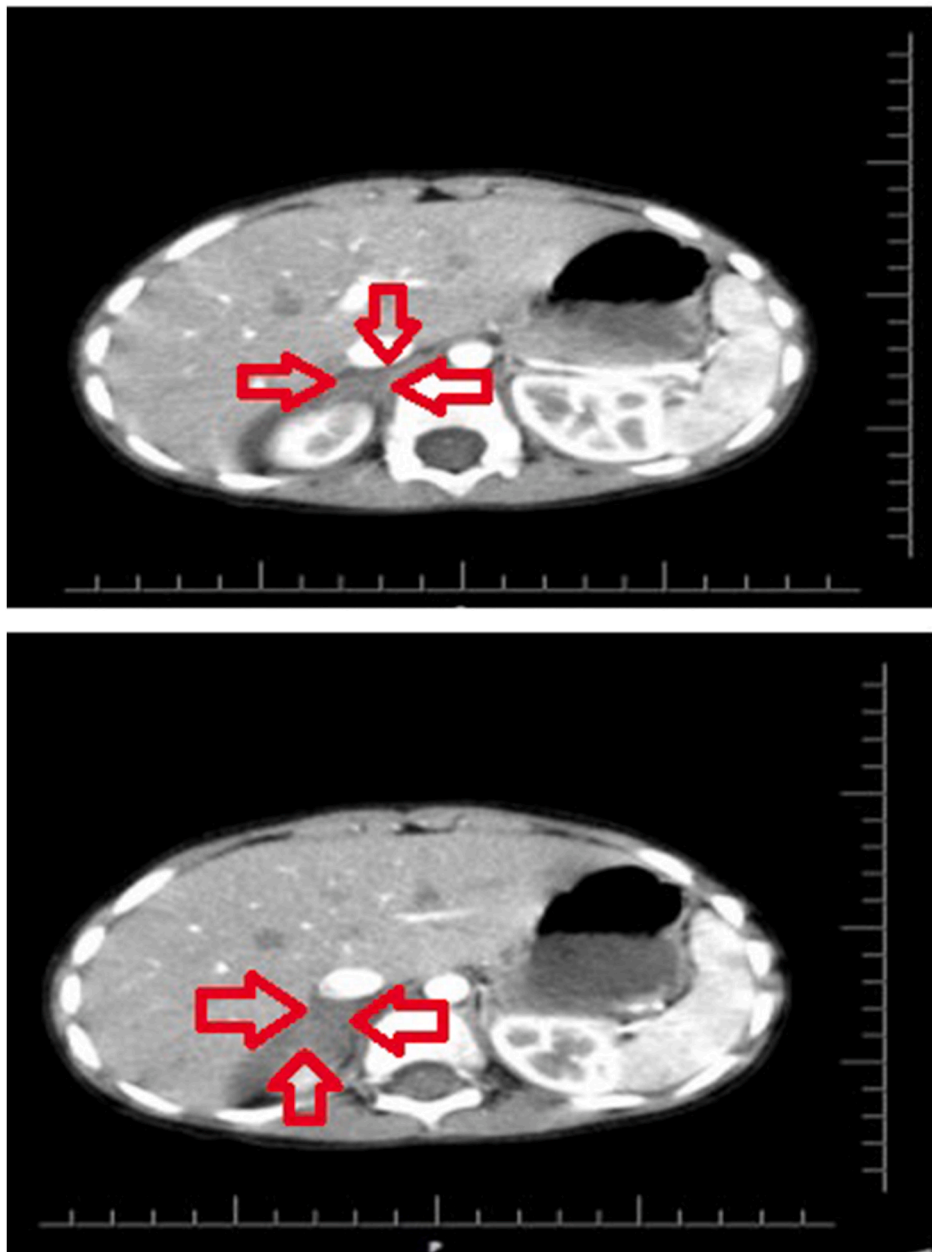


Fig. 1. Axial view of enhanced abdominal CT scan.

adrenal medulla veins 2. Rupture of juxtamedullary cortex as a result of unexpected compression and vena caval compression.<sup>4</sup> There is a logical hypothesis in support of the fact that the right adrenal gland is more vulnerable to damage. In contrast to the left adrenal gland vein, the vein of the right adrenal directly joins the inferior vena cava. Hence, compression of the inferior vena cava is responsible for an abrupt increase in the pressure of the intra-adrenal vein, which results in hemorrhage in the right adrenal gland.<sup>4</sup> In our case, adrenal hemorrhage has occurred in the right adrenal gland, and also the fracture of the radius was detected on the right side. So in the current case, it is possible that the right adrenal hemorrhage was due to compression of inferior vena cava.

Similar to most trauma centers, in the first step, we used focused abdominal sonography for trauma to assess the existence of free fluid of intraperitoneal in three areas including Morison's pouch, the left upper quadrant, and the pelvis. Fortunately, no free fluid was discovered. This method has several limitations in identifying the source of hemorrhage,

the severity of organ injury, and detecting free fluid less than 250 ml.

Currently, the best tool for the diagnosis of adrenal hemorrhage is contrast-enhanced CT scan, which also can identify the injuries of the other abdominal organs. The most prevalent findings of CT scan of adrenal hemorrhage are adrenal expanding hematoma with round or oval shape and diffuse irregular hemorrhage obliterating the adrenal gland.<sup>5</sup> It is of importance to note that unilateral adrenal hemorrhage should be distinguished from some conditions such as metastatic lesions, pheochromocytoma, and incidentaloma.

Choosing the best treatment for patients with adrenal hemorrhage depends on a variety of factors including, but not limited to, the grade of adrenal injury, the other adrenal gland situation, and overall condition of the patient. For most instances, adrenal hemorrhage is managed without any surgical interventions, however, surgical treatment should be considered if the active bleeding is obvious. In the present case, we treated the patient conservatively and no further intervention was warranted.

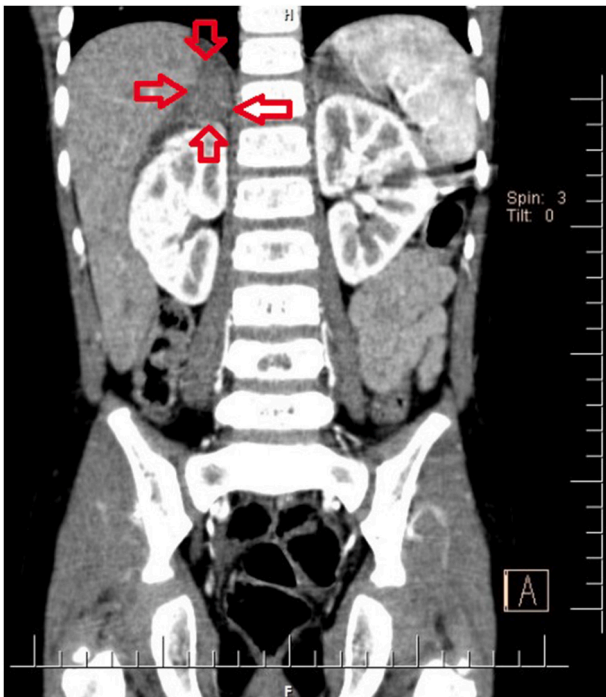


Fig. 2. Coronal view of abdominal CT scan.

## References

1. Ikeda O, Urata J, Araki Y, et al. Acute adrenal hemorrhage after blunt trauma. *Abdom Imag.* 2007;32(2):248–252.

2. Wilms G, Marchal G, Baert A, et al. CT and ultrasound features of post-traumatic adrenal hemorrhage. *J Comput Assist Tomogr.* 1987;11(1):112–115.

3. Sinelnikov AO, Abujudeh HH, Chan D, et al. CT manifestations of adrenal trauma: experience with 73 cases. *Emerg Radiol.* 2007;13(6):313–318.

4. Lee MJ, Kim G, Jang JE, et al. A case of traumatic bilateral adrenal hemorrhage mimicking bilateral adrenal adenomas. *Yeungnam University Journal of Medicine.* 2012;29(1):35–37.

5. Pinto A, Scaglione M, Pinto F, et al. Adrenal injuries: spectrum of CT findings. *Emerg Radiol.* 2003;10(1):30–33.