

Access this article online

Quick Response Code:



Website:
www.e-tjo.org

DOI:
10.4103/tjo.tjo_5_18

Transient cortical blindness in posterior reversible encephalopathy syndrome after postpartum eclampsia

Antonio Sesar¹, Ivan Cavar^{1,2}, Anita Pusic Sesar¹, Irena Sesar¹

Abstract:

Posterior reversible encephalopathy syndrome (PRES) is a clinical condition that can cause different ophthalmological and neurological symptoms. Preeclampsia toxemia or eclampsia is one of the leading causes of PRES. Herein, we present a study of a 35-year old woman who gave birth to healthy twins at 35 weeks of gestation by cesarean section because of threatened preterm delivery. On the 1st postoperative day, the woman developed a severe headache, arterial hypertension, tachycardia, generalized tonic-clonic seizures, and loss of consciousness that persisted for about 2 min. A provisional diagnosis of eclampsia was made, and the woman was then quickly transferred to the intensive care unit where she was treated with antihypertensive therapy, magnesium sulphate, and diazepam. Following stabilization of the general condition, the patient noticed sudden bilateral blindness. An ophthalmological examination revealed significant bilateral loss of vision at the level of insecure light perception, normal pupillary responses to a light stimulus, and normal fundus findings. On this basis, an ophthalmologist made the diagnosis to cortical blindness. Radiographic analysis showed an edematous change in the occipital and parietal brain regions, thus suggesting a diagnosis of PRES. In conclusion, cortical blindness is a clinically striking ophthalmic disorder that may occur in PRES associated with postpartum eclampsia.

Keywords:

Cortical blindness, eclampsia, posterior reversible encephalopathy syndrome

Introduction

Posterior reversible encephalopathy syndrome (PRES) represents a clinicoradiologic entity characterized by visual disturbances, headaches, seizures, severe hypertension, and altered mental status.^[1-4] PRES was first described in 1996 by Hinchey *et al.* and has since then been recognized in a growing number of pathological conditions such as preeclampsia toxemia (PET), eclampsia, hypertensive encephalopathy, autoimmune diseases, infection/sepsis, and the use of cytotoxic or immunosuppressive drugs.^[1,4-7] Among these, PET or eclampsia has been cited in the literature as the most common cause of PRES.^[3] PET is defined as a new onset

of hypertension and proteinuria that appears after the 20th week of gestation in a previously normotensive woman, and it occurs in 2%–3% of all pregnancies. This is a systemic disease characterized by impaired organ perfusion that occurs as a result of vasospasm and activation of the coagulation system.^[8] The occurrence of generalized seizures in women with preeclampsia without an alternatively known cause is defined as eclampsia. Approximately, half of the cases of eclampsia appear after childbirth.^[9]

Ophthalmic disorders that may occur in PRES associated with PET/eclampsia include cortical blindness, central retinal artery and vein occlusions, serious retinal detachment, retinal or vitreous hemorrhages, ischemic optic neuropathy,

This is an open access journal, and articles are distributed under the terms of the Creative Commons Attribution-NonCommercial-ShareAlike 4.0 License, which allows others to remix, tweak, and build upon the work non-commercially, as long as appropriate credit is given and the new creations are licensed under the identical terms.

For reprints contact: reprints@medknow.com

How to cite this article: Sesar A, Cavar I, Sesar AP, Sesar I. Transient cortical blindness in posterior reversible encephalopathy syndrome after postpartum eclampsia. Taiwan J Ophthalmol 2018;8:111-4.

¹Department of Ophthalmology, University Clinical Hospital Mostar,
²Department of Physiology, School of Medicine, University of Mostar, Mostar, Bosnia and Herzegovina

Address for correspondence:

Dr. Ivan Cavar,
Department of Physiology, School of Medicine, University of Mostar, Bijeli Brijeg bb, 88000 Mostar, Bosnia and Herzegovina.
E-mail: ivancavarswe@yahoo.com

Submission: 10-01-2018
Accepted: 05-04-2018

and Purtscher-like retinopathy.^[10] Clinical findings are not sufficiently specific to readily establish the diagnosis of PRES. However, magnetic resonance imaging (MRI) patterns are often characteristic and represent an essential component for the diagnosis of PRES. Brain lesions are usually located in the white matter, and sometimes, the overlying cortex may also be affected.^[11] Most often, the MRI displays abnormalities in the posterior brain regions, particularly in the occipital and parietal lobes.^[2] The pathogenesis of PRES is still not fully understood although it seems to be linked to the failure of autoregulation of the local blood flow and endothelial dysfunction.^[1,2] Timely diagnosis and treatment are of great importance for a good prognosis of the disease since any delay in this regard can lead to permanent neurological deficits and other complications.^[2]

This report presents the case of a woman with acute bilateral vision loss and radiological findings characteristic of PRES after giving birth by caesarean section.

Case Report

A 35-year old woman gave birth to healthy twins at 35 weeks of gestation by cesarean section because of threatened preterm delivery. It was her first pregnancy that began with *in vitro* fertilization. In her medical history, she had a facial nerve paresis without hypertension, cardiac diseases, vision abnormalities, or seizures. On the 1st postoperative day, she experienced a severe headache. Shortly thereafter, she developed generalized tonic-clonic seizures and loss of consciousness that persisted for about 2 min. Measurement of her arterial blood pressure showed a value of 195/110 mmHg with a heart rate of 120 beats/min. A provisional diagnosis of eclampsia was made, and the woman was quickly transferred to the intensive care unit where she was treated with antihypertensive therapy. The patient was given an intravenous (IV) infusion of magnesium sulphate (4 g), ebrantil (2 × 50 mg), and 20% manitol, and diazepam was given orally. Following stabilization of the general condition, the patient noticed bilateral vision loss. The complete blood count, liver function tests, clotting parameters, and electrocardiogram were normal. Urine analysis revealed proteinuria 2+. Other system examinations were normal. Following therapy, the seizures were not repeated, and the headache was alleviated. An ophthalmological examination revealed significant bilateral loss of vision at the level of insecure light perception, normal pupillary responses to a light stimulus, and normal fundus findings. On this basis, an ophthalmologist made the diagnosis to cortical blindness. Neurological examination showed mild right-sided facial nerve paresis, and there were no other neurological disorders.

A multislice computed tomography (MSCT) scan, without contrast, showed hypodensity of the posterior white matter, which, from its characteristics, corresponded with vasogenic edema [Figure 1]. A further MRI was carried out, and T2- and fluid-attenuated inversion recovery (FLAIR)-weighted images symmetrically displayed hyperintense signals in the white matter, predominantly in the parietal and occipital regions and at the junctions of vascular watershed zones of the brain [Figure 2a and b]. The aforementioned characteristics of the MRI confirmed and completed the MSCT findings in the sense that those changes are characteristic of vasogenic edema, which is typical for PRES.

After initial antihypertensive therapy, the patient's general condition stabilized, and she was moved to an obstetrics clinic. In the subsequent period, her blood pressure was stabilized using oral antihypertensive medication: enalapril maleate (10 mg twice daily) and methyldopa (500 mg three times a day). Human albumin, 20% (50 g), was dissolved in 500 ml of saline and then administered by IV to normalize the concentration of proteins in the plasma.

Follow-up ophthalmological examinations showed significant bilateral improvement of the visual function up to 1.0 of best-corrected visual acuity 5 days after the occurrence of eclampsia. Using a slit lamp, the findings from the anterior eye segment and the findings from the fundus were entirely normal. A visual field image (G Standard 07 White/White Top Dynamic) showed bilaterally expressed peripheral relative scotoma and depressed sensitivity of the paracentral left visual field. During the control examination, a neurologist confirmed the right-sided partial facial nerve paresis with no other neurological disturbances.

A follow-up MRI was also carried out, and this showed a significant regression of the edema with the persistence

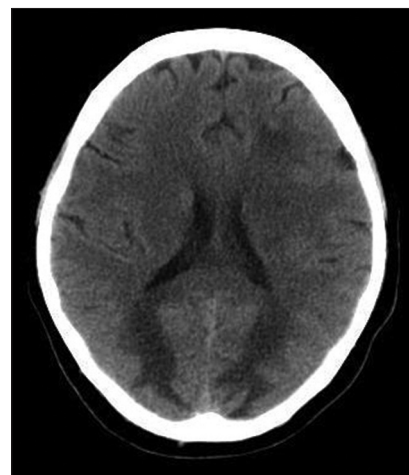


Figure 1: Multislice computed tomography finding in a 35-year old woman at the clinical onset

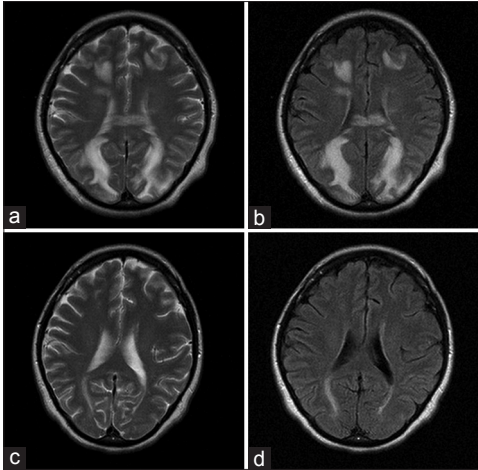


Figure 2: (a and b) T2- and fluid-attenuated inversion recovery-weighted imaging at the clinical onset. (c and d) Control T2- and fluid-attenuated inversion recovery-weighted imaging 8 days after the clinical onset

of discrete residual changes over the posterior horns of the side ventricles [Figure 2c and d]. Three days later, the woman was discharged from the clinic with a recommendation to take oral antihypertensive therapy (enalapril, 10 mg per day) and to continue with physical therapy for the paresis of the facial nerve.

Discussion

The pathogenesis of PRES is not fully understood and is still a matter of debate.^[11,12] On the basis of the results of neuroimaging studies in eclampsia, three theories have been advanced to explain the pathogenesis of hypertensive encephalopathy in PRES. First, the potential pathophysiologic mechanism underlying the development of cerebral lesions and seizures was attributed to vasogenic edema, which occurs as a result of hyperperfusion and/or toxins that cause endothelial injury and disrupt the blood–brain barrier.^[4,6,12–14] Severe hypertension leads to the expansion of cerebral blood vessels, which overcomes intrinsic myogenic vasoconstriction. The breakdown of autoregulation results in hyperperfusion and the subsequent extravasation of fluid into the interstitium of the brain tissue at the periphery of the arterial territories.^[7,15,16] This theory was confirmed by Zeeman *et al.* who showed that patients with PET/eclampsia develop a significant increase in the cerebral blood flow, which causes vasogenic edema.^[17] In addition, toxins directly damage the endothelial cells and thus increase the production of edema.^[12] Second, the concept that has been the most widely accepted among clinicians suggests that encephalopathy is the result of cerebral vasoconstriction in response to acute hypertension. This, in turn, results in a decreased blood flow and intra-arterial thrombosis, which eventually leads to cerebral ischemia and cytotoxic edema.^[15,18,19]

Third, in recent years, it has been suggested that the activation of the immune system that accompanies vasoconstriction contributes to delayed hypoperfusion and edema formation. This mechanism is mediated by the activation and trafficking of T-lymphocytes, as well as by the activation of endothelial cells.^[14]

PET/eclampsia is one of the leading causes of PRES.^[3] Cortical blindness is among the best-documented complications of PET/eclampsia and almost 15% of eclamptic women are affected. This is caused by a dysfunction in the visual pathway that conducts visual information from the lateral geniculate nucleus of the thalamus to the cerebral visual cortex. Therefore, the pupillary reflexes and ocular motility in our patient remained intact. An ophthalmoscopic fundus examination revealed no abnormalities, favoring the diagnosis of cortical blindness. Vasogenic edema is the main cause of cortical blindness. It would appear that the primary visual cortex in the occipital lobes is more susceptible to the breakdown of autoregulation and subsequent hyperperfusion, than other regions.^[10]

Early recognition of PRES is crucial for the timely application of therapy, which typically includes medications that lower blood pressure, act as an antiedematous, and interrupt tonic–clonic convulsions. When an early diagnosis and treatment of PRES is established, patients usually recover within a few weeks, as was the case with our patient. Except in cases of delayed and/or inadequate treatment of PRES, it is possible to develop secondary complications such as intracranial hemorrhage, cerebral ischemia, and status epilepticus.^[3,20] Clinical findings are not usually sufficiently specific, and the characteristics revealed in an MRI show that this is an essential component for the diagnosis of PRES. Typical lesions predominate in the posterior subcortical white matter, especially in the occipital and parietal lobes of the brain.^[1,2] Less common characteristics relate to the involvement of the anterior cerebral regions (frontal and/or temporal lobe), deep white matter, basal ganglia, and the brain stem, which can also be seen in the MRI.^[21] These lesions are hyperintense on the T2- and FLAIR-weighted images and are usually hypointense or isointense on diffusion-weighted images, indicating vasogenic edema.^[1,2]

Conclusion

PRES is a relatively rare condition that can occur as a result of numerous disorders and its clinical presentation may vary. Aside from the neurological disorders, one of the significant symptoms may be acute bilateral vision loss. Despite the typical neuroradiological findings in PRES, an ophthalmologist should be consulted to resolve visual disturbances in patients with PET/eclampsia.

Declaration of patient consent

The authors certify that they have obtained all appropriate patient consent forms. In the form the patient(s) has/have given his/her/their consent for his/her/their images and other clinical information to be reported in the journal. The patients understand that their names and initials will not be published and due efforts will be made to conceal their identity, but anonymity cannot be guaranteed.

Financial support and sponsorship

Nil.

Conflicts of interest

The authors declare that there are no conflicts of interests of this paper.

References

1. Lamy C, Oppenheim C, Méder JF, Mas JL. Neuroimaging in posterior reversible encephalopathy syndrome. *J Neuroimaging* 2004;14:89-96.
2. Staykov D, Schwab S. Posterior reversible encephalopathy syndrome. *Nervenarzt* 2012;83:1013-20.
3. Postma IR, Slager S, Kremer HP, de Groot JC, Zeeman GG. Long-term consequences of the posterior reversible encephalopathy syndrome in eclampsia and preeclampsia: A review of the obstetric and nonobstetric literature. *Obstet Gynecol Surv* 2014;69:287-300.
4. Nielsen LH, Grøn BS, Ovesen PG. Posterior reversible encephalopathy syndrome postpartum. *Clin Case Rep* 2015;3:266-70.
5. Hinchey J, Chaves C, Appignani B, Breen J, Pao L, Wang A, *et al.* A reversible posterior leukoencephalopathy syndrome. *N Engl J Med* 1996;334:494-500.
6. Bartynski WS. Posterior reversible encephalopathy syndrome, part 1: Fundamental imaging and clinical features. *AJNR Am J Neuroradiol* 2008;29:1036-42.
7. Richards CR, McMurray RC, Criman ET, Clark ME, Gillern S. An unusual presentation of a rare disease: Posterior reversible encephalopathy syndrome following abdominal sepsis. *J Surg Case Rep* 2016;2016. pii: rjw184.
8. Neligan PJ, Laffey JG. Clinical review: Special populations—Critical illness and pregnancy. *Crit Care* 2011;15:227.
9. Bo QY, Zhao XH, Yang X, Wang SJ. Reversible posterior encephalopathy syndrome associated with late onset postpartum eclampsia: A case report. *Exp Ther Med* 2016;12:1885-8.
10. Roos NM, Wiegman MJ, Jansonius NM, Zeeman GG. Visual disturbances in (pre) eclampsia. *Obstet Gynecol Surv* 2012;67:242-50.
11. Demirel I, Ozer AB, Bayar MK, Kavak SB. Anesthesia and intensive care management in a pregnant woman with PRES: A Case report. *Case Rep Anesthesiol* 2012;2012:745939.
12. McKinney AM, Short J, Truwit CL, McKinney ZJ, Kozak OS, SantaCruz KS, *et al.* Posterior reversible encephalopathy syndrome: Incidence of atypical regions of involvement and imaging findings. *AJR Am J Roentgenol* 2007;189:904-12.
13. Bartynski WS. Posterior reversible encephalopathy syndrome, part 2: Controversies surrounding pathophysiology of vasogenic edema. *AJNR Am J Neuroradiol* 2008;29:1043-9.
14. Buyukaslan H, Lok U, Gulacti U, Sogut O, Kaya H, Gokdemir T, *et al.* Posterior reversible encephalopathy syndrome during the peripartum period: Report of four cases and review of the literature. *Int J Clin Exp Med* 2015;8:1575-81.
15. Schwartz RB, Mulkern RV, Gudbjartsson H, Jolesz F. Diffusion-weighted MR imaging in hypertensive encephalopathy: Clues to pathogenesis. *AJNR Am J Neuroradiol* 1998;19:859-62.
16. Sekine T, Ikeda K, Hirayama T, Suzuki A, Iwasaki Y. Transient splenic lesion after recovery of cerebral vasoconstriction and posterior reversible encephalopathy syndrome: A case report of eclampsia. *Intern Med* 2012;51:1407-11.
17. Zeeman GG, Hatab M, Twickler DM. Maternal cerebral blood flow changes in pregnancy. *Am J Obstet Gynecol* 2003;189:968-72.
18. Trommer BL, Homer D, Mikhael MA. Cerebral vasospasm and eclampsia. *Stroke* 1988;19:326-9.
19. Truwit CL, Denaro CP, Lake JR, DeMarco T. MR imaging of reversible cyclosporin A-induced neurotoxicity. *AJNR Am J Neuroradiol* 1991;12:651-9.
20. Fugate JE, Claassen DO, Cloft HJ, Kallmes DF, Kozak OS, Rabinstein AA, *et al.* Posterior reversible encephalopathy syndrome: Associated clinical and radiologic findings. *Mayo Clin Proc* 2010;85:427-32.
21. Staykov D, Schwab S. Posterior reversible encephalopathy syndrome. *J Intensive Care Med* 2012;27:11-24.