

Effect of tunnel placements on clinical and magnetic resonance imaging findings 2 years after anterior cruciate ligament reconstruction using the double-bundle technique

Piia Suomalainen¹
Tommi Kiekara²
Anna-Stina Moisala¹
Antti Paakkala²
Pekka Kannus³
Timo Järvelä⁴

¹Division of Orthopaedics and Traumatology, Department of Trauma, Musculoskeletal Surgery and Rehabilitation, Tampere University Hospital, Tampere, ²Medical Imaging Centre, Tampere University Hospital, Tampere, ³Injury and Osteoporosis Research Center, UKK Institute, Tampere, ⁴Arthroscopic and Sports Medicine Center Omasairaala, Helsinki, Finland

Purpose: The purpose of the study reported here was to find out if the clinical and magnetic resonance imaging (MRI) findings of a reconstructed anterior cruciate ligament (ACL) have an association. Our hypothesis, which was based on the different functions of the ACL bundles, was that the visibility of the anteromedial graft would have an impact on anteroposterior stability, and the visibility of the posterolateral graft on rotational stability of the knee.

Methods: This study is a level II, prospective clinical and MRI study (NCT02000258). The study involved 75 patients. One experienced orthopedic surgeon performed all double-bundle ACL reconstructions. Two independent examiners made the clinical examinations at 2-year follow-up: clinical examination of the knee; KT-1000, International Knee Documentation Committee and Lysholm knee evaluation scores; and International Knee Documentation Committee functional score. The MRI evaluations were made by two musculoskeletal radiologists separately, and the means of these measurements were used.

Results: We found that the location of the graft in the tibia had an impact on the MRI visibility of the graft at 2-year follow-up. There were significantly more partially or totally invisible grafts if the insertion of the graft was more anterior in the tibia. No association was found between the clinical results and the graft locations.

Conclusion: Anterior graft location in the tibia can cause graft invisibility in the MRI 2 years after ACL reconstruction, but this has no effect on the clinical recovery of the patient.

Keywords: graft location, tibia, clinical recovery, anteroposterior stability, rotational stability, anteromedial graft, posterolateral graft

Introduction

The anatomy of the knee joint and the double-bundle (DB) structure of the anterior cruciate ligament (ACL) were described almost 200 years ago by the Weber brothers. Since then, there have been a variety of different anatomical studies, cadaveric and clinical, in which the anatomy of the ACL has been resolved thoroughly in the tibial and femoral sites.^{1,2} The anteromedial (AM) bundle of the ACL has been reported to function in all flexion angles of the knee and the posterolateral (PL) bundle in near extension. The PL bundle also acts as a restrictor for the rotational forces of the tibia.³

An ACL tear is a common sports injury and ACL reconstruction is of great interest. Nowadays, the DB reconstruction method is gaining popularity, since the traditional single-bundle method has been reported to result in residual rotational laxity

Correspondence: Piia Suomalainen
Division of Orthopaedics and Traumatology, Department of Trauma, Musculoskeletal Surgery and Rehabilitation, Tampere University Hospital, Teiskontie 35, 33520 Tampere, Finland
Tel +358 3 311 67773
Email piia.suomalainen@uta.fi

and has failed to prevent knee osteoarthritis (OA).⁴ Several prospective studies have compared single- and DB reconstruction methods. The latter seems to give better results and none of the studies has concluded that DB reconstruction would be inferior to its single-bundle (SB) counterpart.⁵⁻¹⁸

The best radiological method for visualizing ligaments of the knee is magnetic resonance imaging (MRI).¹⁹ Normal ACL is seen as a hypo-intense structure on T1- and T2-weighted sequences of the MRI.¹⁹ The reconstructed ACL graft can appear very different in successive MRIs, depending on when the MRI examination takes place following reconstruction, because the maturation process of the graft takes approximately 2 years.¹⁹ The MRI findings of both SB and DB ACL graft disruption includes the absence of intact graft fibers and T2 fluid signal intensity replacing the graft.¹⁹

The purpose of our study was to find out if the clinical and MRI findings of a reconstructed ACL have an association. Our hypothesis, which was based on the different functions of the ACL bundles, was that the visibility of the AM graft would have an impact on anteroposterior stability, and the visibility of the PL graft on the rotational stability of the knee.

Materials and methods

Patients

Patient recruitment (N=75) and baseline data collection were undertaken at our institute between March 2003 and February 2008. Inclusion criteria were: primary ACL reconstruction, closed growth plates, and absence of ligament injury to the opposite knee. All patients underwent a DB ACL reconstruction. There were 32 isolated ACL ruptures, 20 patients had medial meniscus ruptures, 19 lateral meniscus ruptures, and four patients had both menisci ruptured at the time of the surgery. Seven patients had their meniscus fixed with an endoscopic maneuver and 31 had partial resection. The remaining 37 patients had their meniscus left in situ. Sixty-one patients were able to be clinically examined and MRI was done of 64 at the 2-year follow-up. One patient went to revision ACL surgery, five patients had an ACL reconstruction to the contralateral knee, and the others were lost to follow-up due to long distance.

This prospective study was approved by the local ethics committee, and a written informed consent form was signed by every participant. One experienced orthopedic surgeon performed all ACL reconstructions.

Surgical technique of the DB ACL reconstruction

The surgical technique used has been described earlier in detail by Järvelä in 2007.⁹ In brief, a complete diagnostic

arthroscopy was performed first to detect any associated injuries – that is, meniscal ruptures and chondral lesions. Two hamstring grafts were harvested from each operated leg and each graft was doubled. The femoral tunnels were created through an accessory AM portal to insertion sites of the AM and PL bundles of the ACL at the lateral femoral condyle with a freehand technique as low and deep as possible. The tibial tunnels were made at the footprint on the tibia with the aid of a tibial guide. The grafts were inserted into the femur via tibia tunnels in a retrograde manner and fixed with bioabsorbable interference screws (Hexalon™, Inion Co, Tampere, Finland).

Rehabilitation

All patients went through the same rehabilitation. Full weight-bearing, full range-of-motion, and closed-chain exercises were allowed immediately postoperatively and no rehabilitation brace was used. Crutches were used for 3 to 4 weeks. Cycling was allowed with an ergometer bicycle at 4 weeks, running at 3 months, and pivoting sports at 6 months postoperatively, if the patient had full functional stability.

Clinical 2-year evaluations

Two independent examiners evaluated the patients at the 2-year follow-up. The evaluation methods were: clinical examination of the knee, KT-1000 arthrometric measurement, and International Knee Documentation Committee (IKDC) and Lysholm knee evaluation scores. The IKDC functional score was used to evaluate knee function in daily activities.

MRI evaluation

MRI evaluations were made with a 1.5T Signa® Excite™ HD imager (GE Healthcare, Little Chalfont, UK) by use of an eight-channel receiver/transmitter extremity coil. The mean time between the knee operation and MRI was 22 months. MRI sequences were sagittal T1-weighted, proton-density-weighted, and T2-weighted fast-spin-echo (FSE) images with 4 mm slice and 1 mm gap, coronal T1-weighted and fat-saturated T2-weighted FSE images with 4 mm slice and 1 mm gap, axial fat-saturated proton-density FSE images with 4 mm slice and 1 mm gap, and oblique sagittal and oblique coronal T1 FSE images along the AM graft plane with 3 mm slice and 0.3 mm gap. Image interpretation was done with the Impax DS 3000 workstation (Agfa HealthCare, Mortsel, Belgium) by two musculoskeletal radiologists separately and the means of these measurements were used. The radiologists were unaware of the patients' clinical data.

The measurements of the graft location from MRI were made using the method reported by Lorenz et al, although they used computed tomography in their study.²⁰ The use of the modified quadrant method with MRI has been recently described in detail.²¹ In brief, first the centers of the tunnels were measured from sagittal images referring to Blumensaat's line and to the posterior femoral condyle (Figure 1). These were then divided by the maximum diameters of the femoral condyle parallel to and perpendicular to Blumensaat's line. On the tibial side, the centers of the tunnels were measured from the anterior edge of the tibial plateau and then divided by the maximum diameter of the plateau, which was measured from the sagittal view (Figure 2).

Graft visibility was evaluated with MRI. A graft was considered visible when intact graft fibers were seen, partially visible when only few graft fibers were seen (Figure 3), and invisible when no graft fibers were seen (Figure 4).¹⁵

Statistics

SPSS software (v 11.0; SPSS Inc., Chicago, IL, USA) was used to perform the statistical analysis. The calculations of the differences between the means were done by analysis of variance and paired sample *t*-test, and those of frequencies, by the chi-squared test. The significance level was set at $P < 0.05$.

Results

There were 56 male and 19 female participants in this study with a mean age of 32 years (standard deviation [SD] 10) and mean height and weight of 177 cm (SD 9) and 82 kg (SD 16),

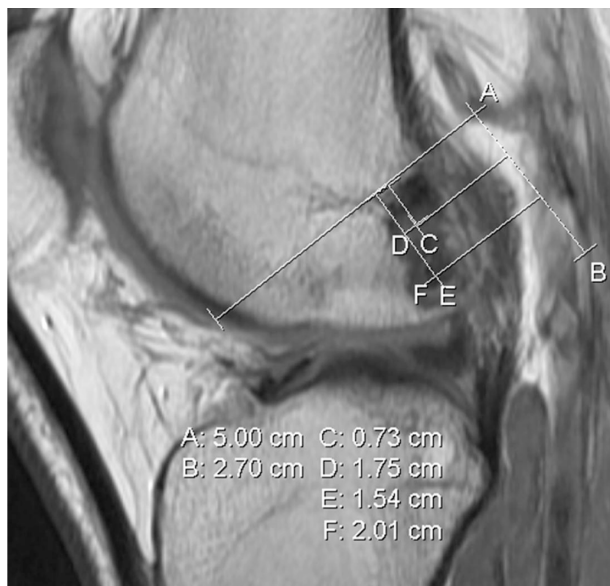

Figure 1 The maximum diameter of the femoral condyle was measured from the sagittal images parallel to and perpendicular to Blumensaat's line in millimeters (A, B) and the tunnel locations in the femur were measured from their own plane (FE, DC).

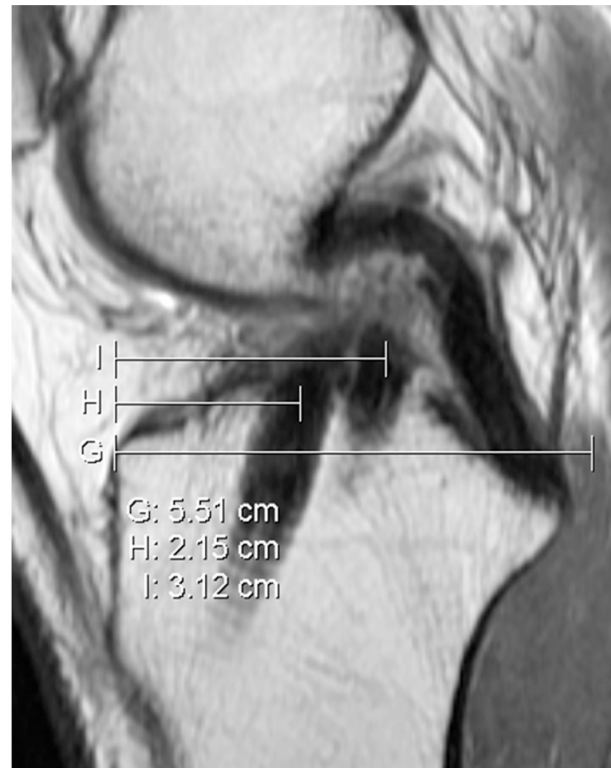

Figure 2 The maximum diameter of the tibia was measured from the sagittal images in millimeters (G) and the centers of the tunnels were determined from the anterior wall of the tibia (H, I).

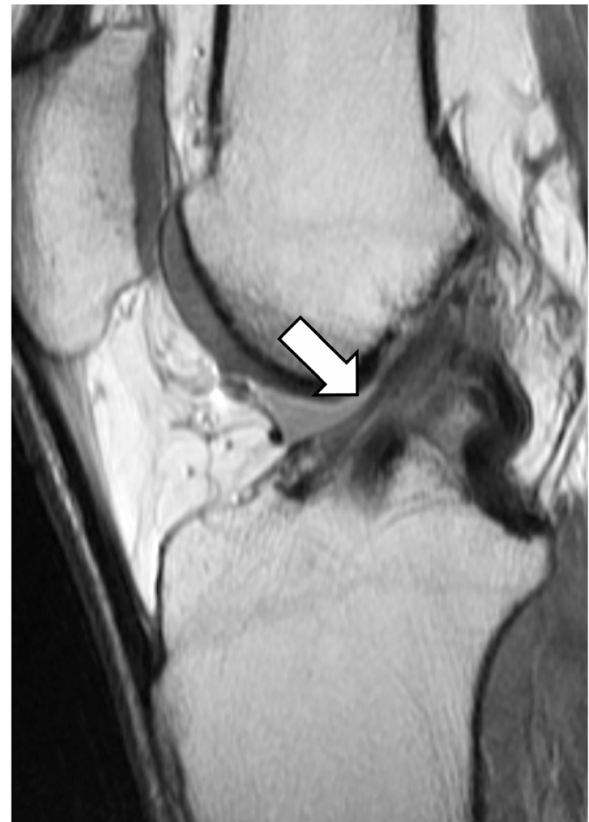

Figure 3 The arrow indicates a partially visible anteromedial graft in sagittal proton-density magnetic resonance imaging.

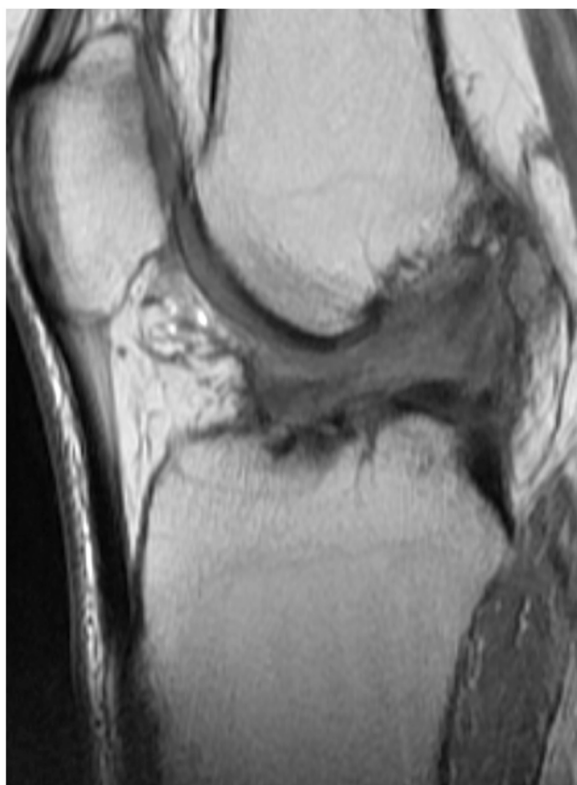


Figure 4 Both grafts invisible in sagittal proton-density magnetic resonance imaging.

respectively. The mean operation time was 73 minutes (SD 16) and follow-up 25 months (SD 2).

The first finding in this DB ACL reconstruction study was that the location of the ACL graft in the tibia had an impact on the MRI visibility of the graft at 2-year follow-up. The more anterior graft locations in either of the DB grafts in the tibia was associated with partial graft visibility or invisibility on MRI (Table 1). In contrast, there was no such association between the clinical results and the MRI-based graft locations in either the tibia or femur (Table 2) and no association between the clinical results and graft visibility (Table 3).

There was a statistically significant difference regarding KT-1000, IKDC function, and Lysholm scores when comparing pre- and postoperative status of the operated knees, with the results favoring the follow-up situation ($P < 0.001$; Table 4). Preoperatively, the IKDC final score was abnormal in 72 patients and severely abnormal in three patients. There was a clear shift to a more normal situation at 2-year follow-up, when there were 26 normal, 23 nearly normal, 11 abnormal, and two severely abnormal knees ($P < 0.001$; Table 4). One of the patients with a severely abnormal knee had had an injury just before the examination and the effusion in their knee caused the limited range of motion, although they were otherwise satisfied with their knee. The other patient

Table 1 Relationship between the tunnel placements of the anterior cruciate ligament reconstructions and visibility of the graft as evaluated by magnetic resonance imaging at 2-year follow-up

| Tunnel placement | Visibility of the graft | | | Significance |
|-------------------------------------|-------------------------|-------------------|-----------|--------------|
| | Intact | Partially visible | Invisible | |
| Anteromedial graft | N=59 | N=2 | N=3 | |
| Tibia | | | | |
| From anterior ^a | 43 (6) | 34 (1) | 36 (7) | $P=0.017$ |
| Femur | | | | |
| From Blumensaat's line ^b | 19 (6) | 24 (2) | 21 (10) | NS |
| From posterior ^a | 28 (5) | 28 (9) | 31 (4) | NS |
| Posterolateral graft | N=51 | N=9 | N=4 | |
| Tibia | | | | |
| From anterior ^a | 57 (6) | 52 (5) | 51 (6) | $P=0.012$ |
| Femur | | | | |
| From Blumensaat's line ^b | 44 (6) | 43 (7) | 43 (7) | NS |
| From posterior ^a | 42 (8) | 47 (8) | 43 (9) | NS |

Notes: Data are presented as mean (standard deviation) unless otherwise specified; ^apercentages from the total length of the tibial or femoral condyle; ^bpercentages from the total length of the condyle from Blumensaat's line to the distal cortex of the femoral condyle.

Abbreviation: NS, not significant.

had already had degenerative changes and a limited range of motion preoperatively, and their status remained similar after the ACL reconstruction, with no improvement seen.

Discussion

The first finding in our DB ACL reconstruction study with 2-year results was that there were statistically more partially visible and totally invisible grafts where the grafts were more anterior in the tibia, as measured by MRI. This was seen in the AM ($P=0.017$) and PL grafts ($P=0.012$). One reason for this invisibility problem may be minor roof impingement, which can occur if the graft is located too anteriorly in the tibia. However, there was no association between graft placement and 2-year clinical observations, and the grafts were in the correct anatomical position based on the MRI measurements in the tibia as well as in the femur. In contrast, Hatayama et al found in their DB ACL study that those grafts placed more anteriorly in the tibia resulted in knees more stable in the anteroposterior plane.²² However, when they measured the graft placements 1 year postoperatively, they used plain X-ray, a method not as precise as MRI.

The statistical difference in the tibia graft insertions probably has no clinical relevance, since the difference between the graft insertion sites in the tibia was approximately 4 mm, but the impingement may interfere with the graft maturation process, which usually takes approximately 2 years.²³ Within this time, the graft goes through ligamentization,

Table 2 Relationship between the tunnel placements of the anterior cruciate ligament reconstructions (as evaluated by magnetic resonance imaging) and the rotational and the anterior stability of the knee (as evaluated by the pivot-shift test and the side-to-side difference in the KT-1000 measurement, respectively) at 2-year follow-up

| Pivot shift | Normal (N=41) | Nearly normal (N=17) | Abnormal ^c (N=3) | Significance |
|---|--------------------------|--------------------------|--------------------------------------|---------------------|
| Tunnel placement | | | | |
| Tibia | | | | |
| AM tunnel from anterior ^a | 42 (6) | 42 (7) | 41 (8) | NS |
| PL tunnel from anterior ^a | 56 (6) | 56 (6) | 59 (3) | NS |
| Femur | | | | |
| AM tunnel from Blumensaat's line ^b | 19 (6) | 19 (7) | 18 (8) | NS |
| PL tunnel from Blumensaat's line ^b | 42 (8) | 42 (9) | 45 (3) | NS |
| AM tunnel from posterior ^a | 28 (6) | 27 (3) | 31 (7) | NS |
| PL tunnel from posterior ^a | 44 (7) | 44 (4) | 47 (4) | NS |
| KT-1000 difference | 0–2 mm (N=40) | 3–5 mm (N=12) | 6–10 mm^d (N=9) | Significance |
| Tunnel placement | | | | |
| Tibia | | | | |
| AM tunnel from anterior ^a | 42 (7) | 42 (5) | 42 (3) | NS |
| PL tunnel from anterior ^a | 56 (6) | 58 (4) | 56 (4) | NS |
| Femur | | | | |
| AM tunnel from Blumensaat's line ^b | 19 (6) | 20 (7) | 17 (4) | NS |
| PL tunnel from Blumensaat's line ^b | 43 (8) | 43 (9) | 41 (6) | NS |
| AM tunnel from posterior ^a | 28 (6) | 28 (5) | 26 (4) | NS |
| PL tunnel from posterior ^a | 44 (6) | 46 (6) | 43 (7) | NS |

Notes: Data are presented as mean (standard deviation) unless otherwise specified; ^apercentages from the total length of the tibial or femoral condyle; ^bpercentages from the total length of the condyle from Blumensaat's line to the distal cortex of the femoral condyle; ^cno severely abnormal knees were found in the pivot-shift test; ^dno patient had more than 10 mm difference in the KT-1000 measurements.

Abbreviations: AM, anteromedial; NS, not significant; PL, posterolateral.

during which the graft receives neosynovium and is revascularized.

In our study, the clinical measurements and knee scores were all significantly better at the 2-year follow-up than preoperatively. In addition, there was no association between graft visibility and the 2-year clinical status of the knees in either

Table 3 Relationship between the visibility of the anterior cruciate ligament graft (as evaluated by magnetic resonance imaging) and the rotational and anterior stability of the knee (as evaluated by the pivot-shift test and the side-to-side difference in the KT-1000 measurement, respectively) at 2-year follow-up

| Pivot shift | Normal | Nearly normal | Abnormal | Significance |
|-------------------------|--------|---------------|----------|--------------|
| Visibility of the graft | | | | |
| PL graft | | | | |
| Intact | 34 | 14 | 3 | NS |
| Partially visible | 6 | 3 | 0 | NS |
| Invisible | 1 | 0 | 0 | NS |
| KT-1000, mm | 0–2 | 3–5 | 6–10 | |
| Visibility of the graft | | | | |
| AM graft | | | | |
| Intact | 38 | 12 | 9 | NS |
| Partially visible | 2 | 0 | 0 | NS |
| Invisible | 0 | 0 | 0 | NS |

Abbreviations: AM, anteromedial; NS, not significant; PL, posterolateral.

the anteroposterior or rotational planes, as evaluated with the KT-1000 and pivot-shift maneuvers. This was also the case in a study by Saupe et al.²⁴ In their study, they proposed that the heterogenous signal intensity in T2-weighted sequences would be due to degenerative changes. Their MRI investigations were made an average of 80 months postoperatively, so the ligamentization process should have been already over.

As far as we are aware, there are a total of 14 prospective and randomized clinical studies on DB ACL surgery,

Table 4 Clinical and functional findings preoperatively and at 2-year follow-up

| Finding | Preoperatively (N=75) | At 2-year follow-up (N=61) | Significance |
|-------------------------|--------------------------|----------------------------------|--------------|
| KT-1000 difference, mm | 4.3 (1.7) | 1.9 (3.0) | $P < 0.001$ |
| Function score | 4 (2) | 8 (1) | $P < 0.001$ |
| Lysholm score | 69 (17) | 89 (13) | $P < 0.001$ |
| IKDC final score, n (%) | | | |
| Normal | 0 (0) | 26 (43) | $P < 0.001$ |
| Nearly normal | 0 (0) | 23 (38) | $P < 0.001$ |
| Abnormal | 72 (96) | 10 (16) | $P < 0.001$ |
| Severely abnormal | 3 (4) | 2 (3) | |

Note: Data are presented as mean (standard deviation) unless otherwise specified.

Abbreviation: IKDC, International Knee Documentation Committee.

but none of them has clearly focused on graft location and the relevance of this. Most have observed that the DB method produces more stable knees in the rotational^{8–11,13,18} or anteroposterior plane.^{6,8,11,13,17} Some studies have additionally found that their DB ACL reconstruction group had fewer notchplasties⁵ and better visual analog scale⁶ and knee scores than its SB counterpart.^{6,7,13,17,18} Suomalainen et al^{15,16} reported that their DB group had a lower reoperation rate due to graft failure and, in their 8-year study, Zaffagnini et al¹⁸ also reported a lower reoperation rate in their DB group, although in that study there were also knee problems other than graft ruptures. They concluded that the DB method resulted in less OA and a better range of motion than the SB ACL reconstruction method. Few studies have not found any difference between SB and DB groups,^{12,14} and none of the randomized controlled trials concluded that the DB method would be inferior to SB ACL reconstruction.²⁵

In contrast to our data, Sonoda et al found in their DB ACL study that MRI findings and clinical measurements have a correlation.²⁶ They reported that a higher signal intensity in the AM bundle correlated with anterior laxity and, in the PL bundle, with rotational laxity. Their results were at 1-year follow-up, which may have had an impact on the data, since the grafts were probably still in the maturation phase.

One limitation of our current study is that the integrity of the ACL grafts was not affirmed by arthroscopy. The reason for this was that the patients found to have invisible grafts at MRI had stable knees, thus the need for a re-arthroscopy was not indicated. Another limitation of our study is that the MRI was done with a 1.5T imager using conventional orthogonal sequences with 4 mm slice thickness. Tunnel location measurement would have been easier with thin slices or 3D multiplanar-reconstruction sequences. However, our imaging protocol is also recommended for ACL graft evaluation making it suitable for clinical work with commonly used 1.5T MR scanners. The strengths of our study are its prospective study design and independent examiners. The two radiologists who interpreted the images were also blinded to the clinical status.

Conclusion

The anterior graft location in the tibia can cause graft invisibility in postoperative MRI at 2-year follow-up, but this does not affect the clinical recovery of the patient.

Disclosure

The authors declare no conflicts of interest in this work.

References

1. Siebold R, Ellert T, Metz S, Metz J. Femoral insertions of the anteromedial and posterolateral bundles of the anterior cruciate ligament: morphometry and arthroscopic orientation models for double-bundle bone tunnel placement – a cadaver study. *Arthroscopy*. 2008;24(5):585–592.
2. Siebold R, Ellert T, Metz S, Metz J. Tibial insertions of the anteromedial and posterolateral bundles of the anterior cruciate ligament: morphometry, arthroscopic landmarks, and orientation model for bone tunnel placement. *Arthroscopy*. 2008;24(2):154–161.
3. Zantop T, Herbort M, Raschke MJ, Fu FH, Petersen W. The role of the anteromedial and posterolateral bundles of the anterior cruciate ligament in anterior tibial translation and internal rotation. *Am J Sports Med*. 2007;35(2):223–227.
4. Lohmander LS, Englund PM, Dahl LL, Roos EM. The long-term consequence of anterior cruciate ligament and meniscus injuries: osteoarthritis. *Am J Sports Med*. 2007;35(10):1756–1769.
5. Adachi N, Ochi M, Uchio Y, Iwasa J, Kuriwaka M, Ito Y. Reconstruction of the anterior cruciate ligament. Single- versus double-bundle multistranded hamstring tendons. *J Bone Joint Surg Br*. 2004;86(4):515–520.
6. Aglietti P, Giron F, Losco M, Cuomo P, Ciardullo A, Mondanelli N. Comparison between single- and double-bundle anterior cruciate ligament reconstruction: a prospective, randomized, single-blinded clinical trial. *Am J Sports Med*. 2010;38(1):25–34.
7. Hussein M, van Eck CF, Cretnik A, Dinevski D, Fu FH. Prospective randomized clinical evaluation of conventional single-bundle, anatomic single-bundle, and anatomic double-bundle anterior cruciate ligament reconstruction: 281 cases with 3- to 5-year follow-up. *Am J Sports Med*. 2012;40(3):512–520.
8. Ibrahim SA, Hamido F, Al Misfer AK, Mahgoob A, Ghafar SA, Alhran H. Anterior cruciate ligament reconstruction using autologous hamstring double bundle graft compared with single bundle procedures. *J Bone Joint Surg Br*. 2009;91(10):1310–1315.
9. Järvelä T. Double-bundle versus single-bundle anterior cruciate ligament reconstruction: a prospective, randomized clinical study. *Knee Surg Sports Traumatol Arthrosc*. 2007;15(5):500–507.
10. Järvelä T, Moisala AS, Sihvonen R, Järvelä S, Kannus P, Järvinen M. Double-bundle anterior cruciate ligament reconstruction using hamstring autografts and bioabsorbable interference screw fixation: prospective, randomized, clinical study with 2-year results. *Am J Sports Med*. 2008;36(2):290–297.
11. Muneta T, Koga H, Mochizuki T, et al. A prospective randomized study of 4-strand semitendinosus tendon anterior cruciate ligament reconstruction comparing single-bundle and double-bundle techniques. *Arthroscopy*. 2007;23(6):618–628.
12. Sastre S, Popescu D, Núñez M, Pomes J, Tomas X, Peidro L. Double-bundle versus single-bundle ACL reconstruction using the horizontal femoral position: a prospective, randomized study. *Knee Surg Sports Traumatol Arthrosc*. 2010;18(1):32–36.
13. Siebold R, Dehler C, Ellert T. Prospective randomized comparison of double-bundle versus single-bundle anterior cruciate ligament reconstruction. *Arthroscopy*. 2008;24(2):137–145.
14. Streich NA, Friedrich K, Gotterbarm T, Schmitt H. Reconstruction of the ACL with a semitendinosus tendon graft: a prospective randomized single blinded comparison of double-bundle versus single-bundle technique in male athletes. *Knee Surg Sports Traumatol Arthrosc*. 2008;16(3):232–238.
15. Suomalainen P, Moisala AS, Paakkala A, Kannus P, Järvelä T. Double-bundle versus single-bundle anterior cruciate ligament reconstruction: randomized clinical and magnetic resonance imaging study with 2-year follow-up. *Am J Sports Med*. 2011;39(8):1615–1622.
16. Suomalainen P, Järvelä T, Paakkala A, Kannus P, Järvinen M. Double-bundle versus single-bundle anterior cruciate ligament reconstruction: a prospective randomized study with 5-year results. *Am J Sports Med*. 2012;40(7):1511–1518.

17. Zaffagnini S, Bruni D, Russo A, et al. ST/G ACL reconstruction: double strand plus extra-articular sling vs double bundle, randomized study at 3-year follow-up. *Scand J Med Sci Sports*. 2008;18(5):573–581.
18. Zaffagnini S, Bruni D, Marcheggiani Muccioli GM, et al. Single-bundle patellar tendon versus non-anatomical double-bundle hamstrings ACL reconstruction: a prospective randomized study at 8-year minimum follow-up. *Knee Surg Sports Traumatol Arthrosc*. 2011;19(3):390–397.
19. Casagrande BU, Maxwell NJ, Kavanagh EC, Towers JD, Shen W, Fu FH. Normal appearance and complications of double-bundle and selective-bundle anterior cruciate ligament reconstructions using optimal MRI techniques. *AJR Am J Roentgenol*. 2009;192(5):1407–1415.
20. Lorenz S, Elser F, Mitterer M, Obst T, Imhoff AB. Radiologic evaluation of the insertion sites of the 2 functional bundles of the anterior cruciate ligament using 3-dimensional computed tomography. *Am J Sports Med*. 2009;37(12):2368–2376.
21. Kiekara T, Järvelä T, Huhtala H, Paakkala A. MRI evaluation of the four tunnels of double-bundle ACL reconstruction. *Acta Radiol*. 2014;55(5):579–588.
22. Hatayama K, Terauchi M, Saito K, Higuchi H, Yanagisawa S, Takagishi K. The importance of tibial tunnel placement in anatomic double-bundle anterior cruciate ligament reconstruction. *Arthroscopy*. 2013;29(6):1072–1078.
23. Miller TT. MR imaging of the knee. *Sports Med Arthrosc*. 2009;17(1):56–67.
24. Saupé N, White LM, Chiavaras MM, et al. Anterior cruciate ligament reconstruction grafts: MR imaging features at long-term follow-up – correlation with functional and clinical evaluation. *Radiology*. 2008;249(2):581–590.
25. Suomalainen P, Kannus P, Järvelä T. Double-bundle anterior cruciate ligament reconstruction: a review of literature. *Int Orthop*. 2013;37(2):227–232.
26. Sonoda M, Morikawa T, Tsuchiya K, Moriya H. Correlation between knee laxity and graft appearance on magnetic resonance imaging after double-bundle hamstring graft anterior cruciate ligament reconstruction. *Am J Sports Med*. 2007;35(6):936–942.

Open Access Journal of Sports Medicine

Publish your work in this journal

Open Access Journal of Sports Medicine is an international, peer-reviewed, open access journal publishing original research, reports, reviews and commentaries on all areas of sports medicine. The manuscript management system is completely online and includes a very quick and fair peer-review system.

Submit your manuscript here: <http://www.dovepress.com/open-access-journal-of-sports-medicine-journal>

Dovepress

Visit <http://www.dovepress.com/testimonials.php> to read real quotes from published authors.