

# Randomized Controlled Trial of Cholestyramine and Hydrotalcite to Eliminate Bile for Capsule Endoscopy

Chen Hong-Bin, Huang Yue, Huang Chun, Xiao Shu-Ping, Zhang Yue, Li Xiao-Lin<sup>1</sup>

Department of Gastroenterology, Sanming First Hospital Affiliated to Fujian Medical University, Sanming,  
<sup>1</sup>Department of Cardiology, Fu Wai Hospital, Chinese Academy of Medical Sciences, Peking Union Medical College, Peking, China

## Address for correspondence:

Prof. Huang Yue,  
Department of Gastroenterology, Sanming First Hospital Affiliated to Fujian Medical University, Sanming - 365 000, China.  
E-mail: huangkeji2008@sina.cn

## ABSTRACT

**Background/Aims:** Bile is the main cause of poor bowel preparation for capsule endoscopy (CE). We aimed to determine whether cholestyramine and hydrotalcite can eliminate bile in the bowel. **Patients and Methods:** Patients undergoing CE were randomized into two groups. Group A patients ( $n = 75$ ) received 250 mL 20% mannitol and 1 L 0.9% saline orally at 20:00 hours on the day before and at 05:00 hours on the day of CE and 20 mL simethicone 30 min before CE. Group B patients ( $n = 73$ ) were treated identically, except for taking oral cholestyramine and hydrotalcite, starting 3 days before CE. Greenish luminal contents were assessed by four tissue color bar segments using Color Area Statistics software. Bowel cleanliness was evaluated by visualized area percentage assessment of cleansing (AAC) score. **Result:** Bowel cleanliness (82.7% [62/75] vs 46.6% [34/73];  $\chi^2 = 14.596$ ,  $P = 0.000$ ). and detected greenish luminal contents (20.0% [15/75] vs 8.2% [6/73];  $\chi^2 = 4.217$ ,  $P = 0.040$ ) were significantly greater in Group A than in Group B. Greenish luminal contents in the two groups differed significantly in the captured small-bowel ( $t = -13.74$ ,  $P = 0.000$ ) segments and proximal small-bowel ( $t = -0.7365$ ,  $P = 0.000$ ) segments, but not for the distal small-bowel ( $t = -0.552$ ,  $P = 0.581$ ) segments. **Conclusions:** Cholestyramine and hydrotalcite were ineffective in eliminating bile and improving small-bowel preparation.

**Key Words:** Bile, capsule endoscopy, cholestyramine, hydrotalcite, small-bowel cleansing, small-bowel preparation

Received: 17.02.2015, Accepted: 11.04.2015

**How to cite this article:** Hong-Bin C, Yue H, Chun H, Shu-Ping X, Yue Z, Xiao-Lin L. Randomized controlled trial of cholestyramine and hydrotalcite to eliminate bile for capsule endoscopy. Saudi J Gastroenterol 2016;22:122-6.

Capsule endoscopy (CE) has enabled the noninvasive, painless, and effective evaluation of the digestive track.<sup>[1-3]</sup> The diagnostic yield of this novel method was shown to be greater than that of other radiological and endoscopic techniques owing to its direct visualization of the mucosa of the small intestine.<sup>[4-8]</sup> However, its diagnostic yield may be reduced by a decrease in visualization of the wall, especially owing to the presence of bile, bubbles, opaque mucus, food debris, and fecal residue in the distal small intestine.<sup>[9-12]</sup> Visualization may be enhanced by bowel preparations that include laxatives (such as polyethylene glycol, magnesium sulfate, sodium phosphate, or mannitol) and a defoaming

agent (simethicone), as well as by prokinetics and postural maneuvers.<sup>[13-16]</sup> Few methods, however, are currently available to eliminate bile during bowel preparation for CE. This study evaluated the ability of cholestyramine and hydrotalcite to eliminate bile, reducing its effects in the small bowel, and to enhance small-bowel cleaning and preparation, thus improving the diagnostic success rate of CE.

## PATIENTS AND METHODS

### Patients

This single-center, prospective, single-blind, parallel, randomized controlled trial conformed to the 1995 Declaration of Helsinki and was approved by the Ethics Committee of Sanming First Hospital. This study was registered on May 31, 2012, in the Chinese Clinical Trial Register (ChiCTR) with a test ID of ChiCTR-DDT-12002211. All patients from June 2012 to August 2014 who were enrolled in the study because of suspected small-bowel disease were randomly allocated into

Access this article online	
Quick Response Code: 	Website: <a href="http://www.saudijgastro.com">www.saudijgastro.com</a>
	DOI: 10.4103/1319-3767.167185

two groups using computer-generated random numbers. Informed consent was obtained from all patients.

Patients were excluded if they presented with known or suspected small-bowel obstruction or stricture; chronic renal, hepatic or cardiac failure; pregnancy; swallowing disorders; history of gastrointestinal or abdominal surgery; use of antispasmodic, analgesic or prokinetic drugs; thyroid disease; or diabetes mellitus. Patients with impaired intestinal motility were also excluded, since this may affect enteric cleansing.

### Study design

Patients randomized to Group A ingested 250 mL 20% mannitol and 1 L 0.9% saline orally at 20:00 h on the day before CE and at 05:00 hours on the day of the procedure, as well as 20 mL oral simethicone (Espumisan; Berlin-Chemie, Germany, 40 mg/mL) and 200 mL water 30 min before CE. Patients randomized to Group B were treated similarly, as well as taking 8 g cholestyramine (Nanjing Life Care Pharmaceutical Co., Ltd., China) and 1.0 g hydrotalcite (Talcid, Bayer Pharmaceutical Ltd., Germany) orally three times per day for 3 days before CE. All patients in both groups abstained from solid food the day before the procedure. After swallowing the capsule, patients were not allowed to drink clear fluids for 2 h and were permitted a light meal after 4 h. Adverse events were recorded.

The OMOM capsule endoscopy system (Chongqing Jinshan Science and Technology Group, China) consists of four main parts: A smart capsule, an image recorder jacket, a portable real-time monitor, and a computer workstation. Each OMOM capsule has 14 receiver elements placed close to the surface of the abdomen and waist in the recorder jacket. The duration of the battery of the OMOM capsule is about 10 h. Images were captured using a charge-coupled device. After ingesting the capsule with a small amount of water, patients were allowed to go about their daily activities. Nine to 10 hours after ingestion, the recorder was disconnected and the sensors removed. The recorded digital information was downloaded to the computer, and images from the stomach and all along the small bowel were analyzed using the proprietary associated software (Chongqing Jinshan Image Processing Software, version 6.0).

Small-bowel cleansing was evaluated by two experienced investigators who had reviewed images from over 200 patients. Both were unaware of the type of bowel preparation.

Gastric emptying time (GET) was defined as the time interval from the first gastric image to the time of the first duodenal image. Small-bowel transit time (SBTT) was defined as the time interval from the first duodenal

image to the time of the first cecal image, whether or not the cecum was reached, and was recorded for each patient. SBTT was divided into two intervals of equal duration, the first half for the proximal and the second half for the distal small bowel.<sup>[17]</sup>

Small-bowel cleansing was evaluated using our previously described visualized area percentage assessment of cleansing score (AAC) grading system.<sup>[18]</sup>

### Evaluation of the stomach and small-bowel bile contents

The Rapid software of the reading station (Given Imaging, Yoqneam, Israel),<sup>[19]</sup> as well as the Jinshan OMOM Imaging Station 6.0, shows a tissue color bar for identifying anatomical landmarks and maintaining perspective on the location of images. The tissue color bar consists of a computerized summary of color representations of individual CE images. This tissue color bar often contains pronounced greenish segments, corresponding to individual CE images of greenish luminal contents, consisting mostly of bile.

To measure the greenish luminal contents, an electronic high-resolution image of the Rapid user interface was captured using commercially available software (Screen Print and Capture 32 3.5, Provtech Ltd., West Kilbride, UK). The color bars for the entire tissue, the stomach, the small bowel, the proximal and distal segments of small bowel were captured individually [Figure 1]. The lengths of the greenish luminal contents of the latter four segments were calculated using Color Area Statistics software, developed by us.

### Statistical analysis

Quantitative data are summarized as the mean and standard deviation (SD) and compared by *t* tests. Normally distributed variables were compared by analysis of variance, and non-normally distributed variables by Kruskal–Wallis tests. Categorical variables were compared by the  $\chi^2$  test or Fisher's exact test (when expected count was  $\leq 5$ ) and Pearson's  $\chi^2$  test. Differences in constituent proportions were evaluated by the one-sample goodness-of-fit test. A two-tailed  $P < 0.05$  was considered statistically significant. SPSS (version 19.0 Chicago, IL) was used for all statistical analyses.

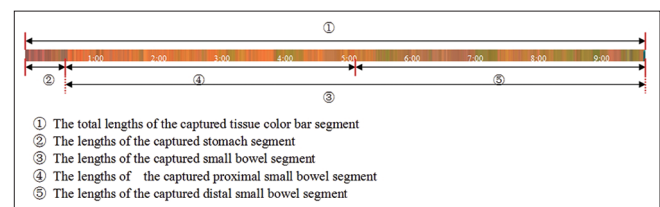


Figure 1: The tissue color bar legend

## RESULTS

### Study population and indications for CE

The study enrolled a total of 160 consecutive inpatients (73 men and 87 women, aged 18–85 years, mean age  $53.5 \pm 12.6$  years). Clinical indications for CE included obscure gastrointestinal bleeding in 97 patients, abdominal pain in 36, and chronic diarrhea in 27. Twelve patients, five in Group A and seven in Group B, were not enrolled into the analysis because the capsule had not reached the cecum before the end of the examination. Of the five patients withdrawn from Group A, one refused the procedure; one had delayed gastric emptying, with the capsule remaining in the stomach for 153 min; and three had capsule retention at the intestinal stricture (one with an ileal adenocarcinoma, one with a stromal tumor in the jejunum, and one with ileal Crohn's disease). Of the seven patients withdrawn from Group B, one refused the procedure; one declined to provide consent for this trial after undergoing the procedure; one showed capsule retention in the diverticulum; one showed capsule retention at the jejunum stenosis and was found to have fungating small-bowel tumors; one was unable to swallow the CE; and two had a prolonged transit time, one requiring 1 h 55 min for the capsule to leave the stomach and the other requiring 2 h 16 min for the capsule to reach the duodenum. Finally, 148 patients were involved in the analysis. There were no between group differences in gender distribution ( $P = 0.611$ ), age ( $P = 0.739$ ), and indications for CE ( $P = 0.888$ ) [Table 1].

### GET, SBTT, and tissue color bar segments

GET ( $51.37 \pm 12.68$  min vs  $49.65 \pm 11.69$  min;  $t = -0.178$ ,  $P = 0.630$ ) and SBTT ( $357.5 \pm 51.83$  min vs  $348.6 \pm 48.43$  min;  $t = 0.564$ ,  $P = 0.592$ ) were similar in Groups A and B. The total length of the captured tissue color bar segment ( $24.89 \pm 2.13$  cm vs  $24.95 \pm 2.08$  cm,  $t = -0.162$ ,  $P = 0.872$ ), as well as the lengths of the stomach ( $2.39 \pm 0.85$  cm vs  $2.46 \pm 0.76$  cm,  $t = -0.153$ ,  $P = 0.981$ ) and small-bowel ( $17.21 \pm 3.12$  cm vs  $16.92 \pm 2.97$  cm,  $t = 0.585$ ,  $P = 0.560$ ) segments were also similar in the two groups. The greenish luminal content lengths of the captured distal small-bowel segments were also similar in the two groups ( $4.80 \pm 1.84$  cm vs  $4.96 \pm 1.84$  cm,  $t = -0.552$ ,  $P = 0.581$ ), whereas the greenish luminal content lengths of the captured tissue color bars of the small-bowel ( $6.59 \pm 2.18$  cm vs  $10.99 \pm 2.29$  cm,  $t = -13.74$ ,  $P = 0.000$ ) and proximal small-bowel ( $3.18 \pm 1.62$  cm vs  $5.35 \pm 1.95$ ,  $t = -0.7365$ ,  $P = 0.000$ ) segments were significantly shorter in Group A than in Group B [Table 2].

Using AAC to evaluate small-bowel cleansing, with 1.5 as the cutoff, showed that of the 75 patients in Group A, 62 (82.7%) were rated as adequate and 13 (17.3%) as

**Table 1: Demographic and clinical characteristics of 148 patients undergoing CE**

Patient characteristics	Group A (n=75)	Group B (n=73)	P
Gender			
Males	36 (52.9%)	32 (47.1%)	$\chi^2=0.258$ 0.611
Females	39 (48.8%)	41 (51.2%)	
Age, mean±SD, years	52.6±11.8	51.3±11.3	$t=-0.179$ 0.739
Indications for CE			
Obscure gastrointestinal bleeding	48 (51.6%)	45 (48.4%)	$\chi^2=0.238$ 0.888
Abdominal pain	15 (46.9%)	17 (53.1%)	
Chronic diarrhea	12 (52.2%)	11 (47.8%)	

CE: Capsule endoscopy

**Table 2: Comparison of performance parameters of CE between the two study groups**

Parameters	Group A	Group B	t	P
GET (min)	51.37±12.68	47.65±11.69	-0.178	0.630
SBTT (min)	357.5±51.83	348.6±48.43	0.564	0.592
Lengths of captured tissue color bar segments, cm				
Total	24.89±2.13	24.95±2.08	-0.162	0.872
Stomach	2.39±0.85	2.46±0.76	-0.153	0.981
Small bowel	17.21±3.12	16.92±2.97	0.585	0.560
Greenish luminal content lengths, cm				
Small bowel	6.59±2.18	10.99±2.29	-13.74	0.000
Proximal small bowel	3.18±1.62	5.35±1.95	-0.7365	0.000
Distal small bowel	4.80±1.84	4.96±1.84	-0.552	0.581

Results presented as mean±SD. GET: Gastric emptying time, SBTT: Small-bowel transit time

inadequate. Of the 73 patients in Group B, 39 (53.4%) were rated as adequate and 34 (46.6%) as inadequate, a statistically significant difference between the two groups ( $\chi^2 = 14.596$ ,  $P = 0.000$ ).

Color Area Statistics software measurements of the greenish luminal content in the stomach showed that 15 of the 75 (20%) patients in Group A and six of the 73 (8.2%) in Group B were positive ( $\chi^2 = 4.217$ ,  $P = 0.040$ ; Table 3).

### Compliance and acceptability

Compliance with each preparation was 100%, and all patients completed the procedure without serious adverse effects. Two patients discontinued the preparation but finally completed the procedure. Adverse events in Group A included paroxysmal abdominal pain in two patients, nausea in three, vomiting in one, dyspepsia in one, weakness in two, and hunger in two. Adverse events in Group B included paroxysmal abdominal pain in three patients, nausea in three, vomiting in two, dyspepsia in two, weakness in one, and hunger in two.

**Table 3: Between-group comparisons of small-bowel cleansing and calculated greenish stomach contents**

Group	n	Adequate n (%)	Inadequate n (%)	$\chi^2$	P	Measured n (%)	No measured n (%)	$\chi^2$	P
A	75	60 (82.7)	13 (17.3)	14.596	0.000	15 (20.0)	60 (80.0)	4.217	0.040
B	73	39 (53.4)	34 (46.6)			6 (8.2)	67 (91.8)		

## DISCUSSION

Bile acids can damage the gastric mucosa through various mechanisms. Hydrotalcite and cholestyramine have been reported to be effective in treating bile reflux gastritis.<sup>[20,21]</sup> Hydrotalcite can neutralize stomach acid, adjusting gastric pH to 3–5, which is optimal for further treatment, and can inhibit pepsin activity. Moreover, hydrotalcite can combine with bile acid, removing almost all tauro lithocholate, glycol deoxycholic, and chenodeoxycholic acid at pH 3. In addition, hydrotalcite has been shown to protect the gastric mucosa by promoting the synthesis of prostaglandins, by activating bicarbonate storage pools, and by inducing the release of epithelial growth factor and basic fibroblast growth factor in the stomach.<sup>[22]</sup> Chenodeoxycholic acid and bile salts have a polar, hydrophilic end and a nonpolar, lipophilic end. These characteristics can result in cell membrane dissolution after cholic acid accumulation. Moreover, decontamination can damage the integrity and stability of the cell membrane. Orally administered cholestyramine can release chloride ion and combine with bile acids to form insoluble, non-absorbing complexes, reducing bile acid damage to the gastric mucosa. We found that treatment with hydrotalcite and cholestyramine 3 days before bowel preparation significantly reduced the percentage of patients with greenish luminal contents in the stomach (20% [15/75] vs 8.2% [6/73];  $\chi^2 = 4.217$ ,  $P = 0.040$ ), suggesting that hydrotalcite and cholestyramine can reduce the level of bile in the stomach.

Cholestyramine is a type of high molecular weight quaternary ammonium anion exchange resin. After oral administration, it combines with intestinal bile acids and hinders bile acid reabsorption in the ileum, significantly increasing the combination of bile acid in the small intestine, while reducing bile acid reflux to the liver. This results in liver microsomes of 7- $\alpha$  hydroxylase (rate-limiting enzyme) in the activated state, as well as promoting cholesterol conversion or binding to bile acids, and increasing bile acid secretion 3- to 15-fold.<sup>[23,24]</sup> Simultaneously, complexes of hydrotalcite with bile acids enter into the alkaline environment of the small bowel, releasing free bile acids and increasing their concentration in the small bowel, as shown by the increased percentage of patients in Group B with small intestinal greenish luminal contents.

Bile may be the most important factor affecting intestinal cleansing, followed by fecal residue, chyme, and bubbles.

Because no feasible methods have been developed to eliminate intestinal bile during small-bowel preparation, we tested whether fasting for 2-3 days may be effective. Ingestion of foods, especially those containing lipids, induces bile secretion to emulsify the fats and help in their digestion, resulting in bile secretion into and retention by the small intestine, and having a negative impact on intestinal preparation. Fasting for 2-3 days can reduce the secretion of bile, reducing the effects of bile on bowel cleanliness.

This study had several limitations. First, none of the patients underwent gastroscopy prior to CE; thus, we could not determine how many of these patients had bile reflux gastritis. Second, although the greenish segments of the tissue color bar consist mostly of bile, chyme, and fecal residue may also be present. However, the software used is unable to distinguish among bile, chyme, and fecal residue.

## CONCLUSION

Despite the widespread use of CE, methods of bowel preparation have drawbacks, especially regarding biliary clearance. This study found that the combination of hydrotalcite and cholestyramine could reduce the level of bile in the stomach, while significantly increasing bile levels in the small intestine. This combination is therefore not recommended for small-bowel preparation in patients undergoing CE. Because not eating can reduce bile acid secretion, fasting for 2-3 days may result in better small-bowel preparation.

## ACKNOWLEDGMENT

We wish to thank our colleagues, technicians and nurses for their great help and cooperation during performing this study.

## REFERENCES

1. Ghoshal UC. Small bowel endoscopy in 2013: The reality and the potential. *Nat Rev Gastroenterol Hepatol* 2014;11:86-7.
2. Neumann H, Fry LC, Neurath MF. Review article on current applications and future concepts of capsule endoscopy. *Digestion* 2013;87:91-9.
3. Aktas H, Mensink PB. Small bowel diagnostics: Current place of small bowel endoscopy. *Best Pract Res Clin Gastroenterol* 2012;26:209-20.
4. Minordi LM, Vecchioli A, Mirk P, Bonomo L. CT enterography with polyethylene glycol solution vs CT enteroclysis in small bowel disease. *Br J Radiol* 2011;84:112-9.
5. Eliakim R, Fischer D, Suissa A, Yassin K, Katz D, Guttman N, *et al.*

- Wireless capsule video endoscopy is a superior diagnostic tool in comparison to barium follow-through and computerized tomography in patients with suspected Crohn's disease. *Eur J Gastroenterol Hepatol* 2003;15:363-7.
6. Mylonaki M, Fritscher-Ravens A, Swain P. Wireless capsule endoscopy: A comparison with push enteroscopy in patients with gastroscopy and colonoscopy negative gastrointestinal bleeding. *Gut* 2003;52:1122-6.
  7. Esaki M, Matsumoto T, Watanabe K, Arakawa T, Naito Y, Matsuura M, *et al.* Use of capsule endoscopy in patients with Crohn's disease in Japan: A multicenter survey. *J Gastroenterol Hepatol* 2014;29:96-101.
  8. Costamagna G, Shah SK, Riccioni ME, Foschia F, Mutignani M, Perri V, *et al.* A prospective trial comparing small bowel radiographs and video capsule endoscopy for suspected small bowel disease. *Gastroenterology* 2002;123:999-1005.
  9. Ito T, Ohata K, Ono A, Chiba H, Tsuji Y, Sato H, *et al.* Prospective controlled study on the effects of polyethylene glycol in capsule endoscopy. *World J Gastroenterol* 2012;18:1789-92.
  10. Brotz C, Nandi N, Conn M, Daskalakis C, DiMarino M, Infantolino A, *et al.* A validation study of 3 grading systems to evaluate small-bowel cleansing for wireless capsule endoscopy: A quantitative index, a qualitative evaluation, and an overall adequacy assessment. *Gastrointest Endosc* 2009;69:262-70.
  11. Park SC, Keum B, Seo YS, Kim YS, Jeon YT, Chun HJ, *et al.* Effect of bowel preparation with polyethylene glycol on quality of capsule endoscopy. *Dig Dis Sci* 2011;56:1769-75.
  12. Chen HB, Huang Y, Chen SY, Song HW, Li XL, Dai DL, *et al.* Small bowel preparations for capsule endoscopy with mannitol and simethicone: A prospective, randomized, clinical trial. *J Clin Gastroenterol* 2011;45:337-41.
  13. Song HJ, Moon JS, Do JH, Cha IH, Yang CH, Choi MG, *et al.* Guidelines for bowel preparation before video capsule endoscopy. *Clin Endosc* 2013;46:147-54.
  14. Connor A, Tolan D, Hughes S, Carr N, Tomson C. Consensus guidelines for the safe prescription and administration of oral bowel-cleansing agents. *Gut* 2012;61:1525-32.
  15. Mathus-Vliegen E, Pellisé M, Heresbach D, Fischbach W, Dixon T, Belsey J, *et al.* Consensus guidelines for the use of bowel preparation on prior to colonic diagnostic procedures: Colonoscopy and small bowel video capsule endoscopy. *Curr Med Res Opin* 2013;29:931-45.
  16. Rokkas T, Papaxoinis K, Triantafyllou K, Pistiolas D, Ladas SD. Does purgative preparation influence the diagnostic yield of small bowel video capsule endoscopy? A meta-analysis. *Am J Gastroenterol* 2009;104:219-27.
  17. Kantianis A, Karagiannis S, Liatsos C, Galanis P, Psilopoulos D, Tenta R, *et al.* Comparison of two schemes of small bowel preparation for capsule endoscopy with polyethylene glycol: A prospective, randomized single-blind study. *Eur J Gastroenterol Hepatol* 2009;21:1140-4.
  18. Hong-Bin C, Yue H, Su-Yu C, Chun H, Lan-Hua G, Dong-Ying D, *et al.* Evaluation of visualized area percentage assessment of cleansing score and computed assessment of cleansing score for capsule endoscopy. *Saudi J Gastroenterol* 2013;19:160-4.
  19. Van Weyenberg SJ, De Leest HT, Mulder CJ. Description of a novel grading system to assess for quality of bowel preparation in video capsule endoscopy. *Endoscopy* 2011;43:406-11.
  20. Chen H, Li X, Ge Z, Gao Y, Chen X, Cui Y. Rabeprazole combined with hydrotalecite is effective for patients with bile reflux gastritis after cholecystectomy. *Can J Gastroenterol* 2010;24:197-201.
  21. Scaldaferrri F, Pizzoferrato M, Ponziani FR, Gasbarrini G, Gasbarrini A. Use and indications of cholestyramine and bile acid sequestrants. *Intern Emerg Med* 2013;8:205-10.
  22. Laine L, Takeuchi K, Tarnawski A. Gastric mucosal defense and cytoprotection: Bench to bedside. *Gastroenterology* 2008;135:41-60.
  23. Walters JR, Johnston IM, Nolan JD, Vassie C, Pruzanski ME, Shapiro DA. The response of patients with bile acid diarrhoea to the farnesoid X receptor agonist obeticholic acid. *Aliment Pharmacol Ther* 2015;41:54-64.
  24. Camilleri M. Advances in understanding of bile acid diarrhea. *Expert Rev Gastroenterol Hepatol* 2014;8:49-61.

**Source of Support:** This study was partly supported by Sanming Department of Science and Technology [2011-s-3 (1)], **Conflict of Interest:** None of the authors of this manuscript have conflicts of interest to state.