

# Biochemical transition during triphasic postpartum thyroiditis: confusion with central hypothyroidism

Samson O Oyibo<sup>1</sup>, Olivia S Green<sup>2</sup>, Nabeel M Laliwala<sup>2</sup> and Satyanarayana V Sagi<sup>1</sup>

<sup>1</sup>Department of Diabetes and Endocrinology, Peterborough City Hospital, Peterborough, UK and <sup>2</sup>Nightingale Medical Centre, Peterborough, UK

Correspondence  
should be addressed  
to S O Oyibo

**Email**  
[samoyibo@yahoo.co.uk](mailto:samoyibo@yahoo.co.uk)

## Summary

Hypothyroidism occurring in the postpartum period can be due to pituitary or hypothalamic disease as in Sheehan's syndrome and postpartum autoimmune hypophysitis or due to a primary thyroid disease as in postpartum thyroiditis. It is important that the correct diagnosis is ascertained because hypothalamic or pituitary disorders are often associated with other pituitary hormone deficiencies, especially life-threatening adrenal insufficiency or adrenal crisis. A combination of various symptoms and biochemical markers, especially serum thyroid-stimulating hormone levels dictate the initial diagnostic pathway. We present a case of a woman who presented with a 2-month history of tiredness and neck discomfort following delivery. A thyroid function test demonstrated results, which we initially interpreted as central hypothyroidism. Follow-up results indicated that this was in fact the transition period between the thyrotoxic phase and hypothyroid phases of postpartum thyroiditis. This case highlights the potential for diagnostic confusion between central hypothyroidism and postpartum thyroiditis.

## Learning points:

- Postpartum thyroiditis affects one in twenty mothers within 12 months of delivery.
- The majority of patients have transient thyrotoxicosis only, some have transient hypothyroidism only, and the rest has a triphasic pattern (thyrotoxic, hypothyroid then a euthyroid phase).
- During the transition from the thyrotoxic phase to hypothyroid phase, when serum TSH is still suppressed, the biochemical results can resemble that of central hypothyroidism.
- If central hypothyroidism is suspected, then urgent diagnostic investigations should be carried out along with the assessment of adrenal function.
- There is a potential for diagnostic confusion between postpartum central hypothyroidism and postpartum thyroiditis; however, the obstetric history, clinical symptoms, and signs (headaches, breastfeeding, goitre, etc.) and serum adrenocorticotrophic levels should help with the differential diagnosis.

## Background

Hypothyroidism occurring in the postpartum period can be secondary to hypothalamic or pituitary damage (central hypothyroidism), such as seen in Sheehan's syndrome (pituitary damage due to hypovolaemic shock from postpartum haemorrhage) or from autoimmune

lymphocytic hypophysitis (1, 2). Hypothalamic or pituitary-induced hypothyroidism is usually associated with other pituitary hormone deficiencies and is accompanied by the inability to produce breast milk post-delivery. The serum thyroid-stimulating hormone



(TSH) level is usually low or normal with a low or normal serum-free thyroxine (FT4) level and low or normal free triiodothyronine (FT3) level.

Hypothyroidism in the postpartum period can also be primary (postpartum thyroiditis), where there is a direct autoimmune injury to the thyroid gland. In postpartum thyroiditis, the autoimmune injury causes an initial thyrotoxic phase, followed by a hypothyroid phase and then a recovery phase (3, 4). The serum TSH level is usually high with a low serum FT4 level in patients with hypothyroidism secondary to postpartum thyroiditis. Additionally, there is an associated raised anti-thyroid peroxidase or anti-thyroglobulin antibodies.

Central hypothyroidism is frequently associated with a deficiency of other pituitary hormones, particularly adrenocorticotrophic hormone (ACTH). Therefore, it is important that postpartum central hypothyroidism is differentiated from postpartum thyroiditis; because if ACTH deficiency is not treated prior to commencing levothyroxine replacement, a life-threatening adrenal crisis can ensue.

We present a case of a woman who presented with tiredness for 2 months after delivery. A thyroid function test demonstrated results, which we initially interpreted as central hypothyroidism, but further investigation revealed the cause to be postpartum thyroiditis. This case highlights the potential for diagnostic confusion between central hypothyroidism and postpartum thyroiditis.

## Case presentation

A 26-year-old woman of Pakistani origin attended the Endocrinology Department for evaluation of abnormal thyroid function. She had presented with a 2-month history of general tiredness, malaise, and anterior neck discomfort and swelling. She had no headache, no visual disturbance, and no increased voiding of urine. She had delivered a baby boy 3 months earlier having moved from Italy to England when she was 6 months pregnant. Her delivery was an uneventful vaginal birth. She did not have any blood transfusion after delivery. She was currently breastfeeding and this was going well. She was not on any regular medication and had no past medical history of thyroid disorder. Her thyroid function test was normal during pregnancy. She had a history of gestational diabetes requiring insulin therapy in this and her previous pregnancy. On examination, she was well with a postpartum weight of 77 kg (BMI 29). She had a firm, non-tender goitre. No other abnormal findings on further examination.

## Investigation

Initial thyroid function blood test done before referral revealed low serum FT4 of 8.0 pmol/L (normal range: 12.0–22.0), normal FT3 of 3.3 pmol/L (normal range: 3.1–6.8), and low TSH of 0.05 mU/L (normal range: 0.3–4.2), consistent with that of central hypothyroidism. Because we suspected central hypothyroidism possibly secondary to postpartum autoimmune hypophysitis, we wanted to rule out adrenocortical insufficiency while repeating the thyroid function test. A repeat thyroid function test done 4 days later revealed similar results but the TSH level had risen to 1.47 mU/L, the FT4 was 5.3 pmol/L, and the FT3 was 2.4 pmol/L. A short Synacthen test revealed a pre-test/baseline serum cortisol of 621 nmol/L and post-test cortisol of 743 nmol/L, indicating normal adrenal function. The simultaneous (baseline) adrenocorticotrophic hormone (ACTH) level was 53 ng/L (normal range: 0–50 ng/L). Full blood count, renal, and liver function tests were normal. The serum electrolytes were within the normal range. The anti-thyroid peroxidase and thyroid receptor antibody tests were both negative. The serum prolactin level was raised (1512 mU/L), consistent with breastfeeding.

Four days later, the patient had a thyrotropin-releasing hormone (TRH) stimulation test to differentiate between a hypothalamic and a pituitary cause. Surprisingly, the pre-TRH injection result indicated hypothyroidism secondary to a primary thyroid gland disorder, and the response to the TRH injection was consistent with this or the hypothyroid phase of postpartum thyroiditis (see Table 1). A subsequent ultrasound scan demonstrated a slightly enlarged, hypervascular thyroid gland.

## Treatment

The patient was commenced on a course of levothyroxine 50 µg daily. She was also reassured after a full explanation and patient information sheet regarding postpartum thyroiditis.

**Table 1** Results of the thyrotropin-releasing hormone (TRH) stimulation test.

	Pre-TRH injection	20-min post-TRH injection	60-min post-TRH injection
TSH	10.5	30.8	24.9
FT4	3.4	3.8	3.6
FT3	2.1	1.9	2.0



## Outcome and follow-up

The patient felt relieved that her differential diagnosis did not include central hypothyroidism and that she did not require a MRI scan. Her anti-thyroglobulin antibody test turned out positive (121.0 kU/L). She remains well and will have a thyroid function test every 6–8 weeks at first, to assess for recovery.

## Discussion

Isolated central hypothyroidism in the postpartum period is rare and usually accompanied by other pituitary hormone deficiencies due to autoimmune hypophysitis or Sheehan's syndrome. Cases of Sheehan's syndrome are rare in the Western world with an incidence of 5.1 per 100,000 women but continues to be widely reported in developing nations where significant postpartum haemorrhage is still a problem (1, 2). Postpartum hypophysitis is less frequent; old reports suggest the incidence of all types of hypophysitis be approximately 1 in 10 million but there is still significant underreporting (5). Patients can present with non-specific symptoms, such as tiredness, malaise, or specific symptoms, such as headache, visual symptoms, collapse, and inability to produce breast milk post-delivery. The diagnosis of central hypothyroidism can be delayed for months or years due to clinical and biochemical misinterpretations of the various low/borderline-low serum TSH and FT4 levels (6, 7, 8).

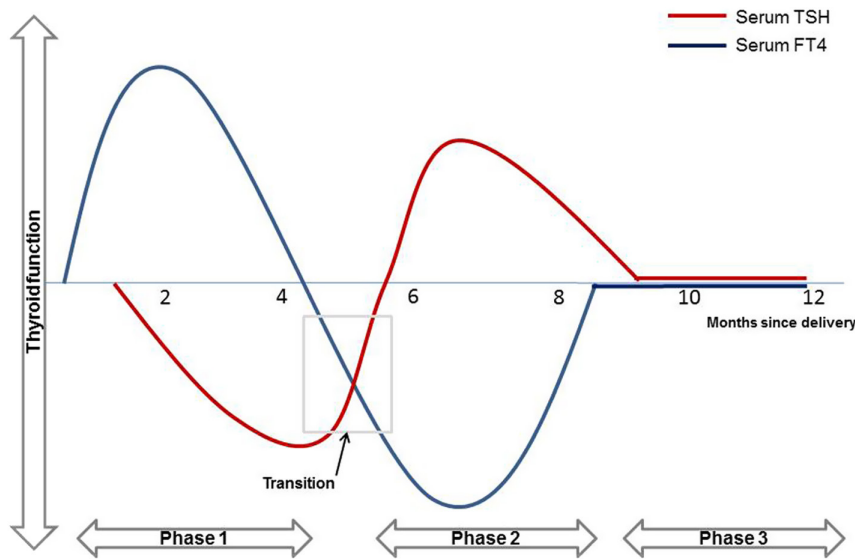
Postpartum thyroiditis occurs within a year of delivery. Epidemiological studies have documented a wide range of prevalence (1.1% to 11.4%) with a mean prevalence of about 8%. This prevalence rate increases to 20% in women with type 1 diabetes and up to 42% in women with a previous history of postpartum thyroiditis (1, 4). Women with postpartum thyroiditis are usually asymptomatic or have just mild symptoms (irritability, palpitations, tiredness) during the thyrotoxic phase, but frequently symptomatic (cold intolerance, tiredness, dry skin, impaired concentration) during the hypothyroid phase (3). A clinical case review demonstrated that the most common presentation was hypothyroidism without the preceding thyrotoxic phase in 43% of cases, the thyrotoxic phase by itself in 32% of the reported cases, and the triphasic pattern (thyrotoxic phase, followed by the hypothyroid phase then the recovery phase) comprising 25% of cases. In addition, most patients are euthyroid by 12 months post-delivery (9).

There has been a published report of diagnostic confusion between central hypothyroidism and

subclinical hypothyroidism because of a slightly raised serum TSH and low-normal serum FT4 (8). This resulted in a diagnosis of subclinical hypothyroidism. However, before starting levothyroxine replacement, a subnormal adrenal function test lead to the discovery of central hypothyroidism and secondary adrenal insufficiency due to an empty sella syndrome. There has also been a published report of diagnostic confusion between central hypothyroidism and subclinical thyrotoxicosis in the postpartum period (10). In this report, a 42-year-old woman had a long history of asthenia, depression, and oligomenorrhoea. A finding of a thyroid nodule, low serum TSH and a low-normal serum FT4 led to a diagnosis of chronic subclinical thyrotoxicosis. The patient went on to have radioiodine therapy. One year later, she presented with hypoglycaemic symptoms and turned out that she had central hypothyroidism and hypopituitarism all along. There has also been a reported case of diagnostic confusion between central hypothyroidism and painless thyroiditis (11). In this report, a 56-year-old woman was initially diagnosed with thyroiditis based on undetectable serum TSH, slightly low serum FT4, weakly positive anti-thyroglobulin antibodies, and low radioiodine uptake. However, after prolonged observation, the actual diagnosis was central hypothyroidism and partial secondary adrenal insufficiency, caused by autoimmune hypophysitis.

Our patient presented with tiredness and a feeling of neck discomfort and swelling. These symptoms plus the absence of any history of headache or peripartum haemorrhage, along with the ultrasound findings should make the suspicion of postpartum central hypothyroidism more unlikely. However, our patient did not have her thyroid ultrasound scan until a few weeks later. The thyroid function blood test did not catch the initial thyrotoxic phase but caught the biochemical transition period between the thyrotoxic phase and hypothyroid phase, during which time the serum FT4 was very low and the serum TSH level was still suppressed by the preceding thyrotoxic phase (see Fig. 1 for a schematic representation).

The anti-thyroid peroxidase antibody test was negative, but subsequent anti-thyroglobulin testing was positive. The thyroid hormone was the only group of hormones affected (prolactin and adrenal hormones were unaffected). Our patient could not have a radioiodine uptake scan while breastfeeding. The fact that the patient was breastfeeding successfully with no history of peripartum haemorrhage would go against Sheehan's syndrome. However, not all patients with Sheehan's syndrome have all the features. The presence of breastfeeding in the postpartum period does not completely rule out Sheehan's syndrome and not



**Figure 1**  
Schematic representation of triphasic postpartum thyroiditis showing the biochemical transition period between the thyrotoxic and hypothyroid phases, when our patient presented.

all patients have all the pituitary hormone deficiencies (12). This patient did not have symptoms suggestive of postpartum autoimmune hypophysitis. However, as in Sheehan's syndrome, patients with postpartum autoimmune hypophysitis can have a variable clinical presentation (13).

It should be noted that postpartum central hypothyroidism due to lymphocytic hypophysitis or Sheehan's syndrome is rare and remains an unlikely diagnosis in a patient with a goitre, with no history of peripartum haemorrhage and no headaches. Additionally, the serum TSH is usually low or even normal rather than suppressed as was found in this reported case. If lymphocytic hypophysitis or Sheehan's syndrome is suspected, then an MRI and further pituitary function test should be performed. Even though there are clear differentiating symptoms and signs, it is still plausible that a similar situation (low TSH, low FT4, symptoms of tiredness/malaise) occurring within 3 months of delivery will ring alarm bells and result in unnecessary investigations.

This case report highlights the potential for diagnostic confusion between postpartum central hypothyroidism and postpartum thyroiditis, particularly during the transition between the thyrotoxic phase and the hypothyroid phase, when the serum TSH is still suppressed by the initial thyrotoxic phase. Although in our case, we were more inclined to suspect central hypothyroidism and decided to rule out life-threatening adrenal failure, the inclination could still have gone the other way such that true pituitary failure is missed while commencing the patient on levothyroxine replacement. The initial results led to a suspicion of postpartum

central hypothyroidism, caused anxiety for our patient, resulted in her having a thyrotropin-releasing hormone stimulation test, and nearly resulted in her having an unnecessary MRI scan.

In conclusion, we report a case of postpartum hypothyroidism, which we initially thought was central hypothyroidism secondary to a postpartum hypothalamic or pituitary pathology. It later turned out that this was the transition between the thyrotoxic and hypothyroid phases of postpartum thyroiditis. This case highlights the potential for diagnostic confusion between postpartum central hypothyroidism and postpartum thyroiditis.

#### Declaration of interest

The authors declare that there is no conflict of interest that could be perceived as prejudicing the impartiality of the research reported.

#### Funding

This research did not receive any specific grant from any funding agency in the public, commercial or not-for-profit sector.

#### Patient consent

Informed and written consent has been obtained from the patient and it is available for review if needed.

#### Author contribution statement

S O O, O S G, N M L, and S V S all wrote the first draft of this manuscript. All authors were involved in the writing and the final review of the manuscript. S O O is the named physician for the patients, and N L is the named general practitioner for the patient.



## References

- 1 Landek-Salgado MA, Gutenber A, Lupi I, Kimura H, Mariotti S, Rose NR & Caturegli P. Pregnancy, postpartum autoimmune thyroiditis, and autoimmune hypophysitis: intimate relationships. *Autoimmunity Reviews* 2010 **9** 153–157. (<https://doi.org/10.1016/j.autrev.2009.06.001>)
- 2 Kristjansdottir HL, Bodvarsdottir SP & Sigurjonsdottir HA. Sheehan's syndrome in modern times: a nationwide retrospective study in Iceland. *European Journal of Endocrinology* 2011 **164** 349–354. (<https://doi.org/10.1530/EJE-10-1004>)
- 3 Alexander EK, Pearce EN, Brent GA, Brown RS, Chen H, Dosiou C, Grobman WA, Laurberg P, Lazarus JH, Mandel SJ, et al. 2017 Guidelines of the American Thyroid Association for the diagnosis and management of thyroid disease during pregnancy and the postpartum. *Thyroid* 2017 **27** 315–389. (<https://doi.org/10.1089/thy.2016.0457>)
- 4 Azizi F. Postpartum thyroid disorders. *Annals of Thyroid* 2018 **3** 13. (<https://doi.org/10.21037/aot.2018.04.04>)
- 5 Joneja U, Hooper DC, Evans JJ & Curtis MT. Postpartum granulomatous hypophysitis: a case study, review of the literature, and discussion of pathogenesis. *Case Reports in Pathology* 2016 **2016** 7510323. (<https://doi.org/10.1155/2016/7510323>)
- 6 Wardle CA, Fraser WD & Squire CR. Pitfalls in the use of thyrotropin concentration as a first-line thyroid-function test. *Lancet* 2001 **357** 1013–1014. ([https://doi.org/10.1016/S0140-6736\(00\)04248-3](https://doi.org/10.1016/S0140-6736(00)04248-3))
- 7 Persani L, Ferretti E, Borgato S, Faglia G & Beck-Peccoz P. Circulating thyrotropin bioactivity in sporadic central hypothyroidism. *Journal of Clinical Endocrinology and Metabolism* 2000 **85** 3631–3635. (<https://doi.org/10.1210/jcem.85.10.6895>)
- 8 Anyiam O, Cheung B & Al-Sabbagh S. Subclinical hypothyroidism or central hypothyroidism—the danger of thyroid function misinterpretation. *Clinical Case Reports* 2018 **6** 1953–1957. (<https://doi.org/10.1002/ccr3.1694>)
- 9 Stagnaro-Green A. Postpartum thyroiditis. *Best Practice and Research: Clinical Endocrinology and Metabolism* 2004 **18** 303–316. (<https://doi.org/10.1016/j.beem.2004.03.008>)
- 10 Boronat M. Central hypothyroidism or subclinical hyperthyroidism: can they be confused with each other? *Endocrinology, Diabetes and Metabolism Case Reports* 2020 **2020** 20–0059. (<https://doi.org/10.1530/EDM-20-0059>)
- 11 Barbesino G, Sluss PM & Caturegli P. Central hypothyroidism in a patient with pituitary autoimmunity: evidence for TSH-independent thyroid hormone synthesis. *Journal of Clinical Endocrinology and Metabolism* 2012 **97** 345–350. (<https://doi.org/10.1210/jc.2011-1591>)
- 12 Gei-Guardia O, Soto-Herrera E, Gei-Brealey A & Chen-Ku CH. Sheehan syndrome in Costa Rica: clinical experience with 60 cases. *Endocrine Practice* 2011 **17** 337–344. (<https://doi.org/10.4158/EP10145.OR>)
- 13 Caturegli P, Newschaffer C, Olivi A, Pomper MG, Burger PC & Rose NR. Autoimmune hypophysitis. *Endocrine Reviews* 2005 **26** 599–614. (<https://doi.org/10.1210/er.2004-0011>)

Received in final form 28 May 2021

Accepted 28 June 2021