

Unveiling Intricacies of DIEP Breast Reconstruction Post Early Breast Cancer: A Deep Dive into a Case of Unforeseen Complications

Li Xie^{1,*}, Xiangyi Kong^{1,2,*}, Jidong Gao^{1,2}

¹Department of Breast Surgical Oncology, National Cancer Center/National Clinical Research Center for Cancer/Cancer Hospital & Shenzhen Hospital, Chinese Academy of Medical Sciences and Peking Union Medical College, Shenzhen, 518116, People's Republic of China; ²Department of Breast Surgical Oncology, National Cancer Center/National Clinical Research Center for Cancer/Cancer Hospital, Chinese Academy of Medical Sciences and Peking Union Medical College, Beijing, 100021, People's Republic of China

*These authors contributed equally to this work

Correspondence: Jidong Gao, Department of Breast Surgical Oncology, National Cancer Center/National Clinical Research Center for Cancer/Cancer Hospital & Shenzhen Hospital, Chinese Academy of Medical Sciences and Peking Union Medical College, Shenzhen, 518116, People's Republic of China, Email abl68@cicams.ac.cn

Abstract: In the vast expanse of restorative surgical procedures, the Deep Inferior Epigastric Perforator (DIEP) flap, originating from the inferior epigastric artery, has emerged as the preferred method of breast reconstruction, attributable to its myriad advantages. The technique provides reliable vascular supply, robust tissue volume for excision, minimal invasiveness to the donor site, with direct closure and concealment of the said site. This paper embarks on an elaborate elucidation of the DIEP surgical procedure, pivoting on the analytical exploration of a particular instance where necrosis of the skin flap occurred following immediate DIEP breast reconstruction in a patient diagnosed with early-stage breast cancer. This patient had previously undergone Nipple Areola Complex Sparing Mastectomy (NSM). We endeavor to extrapolate insights from this singular case of post-NSM DIEP breast reconstruction failure and correlate our findings with current literature dedicated to similar instances of surgical failure in DIEP breast reconstruction.

Keywords: breast cancer, NSM, DIEP, breast reconstruction

Introduction

Evolved from the traditional transverse rectus abdominis muscle (TRAM) flap, the DIEP flap was first employed by Holmstrom in 1979 for breast reconstruction following breast cancer surgery.¹ Hartrampf in 1982 contributed to the increased popularity of the tipped TRAM flap, leveraging superior abdominal wall artery dissection.² Subsequently, Koshima and Soeda outlined the application of the inferior abdominal wall artery flap for oral repair in 1989.³ In 1994, Allen and Treece pioneered the use of the DIEP flap for breast reconstruction, which was later modified by Bloodeel in 1995.⁴ With continuous advancements in clinical techniques, the DIEP flap has solidified its reputation as the gold standard in breast autologous tissue reconstruction.⁵ Its sizable tissue volume, ease of shaping, and minimal damage to the rectus abdominis muscle, have distinguished it as the preferred flap for breast reconstruction.

Through our center's extensive experience with Deep Inferior Epigastric Perforator (DIEP) procedures, we have distilled the process into five core components, all of which are intricately interconnected, each holding significance in its own right. These components include flap extraction, preparation of the donor-recipient vascular connections, microscopic vascular anastomosis, the contouring of the breast, and finally, the closure of the donor area. Among these, flap retrieval and vascular anastomosis are the most crucial, effectively determining the smoothness of blood flow to the entire flap.

- 1) **Flap Extraction:** Prior to the procedure, a meticulously designed plan for the flap is developed. The dimensions of the skin island for the DIEP flap typically range from a height of 10–15 cm to a width of 30–40 cm. Before surgery, either a Computed Tomographic Angiography (CTA) examination or Doppler flow detection is employed to accurately locate the dominant penetrating branch. Intraoperative probing of this branch facilitates informed decision-making regarding its dissection, with particular care to preserve the intercostal motor nerve, minimize trauma to the rectus abdominis muscle, and safeguard the vascular tip. Following the excision, the flap is divided into zones, with optimal hemorrhage generally observed in zones 1 and 2. In contrast, due to insufficient perfusion, the tissue in zone 4 typically needs to be excised.
- 2) **Vascular Anastomosis:** This meticulous step requires the use of a microscope, typically at magnifications ranging from 2x to 4x. The arterioles in the donor-recipient area, commonly measuring 1–3 mm in diameter, are usually secured with 6–8 sutures, using 8–0/9–0 vascular sutures. Adverse influences on the anastomosis may arise from a variety of factors including damage during the recipient area's vessel preparation, vascular fibrosis resultant from chest radiation, chemotherapy, or inflammation, and disparity in the diameters of the vessels. The procedural options include vascular anastomosis and hand suturing, with localized usage of lidocaine (4%) to dilate vessels and heparin solution (100 U/cm³) to cleanse the vessel lumen. It is of vital importance that the vascular alignment of the episiotomy suture is maintained during the anastomosis process to guarantee smooth blood flow. Despite the technical challenges associated with free flaps and microvascular anastomoses, experienced surgeons can masterfully navigate these complexities, leaving no aspect unattended, thus ensuring the overall success of the procedure.

Clinical failure of the DIEP flap typically falls into one of two primary categories: insufficient arterial supply and venous stasis. Clinically, these issues can be addressed by enhancing the blood supply to the flap via a secondary set of vessels, or by amplifying blood flow with the utilization of intermediate vein grafts and thoracodorsal vessel anastomosis or retrograde to the internal thoracic artery.^{6–8} Remarkably, 80% of thrombosis cases associated with venous stasis occur within the initial two days postoperatively. Prompt medical interventions, such as intravenous administration of heparin, thrombotic clot stripping, and injection of streptokinase or urokinase for thrombolysis, significantly improve the salvage rate of the flap.⁹ Based on our center's experience, DIEP flap failures are predominantly attributed to vascular crises, including arterial and venous crises. Arterial crises, which commonly emerge within the first 24 hours post-surgery, are characterized by a pale flap, disappearance of skin lines, reduced or absent skin temperature, and a lack of capillary response. These necessitate immediate surgical exploration for artery rescue. Venous crises typically manifest within 72 hours post-surgery, marked by symptoms such as bruising, discoloration to a purple and black hue, heightened tension, and swelling of the flap, all of which require urgent salvage procedures.

Case Presentation

The patient presented herself at our medical facility with the primary complaint of multiple palpable lumps in her left breast. Comprehensive diagnostic evaluations, including ultrasound and Magnetic Resonance Imaging (MRI), indicated a potential malignancy. The patient subsequently underwent an aspiration biopsy of the palpable left breast swellings. The histopathological assessment revealed a high-grade intraductal carcinoma of the breast with infiltrative characteristics. Consequently, the patient underwent Nipple-Sparing Mastectomy (NSM) combined with Deep Inferior Epigastric Perforator (DIEP) flap surgery. Unfortunately, on the sixth postoperative day, compromised blood flow to the flap was observed. Despite attempts at conservative treatment and surgical debridement, the residual flap was inadequate in providing sufficient tissue for the breast reconstruction. After thoughtful consideration, it was decided to forgo the flap and instead opt for implant reconstruction. Informed consent for participation and publication was obtained from the patient involved in this case study. All personal data was anonymized to protect the patient's privacy in compliance with ethical standards.

Patient Characteristics and Choice of Surgeries

The patient under our care, who had detected multiple masses in her left breast, underwent a comprehensive evaluation for a month. Following her admission, breast ultrasound and MRI examinations revealed several non-mass-like areas that distinctly enhanced, densely clustered in the left breast. The largest lesion measured approximately 8.5×5.9 cm, categorizing it as BI-RADS category 4B. A biopsy confirmed the diagnosis of high-grade intraductal carcinoma with stromal invasion. Immunohistochemistry results indicated ER(-), PR(-), HER-2(3+), and Ki-67(40%+).

Considering the extensive nature of the disease, characterized by multiple lumps and a predominance of high-grade intraductal carcinoma, along with the absence of preoperative lymph node involvement in the ipsilateral axilla, neoadjuvant chemotherapy was considered unnecessary. The extensive nature of the lesions also made breast-conserving surgery an unsuitable option. The patient's medical history revealed significant breast ptosis, as shown in [Figure 1](#), following the birth of two children, with no plans for further pregnancies.

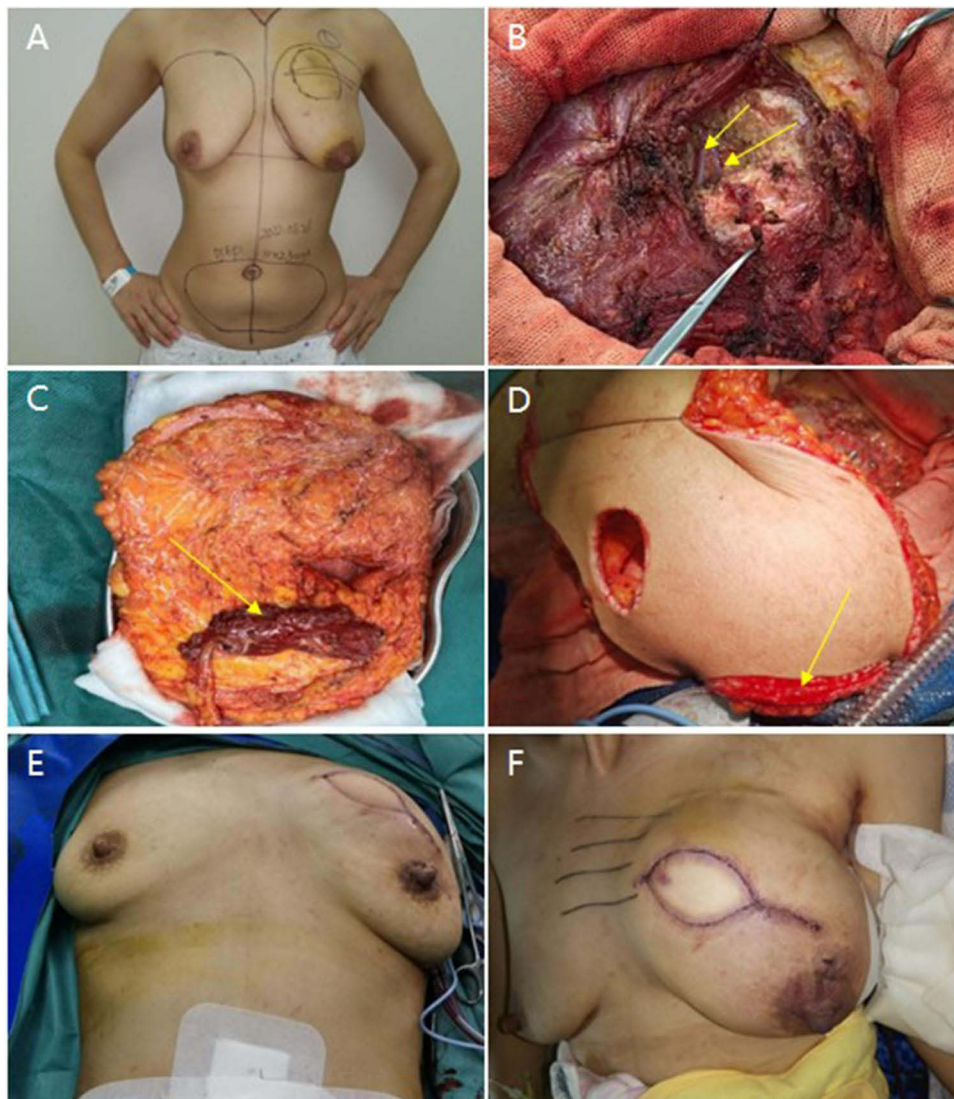

Figure 1 Sequential Stages of the DIEP Breast Reconstruction Surgical Procedure. **(A)** The initial stage involves preoperative markings which denote the tumor location and the range for flap excision. **(B)** This image highlights the vessels in the recipient area: The intra-thoracic arteries and veins are revealed within the 3rd rib space, as shown by arrows indicating 1 artery and 1 accompanying vein. **(C)** Post the freeing of the donor flap, the primary trunk of the subabdominal vessels becomes visible. A small section of the rectus abdominis muscle is observed wrapping around the vessel tips, also indicated by arrows. **(D)** After the vascular anastomosis, the image, guided by arrows, illustrates the flap edges exhibiting bleeding but with good blood flow after the removal of the epidermis. **(E)** Here we see the reconstructed breasts post shaping, with the bilateral breasts demonstrating basic symmetry. **(F)** The final image shows the status of the flap 1–5 days post-surgery, with a stable blood flow apparent.

The patient's physical condition, notably the presence of substantial abdominal adipose tissue, and her desire for breast reconstruction were key factors in the surgical decision-making process. Preoperative imaging suggested that the tumor was more than 4cm away from the nipple, allowing for the safe preservation of the nipple during surgery.

In our clinical practice, two primary types of breast reconstruction surgeries are commonly performed: implant reconstruction and autologous flap reconstruction. The patient expressed a strong preference for abdominal autologous flap reconstruction over implant reconstruction. Consequently, the surgical team opted for nipple-sparing mastectomy (NSM) combined with Deep Inferior Epigastric Perforator (DIEP) flap surgery, aligning with the patient's wishes and clinical indications.

Surgical Procedure and Characteristics

The surgical intervention involved a well-coordinated and meticulous approach, implementing specialized techniques to ensure the best possible outcomes. Prior to surgery, the patient was asked to stand so that a detailed surgical plan could be sketched, delineating the projected extent of the procedure (Figure 1A). The surgical team was organized into two distinct groups, each assigned a specific set of tasks to execute concurrently. The first group of surgeons focused on the radical removal of the primary breast cancer lesion, sentinel lymph node biopsy, and the exposure and preparation of the vessels in the recipient area. Meanwhile, the second group concentrated on the delicate task of flap preparation.

Primary Lesion Excision and Sentinel Lymph Node Biopsy

Approximately fifteen minutes before the commencement of the surgery, 0.5 mL of methylene blue was intradermally administered into the left breast. This acted as a visual guide, helping the surgical team identify and target the areas of concern. The first incision, a shuttle-shaped cut, was made in the inner quadrant of the left breast. This incision was approximately 7 cm in length and 3 cm in width. The team proceeded to peel off a skin slice with a thickness ranging between 0.3 and 0.5 cm.

The surgical boundaries were well-defined: medial to the body's midline, lateral to the outer edge of the latissimus dorsi muscle, superior to 1.5 cm below the clavicle, and inferior to the inframammary fold. The entire breast, in conjunction with the pectoralis muscle fascia, was excised extending to the left axilla. This approach helped to ensure the complete removal of any potentially affected tissue.

Upon examination of the left axilla, multiple blue-stained lymph nodes were visible - A direct result of the preoperative methylene blue injection. These nodes were carefully excised and sent for intraoperative analysis. The rapid intraoperative pathology indicated zero out of the six lymph nodes were cancerous, which was a promising result. Additionally, tissue margins beneath the nipple areola were scrutinized, and results returned negative for any malignant presence.

Vascular Preparation in the Recipient Area

The team then focused on preparing the recipient site for the incoming flap. To do this, a small portion of the pectoralis major muscle adjacent to the sternum was incised to expose the intrathoracic vessels. Upon inspection, an arteriovenous line was noted within the space of the 2nd and 3rd rib. Both the accompanying artery and vein were approximately 1.5 mm in diameter. Microscopic dissection was performed (Figure 1B) to meticulously separate these vessels, taking special care to avoid any damage.

Following the separation, the team assessed the condition of the arteriovenous vessels to ensure they were free of any obstructions or anomalies. Following their confirmation, vascular clamps were strategically placed to occlude the vessels, setting them aside for the subsequent anastomosis. This crucial step was undertaken to ensure that the vessels were ready to receive the flap and facilitate successful integration, which is critical for the viability of the transferred tissue.

Flap Preparation

With the target area meticulously delineated and ready, the focus was then shifted to the preparation of the flap, a vital element for the reconstruction phase. The proposed size of the lower abdominal transverse flap was carefully estimated to be approximately 24×12 cm. The upper boundary of the flap was strategically marked to be around 1 cm away from the

umbilicus, ensuring that the navel's natural placement would be preserved. Following the markings created during the preoperative phase, an incision was made to commence the flap preparation.

Starting from the right side, the flap was gently elevated along the superficial layer of the external oblique aponeurosis, moving from the outer edge inward. Three proximate perforations were identified, which were considerably larger than the others. These were earmarked for preservation, while the remaining perforations were ligated to control bleeding and maintain structural integrity. Along these conserved perforations, an incision was made through the anterior sheath of the rectus abdominis muscle.

Further exploration led to the identification of the inferior epigastric artery, situated between the rectus abdominis muscle and its posterior sheath. The origin of this artery, the external iliac artery, was traced to ensure accurate mapping. During this process, the intercostal nerve was observed crossing the superficial layer of the inferior epigastric artery, entering the rectus abdominis muscle in a phased manner. The team took special care to protect this nerve due to its essential role in transmitting sensory information.

A small hole of approximately 2 cm was bluntly created in the direction of the muscle fibers at the site where the penetrating branch entered the rectus abdominis muscle. This facilitated the observation of its relationship with the inferior epigastric artery and allowed the team to complete the dissection of the entire artery up to this point. Following the dissection, the flap was freed (Figure 1C), revealing a vascular tip of approximately 10 cm. The skin around the umbilicus was carefully incised, and the umbilical hole was excavated to ensure its preservation.

Vascular Anastomosis and Breast Contouring

Having prepared the flap, the surgical team proceeded to transplant it to the area of the left chest wall defect. The vascular cavity of both the donor and recipient regions was flushed with heparin solution (500 mL saline + 2 heparin sodium 12,500 IU preparation) to prevent clotting and ensure smooth blood flow. Under the careful observation of a microscope, a 9-0 vascular suture line was employed to anastomose the inferior epigastric and intrathoracic vessels (1 artery and 1 vein anastomosis). Additionally, a vein from the lower abdominal wall was linked to the distal end of the intrathoracic vein using a 1.5 mm vascular coupler, resulting in the anastomosis of a total of one active and two passive vessels intraoperatively.

The flap was carefully examined to confirm proper blood flow, and the epidermis was bled to promote adequate circulation (Figure 1D). The surgical bed was adjusted into a foldable position, allowing the patient to be placed in a semi-seated position. The reconstructed breast was then contoured to match the shape of the unaffected side, achieving symmetry (Figure 1E).

Donor Area Management

Upon completion of the reconstruction, the surgical team turned their attention to managing the donor area, a crucial step in ensuring the patient's recovery and the success of the procedure. The anterior sheath of the right rectus abdominis muscle was sutured using a No. 1 nylon silk thread, employing a technique of direct interrupted suturing.

For optimal healing and comfort, the patient's upper body was gently flexed, causing the abdomen to flex until the upper and lower trauma margins could be brought together without tension. The lower abdominal wound was meticulously closed in layers to promote healing, and the umbilicus was repositioned for an abdominoplasty and umbilicoplasty procedure. This final phase ensured not only the functional recovery of the patient but also aimed to preserve the aesthetic appeal of the donor area.

Skin Flap Necrosis and Intervention Process

Following the procedure, a series of postoperative care measures were promptly instituted. The patient was administered prophylactic antibiotic cefazolin sodium twice, and low molecular weight heparin sodium at a dosage of 42,500 IU/Qd subcutaneously for a period of four days. These preventive measures were instituted within the first 24 hours post-surgery to minimize the risk of infections and embolic events. To further avert thrombotic events, the patient was advised to engage in limited leg and foot exercises while in bed and to wear elastic compression stockings.

In the immediate aftermath of the surgery, the patient demonstrated a swift recovery, managing to rise from bed on the third postoperative day. The flap's blood flow was diligently monitored and remained stable during the first five days postoperatively, indicative of an initially successful procedure (Figure 1F).

However, on the afternoon of the sixth day, the nursing staff identified that the flap appeared unusually red. Upon pricking the flap with a needle, no blood was observed, raising concerns about the blood flow. Additionally, the skin temperature of the flap was recorded to be 2°C lower than that of the contralateral breast, and the capillary reaction of the flap had disappeared. These symptoms were suggestive of an obstructed blood flow to the flap (Figure 2A). Given these alarming indications, the primary hypothesis was that the arterial blood supply had been compromised. Therefore, a rescue protocol for the flap was immediately initiated.

In an attempt to rectify the compromised circulation, 42,500 IU of low molecular weight heparin sodium was administered intravenously and intracutaneously into the flap. Concurrently, an intravenous infusion of poppy bases and dextrose was administered to promote vasodilation and duct expansion. At the bedside, a debridement procedure was performed to incise part of the breast and probe the vascular tip. A clot was identified surrounding the vascular tip, which was subsequently cleared, and the tip was flushed with a heparin solution. This intervention resulted in palpable arterial pulsation at the vascular tip, and after approximately 10 minutes, blood was observed oozing from the edge of the flap and the needle site (Figure 2B).

On the morning of the seventh postoperative day, despite the interventions, the flap's blood flow did not show a substantial improvement. The distal end of the flap appeared swollen and harder than before, raising concerns of potential ischemic necrosis. Consequently, the patient was moved to the operating room for a more extensive debridement procedure to salvage as much of the flap's blood flow as possible.

All sutures were removed from the incision to scrutinize the extent of the hemorrhage. Blood was evident in the first flap area and part of the second area (Figure 2C). The remaining flap area showed no signs of oozing blood, but upon closer examination, the subdermal vascular network appeared bruised and dilated. Cutting through the vascular network revealed the presence of intravascular thrombi, leading to the excision of approximately 200 g of necrotic tissue and visibly bruised clots and thrombi (Figure 2D).

The remaining flap tissue (about 190 g) exhibited slight oozing of blood at the edge and resembled a cake in shape (Figure 2E). The assessment concluded that this remaining tissue was insufficient to support the required group mass for breast reconstruction, and there remained a risk of further flap necrosis. Following a comprehensive discussion with the patient and their family, it was decided to forgo the remaining flap tissue and instead opt for a skin expander implant, with a subsequent silicone gel prosthesis for stage II reconstruction surgery. Postoperative examination of the discarded flap revealed that while the arterial component of the vascular tip remained intact, the venous wall had suffered damage and had thrombosed (Figure 2F).

Follow-Up Status

At present, the patient is undergoing adjuvant chemotherapy and has been regularly inflating the expander with water injections to stretch the skin. So far, 210 mL of water has been injected, and the excess skin of the breast has retracted (Figure 2G). After the conclusion of chemotherapy, the patient is expected to return for stage II breast reconstruction surgery, where the skin expander will be removed and replaced with a silicone gel implant.

Discussion

In contemporary clinical settings, there has been a marked rise in the number of institutions performing Deep Inferior Epigastric Perforator (DIEP) flap breast reconstruction surgeries. According to certain datasets, the failure rate of these free perforator flaps has been constrained to approximately less than 5%.^{10,11} This noteworthy achievement is primarily attributable to advancements in surgical techniques and postoperative care. The challenges encountered during these procedures can be broadly categorized into two primary issues: inadequate arterial blood supply and venous stasis. Ensuring flap survival largely depends on diligent and enhanced postoperative monitoring of the flap. An early detection of a vascular crisis, typically within a span of 6 hours, followed by prompt surgical intervention can increase the flap

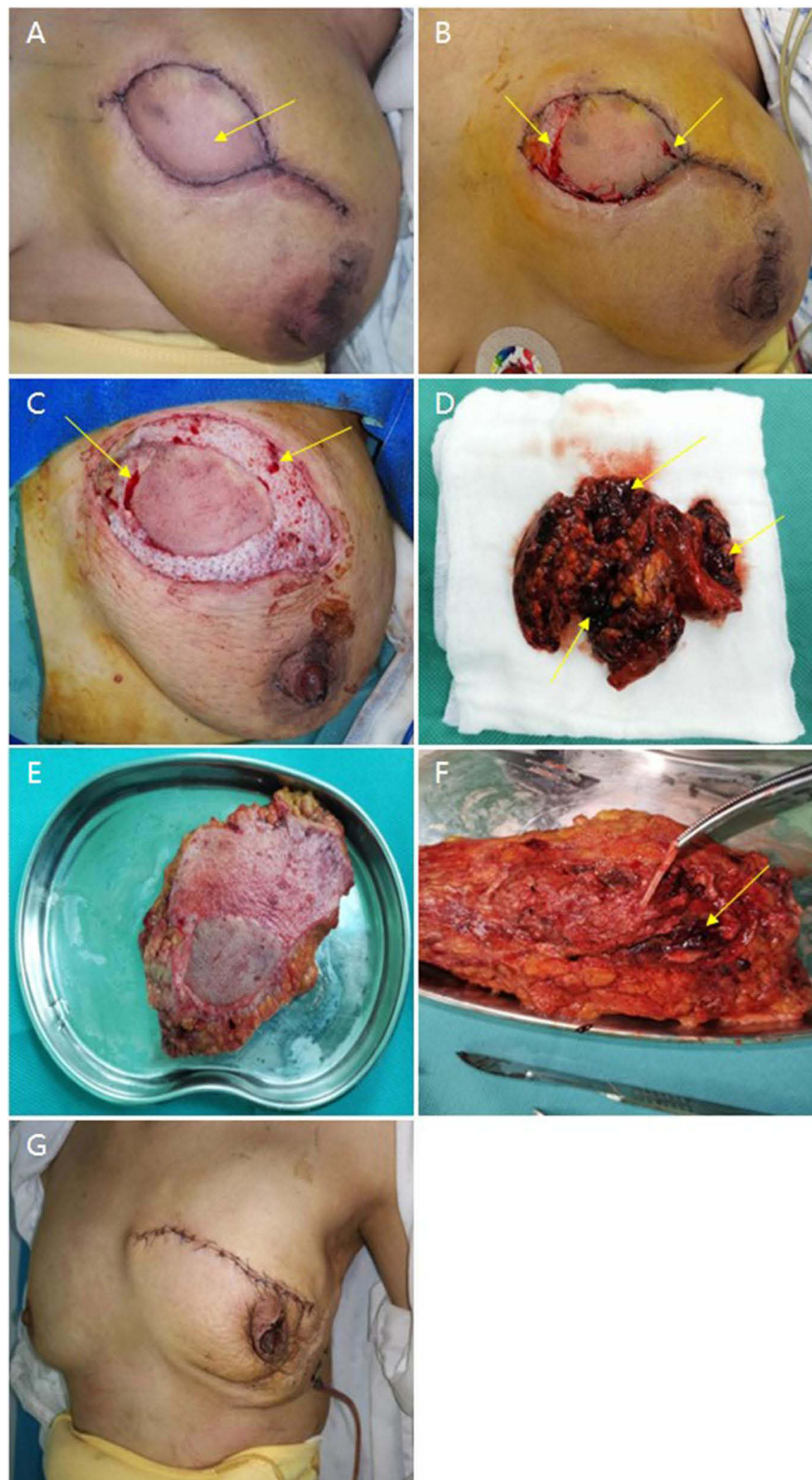


Figure 2 Six-Day Progression of Breast Appearance Following DIEP Surgery: (A) The image captured on the sixth day postoperatively, highlighted by an arrow, illustrates a red, swollen flap suggestive of potential hemorrhagic risk. (B) This image documents a bedside procedure involving the dissection of a portion of the incision suture and the reduction of tension. The arrow points to an area where bleeding is observed from the needle puncture flap. (C) Following surgical debridement, hemorrhage is identified in Area I and part of Area II of the flap, as pointed out by the arrow. Hemorrhage appears impaired in the remaining areas. (D) This photograph shows the area post the clearance of necrotic tissue, with signs of bruising and thrombus formation indicated by arrows. (E) Here, we can observe the residual skin flap subsequent to the removal of the necrotic flap area. (F) The dissection of the flap reveals clot formation around the vessel tip, the presence of an intravenous thrombus, and no detectable abnormality in the artery, as indicated by the arrow. (G) Finally, following the implantation of a skin expander, an injection of 210 mL of water is administered, causing the excess skin of the breast to retract.

salvage success rate up to a substantial 75%.¹² Existing research in this field has shown that instances of single vein thrombosis occur more frequently than arterial or combined arterial and venous thrombosis.¹³

In around 80% of DIEP flap procedures, the incidence of thrombosis tends to transpire within the initial two days following surgery.¹² However, in the present case, an unusual occurrence was observed with the thrombosis event materializing on the sixth postoperative day. A thorough analysis was undertaken to comprehend the reasons behind this deviation, considering the following factors: (1) On the sixth day post-surgery, the flap manifested signs of redness and bruising. These symptoms gradually progressed into more intense bruising and swelling, suggestive of venous thrombosis in the flap. This subsequently developed into extensive microthrombosis within the flap, culminating in necrotic damage to the flap. This chain of events was identified as the principal cause. (2) Another influencing factor was the intraoperative utilization of a microvascular anastomosis in this patient. Given that this is a foreign body implanted in the patient, it inherently raises the risk of thrombosis. Additionally, a failure to extend the postoperative anticoagulation cycle also played a part in enhancing the probability of flap thrombosis. (3) The patient experienced menstruation post-operatively, which is a significant factor to consider. The presence of clots in the menstrual blood and the hypercoagulable state of the blood during the latter part of the menstrual cycle can contribute to the development of flap thrombosis. □ Lastly, the procedure of intraoperative anastomosis of the vessels cannot entirely eliminate the possibility of injury to the anastomosis and damage to the intima, which is another factor that can result in flap thrombosis.

Taking into account the aforementioned factors, it can be inferred that the patient under discussion exhibits an elevated risk for thrombosis. Consequently, there are several recommendations for managing this risk, including extension of the postoperative anticoagulation treatment cycle, or intensification of the anticoagulation regimen. For instance, the use of anticoagulant drugs such as low molecular weight heparin sodium could be continued for up to seven days post-surgery. Such a precautionary measure would offer a safety net, allowing the flap to endure the period of heightened risk without incident.

Further examining the specifics of this case, the patient began menstruating on the fourth day after surgery. By the sixth postoperative day, the patient was in the late phase of the menstrual cycle. Emergency coagulation function tests suggested a high coagulation state, which escalates the threat of thrombosis. Under these circumstances, extending the anticoagulation cycle could be an appropriate step to ensure the sustenance of blood flow to the flap.

The evaluation of clinical instances of flap bruising has led to its categorization into five primary types: (1) Vascular Anastomosis Inaccessibility: This category encompasses situations where the anastomosis – the surgical connection made between blood vessels – exhibits foldings, diametrical mismatches, or an inhibited smoothness of blood flow; (2) Venous Thrombosis: The next category represents a state of blood hypercoagulability or excessive clotting. Insufficient activity following surgery or an elevated risk of thrombosis typically contribute to this condition; (3) Insufficient Venous Traffic Branches Across the Midline or Missing: Clinical findings have shown that approximately 8–36% of patients do not have venous traffic branches crossing the midline of the abdominal wall; (4) Insufficient Traffic Branches of the Deep and Superficial Venous System: During surgery, bruising may indicate that there's insufficient traffic between the deep and superficial venous systems. An increase in SIEV-DIEV anastomosis can rescue nearly 100% of the flap, thereby suggesting shallow venous reflux; (5) Inappropriate Selection of Anastomotic Vein: The last category corresponds to cases where the chosen vein for anastomosis is either inadequately conditioned, not the primary reflux vein itself, or is damaged intraoperatively. These conditions can lead to poor reflux and subsequently result in flap venous bruising. The treatment strategies available for flap bruising are primarily surgical and conservative. Conservative approaches encompass a range of therapies like postural drainage and massage, bloodletting, medical leeches and hirudin, anticoagulation and thrombolysis, hyperbaric oxygen therapy, herbal therapy, and oxygen radical scavengers.¹⁴ A constant awareness of the risk of flap vein bruising must pervade the surgeon's mind at every stage of flap surgery. This consciousness is key to executing pre-emptive strategies that can mitigate potential complications.

Conclusion

A constant awareness of the risk of flap vein bruising must pervade the surgeon's mind at every stage of flap surgery. This consciousness is key to executing pre-emptive strategies that can mitigate potential complications. As we proceed towards the conclusion, it is evident that the widespread adoption of DIEP surgery across numerous medical institutions has led to a growing focus among surgeons on managing and preventing surgical complications, thereby striving to minimize failure rates. Through this case study, our medical center has derived several key insights: (1) It is advisable to avoid surgery during

the perimenstrual period whenever possible. (2) If a surgical procedure necessitates the implantation of a foreign body, an extended postoperative cycle of anticoagulation therapy is recommended to curtail the risk of thrombosis. (3) For free penetrating flap surgery, a standard postoperative prescription of anticoagulant medication for 6–7 days is advised to safely navigate through the flap risk period. (4) Postoperative medication should be administered according to coagulation results until the results return to normal. (5) In the event of a flap blood risk, early surgical exploration is encouraged for flap salvage, ideally within a 6-hour window. (6) For flap surgery, a rescue surgical plan should be prepared in advance. If flap surgery failure does occur, a backup surgical plan can be implemented for salvage operations. By sharing the learnings from this case, we aspire to provide clinical references that could guide other healthcare professionals in their practice, thereby improving patient outcomes.

Ethical/Copyright Statement

Institutional approval was not required to publish the case details.

Disclosure

The authors report no conflicts of interest in this work.

References

1. Holmstrom H. The free abdominoplasty flap and its use in breast reconstruction. An experimental study and clinical case report. *Scand J Plast Reconstr Surg.* 1979;13(3):423–427. doi:10.3109/02844317909013092
2. Hartrampf CR, Schefflan M, Black PW. Breast reconstruction with a transverse abdominal island flap. *Plast Reconstr Surg.* 1982;69(2):216–225. doi:10.1097/00006534-198202000-00006
3. Koshima I, Soeda S. Inferior epigastric artery skin flaps without rectus abdominis muscle. *Br J Plast Surg.* 1989;42(6):645–648. doi:10.1016/0007-1226(89)90075-1
4. Blondeel PN, Christiaens MR, Thomas J, et al. Primary leiomyosarcoma of the diaphragm. *Eur J Surg Oncol.* 1995;21(4):429–431. doi:10.1016/S0748-7983(95)92912-6
5. Allen RJ, Treece P. Deep inferior epigastric perforator flap for breast reconstruction. *Ann Plast Surg.* 1994;32(1):32–38. doi:10.1097/0000637-199401000-00007
6. Barnett GR, Carlisle IR, Gianoutsos MP. The cephalic vein: an aid in free TRAM flap breast reconstruction. Report of 12 cases. *Plast Reconstr Surg.* 1996;97(1):71–6; discussion 77–8. doi:10.1097/00006534-199601000-00011
7. Semple JL. Retrograde microvascular augmentation (turbocharging) of a single-pedicle TRAM flap through a deep inferior epigastric arterial and venous loop. *Plast Reconstr Surg.* 1994;93(1):109–117. doi:10.1097/00006534-199401000-00016
8. Harashina T, Sone K, Inoue T, et al. Augmentation of circulation of pedicled transverse rectus abdominis musculocutaneous flaps by microvascular surgery. *Br J Plast Surg.* 1987;40(4):367–370. doi:10.1016/0007-1226(87)90039-7
9. Serletti JM, Moran SL, Orlando GS, et al. Urokinase protocol for free-flap salvage following prolonged venous thrombosis. *Plast Reconstr Surg.* 1998;102(6):1947–1953. doi:10.1097/00006534-199811000-00021
10. Huang H, Bast JH, Otterburn DM. Delineating the risk factors of venous congestion: an analysis of 455 deep inferior epigastric perforator flaps with radiographic correlation. *J Plast Reconstr Aesthet Surg.* 2022;75(6):1886–1892. doi:10.1016/j.bjps.2022.01.003
11. Alves AS, Tan V, Scampa M, et al. Complications of immediate versus delayed DIEP reconstruction: a meta-analysis of comparative studies. *Cancers.* 2022;14(17):4272. doi:10.3390/cancers14174272
12. Khouri RK. Avoiding free flap failure. *Clin Plast Surg.* 1992;19(4):773–781. doi:10.1016/S0094-1298(20)30795-1
13. Nahabedian MY, Momen B, Manson PN. Factors associated with anastomotic failure after microvascular reconstruction of the breast. *Plast Reconstr Surg.* 2004;114(1):74–82. doi:10.1097/01.PRS.0000127798.69644.65
14. Boissiere F, Gandolfi S, Riot S, et al. Flap venous congestion and salvage techniques: a systematic literature review. *Plast Reconstr Surg Glob Open.* 2021;9(1):e3327. doi:10.1097/GOX.00000000000003327

Cancer Management and Research

Dovepress

Publish your work in this journal

Cancer Management and Research is an international, peer-reviewed open access journal focusing on cancer research and the optimal use of preventative and integrated treatment interventions to achieve improved outcomes, enhanced survival and quality of life for the cancer patient. The manuscript management system is completely online and includes a very quick and fair peer-review system, which is all easy to use. Visit <http://www.dovepress.com/testimonials.php> to read real quotes from published authors.

Submit your manuscript here: <https://www.dovepress.com/cancer-management-and-research-journal>