

Original Paper

Cerebral Hemodynamic Changes Induced by a Lumbar Puncture in Good-Grade Subarachnoid Hemorrhage

Eric A. Schmidt^{a, f} Stein Silva^{c, f} Jean François Albucher^{b, f}
Aymeric Luzi^c Isabelle Loubinoux^f Anne Christine Januel^e
Christophe Cognard^e Pierre Payoux^{d, f} François Chollet^{b, f}

^aNeurosurgery, ^bNeurology, ^cAnesthesiology, ^dNuclear Medicine, ^eNeuroradiology, CHU Toulouse, and ^fINSERM 825, UMR 825, Université de Toulouse, Toulouse, France

Key Words

Subarachnoid hemorrhage · Cerebral blood flow · Lumbar puncture · Intracranial pressure · PET scanner

Abstract

Background: Patients with good-grade subarachnoid hemorrhage (SAH) are those without initial neurological deficit. However, they can die or present severe deficit due to secondary insult leading to brain ischemia. After SAH, in a known context of energy crisis, vasospasm, hydrocephalus and intracranial hypertension contribute to unfavorable outcome. Lumbar puncture (LP) is sometimes performed in an attempt to reduce intracranial pressure (ICP) and release headaches. We hypothesize that in good-grade SAH patients, a 20-ml LP releases headaches, reduces ICP and improves cerebral blood flow (CBF) as measured with O¹⁵ PET scan. **Methods:** Six good-grade (WFNS grade 1 or 2) SAH patients (mean age 48 years, 2 women, 4 men) were prospectively included. All aneurysms (4 anterior communicating artery and 2 right middle cerebral artery) were coiled at day 1. Patients were managed according to our local protocol. LP was performed for severe headache (VAS >7) despite maximal painkiller treatment. Patients were included when the LP was clinically needed. The 20-ml LP was done in the PET scan (mean delay between SAH and LP: 3.5 days). LP allows hydrostatic measurement of ICP. Arterial blood pressure (ABP) was noninvasively gauged with photoplethysmography. Every signal was monitored and analyzed off-line. Regional CBF (rCBF) was measured

semiquantitatively with O^{15} PET before and after LP. Then we calculated the difference between baseline and post-LP condition for each area: positive value means augmentation of rCBF after the LP, negative value means reduction of rCBF. Individual descriptive analysis of CBF was first performed for each patient; then a statistical group analysis was done with SPM for all voxels using t statistics converted to Z scores ($p < 0.01$, Z score > 3.2). **Results:** A 20-ml LP yielded a reduction in pain (–4), a drop in ICP (24.3 ± 12.5 to 6.9 ± 4.7 mm Hg), but no change in ABP. Descriptive and statistical image analysis showed a heterogeneous and biphasic change in cerebral hemodynamics: rCBF was not kept constant and either augmented or decreased after the drop in ICP. Hence, cerebrovascular reactivity was spatially heterogeneous within the brain. rCBF seems to augment in the brain region roughly close to the bleed and to be reduced in the rest of the brain, with a rough plane of symmetry. **Conclusions:** In good-grade SAH, LP releases headaches and lowers ICP. LP and the drop in ICP have a heterogeneous and biphasic effect on rCBF, suggesting that cerebrovascular reactivity is not spatially homogeneous within the brain.

Copyright © 2012 S. Karger AG, Basel

Introduction

Subarachnoid hemorrhage (SAH) is a challenging cerebrovascular disease with complex mechanisms threatening brain perfusion and function. The therapeutic challenge is to actively treat and optimize cerebral hemodynamics at bedside, prevent secondary insult and improve clinical outcome. After SAH, a context of cerebral energy crisis has been demonstrated [1]. This crisis might be magnified by secondary insults, such as vasospasm and hydrocephalus that contribute to unfavorable outcome via biochemical and biomechanical aggressions. The biochemical stress is related to the presence of blood-derived compounds that alter microvascular function, yielding vascular spasm with reduction of blood delivery that intensifies the oligemic brain vulnerability [2]. The biomechanical stress is mainly related to raised intracranial pressure (ICP) [3] that reduces the cerebral perfusion and threatens the brain function [4].

Patients with good-grade SAH (WFNS 1 or 2) [5] are those without initial neurological deficit. However, they can die or present severe deficit due to delayed insult leading to brain ischemia [6]. This fragile population mandates an optimal treatment, but little is known with respect to ICP management.

In clinical practice, lumbar puncture (LP) is sometimes performed to withdraw CSF and to release headaches in awake patients after SAH. The indication of LP is mainly based on an empirical and controversial approach. There is no clear evidence of the benefit of this procedure neither in terms of headache, drop-in ICP nor in change in cerebral hemodynamics.

We hypothesize that in good-grade SAH patients, a 20-ml LP reduces – within a time frame of one hour – headache and ICP, but also improves cerebral hemodynamics as measured with O^{15} positron emission tomography (PET).

Methods

Patients

Patients with good-grade SAH (WFNS 1 or 2) [5] were eligible to this study. They all presented an acute headache, were conscious and had no focal neurological deficit. The diagnosis of SAH was confirmed by the presence of blood in the subarachnoid spaces on

Table 1. Demographics and clinical data

Pa-tient	Sex	Age	Admission WFNS	Fisher score	Evan's index	Aneurysm location	Day of coiling after SAH	Day of PET after SAH	Change in VAS	GOS
1	m	46	1	4	0.29	AcomA	1	4	-4	5
2	f	43	1	2	0.22	AcomA	1	5	-5	4
3	m	52	1	2	0.22	rMCA	1	4	-1	5
4	f	39	2	4	0.22	rMCA	1	2	-2	5
5	m	57	1	3	0.26	AcomA	1	3	-5	4
6	m	55	1	3	0.28	AcomA	1	3	-5	4
4m/2f		48	1	3	0.24	4 AcomA 2 rMCA	1	3.5	-4	

Total and mean values are indicated in the last line.

CT scan, graded with the Fisher score. The degree of ventricular dilatation was measured with the frontal ventricle/cerebral index or Evan's index (normal <30%). Patients were transferred to our Stroke Unit. No LP had been performed at that time. The origin of the bleed was investigated with angiography under general anesthesia within the first 24 hours. An aneurysm was detected in every patient, and successfully treated with endovascular coiling. No actual vasospasm was identified. Patients were managed according to our local protocol associating painkillers (stepwise from paracetamol 1 g i.v. every 8 h to morphine sulfate 2–4 mg i.v. every 2–4 h), nimodipin (60 mg p.o. every 4 h for 21 days), enoxaparin (0.4 ml/day s.c.), pravastatin (40 mg/day p.o.). We perform LP for severe headaches when the visual analog scale (VAS) >7 despite maximal painkiller treatment (paracetamol and morphine).

Inclusion criteria were as follows: (i) WFNS 1 or 2 SAH with treated aneurysm and (ii) severe headache requiring an LP in our institution to withdraw 20 ml CSF, (iii) signed consent and (iv) no anticoagulants 12 h prior to the LP.

Patient Inclusion

At our institution, we perform LP in about 30 % of our good-grade SAH patients. Within the 18-month inclusion period, 40 patients were admitted for good-grade SAH in our Stroke Unit. The study was proposed to all patients who required an LP. Nine patients agreed to participate to the study. Two patients were finally not included because of cyclotron problem. Seven patients were actually included with signed consent, but one patient moved during the second PET run and the cerebral blood flow (CBF) analysis was not interpretable. Despite our endeavor, we finally included and analyzed 6 patients in this prospective study.

Study Procedure

The study procedure was performed between day 2 and day 5 after the SAH onset (table 1). It sequentially consisted of (i) a pre-LP pain estimation with VAS, (ii) an ICP and non-invasive arterial blood pressure (ABP) monitoring, (iii) a PET measurement of CBF (3 consecutive runs), (iv) a 20-ml CSF removal, (v) a second PET measurement of CBF (3 consecutive runs) and finally (vi) a post-LP pain evaluation with VAS. The whole procedure lasted 2 hours and was performed in the PET Scan area.

ICP and ABP Monitoring Technique

The patient was lying horizontally in the left lateral position. After local anesthesia a 20G lumbar needle was inserted in the L4–L5 interspinous space and was left in place during the whole procedure. The lumbar puncture allows gauging ICP in communicating hydrocephalus [7] and SAH [8]. Therefore CSF lumbar pressure was used in this protocol as a surrogate measurement of ICP. The CSF pressure was measured with a fluid transducer. The zero reference pressure was the atmospheric pressure at the level of the foramen of Monro. ABP was monitored noninvasively using photoplethysmography with a cuff placed on the left medius. The pressure monitors were connected to an analog-to-digital converter, fitted into a computer running a dedicated software (<http://www.neurosurg.cam.ac.uk/icmplus>, Cambridge University, UK) [9].

The waveforms of ICP and ABP were sampled and digitized. The digital signals were analyzed off-line. ICP mean (ICPm), ABP mean (ABPm) and cerebral perfusion pressure (CPP = ABPm – ICPm) were calculated. ICP pulse amplitude (ICPa) was processed as the first harmonic component of ICP. Pressure-volume compensatory reserve was estimated by the RAP index [10], calculated as the linear correlation coefficient between ICPm and ICPa. When the pressure-volume compensatory reserve is preserved, small intracranial volume does not influence the pulsatility of ICP producing a lack of coupling between changes in ICPm and in ICPa, demonstrated by a correlation coefficient close to 0. RAP index close to 0 indicates a preserved pressure-volume compensatory reserve. Conversely when the pressure-volume compensatory reserve is altered, ICPm and ICPa are positively coupled with a RAP index close to +1.

PET Technique

The scanner used was an EXACT HR+ (CTI/Siemens CTI, Knoxville, Tenn., USA). The whole brain was imaged. For attenuation correction, a 10-minute transmission scan was acquired with a $^{68}\text{Ge}/^{68}\text{Ga}$ ring source. After reconstruction, axial and in-plane resolution was 4.1–4.5 mm. During the whole procedure, subjects were kept in left lateral position in a vacuum mattress. The light was dimmed in a quiet camera room, the patients were asked to lie calm with their eyes closed during the whole procedure, avoiding any head movement. CBF was monitored with intravenous bolus injections of oxygen-15-radiolabeled water (H_2^{15}O) as a blood flow tracer. To improve reliability of the measurement, each subject received 3 consecutive intravenous boluses of 300 MBq of H_2^{15}O . Then 3 PET scans were acquired to measure CBF at baseline. Then 20 ml CSF were drained by simple gravity after opening a three-way tap on the LP needle. Subsequently the tap was closed and finally 3 intravenous injections of 300 MBq and 3 PET scans were performed. In order to obtain a significant reduction of the injected radioactivity (half-life of H_2^{15}O = 123 s), at least 10 minutes elapsed between each scan. PET data were reconstructed by filtered back projection with corrections for attenuation, scatter, randoms, dead time, and decay and smoothed by a Gaussian function with 7.3-mm full-width half-maximum.

Data Analysis

Data are expressed as mean \pm standard deviation. The nonparametric Wilcoxon test for paired data was used for clinical and monitoring data. All calculations were performed using Statistica 6.1 (StatSoft, Inc).

Image Analysis

We semiquantitatively measured CBF and performed two different image analyses: one descriptive and one statistical analysis.

Table 2. Monitoring data

Patient	Baseline					After LP				
	ICPm	ICPa	RAP	ABPm	CPPm	ICPm	ICPa	RAP	ABPm	CPPm
1	29.5	6.1	0.97	104	74.5	7.47	0.71	0.2	109	101.5
2	13.9	0.742	0.56	94	80.1	7.45	0.91	0.34	95	87.6
3	11.9	1.27	0.74	95.6	83.7	6.27	1.26	0	109	102.7
4	33.1	6.53	0.91	93.9	60.8	13.7	0.92	0.25	98.3	84.6
5	15.1	4.92	0.68	82	66.9	-1.1	0.22	0.21	88.2	89.2
6	42.5	15	0.78	115	72.5	7.27	1.15	0.38	110	102.7
Mean ± SD	24.3 ± 12.5	5.76 ± 5.14	0.77 ± 0.14	97.4 ± 11.1	73.1 ± 8.4	6.9 ± 4.7	0.86 ± 0.37	0.22 ± 0.15	101.6 ± 9.1	94.7 ± 8.5

Mean and SD of various monitoring indices before and after the LP for each patient: mean and pulse amplitude of intracranial pressure (ICPm and ICPa, respectively), pressure-volume compensatory reserve (RAP), arterial blood pressure mean (ABPm) and cerebral perfusion mean (CPPm).

The first descriptive analysis was performed using the raw signal, normalized to mean cerebral activity and we applied a Brodmann mask [<http://www.cabiatl.com/micro/mri-cro/micro.html>] on the images. We measured the mean value of the pixels for each Brodmann area at baseline and after the LP. Then we calculated the difference between baseline and post-LP condition for each Brodmann area: positive value means augmentation of relative CBF after the LP, negative value means reduction of regional CBF (rCBF). The semi-quantitative results were displayed graphically with axial views of the brain.

The second analysis was performed using Statistical Parametric Map (SPM 5) (Wellcome Department of Cognitive Neurology, Institute of Neurology, London, UK). We analyzed the variation in rCBF. rCBF data were covaried for all voxels and comparisons across the two conditions (before and after CSF drainage) were made using t statistics with appropriate linear contrasts and then converted to Z scores. Only regions that exceeded a threshold of $p < 0.05$ (Z score >3.2) were considered significant. This analysis allows showing significant increase or decrease of blood flow after the LP.

Protocol Approvals and Patient Consents

Our local research ethics committee approved the study and a signed consent was obtained from all patients participating in the study.

Results

Pain

One hour after LP, pain decreased in all patients with a significant mean drop of -4 (table 1).

Monitoring Analysis

An example of the recording is displayed figure 1, and results are given in table 2. The mean baseline ICP was 24.3 ± 12.5 mm Hg with high pulsatility pattern, demonstrating at baseline an intracranial hypertension in our group of patients. The withdrawal of 20 ml of CSF produced a rapid drop in ICP down to a mean value of 6.9 ± 4.7 mm Hg ($p = 0.02$). ICP pulse amplitude plunged from 5.76 ± 5.14 to 0.86 ± 0.37 mm Hg. RAP significantly dropped from 0.77 ± 0.14 to 0.22 ± 0.15 ($p = 0.02$) suggesting that pressure-volume compensatory reserve improved after LP. There was no change in mean ABP (97.4 ± 11.1 vs. 101.6 ± 9.1

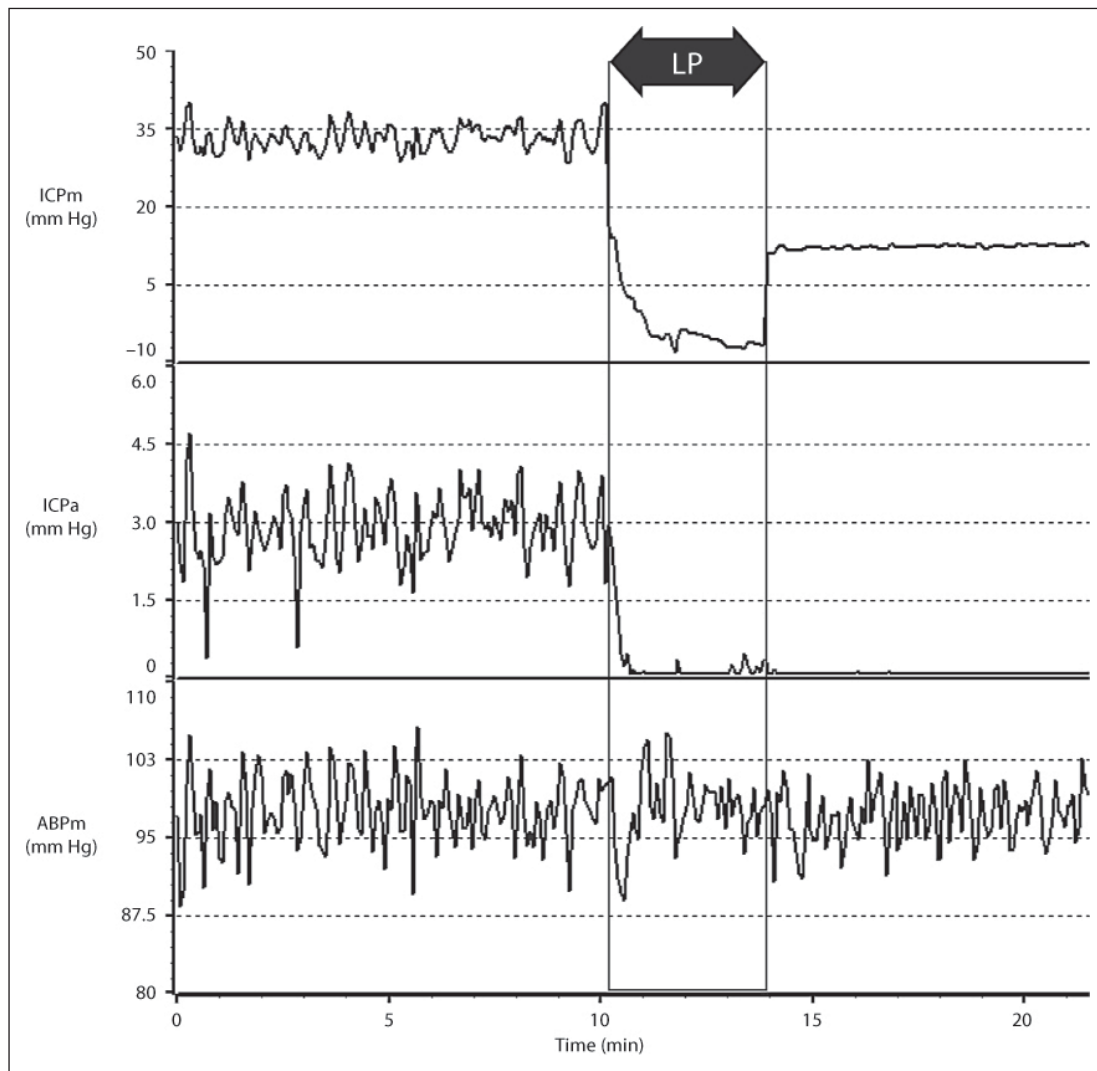


Fig. 1. Example of a recording (patient 4). Intracranial pressure mean (ICPm) and ICP pulse amplitude (ICPa) are measured with a lumbar needle. ICP is elevated (mean 33 mm Hg) demonstrating an intracranial hypertension at baseline. Arterial blood pressure mean (ABPm) is measured noninvasively. At 10 min, 20 ml of CSF are drained via a 3-way tap; ICPm and ICPa drop immediately. At 14 min, the 3-way tap is closed. ICPm and ICPa are below the baseline value. ABP is stable.

mm Hg). CPP increased significantly from 73.1 ± 8.4 to 94.7 ± 8.5 mm Hg ($p = 0.02$) as a direct consequence of the drop in ICP.

Cerebral Hemodynamic Analysis

Descriptive Individual Analysis

We first performed descriptive semiquantitative regional CBF analysis: for each patient we imaged the increase and decrease in blood flow after LP (fig. 2).

Patient 1 (anterior communicating artery, AcomA): increase in rCBF in the bifrontal and left temporal regions; reduction in the posterior and right parieto-occipital area.

Patient 2 (AcomA): global reduction in rCBF; increase in blood flow in very limited regions.

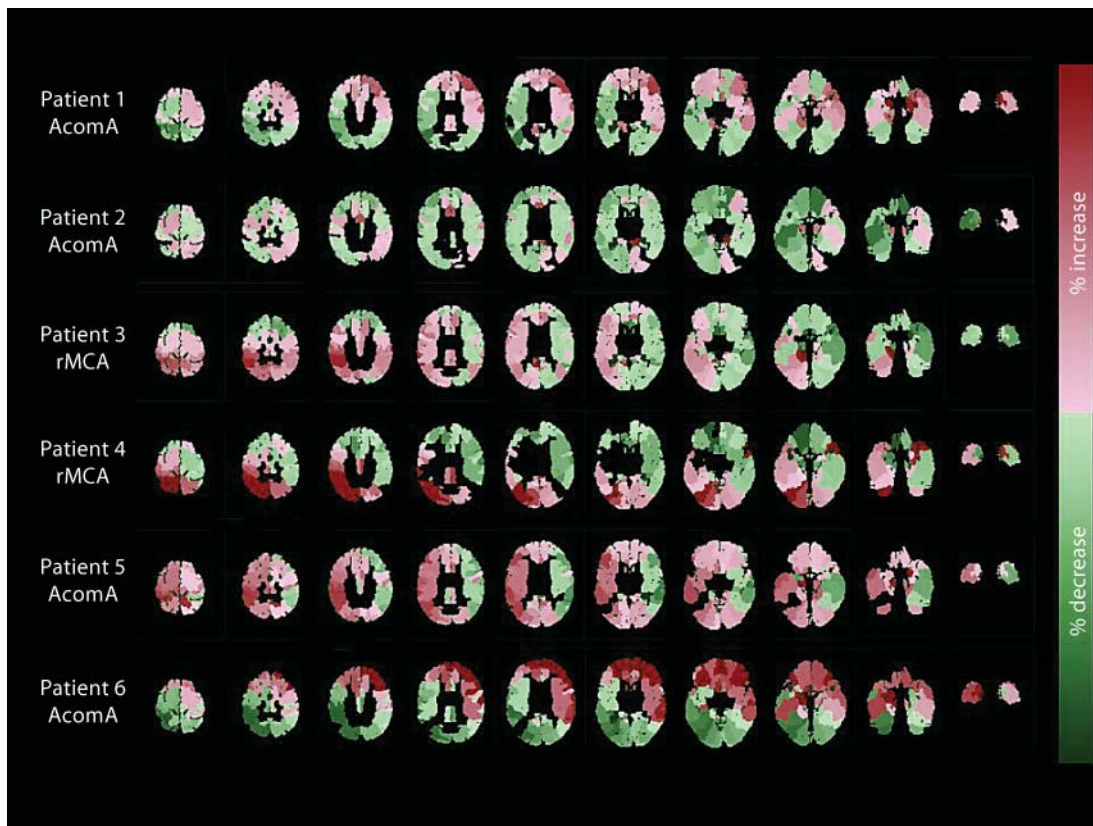


Fig. 2. Axial view of individual rCBF changes. For each patient, we imaged semiquantitatively the changes in regional CBF after a 20-ml LP. Red means increase in blood flow after the LP, whereas green means decrease in rCBF. Note the heterogeneity of the cerebrovascular reactivity after an LP, and the biphasic effect with increase in blood flow on one side and decrease on the other side.

Patient 3 (right middle cerebral artery, rMCA): rCBF augmented prominently on the right hemisphere; parallel diminution on the left.

Patient 4 (rMCA): increase on the right hemisphere and posteriorly; rCBF was reduced on the left.

Patient 5 (AcomA): increase bifrontally and in the right hemisphere; reduction on the left temporal.

Patient 6 (AcomA): augmentation in the bifrontal and reduction in the posterior regions.

Overall, LP seems to yield a heterogeneous and biphasic effect: rCBF increases in one area of the brain, and a rather symmetrical decrease took place on the opposite side. This biphasic effect has roughly a bilateral symmetry, with a coronal plane symmetry in AcomA aneurysm patients, and sagittal plane symmetry in patients with rMCA aneurysm.

Statistical Group Analysis

We performed a statistical analysis of the AcomA group (n = 4) and color-coded augmentation and reduction of blood flow on a brain surface rendering (fig. 3). The LP produced a significant increase in rCBF mainly in the bifrontal and interhemispheric region, wider than the strict AcomA vascular territory, and a significant reduction of blood flow in the posterior part of the brain. The increase (resp. decrease) in rCBF took place in regions close to (resp. remote from) the bleed.

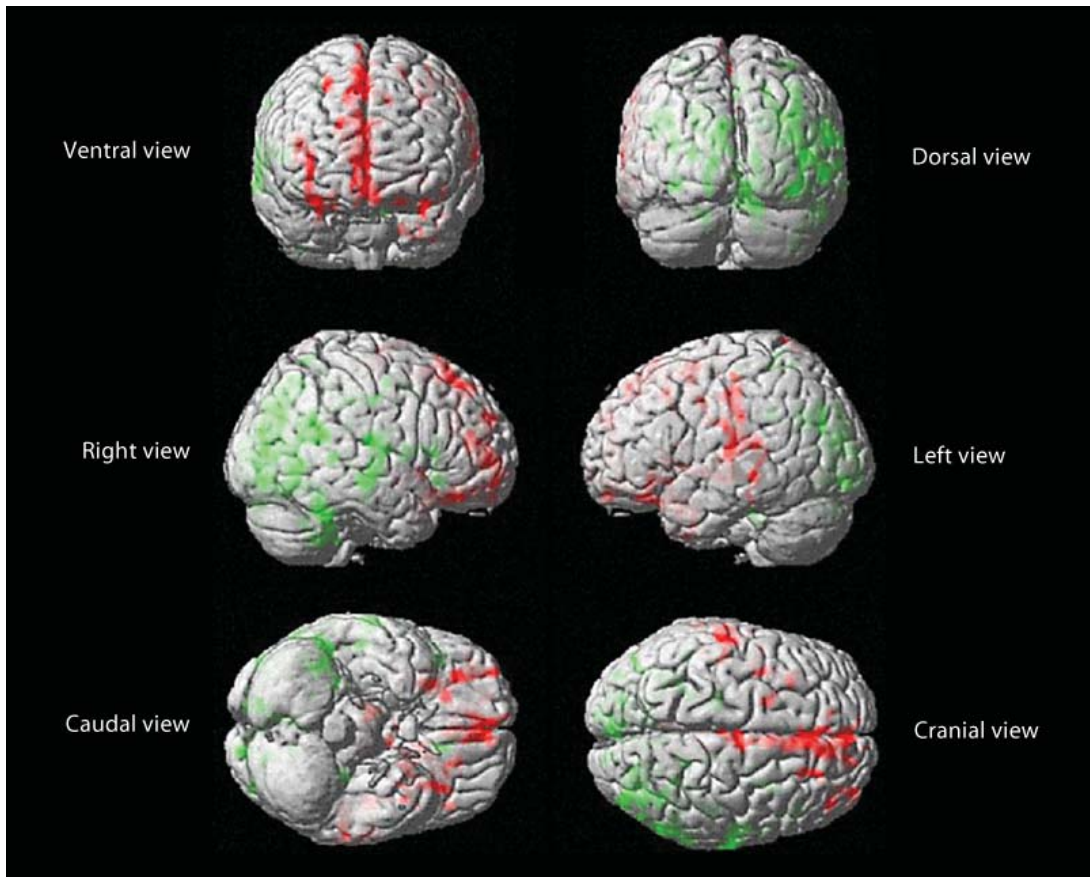


Fig. 3. Statistically significant change in rCBF on a brain surface rendering. AcomA subgroup (n = 4, Z score >3.2). Changes in regional blood flow following a 20-ml LP, color-coded on a brain surface rendering. An increase in blood flow, represented in red, was prominent in the anterior interhemispheric region, but also in the bifrontal area with blood in the subarachnoid space. A decrease in blood flow, in green, was identified in the brain tissue remote from the bleed, especially in the posterior part of the brain.

Conclusions

This prospective study provides novel and clinically important information on the consequences of subtractive LP in good-grade SAH patients.

After SAH, outcome depends on primary brain insults, which are not preventable, but also on secondary insults like vasospasm, delayed ischemic deficit and hydrocephalus, which are potentially preventable. Patients with good-grade SAH are initially in good neurological status as they did not encounter massive primary insults, but can present subtle neurological signs which are associated with worse outcome [6]. These fragile patients without initial deficit can die or present severe deficit due to secondary lesions leading to brain ischemia [11]. LP might be a clinically useful tool to reduce ICP and ameliorate blood delivery to the brain.

To our knowledge, this is the first case series that addresses the consequences of an LP in good-grade SAH patients, in terms of pain, brain biophysics and cerebral hemodynamics. This is also the first time that cerebrovascular reactivity is imaged in vivo, in a fragile SAH population, following a drop in ICP.

Patients with SAH Are at Risk of Ischemia

After SAH, an oligemic context has been demonstrated in both experimental and clinical investigations heralding a brain energy failure [4].

In our patients, brain energy production could be jeopardized due to secondary insults: rebleed, vasospasm and hydrocephalus. Rebleed was avoided by rapid coiling of the aneurysm. Vasospasm is a SAH-specific complication related to the narrowing of the vessels on the angiography. Vasospasm appears from day 2 to 15, and peaks at day 4 to 7 [12]. Only 30% of the patients with vasospasm actually develop neurological signs, a condition termed delayed ischemic deficit (DID) [12]. DID is correlated with up to 3-fold increase in mortality within the first 2 weeks after SAH [13]. But vasospasm does not resume vascular dysfunction after SAH [14]. Hydrocephalus might also produce secondary lesion after SAH, but its incidence is underevaluated. Acute ventricular dilation after SAH is reported up to 30%, most of the time associated with raised ICP and clinical worsening [15]. Acute hydrocephalus with raised ICP might impede the blood delivery. Indeed ICP and vascular wall tension represent constricting forces acting on the vessel; on the contrary, ABP is a dilating force [16, 17]. Hence raised ICP should constrict the vessels and reduce blood delivery. Draining CSF should reduce ICP and dilate the cerebral vasculature. But thanks to autoregulation, vascular smooth muscle cells should constrict to maintain CBF constant [18]. If autoregulation is efficient, a reduction of ICP should not influence blood delivery.

CSF Withdrawal and Brain Biomechanics

Our data demonstrates a biomechanical hazard to the brain with raised ICP and deranged pressure-volume compensatory reserve, i.e. inability of the craniospinal space to tolerate volume changes. As expected, LP seems to have a significant effect to reduce ICP but also to ameliorate the craniospinal compliance, at least temporarily. In good-grade SAH, a 20-ml LP seems to be an interesting tool to improve the biomechanical conditions that act onto the brain.

Changes in CBF Induced by an LP

We analyzed how the blood flow is actively redistributed within the brain after a drop in ICP, in other words how reactive the brain microcirculation is to maintaining constant blood flow. Our data suggest a heterogeneous and biphasic cerebrovascular reactivity due to the sole ICP drop induced by an LP. There are various ways to address cerebrovascular reactivity: acetazolamide, CO₂, ABP change, etc. Our study refers to a different approach: ICP drop is a pure biomechanical trigger irrespective of any indirect or systemic effect. Our results advocate for a heterogeneous and biphasic effect of LP on cerebral hemodynamics. It seems that rCBF augmented in the brain's region with blood in the subarachnoid space and was reduced on the opposite side of the brain. To our knowledge, this is the first time that small-vessel reactivity is imaged without any pharmacological mean after SAH. In two recent studies, heterogeneity of CBF has been demonstrated to be associated with worse clinical outcome [19, 20]. Our study does not confirm the heterogeneity of blood flow, but suggests that microcirculation reactivity is also heterogeneous and surprisingly biphasic.

A 20-ml LP seems to increase blood flow in certain regions of the brain tissue. An increase in rCBF after a drop in ICP heralds a defective autoregulation as stated above. Autoregulation and vasospasm are two intermingled phenomena: alteration of autoregulation seems to precede and be magnified by vasospasm [21], but also to be a predictor of DID [22]. Our results suggest an altered autoregulation in the SAH region. A 20-ml LP seems to produce also a reduction of the blood delivery in various regions, surprisingly in the brain tissue remote from the bleed. This hemodynamic pattern has never been described before, and relates neither to a steal phenomenon nor to autoregulation. The reduction of blood flow has

to be a consequence of an active vasoconstriction of the local microcirculation, overtaking the relative vasodilation due to the drop in ICP. In normal brain, the blood flow control depends on pressure responsiveness, vasoactive agents, and on local neuronal activity. The neuronal control plays a major role in the regulation of vascular tone and brain perfusion. It is a key determinant in the spatial and temporal adaptation of local blood distribution [23]. After SAH, the sympathetic system is overactive and brain vessel sensitivity to catecholamine is also increased [24]. The unexpected drop in blood flow could be due – at least partially – to a derangement of the neuronal vascular control.

LP in the Armamentarium of SAH

In good-grade SAH, the current therapeutic strategies to avoid stroke is to prevent insults of systemic origin, administer painkiller, nimodipin, statin and to address large-artery vasospasm with angiography.

We demonstrated that within a one-hour time frame, LP improves headaches, reduces ICP, ameliorates the pressure-volume compensatory reserve and has a significant effect on cerebral blood flow. In this study, we cannot state whether LP prevents the constitution of vasospasm or DID, or improves blood flow. However, the clinical benefit of CSF withdrawal has been suggested in other retrospective studies: CSF lumbar drainage protocol seems to reduce the risk of DID and to improve outcome [25, 26]. Lumbar drain could remedy intracranial hypertension, improve brain biomechanics and potentially ameliorate blood delivery to the brain. CSF withdrawal might also be useful to remove biochemical compounds that might contribute to microvessel dysfunction favoring vasospasm, like bilirubin oxidation products (BOXes) [2].

Limits of the Study

Our study has two major limits: the low recruitment and the poor temporal analysis. The low recruitment is the burden of acute PET studies and has been addressed in details in the Methods chapter. PET scanner has an excellent spatial but a poor temporal resolution. The study was designed to analyze the one-hour time frame effects of an LP in good-grade SAH patients. The mid- and long-term effects of an LP needs further work in a larger group.

Funding

This work was supported by a grant from the Clinical Research Hospital Program from the French Ministry of Health (PHRC 2004-03108). The authors have no conflict of interest to declare.

References

- 1 Sarrafzadeh AS, Haux D, Lüdemann L, Amthauer H, Plotkin M, Küchler I, Unterberg AW: Cerebral ischemia in aneurysmal subarachnoid hemorrhage: a correlative microdialysis-PET study. *Stroke* 2004;35:638–643.
- 2 Dietrich HH, Dacey RG Jr: Molecular keys to the problems of cerebral vasospasm. *Neurosurgery* 2000;6:517–530.
- 3 Heuer GG, Smith MJ, Elliott JP, Winn HR, LeRoux PD: Relationship between intracranial pressure and other clinical variables in patients with aneurysmal subarachnoid hemorrhage. *J Neurosurg* 2004;101:408–416.

- 4 Hayashi T, Suzuki A, Hatazawa J, Kanno I, Shirane R, Yoshimoto T, Yasui N: Cerebral circulation and metabolism in the acute stage of subarachnoid hemorrhage *J Neurosurg* 2000;93:1014–1018.
- 5 Drake CG: Report of World Federation of Neurological Surgeons Committee on a Universal Subarachnoid Haemorrhage Scale. *J Neurosurg* 1988;68:985–986.
- 6 Leira EC, Davis PH, Martin CO, Torner JC, Yoo B, Weeks JB, Hindman BJ, Todd MM: Improving prediction of outcome in ‘good grade’ subarachnoid hemorrhage. *Neurosurgery* 2007;61:470–473.
- 7 Lenfeldt N, Koskinen LO, Bergenheim AT, Malm J, Eklund A: CSF pressure assessed by lumbar puncture agrees with intracranial pressure. *Neurology* 2007;68:155–158.
- 8 Speck V, Staykov D, Huttner HB, Sauer R, Schwab S, Bardutzky J: Lumbar catheter for monitoring of intracranial pressure in patients with post-hemorrhagic communicating hydrocephalus. *Neurocrit Care* 2011;14:208–215.
- 9 Smielewski P, Czosnyka M, Zabolotny W, Kirkpatrick P, Richards H, Pickard JD: A computing system for the clinical and experimental investigation of cerebrovascular reactivity. *Int J Clin Monit Comput* 1997;14:185–198.
- 10 Kim DJ, Czosnyka Z, Keong N, Radolovich DK, Smielewski P, Sutcliffe MP, Pickard JD, Czosnyka M: Index of cerebrospinal compensatory reserve in hydrocephalus. *Neurosurgery* 2009;64:494–501.
- 11 Bederson JB, Awad IA, Wiebers DO, Piepgras D, Haley EC Jr, Brott T, Hademenos G, Chyatte D, Rosenwasser R, Caroselli C: Recommendations for the management of patients with unruptured intracranial aneurysms: A Statement for healthcare professionals from the Stroke Council of the American Heart Association. *Stroke* 2000;31:2742–2750.
- 12 Macdonald RL: Management of cerebral vasospasm. *Neurosurg Rev* 2006;29:179–193.
- 13 Treggiari-Venzi MM, Suter PM, Romand JA: Review of medical prevention of vasospasm after aneurysmal subarachnoid hemorrhage: a problem of neurointensive care. *Neurosurgery* 2001;48:249–261.
- 14 Stein SC, Levine JM, Nagpal S, LeRoux PD: Vasospasm as the sole cause of cerebral ischemia: how strong is the evidence? *Neurosurg Focus* 2006;21:E2.
- 15 Van Gijn J, Hijdra A, Wijdicks EF, Vermeulen M, van Crevel H: Acute hydrocephalus after aneurysmal subarachnoid hemorrhage. *J Neurosurg* 1985;63:355–362.
- 16 Bayliss WM: On the local reactions of the arterial wall to changes of internal pressure. *J Physiol* 1902;28:220–231.
- 17 Burton AC: On the physical equilibrium of the small blood vessels. *Am J Physiol* 1951;164:319–329.
- 18 Johnson PC: The myogenic response; in: *Handbook of Physiology. The Cardiovascular System. Vascular Smooth Muscle*. Bethesda, MD: Am Physiol So. 1980, sect. 2, vol. II, chapt. 15.
- 19 Mustonen T, Koivisto T, Vanninen R, Hänninen T, Vapalahti M, Hernesniemi J, Kuikka JT, Vanninen E: Heterogeneity of cerebral perfusion 1 week after haemorrhage is an independent predictor of clinical outcome in patients with aneurysmal subarachnoid haemorrhage. *J Neurol Neurosurg Psychiatry* 2008;79:1128–1133.
- 20 Dankbaar JW, de Rooij NK, Smit EJ, Velthuis BK, Frijns CJ, Rinkel GJ, van der Schaaf IC: Changes in cerebral perfusion around the time of delayed cerebral ischemia in subarachnoid hemorrhage patients. *Cerebrovasc Dis* 2011;32:133–140.
- 21 Lang EW, Diehl RR, Mehdorn HM: Cerebral autoregulation testing after aneurysmal subarachnoid hemorrhage: the phase relationship between arterial blood pressure and cerebral blood flow velocity. *Crit Care Med* 2001;29:158–163.
- 22 Soehle M, Czosnyka M, Pickard JD, Kirkpatrick PJ: Continuous assessment of cerebral autoregulation in subarachnoid hemorrhage. *Anesth Analg* 2004;98:1133–1139.
- 23 Hamel E: Perivascular nerves and the regulation of cerebrovascular tone. *J Appl Physiol* 2006;100:1059–1064.
- 24 Hansen Schwartz JAS, Edvinson L: Subarachnoid hemorrhage: extravasation of blood in the subarachnoid space; in: Edvinson L, Krause DN (eds): *Cerebral Blood Flow and Metabolism*. Philadelphia: Lippincott Williams & Wilkins 2002. Chapt. 30.
- 25 Klimo P Jr, Kestle JR, MacDonald JD, Schmidt RH: Marked reduction of cerebral vasospasm with lumbar drainage of cerebrospinal fluid after subarachnoid hemorrhage. *J Neurosurg* 2004;100:215–224.
- 26 Kwon OY, Kim YJ, Kim YJ, Cho CS, Lee SK, Cho MK: The Utility and Benefits of External Lumbar CSF Drainage after Endovascular Coiling on Aneurysmal Subarachnoid Hemorrhage. *J Korean Neurosurg Soc* 2008;43:281–287.