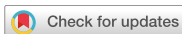

Case Report
Infectious Diseases,
Microbiology & Parasitology



Subacute Thyroiditis After Receiving the mRNA COVID-19 Vaccine (Moderna): The First Case Report and Literature Review in Korea

Min Jhon ,^{1*} Sun-Ho Lee ,^{2*} Tae-Hoon Oh ,³ and Ho-Cheol Kang ⁴

¹Department of Psychiatry, Chonnam National University Medical School, Gwangju, Korea

²Department of Orthopedic Surgery, Chonnam National University Hospital, Chonnam National University Medical School, Gwangju, Korea

³Division of Infectious Diseases, Department of Internal Medicine, Chonnam National University Hospital, Chonnam National University Medical School, Gwangju, Korea

⁴Division of Endocrinology and Metabolism, Department of Internal Medicine, Chonnam National University Medical School, Gwangju, Korea



Received: Nov 24, 2021

Accepted: Dec 28, 2021

Published online: Jan 24, 2022

Address for Correspondence:

Ho-Cheol Kang, MD, PhD

Division of Endocrinology and Metabolism,
Department of Internal Medicine, Chonnam
National University Medical School, 160
Baekseo-ro, Dong-gu, Gwangju 61469,
Republic of Korea.

Email: drkang@chonnam.ac.kr

*Min Jhon and Sun-Ho Lee contributed
equally to this work.

© 2022 The Korean Academy of Medical
Sciences.

This is an Open Access article distributed
under the terms of the Creative Commons
Attribution Non-Commercial License (<https://creativecommons.org/licenses/by-nc/4.0/>)
which permits unrestricted non-commercial
use, distribution, and reproduction in any
medium, provided the original work is properly
cited.

ORCID iDs

Min Jhon

<https://orcid.org/0000-0002-0408-768X>

Sun-Ho Lee

<https://orcid.org/0000-0003-4792-0034>

Tae-Hoon Oh

<https://orcid.org/0000-0003-0788-5780>

Ho-Cheol Kang

<https://orcid.org/0000-0002-0448-1345>

ABSTRACT

Subacute thyroiditis (SAT) is a painful thyroiditis that often requires steroid therapy. Here, we report the first case of severe SAT in a patient who received the first dose of mRNA coronavirus disease 2019 (COVID-19) vaccination. A 34-year-old man without a viral prodrome felt a lump when swallowing 5 days after his first dose of mRNA-1273 (Moderna) vaccination. Ten days after vaccination, the patient visited the hospital and was advised to rest and take nonsteroidal anti-inflammatory drugs. He revisited the hospital 10 days later as symptoms aggravated with anterior neck pain, headache, fatigue, muscle weakness, and weight loss. Thyroid hormone levels and inflammatory markers were consistent with thyrotoxicosis. A thyroid ultrasound scan revealed typical SAT findings. His symptoms rapidly improved after receiving prednisone. A week later, the patient successfully completed his second dose of the vaccine. The thyroid function test results were nearly normal 1 month after the completion of the vaccination. We report this case to raise awareness of the occurrence of SAT after COVID-19 vaccination. As the risk of COVID-19 outweighs the minor risks of the vaccine, managing the side effects of the first vaccine dose is crucial to complete COVID-19 vaccination.

Keywords: COVID-19; COVID-19 Vaccines; mRNA-1273 Vaccine; Subacute Thyroiditis; Anterior Neck Pain

INTRODUCTION

Subacute thyroiditis (SAT) is a painful thyroiditis presumed to be caused by viral infection or a post-viral inflammatory process. However, there are also reports of SAT after the administration of viral vaccinations, such as the seasonal flu vaccine.¹ As the rate of vaccination against coronavirus disease 2019 (COVID-19) has risen worldwide, reports of COVID-19 vaccine-related SAT are increasing.²⁻¹⁷ However, previous reports did not mention the completion of the COVID-19 vaccine when the SAT developed after the first dose of vaccination. Here, we present the first case of severe SAT in Korea in a patient who had received the first dose of mRNA-1273 vaccine (Moderna) and successfully completed his

Disclosure

The authors have no potential conflicts of interest to disclose.

Author Contributions

Conceptualization: Jhon M, Kang HC. Formal analysis: Jhon M, Oh TH. Investigation: Lee SH. Methodology: Jhon M. Writing - original draft: Jhon M, Lee SH. Writing - review & editing: Kang HC, Jhon M, Lee SH.

second dose during the treatment. Further, we summarized 22 patients who were previously reported to develop SAT following COVID-19 vaccination.

CASE DESCRIPTION

A 34-year-old male physician was admitted to the endocrinology outpatient clinic on the 20th day after the first dose of mRNA-1273 vaccination. He reported fatigue, headache, weakness in the lower extremities, sweating, and weight loss, which started 5 days after the first dose of the vaccine; the first symptom was a lump sensation when swallowing. The course of the vaccination and his symptoms are shown in Fig. 1. As the patient was a physician, he assumed that the symptoms were the common side effects of vaccination, such as neck lymphadenopathy, which was reported after mRNA-1273 vaccination. As symptoms worsened, he visited the infectious disease outpatient clinic on the 10th day after vaccination. At that time, his physical examination was unremarkable. The serum polymerase chain reaction assay, electrocardiography, chest radiography, and laboratory tests showed no evidence of COVID-19 or other known side effects of COVID-19 vaccination, such as myocarditis (Supplementary Table 1, Supplementary Figs. 1 and 2). He was advised to rest, and nonsteroidal anti-inflammatory drugs were prescribed; however, the symptoms persisted.

At presentation, his body temperature was 37.8°C, and he had sinus tachycardia (108/min). Physical examination revealed goiter, and pain was observed when it was touched. His

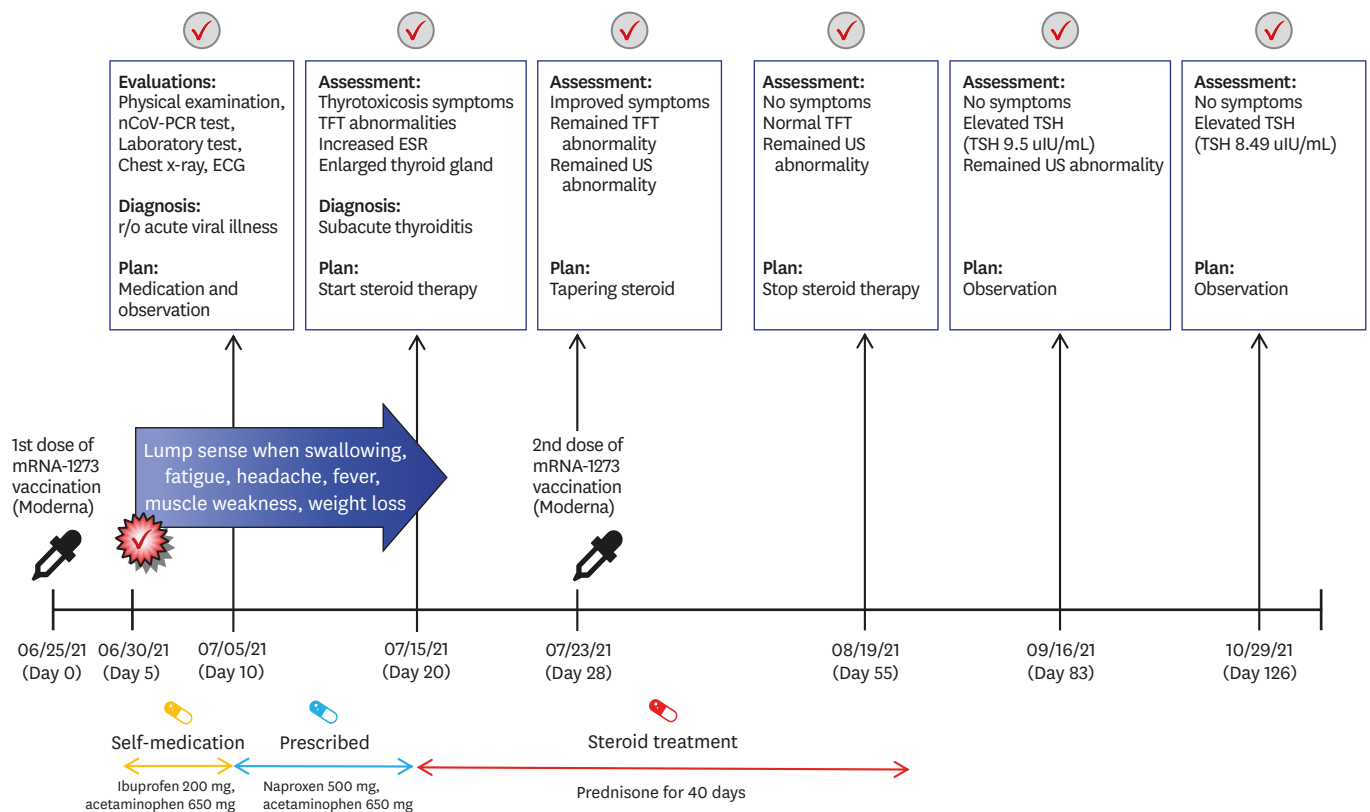


Fig. 1. Timeline of the symptoms, diagnosis and treatment of subacute thyroiditis after mRNA-1273 vaccination (Moderna). nCoV-PCR = novel coronavirus polymerase chain reaction, ECG = electrocardiogram, TFT = thyroid function tests, US = ultrasound scan, ESR = erythrocyte sedimentation rate, TSH = thyroid-stimulating hormone.

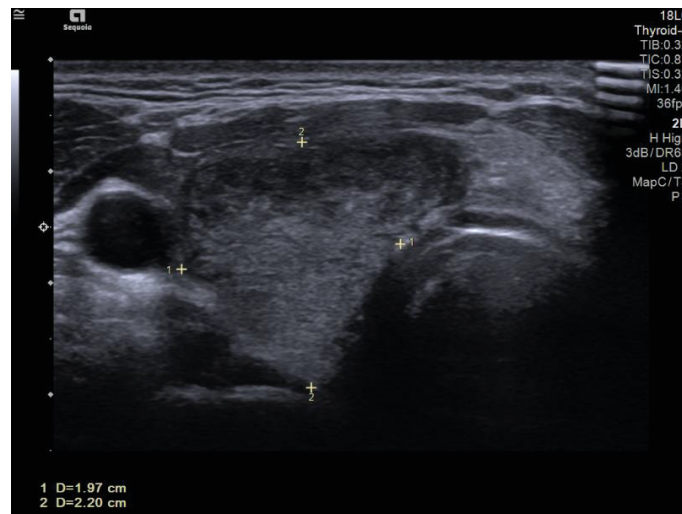


Fig. 2. Thyroid US image demonstrates enlarged thyroid gland (1.97 × 2.20 cm) with heterogeneous echotexture granuloma at the patient's second visit to hospital. US = ultrasound scan.

thyroid hormone levels and inflammatory markers were consistent with thyrotoxicosis: thyroid-stimulating hormone (TSH) 0.005 μ IU/mL (normal range, 0.4–4.8 μ IU/mL), T3 2.82 ng/ml (normal range, 0.6–1.6 ng/mL), free T4 4.35 ng/dL (normal range, 0.8–1.71 ng/dL), C-reactive protein 6.54 mg/dL (normal range, 0–0.3 mg/dL), and sedimentation 79 mm/hr (normal range, 0–26 mm/hr). Thyroid autoantibody levels were normal: anti-microsome Ab < 9 IU/mL (normal range, 0.4–4.8 IU/mL), anti-thyroglobulin antibody 11.10 IU/mL (normal range, 0–115 IU/mL), and thyroid-stimulating immunoglobulin 0.1 IU/L (normal range, 0–1.5 IU/L). Thyroid ultrasonography (USG) demonstrated typical SAT findings, including an enlarged thyroid gland and heterogeneous echotexture (Fig. 2). Prednisone 30 mg was initiated, and his symptoms rapidly improved after medication. A week later, he received a second dose of the mRNA-1273 vaccine as scheduled while taking 22.5 mg of prednisone. He further had no symptoms associated with SAT and took prednisone for a total of 40 days, which was slowly tapered.

On the 55th day, his thyroid hormone level normalized (TSH, 0.288 μ IU/mL; T3, 0.72 ng/mL; and free T3, 0.81 ng/dL), but the USG revealed an enlarged thyroid gland. On the 83rd day, the TSH level increased to 9.5 μ IU/mL. As his free T4 level (0.85 ng/dL) was in normal range, he was observed without any medication and TSH level slightly decreased to 8.5 μ IU/mL (day 126). The patient experienced symptoms associated with SAT.

Ethics statement

Informed consent for publication of clinical data was obtained from the case patient.

DISCUSSION

To the best of our knowledge, this is the first case of SAT caused by mRNA vaccination against COVID-19 in Korea. The patient developed SAT after the first dose of mRNA-1273 COVID-19 vaccination (Moderna) and completed the second dose while being treated for SAT.

SAT is presumed to be caused by a viral infection in which many patients have a viral prodrome typically 2 to 8 weeks beforehand. Adenovirus, enterovirus, influenza virus, coxsackievirus, mumps, measles, and other viruses have been reported as possible agents in SAT.¹⁸ Although the pathogenesis of SAT is not yet clearly defined, it is thought to be associated with genetically predisposed individuals who carry certain human leukocyte antigen (HLA) haplotypes.¹⁹ A unifying hypothesis is that an antigen from the viral infection binds to HLA-B35 molecules on macrophages, which activates cytotoxic T lymphocytes that damage thyroid follicular cells. Furthermore, cases of SAT are also seen after viral vaccinations, such as the seasonal flu vaccine.¹ One is thought that viral antigens in the vaccine may damage thyroid cells, similar to infectious agents. The other is autoimmune/inflammatory syndrome induced by vaccine adjuvants.²⁰

SAT has been reported following severe acute respiratory syndrome coronavirus 2 infection since the emergence of the COVID-19 pandemic,^{21,22} and more recently, cases of SAT associated with COVID-19 vaccination have increased rapidly. To date, a total of 16 reports with 22 SAT cases after vaccination against COVID-19 have been reported.²⁻¹⁷ The clinical features of each patient, including our patient, are summarized in **Table 1**. Six types of vaccines have been reported to be associated with SAT: AstraZeneca (6 cases),^{2,4,8,9,13} CoronaVac (5 cases),^{6,14,15} Pfizer-BioNTech (4 cases),^{5,7,11,16} Moderna (3 cases),^{2,12} Janssen (1 case),⁸ Covaxin (1 case)¹⁷ and cases that did not include the type of vaccine (3 cases).^{3,10} There were more cases of SAT after the first dose (13/23 cases) than after the second dose (10/23 cases). Most patients were female (18/23 cases), and patients ages ranged from 26 to 75 years (median, 40 years). The median number of days for the development of symptoms after vaccination was 7 days (range, 5–21 days). It took about median 2 weeks from the onset of symptoms to the diagnosis, but it ranged from 6 days to 10 weeks. Of the 23 patients, 13 required steroid therapy. As compared with 8 cases of SAT after influenza vaccine (time of exposures, 2 days to 8 weeks; treatment, steroid use among 4 cases),¹ SAT associated with COVID-19 vaccine seems to develop around 7 days after the injection and commonly requires steroids. This may occur regardless of the vaccine type and shots. Females seem to be more vulnerable as they are known to be risk factors for typical SATs. It seems that it takes about 2 weeks to diagnose because the development of SAT after COVID-19 vaccination is not well known.

Our patient completed the second dose while receiving steroid treatment. With respect to safety, vaccination undergoing steroid treatment was concerned with the setting of live vaccination and at systemic doses equivalent to 2 mg/kg or a dose of 20 mg per day of prednisone equivalents for 2 or more weeks. Although our patient started taking 30 mg of prednisone a week ago, the vaccine did not employ live viruses, so we did not anticipate any problems. With respect to efficacy, previous data demonstrate that chronic high-dose steroids may impair vaccine-based immunity, but its efficacy is small.²³ Since the symptoms caused by SAT were severe, our patient could not delay or stop the steroid treatment. The safety and efficiency of steroid use in COVID-19 vaccinations require further research.

More than 70% of the Korean population has received a COVID-19 vaccine and booster vaccination shots have recently begun. We report this case to raise awareness of the occurrence of SAT after COVID-19 vaccination as its symptoms can severely interfere with the patients' daily lives. To the best of our knowledge, this is the first case of a patient who completed vaccination with appropriate treatment for SAT. SAT can be mistaken as a common side effect of COVID-19 vaccination. The general side effects of vaccination usually resolve within 2–3 days. If anterior neck pain with fatigue, fever, and muscle pain persists unlike the usual course of post-vaccination symptoms, clinicians should consider SAT as a cause.

Subacute Thyroiditis After COVID-19 Vaccination

Table 1. Clinical features of patients previously reported to develop subacute thyroiditis after coronavirus disease 2019 vaccination

Author	Type of vaccine	Number of shots	Age/sex	Time of symptoms onset	Chief complaints	Symptom duration until diagnosis	Medication
Current	mRNA-1273 (Moderna)	1st shot	34/Male	5 days	Anterior neck pain, fatigue, headache, fever, tachycardia, weight loss	15 days	Acetaminophen naproxen After diagnosis: prednisone 30 mg
Patient 1 ²	mRNA-1273 (Moderna)	1st shot	49/Female	1 week	Headache, cervical sore throat	3 weeks	Diclofenac, prednisolone
Patient 2 ¹²	mRNA-1273 (Moderna)	2nd shot	42/Female	5 days	Earache radiating down to the lateral and anterior neck and bilateral lower jaw	-	Nonsteroidal anti-inflammatory drugs, prednisone
Patient 3 ⁵	BNT162b2 (Pfizer-BioNTech)	1st shot	42/Female	5 days	Sore throat, palpitations, tachycardia	10 days	Prednisone, propranolol
Patient 4 ¹⁶	BNT162b2 (Pfizer-BioNTech)	1st shot	51/Female	4 days	Nausea, mild anterior neck pain and fever	11 days	Methylprednisolone
Patient 5 ¹¹	BNT162b2 (Pfizer-BioNTech)	2nd shot	57/Female	2 days	Anterior neck pain and swelling, fever	12 days	Propranolol, ibuprofen, prednisone
Patient 6 ⁷	BNT162b2 (Pfizer-BioNTech)	2nd shot	Middle-aged/Female	2 weeks	Painful swelling of the thyroid gland, poor sleep, night sweats, hyper defecation and weight loss	-	Nonsteroidal anti-inflammatory drugs
Patient 7 ³	COVID-19 mRNA vaccine	1st shot	35/Female	12 days	Acute neck pain radiating to the jaw and ear, fatigue, and rare palpitations	-	Prednisone
Patient 8 ³	COVID-19 mRNA vaccine	2nd shot	32/Female	4 days	Neck pain radiating to the jaw and ear, and mild fatigue	-	Prednisone
Patient 9 ⁹	ChAdOx1 nCoV-19 (Oxford-AstraZeneca)	1st shot	55/Female	3 weeks	Neck pain and swelling, headache, sore throat, generalized aches, palpitations	4 weeks	Propranolol, ibuprofen, paracetamol 6 weeks later: levothyroxine
Patient 10 ¹³	ChAdOx1 nCoV-19 (Oxford-AstraZeneca)	1st shot	75/Male	14 days	Pain and tenderness in front neck, shortness of breath, palpitations, insomnia, anxiety	10 weeks	Ibuprofen
Patient 11 ²	ChAdOx1 nCoV-19 (Oxford-AstraZeneca)	1st shot	26/Female	2 days	Cervical pain, fever, chill	2 weeks	Ibuprofen, prednisone
Patient 12 ⁸	ChAdOx1 nCoV-19 (Oxford-AstraZeneca)	1st shot	73/Female	11 days	Fever, neck pain	-	-
Patient 13 ⁴	ChAdOx1 nCoV-19 (Oxford-AstraZeneca)	1st shot	47/Female	3 weeks	Fever, neck pain, restlessness, difficulty in swallowing and weight loss of 3 kg	2 weeks	Propranolol
Patient 14 ⁸	ChAdOx1 nCoV-19 (Oxford-AstraZeneca)	2nd shot	39/Female	4 days	Neck pain	-	-
Patient 15 ⁶	SARS-CoV-2 (CoronaVac)	1st shot	34/Female	4 days	Anterior neck pain, fatigue, weight loss	-	Methylprednisolone, propranolol
Patient 16 ⁶	SARS-CoV-2 (CoronaVac)	2nd shot	35/Female	4 days	Severe anterior neck pain, palpitation	15 days	Methylprednisolone, propranolol
Patient 17 ⁶	SARS-CoV-2 (CoronaVac)	2nd shot	37/Female	7 days	Mild anterior neck pain	-	Rarely need paracetamol
Patient 18 ¹⁴	SARS-CoV-2 (CoronaVac)	2nd shot	67/Male	10 days	Hypertension complaints, fever, weight loss, mild anterior neck pain	7 days	Ibuprofen
Patient 19 ¹⁵	SARS-CoV-2 (CoronaVac)	2nd shot	38/Female	2 weeks	Swelling in the neck, pain, fatigue, loss of appetite and sweating in the evening	-	Naproxen sodium, propranolol On the 30th day: levothyroxine
Patient 20 ⁸	JNJ-78436735 (Janssen)	1st shot	39/Male	14 days	Fever, neck pain	-	-
Patient 21 ¹⁷	COVAXIN (The Bharat Biotech COVID-19 Vaccine)	1st shot	34/Female	5 days	Mild fever, palpitation, and radiating anterior neck pain	6 days	Prednisone, propranolol
Patient 22 ¹⁰	-	2nd shot	48/Male	1 week	Neck swelling, throat discomfort, palpitations, fevers, and weight loss	3 weeks	Nonsteroidal anti-inflammatory drugs, prednisone

SUPPLEMENTARY MATERIALS

Supplementary Table 1

Serial laboratory data

[Click here to view](#)

Supplementary Fig. 1

EKG on presentation.

[Click here to view](#)

Supplementary Fig. 2

Chest X-ray on presentation. Chest X-ray for case patient shows normal finding.

[Click here to view](#)

REFERENCES

1. Bragazzi NL, Hejly A, Watad A, Adawi M, Amital H, Shoenfeld Y. ASIA syndrome and endocrine autoimmune disorders. *Best Pract Res Clin Endocrinol Metab* 2020;34(1):101412.
[PUBMED](#) | [CROSSREF](#)
2. Bornemann C, Woyk K, Bouter C. Case report: two cases of subacute thyroiditis following SARS-CoV-2 vaccination. *Front Med (Lausanne)* 2021;8:737142.
[PUBMED](#) | [CROSSREF](#)
3. Chatzi S, Karampela A, Spiliopoulou C, Boutzios G. Subacute thyroiditis after SARS-CoV-2 vaccination: a report of two sisters and summary of the literature. *Hormones (Athens)* 2021:1-3.
[PUBMED](#) | [CROSSREF](#)
4. Das L, Bhadada SK, Sood A. Post-COVID-vaccine autoimmune/inflammatory syndrome in response to adjuvants (ASIA syndrome) manifesting as subacute thyroiditis. *J Endocrinol Invest* 2021:1-3.
[PUBMED](#) | [CROSSREF](#)
5. Franquemont S, Galvez J. Subacute thyroiditis after mRNA vaccine for COVID-19. *J Endocr Soc* 2021;5(Suppl 1):A956-7.
[CROSSREF](#)
6. İremli BG, Şendur SN, Ünlütürk U. Three cases of subacute thyroiditis following SARS-CoV-2 vaccine: postvaccination ASIA syndrome. *J Clin Endocrinol Metab* 2021;106(9):2600-5.
[PUBMED](#) | [CROSSREF](#)
7. Jeeyavudeen MS, Patrick AW, Gibb FW, Dover AR. COVID-19 vaccine-associated subacute thyroiditis: an unusual suspect for de Quervain's thyroiditis. *BMJ Case Rep* 2021;14(11):e246425.
[PUBMED](#) | [CROSSREF](#)
8. Lee KA, Kim YJ, Jin HY. Thyrotoxicosis after COVID-19 vaccination: seven case reports and a literature review. *Endocrine* 2021;74(3):470-2.
[PUBMED](#) | [CROSSREF](#)
9. Oyibo SO. Subacute thyroiditis after receiving the adenovirus-vectored vaccine for coronavirus disease (COVID-19). *Cureus* 2021;13(6):e16045.
[PUBMED](#) | [CROSSREF](#)
10. Patel KR, Cunnane ME, Deschler DG. SARS-CoV-2 vaccine-induced subacute thyroiditis. *Am J Otolaryngol* 2022;43(1):103211.
[PUBMED](#) | [CROSSREF](#)
11. Schimmel J, Alba EL, Chen A, Russell M, Srinath R. Letter to the editor: thyroiditis and thyrotoxicosis after the SARS-CoV-2 mRNA vaccine. *Thyroid* 2021;31(9):1440.
[PUBMED](#) | [CROSSREF](#)
12. Plaza-Enriquez L, Khatiwada P, Sanchez-Valenzuela M, Sikha A. A case report of subacute thyroiditis following mRNA COVID-19 vaccine. *Case Rep Endocrinol* 2021;2021:8952048.
[PUBMED](#) | [CROSSREF](#)

13. Ratnayake GM, Dworakowska D, Grossman AB. Can COVID-19 immunisation cause subacute thyroiditis? *Clin Endocrinol (Oxf)*. Forthcoming 2021. DOI: 10.1111/cen.14555.
[PUBMED](#) | [CROSSREF](#)
14. Şahin Tekin M, Şaylısoy S, Yorulmaz G. Subacute thyroiditis following COVID-19 vaccination in a 67-year-old male patient: a case report. *Hum Vaccin Immunother* 2021;17(11):4090-2.
[PUBMED](#) | [CROSSREF](#)
15. Saygılı ES, Karakilic E. Subacute thyroiditis after inactive SARS-CoV-2 vaccine. *BMJ Case Rep* 2021;14(10):e244711.
[PUBMED](#) | [CROSSREF](#)
16. Siolos A, Gartzonika K, Tigas S. Thyroiditis following vaccination against COVID-19: report of two cases and review of the literature. *Metabol Open* 2021;12:100136.
[PUBMED](#) | [CROSSREF](#)
17. Soltanpoor P, Norouzi G. Subacute thyroiditis following COVID-19 vaccination. *Clin Case Rep* 2021;9(10):e04812.
[PUBMED](#) | [CROSSREF](#)
18. Desaillood R, Hober D. Viruses and thyroiditis: an update. *Virology* 2009;6(1):5.
[PUBMED](#) | [CROSSREF](#)
19. Ohsako N, Tamai H, Sudo T, Mukuta T, Tanaka H, Kuma K, et al. Clinical characteristics of subacute thyroiditis classified according to human leukocyte antigen typing. *J Clin Endocrinol Metab* 1995;80(12):3653-6.
[PUBMED](#) | [CROSSREF](#)
20. Watad A, David P, Brown S, Shoenfeld Y. Autoimmune/inflammatory syndrome induced by adjuvants and thyroid autoimmunity. *Front Endocrinol (Lausanne)* 2017;7:150.
[PUBMED](#) | [CROSSREF](#)
21. Brancatella A, Ricci D, Viola N, Sgrò D, Santini F, Latrofa F. Subacute thyroiditis after Sars-COV-2 infection. *J Clin Endocrinol Metab* 2020;105(7):dgaa276.
[PUBMED](#) | [CROSSREF](#)
22. Ruggeri RM, Campenni A, Siracusa M, Frazzetto G, Gullo D. Subacute thyroiditis in a patient infected with SARS-COV-2: an endocrine complication linked to the COVID-19 pandemic. *Hormones (Athens)* 2021;20(1):219-21.
[PUBMED](#) | [CROSSREF](#)
23. Chakravarthy K, Strand N, Frosch A, Sayed D, Narra LR, Chaturvedi R, et al. Recommendations and guidance for steroid injection therapy and COVID-19 vaccine administration from the American Society of Pain and Neuroscience (ASPN). *J Pain Res* 2021;14:623-9.
[PUBMED](#) | [CROSSREF](#)