



# A Rare Case of Unruptured Small Aneurysm Arising from the Posterior Surface of Proximal A1 Segment, Projecting Posterior-Inferiorly and Entangled with Multiple Perforators from the A1 Segment

Samir Jagannath Kale<sup>1</sup> Riki Tanaka<sup>2</sup> Mai Okubo<sup>2</sup> Kento Sasaki<sup>2</sup>  Kyosuke Miyatani<sup>2</sup>  
Yasuhiro Yamada<sup>2</sup> Fuminari Komatsu<sup>2</sup>  Yoko Kato<sup>2</sup>

<sup>1</sup>Department of Neurosurgery, Dr. D. Y. Patil Medical College and Hospital, Mumbai, Maharashtra, India

<sup>2</sup>Department of Neurosurgery, Fujita Health University, Bantane Hospital, Nagoya, Aichi, Japan

Address for correspondence Samir Jagannath Kale, MBBS, MS, DNB, Department of Neurosurgery, Dr. D. Y. Patil Medical College and Hospital, Nerul Navi Mumbai 400706, Maharashtra, India (e-mail: samir5485@gmail.com).

Asian J Neurosurg 2024;19:536–539.

## Abstract

Aneurysm arising from the A1 segment of the anterior cerebral artery is rare. Aneurysm of the A1 segment even being small tend to rupture early. They tend to develop along the with various vascular anomalies of the vessels arising from the A1 segment. Use of computational fluid dynamics and hemodynamic consideration is of importance in this aneurysm. In this report we describe a 57-year-old woman with a small, unruptured A1 segment aneurysm arising from the proximal segment of the posterior surface of A1, and pointing posterior-inferiorly with multiple perforators entangling around for which microsurgical clipping was done. Intraoperative clipping of the aneurysm and salvaging the multiple perforators were challenging. We report a rare case of an A1 segment aneurysm arising from the posterior surface facing with multiple perforators. It is of significance to understand that a small, unruptured A1 aneurysm can arise from the posterior surface of the A1 segment with projection posterior-inferiorly making it deeper in location with multiple perforators entangling it; hence, it is challenging to treat without causing neurological deficits.

## Keywords

- ▶ proximal A1 segment
- ▶ posterior-inferiorly
- ▶ perforators
- ▶ computational fluid dynamics
- ▶ motor-evoked potential (MEP)

## Introduction

Aneurysms of the anterior cerebral artery (ACA) are generally seen arising from the anterior communicating artery and from the distal portion of the ACA. A1 segment aneurysms are rare and are less than 1% of all cerebral aneurysm.<sup>1</sup> They

present as intracranial bleed; they are unique in being frequently associated with vascular anomalies and multiple intracranial aneurysms.<sup>2</sup>

All this coupled with the highly variable course of the A1 segment of the ACA, the variations in the projection of the aneurysm, location of the aneurysm with respect to the

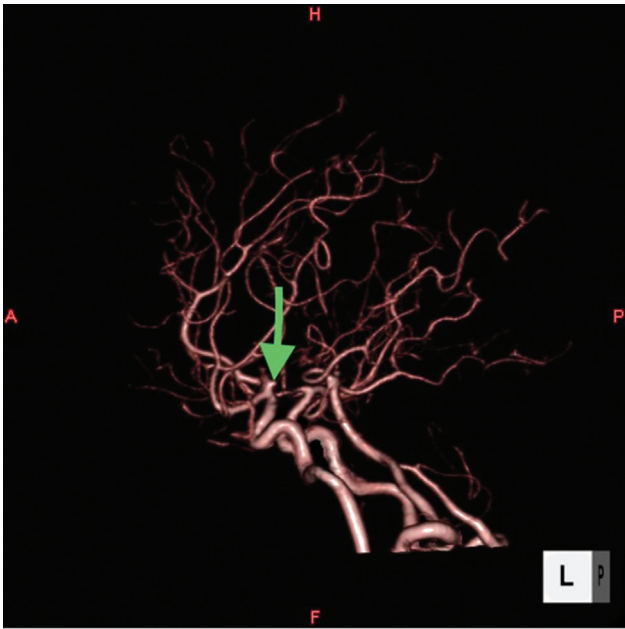
article published online  
July 4, 2024

DOI <https://doi.org/10.1055/s-0043-1776990>.  
ISSN 2248-9614.

© 2024. Asian Congress of Neurological Surgeons. All rights reserved.

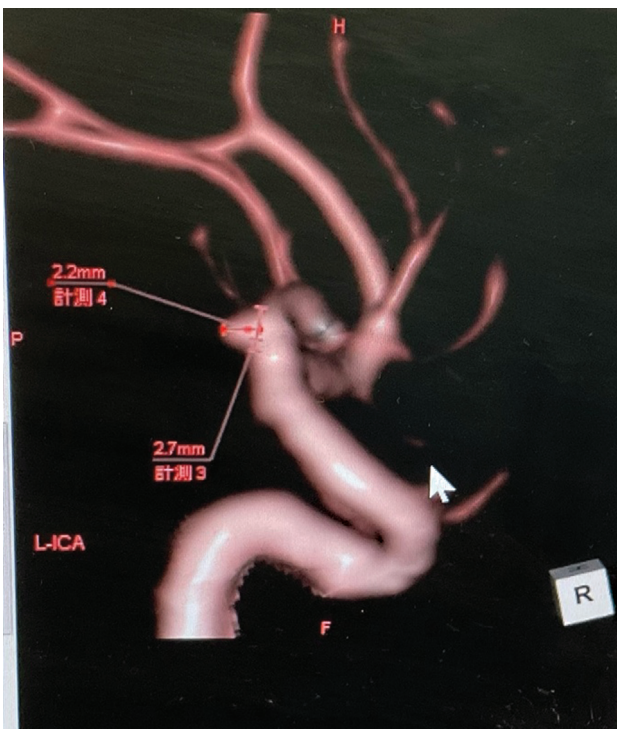
This is an open access article published by Thieme under the terms of the Creative Commons Attribution-NonDerivative-NonCommercial-License, permitting copying and reproduction so long as the original work is given appropriate credit. Contents may not be used for commercial purposes, or adapted, remixed, transformed or built upon. (<https://creativecommons.org/licenses/by-nc-nd/4.0/>)

Thieme Medical and Scientific Publishers Pvt. Ltd., A-12, 2nd Floor, Sector 2, Noida-201301 UP, India

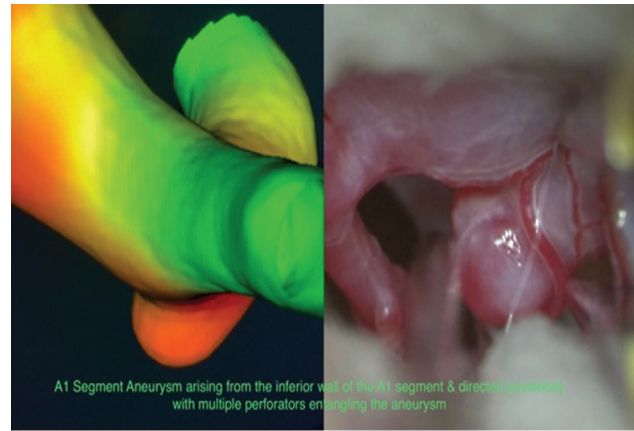


**Fig. 1** Three-dimensional computed tomography angiography of brain demonstrating an A1 segment aneurysm projecting posterior-inferiorly (green arrow).

parent artery, and its proximity to critical perforators makes aneurysms of this region a challenge to treat.<sup>3,4</sup> Proximal A1 segment aneurysm tends to rupture even being small in size and their computational fluid dynamics gives the risk assessment of their rupture and helps in early decision of surgical management.<sup>5</sup>



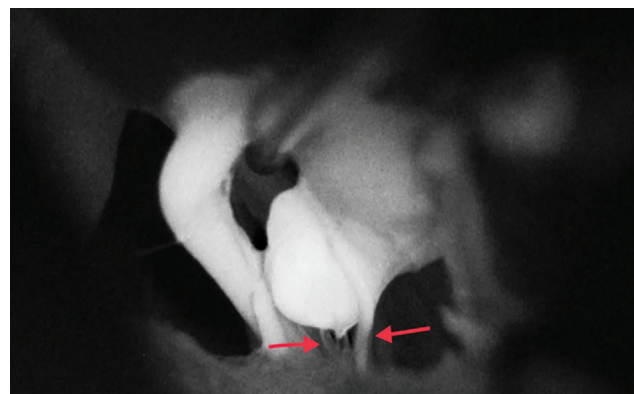
**Fig. 2** Dimensions of the aneurysm.



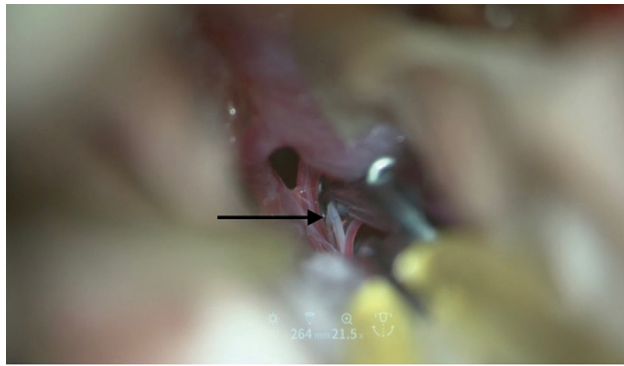
**Fig. 3** Computational fluid dynamics demonstrating high wall shear stress within aneurysm.

### Case Report

A 57-year-old female, pianist by profession, was referred to our department. Her chief complaints were headache and nausea for which her brain computed tomography (CT) and magnetic resonance imaging were done at an outside hospital, which showed an unruptured A1 segment aneurysm (►Fig. 1). Her three-dimensional CT brain angiogram showed the dimensions of the aneurysm as 2.7 mm of the neck and 2.2 mm of the height (►Fig. 2). Her computational fluid dynamics confirmed high probability of the rupture of the aneurysm (►Fig. 3), hence the decision of early operating the patient was taken and patient underwent a standard left pterional craniotomy and clipping of the aneurysm under general anesthesia. Intraoperatively an aneurysm was confirmed at the proximal segment of the A1 segment of the ACA projecting posterior-inferiorly with multiple perforators entangling the aneurysm; indocyanine green (ICG) video angiography confirmed multiple perforators (►Fig. 4). Post clipping, the motor-evoked potential (MEP) dropped to 40%. Multiple perforators were noted to be involved within the clip (►Fig. 5); hence, the clip was removed. Further dissection of the perforators from the aneurysm was done and the clip was reapplied. Post repositioning of the clip, ICG video angiography showed partial restored flow in the perforators



**Fig. 4** Intraoperative indocyanine green video angiography revealed multiple perforators (red arrows).

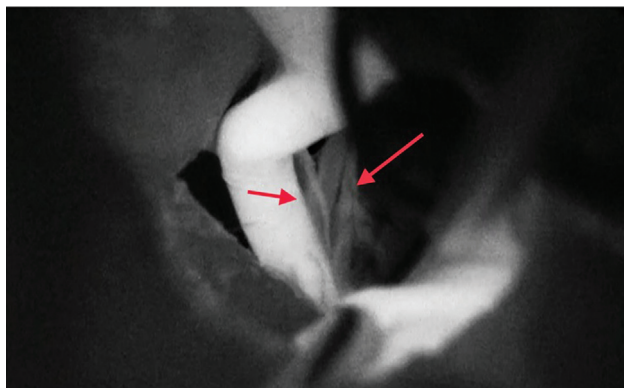


**Fig. 5** Intraoperative pic showing perforators' involvement within the clip (black arrow).

(→**Fig. 6**). MEP was maintained post clipping. The patient's postoperative course was uneventful.

## Discussion

Yasargil was the one to categorize A1 aneurysm by location into three groups: those of the proximal, middle, and distal A1 segment.<sup>6</sup> Bhaisorat et al<sup>7</sup> proposed a classification system of A1 aneurysms based on their location on the A1 segment and also on the direction of the aneurysm dome. A recent study done by Kim et al showed that the direction of the A1 aneurysm was either superior or inferior, with most of the proximal segment aneurysm direction projecting posteriorly.<sup>8</sup> However, the direction of the aneurysm in the present case was projecting posterior-inferiorly, making it more deep in location and difficult to access. Perforating arteries usually arise from the superior and/or posterior aspect of the A1 segment and run directly to the anterior perforating substance.<sup>9</sup> Type 1 aneurysms typically project superiorly and/or posteriorly. Therefore, when type 1 aneurysms are clipped, separation of the perforating arteries from the neck or dome of the aneurysm is required.<sup>10,11</sup> In contrast, when the aneurysm anatomically projects downward, as in this present case, it might be unrelated to the origin or course of the perforating arteries; hence, easy clipping of the aneurysm can be performed.<sup>12</sup>



**Fig. 6** Post clipping indocyanine green showing partial filling of the perforators (red arrows).

In the present case, the entanglement of the aneurysm by multiple perforators all around made it technically very difficult to clip without sacrificing some of the perforators, and causing significant motor deficit. Thus, use of MEP intraoperatively helped significantly as when we clipped the aneurysm in the first attempt the MEP dropped to 40%, which led us to remove the previously applied clip thus leading the MEP to return to baseline. Thus, in A1 segment aneurysm that projects posterior-inferiorly with multiple perforators surrounding the aneurysm, it should undergo early surgery with complete dissection of the perforators surrounding the aneurysm under MEP and ICG video angiography guidance to prevent any postoperative neurological deficits and improve the outcome of the surgery. Such patients can also be given an option of endovascular stent-assisted coil embolization, which is an alternative option in such difficult anatomical aneurysm with partial or complete coil embolization results.

## Conclusion

We experienced a rare case of an unruptured small aneurysm arising from the posterior surface of proximal A1 segment, projecting posterior-inferiorly and entangled with multiple perforators from the A1 segment. While treating such difficult aneurysms, options of both clipping and stent-assisted coil embolization should be kept in mind. Clipping should be done under MEP and ICG video angiography guidance to prevent any postoperative neurological deficits and improve the outcome of the surgery.

### Conflict of Interest

None declared.

### Acknowledgments

The authors would like to thank the patient and her family for their cooperation.

## References

- 1 Dashti R, Hernesniemi J, Lehto H, et al. Microneurosurgical management of proximal anterior cerebral artery aneurysms. *Surg Neurol* 2007;68(04):366–377
- 2 Hino A, Fujimoto M, Iwamoto Y, Oka H, Echigo T. Surgery of proximal anterior cerebral artery aneurysms. *Acta Neurochir (Wien)* 2002;144(12):1291–1296, discussion 1296
- 3 Park HS, Choi JH, Kang M, Huh JT. Management of aneurysms of the proximal (A1) segment of the anterior cerebral artery. *J Cerebrovasc Endovasc Neurosurg* 2013;15(01):13–19
- 4 Hunt WE, Hess RM. Surgical risk as related to time of intervention in the repair of intracranial aneurysms. *J Neurosurg* 1968;28(01):14–20
- 5 Czebrat JR, Mut F, Weir J, Putman CM. Association of hemodynamic characteristics and cerebral aneurysm rupture. *AJNR Am J Neuroradiol* 2011;32(02):264–270
- 6 Yasargil MG. Proximal anterior cerebral artery aneurysms. In: *Microneurosurgery*. Vol 2; Stuttgart: Georg Thieme Verlag; 1984: 165–169
- 7 Bhaisorat KS, Behari S, Prasad G, et al. A I-segment aneurysms: management protocol based on a new classification. *Neurol India* 2014;62(04):410–416

- 8 Kim MK, Lim YC. Aneurysms of the proximal (A1) segment of the anterior cerebral artery: a clinical analysis of 31 cases. *World Neurosurg* 2019;127:e488–e496
- 9 Rosner SS, Rhoton AL Jr, Ono M, Barry M. Microsurgical anatomy of the anterior perforating arteries. *J Neurosurg* 1984;61(03):468–485
- 10 Yilmaz M, Kalemci O, Yurt A, Durmaz MO, Arda NM. Treatment of aneurysms arising from the proximal (A1) segment of the anterior cerebral artery. *Bosn J Basic Med Sci* 2014;14(01):8–11
- 11 Marinković S, Milisavljević M, Kovacević M Anatomical bases for surgical approach to the initial segment of the anterior cerebral artery. *Microanatomy of Heubner's artery and perforating branches of the anterior cerebral artery. Surg Radiol Anat* 1986; 8(01):7–18
- 12 Nomura JI, Tsutsui S, Hatchome Y, Misaki T, Konno H, Ogasawara K. Ruptured aneurysm at the origin of an anomalous callosomarginal artery arising from the A1 segment of the anterior cerebral artery-a case report. *NMC Case Rep J* 2022;9:183–186