

- 4 Ballabio A, Carrozzo R, Parenti G et al. Molecular heterogeneity of steroid sulfatase deficiency: a multicenter study on 57 unrelated patients, at DNA and protein levels. *Genomics* 1989; **4**:36–40.
- 5 Corominas J, Smeekens SP, Nelen MR et al. Clinical exome sequencing – mistakes and caveats. *Hum Mutat* 2022; **43**:1041–55.
- 6 Richards S, Aziz N, Bale S et al. Standards and guidelines for the interpretation of sequence variants: a joint consensus recommendation of the American College of Medical Genetics and Genomics and the Association for Molecular Pathology. *Genet Med* 2015; **17**:405–24.
- 7 Elias PM, Williams ML, Choi EH, Feingold KR. Role of cholesterol sulfate in epidermal structure and function: lessons from X-linked ichthyosis. *Biochim Biophys Acta* 2014; **1841**:353–61.
- 8 Traupe H, Fischer J, Oji V. Nonsyndromic types of ichthyoses – an update. *J Dtsch Dermatol Ges* 2014; **12**:109–21.

Clinical, dermoscopic and histopathological findings in localized human monkeypox: a case from northern Italy

DOI: 10.1111/bjd.21773

DEAR EDITOR, The recent monkeypox (MP) outbreak is an increasingly alarming public health concern, as multiple clusters are being identified throughout Europe, especially in men who have sex with men (MSM).^{1–3} This emerging zoonotic disease is transmitted through intimate contact and air droplets, with the possibility of spread via sexual fluids still under investigation.^{2,4,5}

A 44-year-old Ukrainian individual, identifying himself as an MSM, presented to the sexually transmitted diseases outpatient service of our dermatology unit in Milan for an

asymptomatic cutaneous eruption that had appeared 5 days before on his external genitalia and the third finger of his right hand. Prior to the appearance of skin lesions, he had reported low-grade fever, headache and malaise for a week.

His medical history was positive for past nodal tuberculosis and untreated chronic hepatitis C virus infection. Moreover, he was HIV-1 positive and currently under combination antiretroviral therapy (CD4 count 0.935×10^9 cells L⁻¹; HIV viral load < 200 copies mL⁻¹). Recently, he had also been treated for primary syphilis, with normalization of serum rapid plasma reagin titre. It is noteworthy that he had not been vaccinated for smallpox. The patient did not recall being in close contact with animals and denied travelling abroad in the past year, but mentioned numerous occasions of condomless sexual intercourse in the preceding months.

Upon physical examination, multiple vesiculopustular lesions approximately in the same stage of development were noted on the patient's scrotum, penis, right thigh and distal phalanx of the third finger of his dominant hand, some with marked umbilication and central crusting (Figure 1a, b). Tender, bilateral inguinal lymphadenopathy was found on palpation. Dermoscopy showed whitish structureless areas with brownish central crusts and perilesional erythema (Figure 1a; inset).

On histology, a central area of full-thickness epidermal necrosis with adjacent acanthosis and keratinocyte degeneration was shown – possibly corresponding to the whitish halo observed on dermoscopy – along with exocytosis of lymphocytes, neutrophils and rare eosinophils (Figure 1c). Keratinocytes displayed cytopathic changes consisting of an eosinophilic 'ground glass' appearance of the nucleus. The underlying dermis revealed a full-thickness inflammatory

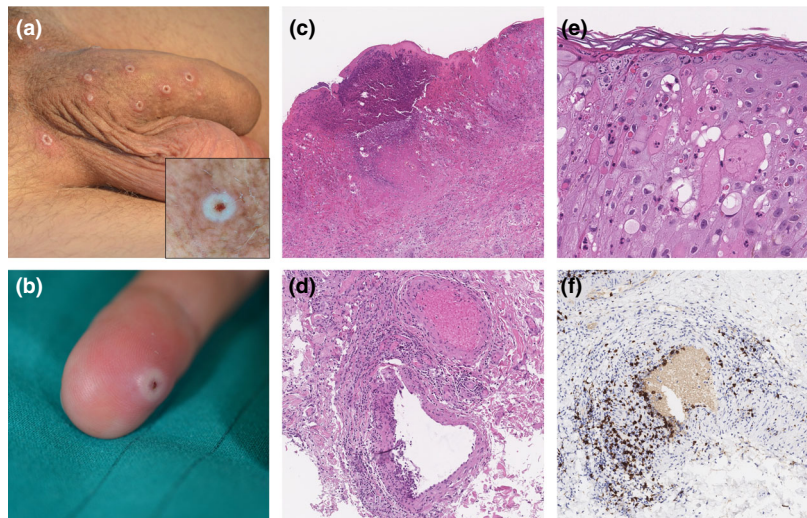


Figure 1 (a) Typical vesiculopustular lesions, predominantly distributed on the patient's genitalia. Dermoscopy revealed whitish structureless areas with brownish central crusts and perilesional erythema (inset). (b) A single pustular element on the third finger of the patient's dominant hand was observed. (c) On histology, full-thickness epidermal necrosis with surrounding acanthosis and keratinocyte degeneration was demonstrated [haematoxylin and eosin (H&E), original magnification $\times 40$]. (d) Signs of vessel wall involvement were also noted (H&E, $\times 200$). (e) At higher magnification (H&E, $\times 400$), rare multinucleated keratinocytes were seen, together with eosinophilic, homogeneous spherical intracytoplasmic inclusions (Guarnieri bodies). (f) On immunohistochemistry, angiotropic CD8⁺ T cells colocalized with cytopathic changes (anti-CD8 monoclonal antibody; Dako, Glostrup, Denmark; clone C8/144B, peroxidase, $\times 200$).

infiltrate composed of lymphocytes, neutrophils and eosinophils in a perieccrine and perivascular distribution. Interestingly, features of angiotropism were spotted in the deep dermis involving medium-sized vessels (Figure 1d). Rare multinucleated keratinocytes were present together with eosinophilic cytoplasmic inclusions (so-called Guarnieri bodies) (Figure 1e).⁶ On immunohistochemistry, the lymphocytic infiltrate was predominantly T cell with CD4⁺ and CD8⁺ elements, the latter being more represented at foci of angiotropism (Figure 1f). Pharyngeal and vesiculopustular fluid swabs were positive for MP DNA on a previously described real-time polymerase chain reaction (RT-PCR) assay.²

The patient was admitted to our infectious diseases unit. Contact and droplet isolation measures were undertaken immediately. He recovered spontaneously in about a week and was then discharged to self-isolation at home for two additional weeks.









Human MP-associated cutaneous features encompass the full spectrum of vesiculopustular to crusted elements, depending on timing and lesion evolution. A maculopapular, pinkish rash has also been described.¹ Concomitant HIV positivity, along with the resulting systemic immunodepression, may have facilitated the clinical expressivity of the disease. However, local immunity may also play a key role in determining the clinical picture, possibly deciding between localized and generalized MP. In this regard, the peculiar, localized lesional distribution of our case suggests transmission through intimate contact, rather than true systemic spread via sexual fluids.³ It is unclear whether concurrent HIV and hepatitis C virus infection^{1–3} and recent history of syphilis merely reflect spread in high-risk communities or facilitate MP transmission. Moreover, although already demonstrated in cutaneous viral eruptions,⁷ evidence of direct cytopathic changes on vascular walls is intriguing, as it may explain the presence of systemic symptoms also in localized cases.

Dermoscopy of human MP, with its lack of vascular structures and intensely whitish hue, has not been described previously and may aid in the differential diagnosis from similar entities, such as herpes virus infections, molluscum contagiosum, orf and milker's nodules. Laboratory confirmation of clinically suspected cases through RT-PCR is the gold standard, as serology is limited by cross-reactivity with other poxviruses.²

Dermatologists should enact droplet and contact protective measures. The room in which the patient is first visited should be sanitized immediately. Depending on clinical conditions, the patient should either be sent home for self-isolation for 3 weeks or be admitted in an infectious diseases setting.

New cases of human MP are continually being identified and, although attaching the stigma of MP to the community of MSM should be avoided,⁸ proper counselling should be given to those who engage in high-risk sexual practices, to prevent further spread of this new outbreak and limit its chance to become endemic.

Acknowledgment: Open Access Funding provided by Università degli Studi di Milano within the CRUI-CARE Agreement.

Carlo A. Maronese ^{1,2} Andrea Beretta ^{1,2} Gianluca Avallone ³ Francesca L. Boggio ⁴ Dario A. Marletta ^{1,2} Giulia Murgia,^{1,2} Marco Cusini ¹ Andrea Gori,^{2,5} Carlo G. Carrera,¹ Alessandra Di Benedetto,¹ Stefano Ramoni ¹ and Angelo V. Marzano ^{1,2}

¹Dermatology Unit; ²Department of Pathophysiology and Transplantation, Università degli Studi di Milano, Milan, Italy; ³Department of Medical Sciences, University of Turin, Dermatology Clinic, Turin, Italy; ⁴Pathology Unit; and ⁵Infectious Diseases Unit, Fondazione IRCCS Ca' Granda Ospedale Maggiore Policlinico, Milan, Italy

Correspondence: Angelo V. Marzano.

Email: angelo.marzano@unimi.it

Funding sources: none.

Conflicts of interest: the authors declare they have no conflicts of interest.

Data availability statement: all available information is contained within the manuscript.

C.A.M., A.B. and G.A. contributed equally and all qualify as first authors.

S.R. and A.V.M. contributed equally and both qualify as senior authors.

References

- de Nicolas-Ruanes B, Vivancos M, Azcarraga-Llobet C et al. Monkeypox virus case with maculopapular exanthem and proctitis during the Spanish outbreak in 2022. *J Eur Acad Dermatol Venereol* 2022; in press; doi:<https://doi.org/10.1111/jdv.18300>.
- Mileto D, Riva A, Cutrera M et al. New challenges in human monkeypox outside Africa: a review and case report from Italy. *Travel Med Infect Dis* 2022; **49**:102386.
- Hammerschlag Y, MacLeod G, Papadakis G et al. Monkeypox infection presenting as genital rash, Australia, May 2022. *Euro Surveill* 2022; **27**:2200411.
- Heskin J, Belfield A, Milne C et al. Transmission of monkeypox virus through sexual contact – a novel route of infection. *J Infect* 2022; in press; doi:<https://doi.org/10.1016/j.jinf.2022.05.028>.
- Adler H, Gould S, Hine P et al. Clinical features and management of human monkeypox: a retrospective observational study in the UK. *Lancet Infect Dis* 2022; in press; doi:[https://doi.org/10.1016/S1473-3099\(22\)00228-6](https://doi.org/10.1016/S1473-3099(22)00228-6).
- Guarnieri's vaccine bodies. *JAMA* 1901; **37**:1466.
- Leinweber B, Kerl H, Cerroni L. Histopathologic features of cutaneous herpes virus infections (herpes simplex, herpes varicella/zoster): a broad spectrum of presentations with common pseudolymphomatous aspects. *Am J Surg Pathol* 2006; **30**:50–8.
- Bragazzi NL, Khamisy-Farah R et al. Attaching a stigma to the LGBTIQ+ community should be avoided during the monkeypox epidemic. *J Med Virol* 2022; in press; <https://doi.org/10.1002/jmv.27913>.