

Prediction of premature ventricular complex origins using artificial intelligence-enabled algorithms



Tomofumi Nakamura, MD, PhD,* Yasutoshi Nagata, MD,* Giichi Nitta, MD,* Shinichiro Okata, MD, PhD,* Masashi Nagase, MD,* Kentaro Mitsui, MD,* Keita Watanabe, MD,* Ryoichi Miyazaki, MD,* Masakazu Kaneko, MD,* Sho Nagamine, MD, PhD,* Nobuhiro Hara, MD,* Tetsumin Lee, MD, PhD,* Toshihiro Nozato, MD, PhD,* Takashi Ashikaga, MD, PhD,* Masahiko Goya, MD, PhD,[†] Tetsuo Sasano, MD, PhD[†]

From the *Department of Cardiology, Japanese Red Cross Musashino Hospital, Tokyo, Japan, and

[†]Department of Cardiovascular Medicine, Tokyo Medical and Dental University Hospital, Tokyo, Japan.

BACKGROUND Catheter ablation is a standard therapy for frequent premature ventricular complex (PVCs). Predicting their origin from a 12-lead electrocardiogram (ECG) is crucial but it requires specialized knowledge and experience.

OBJECTIVE The objective of the present study was to develop and evaluate machine learning algorithms that predicted PVC origins from an ECG.

METHODS We developed the algorithms utilizing a support vector machine (SVM) and a convolutional neural network (CNN). The training, validating, and testing data consisted of 116 PVCs from 111 patients who underwent catheter ablation. The ECG signals were labeled with the PVC origin, which was confirmed using a 3-dimensional electroanatomical mapping system. We classified the origins into 4 groups: right or left, outflow tract, or other sites. We trained and evaluated the model performance. The testing datasets were also evaluated by board-certified electrophysiologists and an existing classification algorithm. We also developed binary classification models that predicted whether the origin was on the right or left side of the heart.

RESULTS The weighted accuracies of the 4-class classification were as follows: SVM 0.85, CNN 0.80, electrophysiologists 0.73, and existing algorithm 0.86. The precision, recall, and F_1 in the machine learning models marked better than physicians and comparable to the existing algorithm. The SVM model scored among the best accuracy in the binary classification (the accuracies were 0.94, 0.87, 0.79, and 0.90, respectively).

CONCLUSION Artificial intelligence-enabled algorithms that predict the origin of PVCs achieved superior accuracy compared to the electrophysiologists and comparable accuracy to the existing algorithm.

KEYWORDS Artificial intelligence; Convolutional neural network; Electrocardiogram; Machine learning; Premature ventricular complex; Support vector machine

(Cardiovascular Digital Health Journal 2021;2:76–83) © 2020 Heart Rhythm Society. This is an open access article under the CC BY-NC-ND license (<http://creativecommons.org/licenses/by-nc-nd/4.0/>).

Introduction

Frequent premature ventricular complexes (PVCs) are generally considered as a benign condition if there is no comorbid structural abnormality; however, the condition often causes chest discomfort, which affects daily activity and also contributes to a depressed ventricular function.¹ Catheter ablation is an optimal therapeutic option for those symptomatic PVCs.^{2–5}

The expert guidelines on catheter ablation of ventricular arrhythmias stratify the strength of the recommendations into a class IIa indication for PVCs from the left ventricular

outflow tract (LVOT) and a class I recommendation for PVCs from other origins.⁶ That is because the catheter ablation of LVOT PVCs can be challenging owing to the structural complexity in that region and the risk of collateral injury to adjacent coronary arteries and systemic embolisms.^{7,8} Predicting the origin of target PVCs before the ablation procedure is important in terms of estimating the procedural difficulty and possible adverse events. It also helps reduce the labor and procedure time. Although the PVC origin can be predicted from a standard 12-lead electrocardiogram (ECG) and several criteria have been proposed, it is sometimes complicated and the accuracy is limited.^{9,10}

Recently, machine learning technologies are emerging and they are being utilized in the medical field.^{11,12} Artificial intelligence (AI)-based ECG analyses are providing

Address reprint requests and correspondence: Dr Tomofumi Nakamura, Japanese Red Cross Musashino Hospital, 1-26-1, Kyonancho, Musashino City, Tokyo, Japan. E-mail address: tomonakamura-tmd@umin.ac.jp.

KEY FINDINGS

- Catheter ablation is one of the important therapeutic options for symptomatic frequent premature ventricular complexes (PVCs). Predicting the source of PVCs prior to ablation can reduce procedural time and fluoroscopy time, save labor, and reduce the risk of complications. Although it can be predicted from an electrocardiogram, it requires skill to interpret and it is sometimes misleading.
- In this study, we developed 2 artificial intelligence-based algorithms that were trained using real-world spontaneous PVCs. The models used the support vector machine and the convolutional neural network, both of which showed excellent prediction accuracy. The models were able to predict the origin of PVCs with greater accuracy than the skilled electrophysiologists.
- The models showed satisfactory results even though the number of training datasets was not abundant, especially for a convolutional neural network. We expect that by accumulating data, models consisting of complex deep networks will be implemented, which can predict more detailed sites.

promising results in the detection of arrhythmias and myopathies.^{13–16} We expected that this technology could be applied to the detection of PVC origins and then developed machine learning models.

Methods

Data description

We identified a total of 116 PVCs from 111 patients who underwent catheter ablation of frequent PVCs in our hospital from December 2011 to May 2020 (Figure 1). All of the 12-lead ECGs during the catheter ablation procedure had been recorded and stored on the CardioLab electrophysiology system (General Electric Healthcare, Barrington, IL). The signals were recorded at a sampling frequency of 977 Hz and were filtered with a low-frequency digital filter cutoff of 0.05 Hz and high-frequency digital filter cutoff of 100 Hz. We manually identified the target PVC and exported it from approximately 140 ms before to 120 ms after the absolute peak of any leads as a CSV format. This step yielded a 12×260 matrix with the spatial first dimension and the temporal second dimension; each value indicated the voltage measured every 1.02 ms. The output value ranged from -5 to 5 mV. We then selected 8 independent leads (leads I, II, and V_1 – V_6) and disregarded the other augmented leads (leads III, aVR, aVL, and aVF) because the augmented leads did not contain any incremental information and could be learned by the models. This sample extraction was repeated 4 times for each PVC at different times for data augmentation. Generally, flipping, stretching, and rotation are performed for augmentation of image data, but we considered it is not appli-

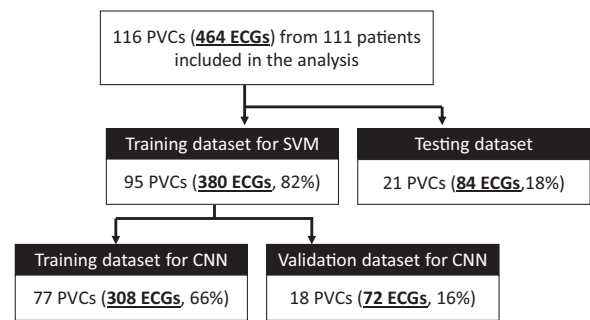


Figure 1 Flow diagram of the selection of the patients for the training, validation, and testing cohorts. CNN = convolutional neural network; ECG = electrocardiogram; PVC = premature ventricular complex; SVM = support vector machine.

cable for this study. Instead, we extracted 4 independent pieces of data of each PVC in different timing. Since each PVC waveform had slightly different potentials and baseline noise, this data collection could be a substitute for data distortion. Each piece of data was labeled with a PVC origin, which is described in the following section. The datasets were randomly split into a training set and testing set with a 4:1 ratio on a PVC basis so that no PVCs overlapped between the datasets. The training set was used for the training and optimization of the support vector machine (SVM) model. The training set was randomly subdivided into training and validation sets with a 4:1 ratio on a PVC basis for the training and validation of the convolutional neural network (CNN) model. Hence no PVCs overlapped among the datasets: 4 independent ECG data from 1 PVC were included in the same dataset.

This research protocol was designed by the authors and approved by the institutional review board of the Japanese Red Cross Musashino Hospital (approval number: 2034). Written informed consent for ablation and data usage was given by all patients. The information disclosure document of this study has been published on the hospital website. The research reported in this paper adhered to the Declaration of Helsinki.

Ablation procedure

Mapping and ablation of frequent PVCs were performed in the standard fashion using either of the 3-dimensional electroanatomical mapping systems: CARTO 3 (Biosense Webster, Irvine, CA) or Ensite (Abbott, Green Oaks, IL). Endocardial activation maps of the chamber of interest were generated with standard ablation catheters or multi-electrode catheters supplied from each manufacturer. The endocardial sites that were felt to be closest to the arrhythmia origin based on the activation mapping and pace mapping were selected for ablation. Radiofrequency current was applied in a temperature-controlled mode set to 60°C and with a power initially limited to 15–35 watts and manually increased to as much as 40 watts for a maximum of 60 seconds. Any advanced techniques, such as epicardial ablation, bipolar or simultaneous unipolar

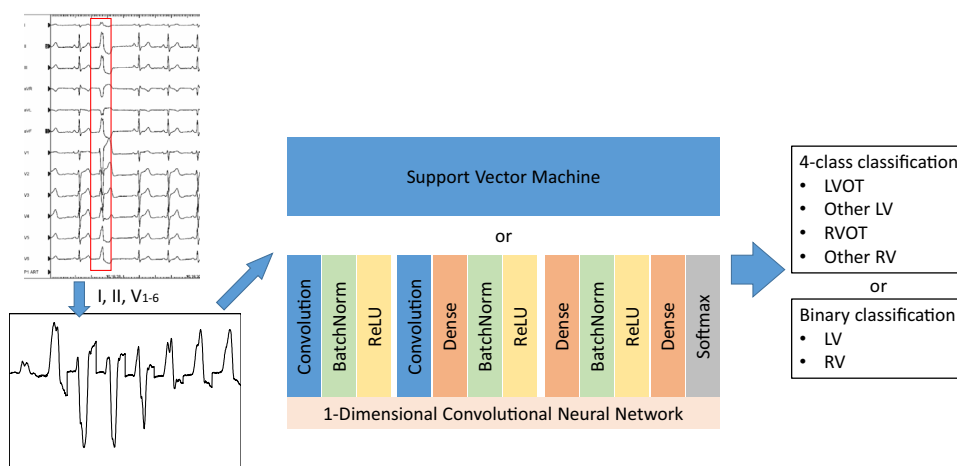


Figure 2 Illustration of the input data processing and structure of the neural network. The electrocardiograms of the premature ventricular complexes are electrically exported from a recording system and processed into a single strip (see text for detail). The datasets were fed into the classifiers used by the support vector machine or 1-dimensional convolutional neural network. The classifiers performed a 4-class or binary classification. LV = left ventricle; LVOT = left ventricular outflow tract; ReLU = rectified linear unit; RV = right ventricle; RVOT = right ventricular outflow tract.

ablation, ethanol ablation, or needle ablation, were not attempted in all cases. At the end of the ablation procedure, a 15-minute observation period was made to evaluate the acute outcome. The PVC origin was defined as the ablation site where the PVC was eliminated or suppressed at least 80% of burden if not eliminated. The PVC origins were classified into 4 groups: LVOT, other left ventricle (LV) sites, right ventricular outflow tract (RVOT), and other right ventricle (RV) sites. The LVOT was defined as the coronary cusps, the area immediately below the aortic root, aortomitral continuity, and LV summit. The RVOT was defined as the area between the conus arteriosus and pulmonary artery. This coding was used for the 4-class classification. We also classified the origin into 2 groups: the right side of the heart or the left side of the heart. This was used for the binary classification. If the different morphologic PVCs were seen prior to the procedure and both were targeted, they were counted as different PVCs. If the PVC morphology changed during ablation and several chambers were ablated, final morphology was recorded and elimination site was considered as origin. All patients underwent a routine follow-up Holter ECG after 3–6 months from the index procedure.

Algorithm development: Support vector machine

The SVM with a radial basis function kernel was used to conduct supervised machine learning. For an optimal selection of the SVM parameters, a grid search was performed on C and γ using a 5-fold cross-validation using the following sets of values: $C = \{0.0001, 0.001, 0.01, 0.1, 1, 10, 100\}$ and $\gamma = \{0.0001, 0.001, 0.01, 0.1, 1, 10, 100\}$. This meant that for each combination of parameters, the training dataset was randomly split in a 4:1 ratio, and the model training and internal validation were repeated 5 times. The most optimal combination of parameters was then selected. The features within the dataset were standardized prior to being fed into the model.

We developed a 4-class classification model and a binary classification model. Those models were developed using the Scikit-learn library and Python (Python Software Foundation, Beaverton, OR).

Algorithm development: Convolutional neural network

We implemented a 1-dimensional CNN using the Keras Framework with a TensorFlow (Google, Mountain View, CA) backend and Python. We tested multiple networks, including a light neural network and deep neural network, and selected the model that provided the higher accuracy and lower computing cost. The framework of the CNN model is illustrated in Figure 2. The network was composed of 2 convolution layers (filters were 64 and 32, respectively; kernel sizes were 3; kernel regularizers were L2 [0.001]) and both were followed by a batch-normalization layer for normalization of the data distribution and a nonlinear ReLU activation function to provide nonlinearity for the model. The output was then fed to 2 dense layers (units were 256 and 128, respectively) with an intervening batch-normalization layer with a ReLU activation. The final output layer was activated using the softmax function, which generated a probability of each class. For training, the training dataset was fed to the network and the network weights were updated using the stochastic gradient descent optimizer with categorical cross-entropy as the loss function. After each epoch, the network was tested using the internal validation dataset. The network hyperparameters, batch, and step size were also tuned during this process and the network with the lowest categorical cross-entropy loss value was selected once the loss value on the validation set stopped decreasing for the following 30 epochs. A grid search and cross-validation were not applied for this model. The binary cross-entropy was used for the binary classification.

Table 1 Patient characteristics

Dataset	Training for SVM	Training for CNN	Validation for CNN	Test
Number of patients	91	73	18	21
Number of PVCs*	380 (95)	308 (77)	72 (18)	84 (21)
Age	64 [48–70]	64 [48–70]	64 [47–73]	67 [59–76]
Sex, male	48 (53%)	36 (49%)	12 (67%)	12 (57%)
EF, %	66 [60–71]	66 [60–71]	66 [61–72]	63 [54–75]
Myopathy				
None	87	70	17	19
Ischemic	1	0	1	1
Nonischemic	3	3	0	1
PVC burden, before, %	22 [14–29]	22 [13–28]	23 [14–30]	18 [14–25]
PVC burden, after, %	0.02 [0–0.6]	0.02 [0–1.08]	0.01 [0–0.28]	1.1 [0.01–5.38]
PVC origin, %				
RVOT	46%	48%	39%	52%
RV other area	14%	13%	17%	19%
LVOT	23%	22%	28%	19%
LV other area	17%	17%	17%	10%
Morphology change	14 (15%)	12 (16%)	2 (11%)	2 (10%)
Ablation from both sides	9 (9%)	7 (9%)	2 (11%)	3 (14%)
Elimination	86 (91%)	69 (90%)	17 (94%)	18 (86%)
Significant reduction	8 (8%)	7 (9%)	1 (6%)	2 (10%)
Failure	1 (1%)	1 (1%)	0 (0%)	1 (1%)

CNN = convolutional neural network; EF = ejection fraction; LV = left ventricle; LVOT = left ventricular outflow tract; PVC = premature ventricular complex; RV = right ventricle; RVOT = right ventricular outflow tract; SVM = support vector machine.

Values are expressed in median [interquartile range].

*The type of waveform is shown in parentheses and the number of waveforms entered as data is shown outside the parentheses.

Comparison of performance between models and physicians

The testing dataset, which was not used for the training and validation process, was used to assess the AI-enabled model's ability to classify the PVC origin. The 21 ECG strips for testing PVCs were printed out anonymously and given to 3 board-certified electrophysiologists (Y.N., K.W., and M.K.). They had been in clinical practice as an electrophysiologist for 10 to 25 years. They were requested to predict the PVC origin in a 4-class and binary classification from the PVC morphology. We also estimated the origin using an existing algorithm proposed by Enriquez and colleagues.⁹ The performance of the SVM and CNN models was assessed according to the receiver operating characteristic curve, area under the curve (AUC), accuracy, precision, recall, and F_1 score. The F_1 score was the harmonic mean of the precision and recall. We used confusion matrices to evaluate the performance of the prediction of the PVC origin of the AI-enabled models, electrophysiologists, and existing algorithm with respect to the confirmed origins. Confusion matrices were made for both the binary and 4-class classification.

Results

Study population

The patients' background and description of the datasets used for model training, validation, and testing are summarized in Table 1. The age distribution was similar (median age was around 65 years) and roughly half of the patients had a male sex in all datasets. Five patients had 2 PVCs. As a result of the random assignment, both PVCs were included in the

training dataset in 4 patients. In the remaining 1 patient, PVC was allotted to the validation and testing datasets, respectively. The waveforms and sources were completely independent. Most patients had no organic heart disease, but ischemic cardiomyopathy was present in 2 patients and nonischemic cardiomyopathy in 4 patients. PVC waveform changes by ablation were seen in 16 PVCs. Ablation from both sides was needed in 12 PVCs. Ninety percent of the PVCs were eradicated, 9% of the PVCs showed a significant reduction, and 2 PVCs did not respond to treatment. Of the 2 failure cases, 1 PVC apparently arose from the parahisian area and ablation to the area immediately suppressed the PVC but had to be given up prematurely because of the risk of atrioventricular block. Another unsuccessful PVC ablation was apparently from LV summit and endocardial ablation suppressed transiently.

The PVC origin distribution was also similar among the datasets: 40%–50% were from the RVOT, 20%–25% from the LVOT, 15% from other RV sites, and 15% from other LV sites.

Table 2 Diagnostic performance of the 4-class classification of the prediction of the premature ventricular complex origin

	Accuracy	F_1	Precision	Recall
SVM	0.85	0.85	0.86	0.85
CNN	0.80	0.80	0.81	0.80
Enriquez et al ⁹	0.86	0.86	0.90	0.86
Electrophysiologists	0.73	0.74	0.81	0.73

CNN = convolutional neural network; SVM = support vector machine.

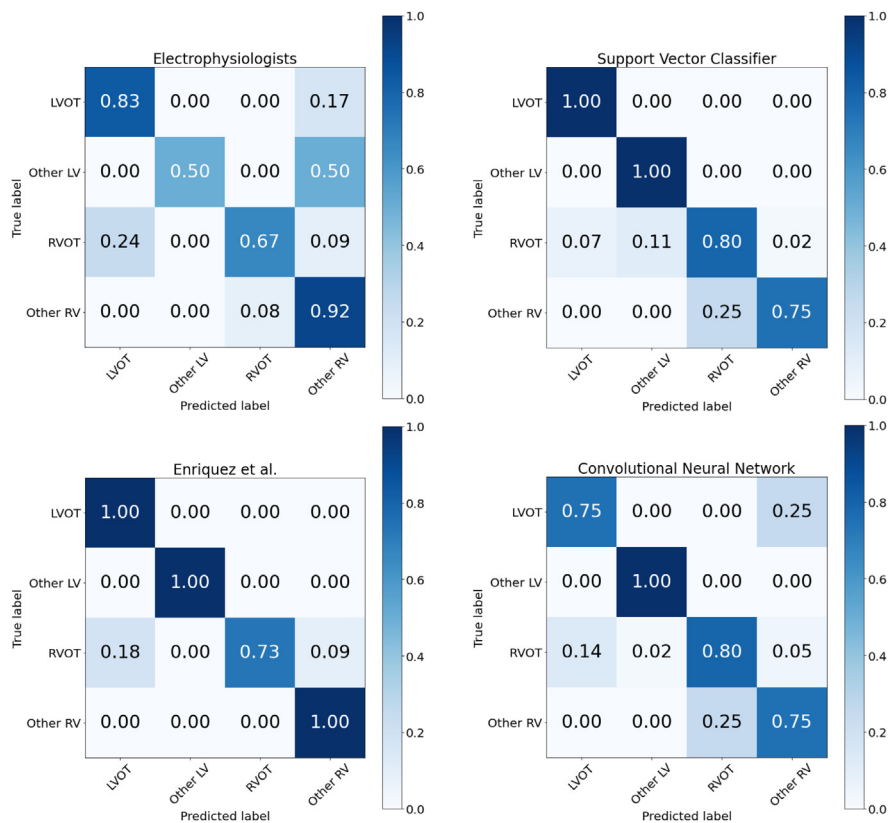


Figure 3 The confusion matrices of the 4-class classification for the board-certified electrophysiologists, existing classification algorithm, support vector machine, and convolutional neural network. The accuracy of each premature ventricular complex origin is displayed in a color gradient scale. LV = left ventricle; LVOT = left ventricular outflow tract; ReLU = rectified linear unit; RV = right ventricle; RVOT = right ventricular outflow tract.

Model performance: 4-class classification

The training and the output of the results were completed within a very short time on all models. The most time-consuming was the SVM with grid search, but it took no longer than 5 minutes to complete. The diagnostic performance of the models and physicians for the 4-class classification of the PVC origin is presented in Table 2. The weighted average of the accuracies, F₁ scores, precisions, and recalls were around 0.85 in the SVM model and 0.80 in the CNN model. Both models achieved better results compared to the board-certified electrophysiologists and were comparable to the existing algorithm. The optimal hyperparameters of the SVM model were as follows: {'C': 100, 'gamma': 0.0001, 'kernel': 'rbf'}. Figure 3 shows the confusion matrices of each model. Both machine learning models and the existing algorithm had similar classification abilities. The representative case is demonstrated in Figure 4. This PVC was successfully eliminated by radiofrequency catheter ablation from the RVOT. The existing algorithm determined this PVC to be of LVOT origin, while both machine learning models and two-thirds of the electrophysiologists correctly determined it to be of RVOT origin. As shown in this example case, right-or-left confusion may occur especially when the polarity of lead I was subtle.

Model performance: Binary classification

The diagnostic performance of the models and physicians for the binary classification of the PVC origin is presented in Table 3 and the confusion matrices and receiver operating characteristic curves are shown in Figure 5. The optimal hyperparameters of the SVM model were as follows: {'C': 1, 'gamma': 0.01, 'kernel': 'rbf'}. As with the 4-class classification, the machine learning algorithms achieved superiorly compared to the electrophysiologists and showed comparable classification abilities to the existing algorithm. The SVM model achieved among the best results. The confusion matrices exhibited in both AI models had a good classification ability regardless of which side of the heart the PVC was from. The classifier using the SVM achieved an AUC of 0.997 and the CNN-utilized model achieved an AUC of 0.908.

Discussion

Recently, several studies have been reported to estimate the origin of ventricular arrhythmias using machine learning.^{17,18} Most of them are for ventricular tachycardia from damaged myocardium, and the training data are based on intraprocedural pacing waveforms. In contrast, the present study

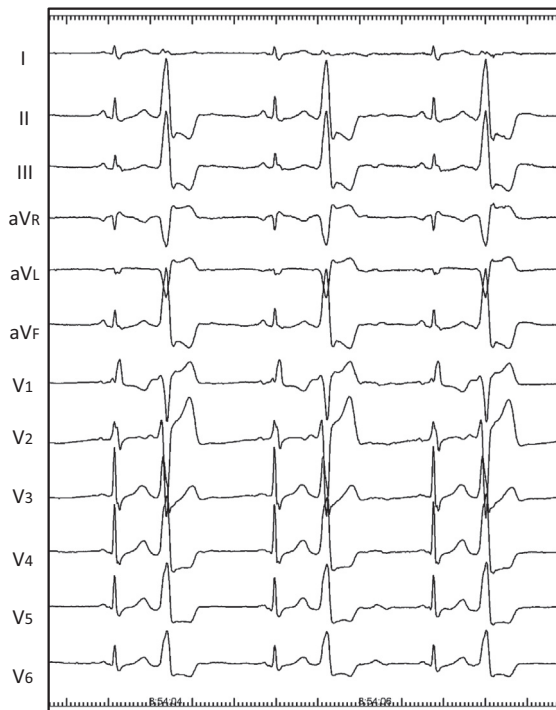


Figure 4 Representative case of premature ventricular complexes (PVCs). This PVC was successfully eliminated by radiofrequency catheter ablation from the right ventricular outflow tract (RVOT). The existing algorithm determined this PVC to be of LVOT origin, while 2 machine learning models and two-thirds of the electrophysiologists correctly determined it to be of RVOT origin.

targeted mainly solitary PVCs from normal hearts without cardiomyopathy, and the training data are clinical PVC rather than paced waveform. The pace map has been shown to be inaccurate, especially in the outflow tract PVC owing to the presence of preferential conductions; therefore, it was concerning that the use of pacing waveforms for training would not lead to accurate prediction of the origin.^{19–21}

In this study, we developed 2 machine learning models using the SVM and CNN. Both models showed superior distinguishability to the board-certified electrophysiologists and comparable distinguishability to the existing algorithm. The SVM is one of the most popular machine learning tools using kernel tricks, which is considered particularly effective for classification problems with small sample sizes. As is the nature of a single-center study, the present study had a limited sample size. The findings of the current study that the SVM model showed among the best results implied that the data

Table 3 Diagnostic performance of the binary classification of the prediction of the premature ventricular complex origin

	Accuracy	F ₁	Precision	Recall
SVM	0.94	0.94	0.95	0.94
CNN	0.87	0.87	0.91	0.87
Enriquez et al ⁹	0.90	0.91	0.93	0.90
Electrophysiologists	0.79	0.80	0.81	0.79

CNN = convolutional neural network; SVM = support vector machine.

size was sufficient for the SVM model and relatively small for the CNN model. The CNN is an emerging technique to act as a prognostic aid for a group of classification tasks. The CNN shows its superb classification abilities mainly for image recognition fields, but this technique can also be applied to waveform identification tasks using a 1-dimensional CNN, as we have done in this study. A unique characteristic of the CNN is that it can perform an automatic feature extraction without human intervention, unlike most traditional machine learning algorithms, and it is extendable to a deep learning algorithm by accumulating layers. In this study, however, none of the deep learning models worked effectively because of the vanishing gradient no matter which hyperparameters we chose. We assumed this was because the training dataset was too small, and indeed, it consisted of only 308 ECGs. Although this quantity of data is generally considered quite small for creating a CNN model, the present model achieved comparable accuracy to that of established algorithms. As the classifying ability of CNN will evolve as the training data increases, we expect that the classifier using CNN will be more accurate with increasing data. An ECG is a diagnostic tool that visualizes electrical activity within a heart from multiple aspects. Electrical conduction during PVCs can be patterned; hence the predictive accuracy of the AI model can theoretically be expected to reach nearly 100% as long as the heart does not have conductive abnormalities. We assume that the distinctive ability of the AI model has the potential to become more precise by accumulating datasets so that it will be able to perform more complicated classifications, not only of the LVOT but also of sites distinct from any of the coronary cusps or epicardium. Another possible option for utilizing the CNN for machine learning is to export the PVC ECG strips as image files and put them into a 2-dimensional CNN as an image recognition task; however, it may require far more training data, so we did not attempt that in the present study.

The accurate origin prediction prior to the procedure is crucial in the clinical setting and is not so difficult for well-trained electrophysiologists in most of the PVC cases, so these machine learning models are useful mainly for the person who is not well trained. However, we think these are also useful even for the skilled ablationist, as there do exist the confusion cases as shown in Figure 4. Catheter ablation is generally attempted from the right side of the heart via the inferior vena cava for PVCs from the RV and possibly via the superior vena cava for some case of RVOT PVCs. On the other hand, the transaortic retrograde approach is usually attempted first for PVCs from the LVOT and the transatrial septal antegrade approach is attempted first for PVCs from other LV sites. The accurate prediction of the PVC origin prior to the procedure contributes to avoiding unnecessary catheter manipulation and therefore reduces the procedure time and perioperative adverse event risks. The waveform change by ablation was observed in 16 PVCs. It means that these could have emerged from the intramural area rather than the endocardium. In this study, the final waveforms and successful sites were registered, which means that the

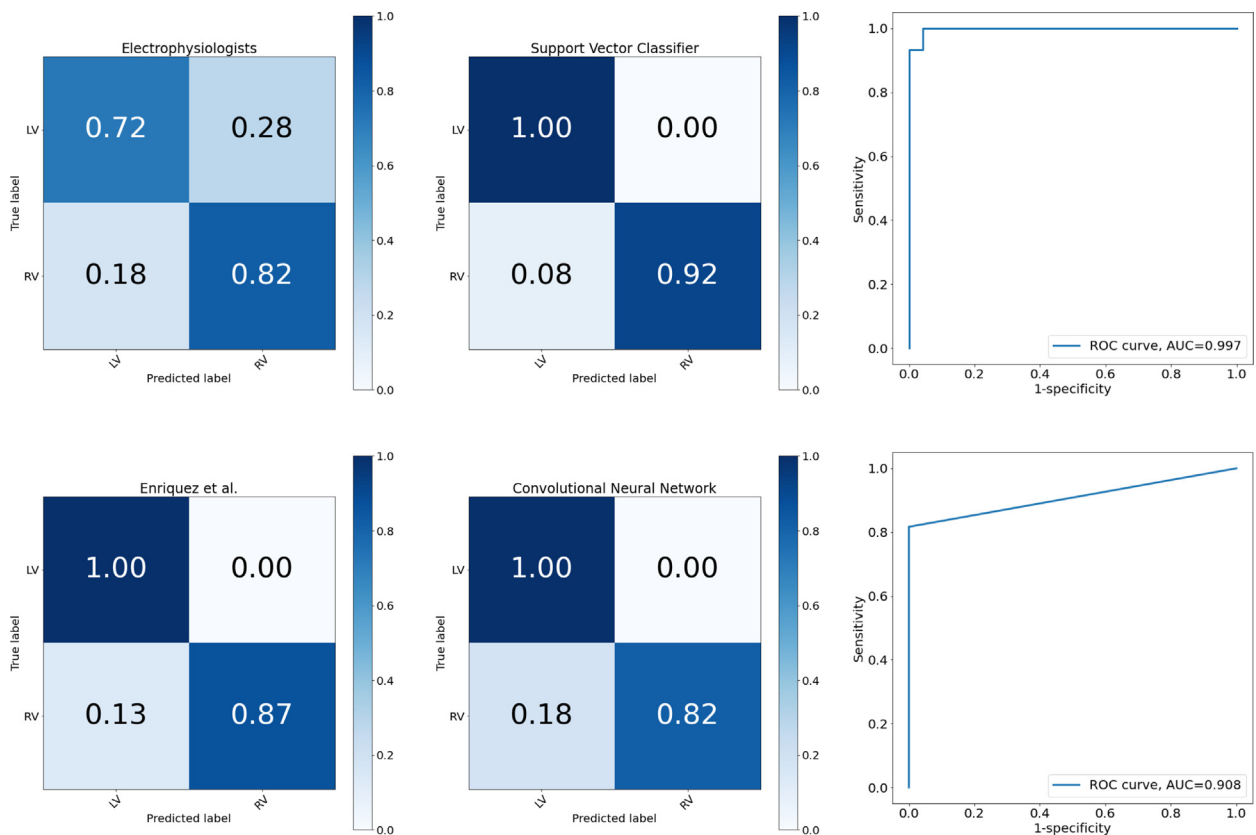


Figure 5 Confusion matrices of the binary classification for the board-certified electrophysiologists, existing classification algorithm, support vector machine (SVM), and convolutional neural network (CNN). The receiver operating characteristic (ROC) curves for the performance of the machine learning models are shown in the right panels (top: ROC curve for the SVM; bottom: ROC curve for the CNN). The accuracy of the origin of each premature ventricular complex is displayed in a color gradient scale.

final remaining exit sites were registered. It might be more accurate to say that these were the programs that predicted exit, rather than the origin.

Limitations

The present study had several limitations. First, as described in the discussion section, the sample size was sufficient for SVM but relatively small for CNN. Therefore, the results may be still preliminary and not definitive for the CNN model. Second, this study was a single-center study and the ECG data were derived from a specific recording system; thus the applicability in other settings remains to be determined. Third, the conductivity within the heart can be affected by the presence of bundle branch block or a myocardial infarction, which were not considered in this study. Finally, the ECGs in this study were derived during ablation sessions using an electroanatomical mapping system. During ablation with these systems, there are often many patches for the mapping system and defibrillator, and this sometimes results in PVCs not recording the same as they would outside of the lab. This might have made the analysis by humans challenging. In this study, we used Enriquez's Criteria as a comparator of the algorithms, but it has to be noted that this is not a prospectively derived and validated algorithm, nor was it intended to distinguish right vs left sources alone.

Conclusion

AI-enabled algorithms that predict the origin of PVCs achieved superb accuracy compared to the electrophysiologists and comparable accuracy to the existing algorithm. This study showed the promising perspective of the machine learning models that predict PVC origin. Further model training with accumulated samples is warranted to improve the diagnostic efficacy.

Acknowledgments

We thank Mr John Martin for his linguistic assistance with this article.

Funding Sources

This research did not receive any specific grant from funding agencies in the public, commercial, or not-for-profit sectors.

Disclosures

The authors declare no conflicts of interest.

References

1. Baman TS, Lange DC, Ilg KJ, et al. Relationship between burden of premature ventricular complexes and left ventricular function. *Heart Rhythm* 2010; 7:865–869.

2. Takemoto M, Yoshimura H, Ohba Y, et al. Radiofrequency catheter ablation of premature ventricular complexes from right ventricular outflow tract improves left ventricular dilation and clinical status in patients without structural heart disease. *J Am Coll Cardiol* 2005;45:1259–1265.
3. Sekiguchi Y, Aonuma K, Yamauchi Y, et al. Chronic hemodynamic effects after radiofrequency catheter ablation of frequent monomorphic ventricular premature beats. *J Cardiovasc Electrophysiol* 2005;16:1057–1063.
4. Yarlalagadda RK, Iwai S, Stein KM, et al. Reversal of cardiomyopathy in patients with repetitive monomorphic ventricular ectopy originating from the right ventricular outflow tract. *Circulation* 2005;112:1092–1097.
5. Bogun F, Crawford T, Reich S, et al. Radiofrequency ablation of frequent, idiopathic premature ventricular complexes: comparison with a control group without intervention. *Heart Rhythm* 2007;4:863–867.
6. Cronin EM, Bogun FM, Maury P, et al. 2019 HRS/EHRA/APHRS/LAHR expert consensus statement on catheter ablation of ventricular arrhythmias. *Heart Rhythm* 2020;17:e2–e154.
7. Yamada T, Doppalapudi H, Litovsky SH, McElderry HT, Kay GN. Challenging radiofrequency catheter ablation of idiopathic ventricular arrhythmias originating from the left ventricular summit near the left main coronary artery. *Circ Arrhythm Electrophysiol* 2016;9:e004202.
8. Whitman IR, Gladstone RA, Badhwar N, et al. Brain emboli after left ventricular endocardial ablation. *Circulation* 2017;135:867–877.
9. Enriquez A, Baranchuk A, Briceno D, Saenz L, Garcia F. How to use the 12-lead ECG to predict the site of origin of idiopathic ventricular arrhythmias. *Heart Rhythm* 2019;16:1538–1544.
10. Marcus GM. Evaluation and management of premature ventricular complexes. *Circulation* 2020;141:1404–1418.
11. Cohen AM, Chamberlin S, Deloughery T, et al. Detecting rare diseases in electronic health records using machine learning and knowledge engineering: Case study of acute hepatic porphyria. *PLoS One* 2020;15:e0235574.
12. Miskin N, Qin L, Matalon SA, et al. Stratification of cystic renal masses into benign and potentially malignant: applying machine learning to the bosniak classification. *Abdom Radiol* 2020; <https://doi.org/10.1007/s00261-020-02629-w>.
13. Chang KC, Hsieh PH, Wu MY, et al. Usefulness of machine learning-based detection and classification of cardiac arrhythmias with 12-lead electrocardiograms. *Can J Cardiol* 2020;S0828-282X(20). 30216-6.
14. Attia ZI, Noseworthy PA, Lopez-Jimenez F, et al. An artificial intelligence-enabled ECG algorithm for the identification of patients with atrial fibrillation during sinus rhythm: a retrospective analysis of outcome prediction. *Lancet* 2019;394:861–867.
15. Hannun AY, Rajpurkar P, Haghpanahi M, et al. Cardiologist-level arrhythmia detection and classification in ambulatory electrocardiograms using a deep neural network. *Nat Med* 2019;25:65–69.
16. Ko WY, Siontis KC, Attia ZI, et al. Detection of hypertrophic cardiomyopathy using a convolutional neural network-enabled electrocardiogram. *J Am Coll Cardiol* 2020;75:722–733.
17. Yokokawa M, Liu TY, Yoshida K, et al. Automated analysis of the 12-lead electrocardiogram to identify the exit site of postinfarction ventricular tachycardia. *Heart Rhythm* 2012;9:330–334.
18. Sapp JL, Bar-Tal M, Howes AJ, et al. Real-time localization of ventricular tachycardia origin from the 12-lead electrocardiogram. *JACC Clin Electrophysiol* 2017;3:687–699.
19. Yokokawa M, Jung DY, Hero AO III, et al. Single- and dual-site pace mapping of idiopathic septal intramural ventricular arrhythmias. *Heart Rhythm* 2016;13:72–77.
20. Kanagaratnam L, Tomassoni G, Schweikert R, et al. Ventricular tachycardias arising from the aortic sinus of Valsalva: An under-recognized variant of left outflow tract ventricular tachycardia. *J Am Coll Cardiol* 2001;37:1408–1414.
21. Enriquez A, Malavassi F, Saenz LC, et al. How to map and ablate left ventricular summit arrhythmias. *Heart Rhythm* 2017;14:141–148.