



Case report

Unusual location of cutaneous alternariosis in an immunocompetent patient



Maroua Jebari^{a,d}, Latifa Mtibaa^{a,d,*}, Rym Abid^{b,d}, Souha Hannechi^{b,d}, Hana Soudi^a, Riadh Battikh^{b,d}, Bassem Louzir^{c,d}, Boutheina Jemli^a

^a Laboratory of Parasitology-Mycology, Military Hospital of Tunis, Monfleury, 1008 Tunis, Tunisia

^b Department of Infectious Diseases, Military Hospital of Tunis, Monfleury, 1008 Tunis, Tunisia

^c Department of Internal Medicine, Military Hospital of Tunis, Monfleury, 1008 Tunis, Tunisia

^d Faculty of medicine of Tunis, University Tunis El Manar, Tunisia

ARTICLE INFO

Article history:

Received 10 May 2021

Received in revised form 22 November 2021

Accepted 5 December 2021

Available online xxxx

Keywords:

Cutaneous alternariosis

Immunocompetent

Alternaria alternata

ABSTRACT

Alternaria is a dematiaceous fungus ubiquitously found in nature. It can cause infections, especially in immunocompromised patients. We report a periorbital location of *Alternaria* infection in an immunocompetent woman with a confusing clinical presentation. The diagnosis was confirmed by a cutaneous biopsy of the cheek. PCR sequencing identified *Aternaria alternata* species. The evolution was fatal despite antifungal treatment.

© 2021 Published by Elsevier Ltd.

CC_BY_NC_ND_4.0

Introduction

Alternaria is a dematiaceous fungus ubiquitously found in nature. Thereby it could contaminate the culture or colonize the skin but not infect superficial tissue [1,2]. Phaeohyphomycoses are caused by this melanized mold and are uncommon as human infection [2,3]. Furthermore, this fungus has a wide spectrum of clinical disease from local organ manifestations to systemic infection [1,4]. It has often been associated with hypersensitivity pneumonitis, bronchial asthma, and allergic sinusitis and rhinitis. Nevertheless, it can cause paranasal sinusitis, eye infections, onychomycosis, skin infections, or granulomatous lung disease, soft palate perforation, and disseminated disease [5,6]. Infection by *Alternaria* species are mostly localized in the skin and soft tissue and are of specific concern in immunocompromised patients (transplanted patients, sarcoidosis, hematological malignancy, Diabetes) [3,4,7–9]. However, only a few cases of primary cutaneous alternariosis have been reported in

immunocompetent patients [2,6,10,11]. We report a periorbital location of *Alternaria* infection in an immunocompetent woman with a confusing clinical presentation. We also provide a review of previously reported cases in the literature.

Case

A 36 yearsold woman, pharmacy assistant who has no significant pathological history, no particular treatment or use of contact Lenses nor of special eye drops, was hospitalized in Ophthalmology department 6 months ago for a bilateral eyelid redness with edema evolving for 2 months (without fever). At the initial biology, the CBC, Sedimentation rate (SR), C-reactive protein, PCT, Calcemia, phosphoremia, serum protein electrophoresis, serum-angiotensin converting enzyme, anti-nuclear antibodies, ANCA, β 2 microglobulin, Creatine kinase, AST, ALT, LDH, FT4 and TSH were normal. The tuberculin skin test was 6 mm and the test for *Mycobacterium tuberculosis* in sputum was negative. The chest x-ray was without abnormalities. Orbital MRI revealed inflammatory thickening of the left lacrimal gland, oculomotor muscles and orbital fat, justifying a biopsy of the lacrimal glands addressed to pathology department. It showed non-specific inflammation. An inflammatory pseudotumor was suspected and corticosteroid therapy was started at a dose of 1 mg/kg/day for 2 months combined with methotrexate at a dose of 20 mg per week for 1 month. The evolution was marked by the

Abbreviations: Fig, Figure

* Correspondence to: Laboratory of Parasitology-Mycology, Military Hospital of Tunis, Monfleury 1008 Tunisia.

E-mail addresses: jebarimaroua2@gmail.com (M. Jebari), mtibaalatifa@yahoo.fr (L. Mtibaa), abid_rym@yahoo.fr (R. Abid), souha_hannechi@yahoo.fr (S. Hannechi), hanasoudi@gmail.com (H. Soudi), battikh.riadh@gmail.com (R. Battikh), louzir.bassem@yahoo.fr (B. Louzir), bjemli@yahoo.fr (B. Jemli).

<https://doi.org/10.1016/j.idcr.2021.e01356>

2214-2509/© 2021 Published by Elsevier Ltd.

CC_BY_NC_ND_4.0

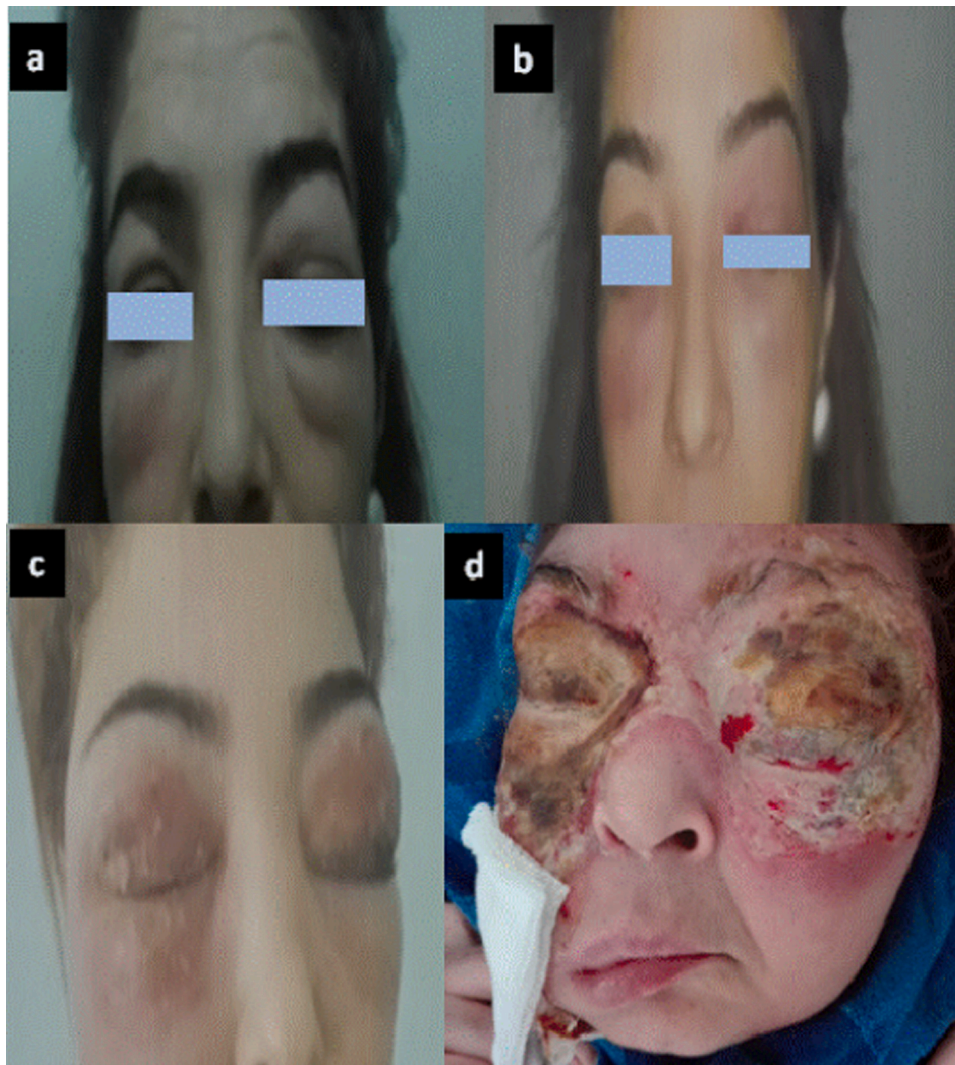

Fig. 1. : Clinical evolution of orbital edema: Day 0 (a); Day +15 (b); Day +45 (c); Day +60 (d).

decrease in visual acuity related to a compressive occlusion of the central artery of the left eye. A CT scan of the facial mass showed an osteosclerotic bone change predominant in the left orbit and maxillary sinuses suggesting inflammatory involvement. A second biopsy of the nasal cavity sent to pathology department, revealed an erosive chronic inflammatory rearrangement of the nasal mucosa without specific granuloma or signs of malignancy. She was treated by broad-spectrum antibiotic therapy during 18 days without improvement.

Therefore, she was addressed to the department of infectious disease and was hospitalized on day 0. On admission, she was febrile at 39 °C. She had bilateral proptosis, edema, and eyelid and periorbital redness with crusted lesions and clear secretions causing discomfort in eyelids opening. Fig. 1 illustrates the clinical evolution of skin lesions. The ophthalmologic examination showed a decrease in visual acuity on the right eye with no light perception on the left one. It also objective a weak direct photomotor reflex on the right eye, a reflective mydriasis on the left eye, hypertonic globes, suggesting compressive optic neuropathy. An examination under general anesthesia revealed in the anterior segment of eyes, significant chemosis and corneal edema, the posterior chamber was not seen (day 1). Biology investigation (day 0) to research an underlying disease as inflammatory disease or a cause of immunodepression: anti-SSA/Ro, anti-SSB/La, Rheumatoid factor, C3, C4, dsDNA and HIV

serology were ordered and were normal; the CBC showed a pancytopenia (Hb=10.3 g /dl; MCV=80.2 fl; WBC=2800/mm³; neutrophils=2230/mm³; lymphocytes=300/mm³; platelets=95000/mm³) justifying a sternal puncture (for bone marrow aspiration) which was normal. C-reactive protein, PCT were negative and SR was 40 mm/hour. A hypercalciuria at 24 mmol/24 h was noted. Orbital MRI (day 9) showed a diffuse intra and extra orbital inflammatory process infiltrating periorbital soft tissues, oculomotor muscles, and optic nerves evoking granulomatosis (Fig. 2). Thoracoabdominal CT (day 9) showed a pericardial effusion of moderate abundance. The diagnosis of sarcoidosis was evoked justifying the prescription of 3 boluses of solumedrol followed by an oral relay at a dose of 1 mg/kg/day with a dose of Endoxan 700 mg on day 15. Nevertheless, the fever persisted. The CBC was normalized. A third biopsy of the orbital fat was made on day 41 and addressed to pathology department. Histological study showed of a dense and diffuse inflammatory reaction without signs of malignancy. Microbiological swab of lesions was sent to Microbiology and parasitology laboratories. It was positive in culture for *Alcaligenes xylosoxidans*, *Stenotrophomonas maltophilia* and *Candida albicans*. The patient was therefore treated with antibiotic therapy, voriconazole and corticosteroid therapy was maintained at a dose of 40 mg (day 45).

In front of the extension of the edema to the hemiface and the appearance of cutaneous necrosis in the left cheek (Fig. 1), the

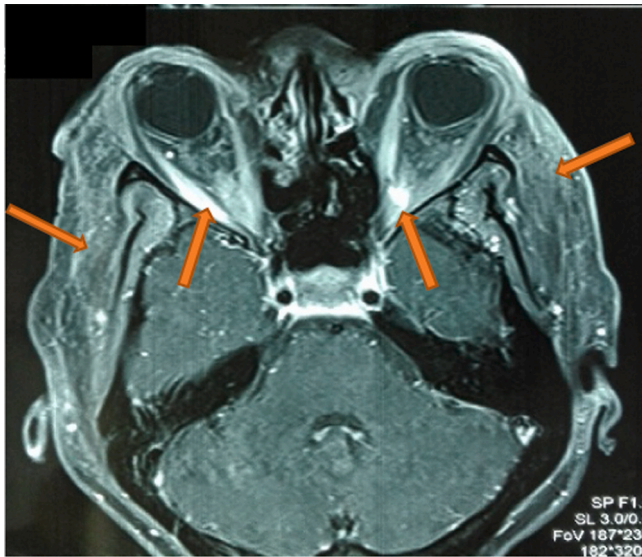

Fig. 2. : Orbital MRI: Diffuse inflammation intra and extra orbital infiltrating peri-orbital soft tissues, oculomotor muscles and optic nerves.

diagnosis of mucormycosis was suspected. Thus the corticosteroid therapy was stopped and the V-fend was replaced by Amphotericin B (AMB: 1 mg/kg/day) (on day 52) associated to antibiotic therapy. However, no improvement was seen. The last cutaneous biopsy of the cheek was sent to the parasitology laboratory on day 60 and isolated in culture *Alternaria sp.* The diagnosis of facial alternariosis has been made. But unfortunately the evolution was fatal despite antifungal treatment (she totalized 8 days of AMB).

Microbiological study

The specimen was cultured on Chloramphenicol Sabouraud agar medium. After 7 days of culture, the colonies appear black and downy on the recto side and brown/black on the reverse side. The microscopic examination of colonies showed brown dictyospores arranged in short chains compatible with *Alternaria* species (Fig. 3). For species identification, molecular techniques were used. DNA was extracted from the colonies. The ITS2 region was amplified and sequenced using universal primers ITS1 (5'-TCCGTAGGTGAACCTGCGGC-3') and ITS4 (5'-TCCTCCGCTTATTGATATGC-3').




Fig. 3. : Characterization of *Alternaria alternata* colonies on front view (a) and back view (b) after culture on Sabouraud medium for 7 days.c: Dark septate hyphae and multiple dictyospores arranged in short chains. Scale bar = 20 µm.

Table 1 Characteristics and species of 10 immunocompetent patients with cutaneous alternariosis in the literature.

Authors/Year	Country	Patient Age/Sex	Lesion site	Associated Trauma	Corticosteroid	Species Identified	Treatment	Outcome
Current case	Tunisia	36/Female	orbital	No	yes	<i>Alternaria alternata</i>	Amphotericin B	Death
Z. Hattab /2019[6]	Tunisia	19/ Male	Rhino sinusitis and orbital	Not reported	None	<i>Alternaria alternata</i>	Amphotericin B followed by itraconazole+surgery	Healing
R.C. Patel/2015[2]	USA	13/Male	Ankle	Kicked duringSporting event	None	<i>Alternaria spp.</i>	Oral itraconazole, topical econazole 1%	Healing
Hu W./2014[10]	China	28/Male	Leg	Tripped over a stone	None	<i>Alternaria arborescens</i>	Oral itraconazole, topical amphotericin B 0.25%	Healing
Dessoniti/2013[19]	Greece	58/Male	Dorsal Hand	Lemon tree thorn	None	<i>Alternaria alternata</i>	Oral fluconazole, topical bifonazole 1%	Healing
Matson DR/2010[12]	USA	17/Male	Ankle	Laceration	None	<i>Alternaria spp.</i>	Oral itraconazole	Healing
GurcanS./2009[11]	Turkey	71/Male	Ankle	Not reported	None	<i>Alternaria alternata</i>	Oral itraconazole, topical bifonazole, oral/topical griseofulvin	Healing
Williams C./2008[20]	UK	85/Male	Thigh	No trauma	None	<i>Alternaria spp.</i>	Oral itraconazole	Healing
Ono M./2004[13]	Mexico	48/Female	Knee	Not reported	Yes (topical steroid prescribed for Reiter's disease) before Alternariosis diagnosis	<i>Alternaria alternata</i>	Oral itraconazole	Healing
Robb CW/2003[14]	USA	6/Male	Cheek	Not reported	Yes (desonide 0.05% cream) prescribed for <i>Alternaria</i> infection	<i>Alternaria spp.</i>	Oral fluconazole, topical econazole	Healing

After DNA extraction, the amplification of the ITS2 region gives a DNA band of approximately 600 bp. By comparing the sequencing data to others existing on GenBank, the present species matched 100% to *Alternaria alternata*.

Discussion

In total, our patient was immunocompetent and had an un-specific clinical presentation evolving for 6 months before her admission. During her 2 months of hospitalization, several diagnoses were evoked: granulomatosis, sarcoidosis with prolonged corticosteroid therapy further aggravating the lesions. Four biopsies were performed, of which 3 were addressed to anatomopathology and did not allow visualization of the fungus. Only one but late biopsy was addressed in mycology and allowed the isolation of *Alternaria*.

To our knowledge, there are nine cases reported of cutaneous alternariosis in immunocompetent patients (Table 1). The most common locations are the lower extremities, and there is a trauma story in most cases [2,10–13]. However in our case the notion of minor or major face trauma was not found. Hu in a review of all cutaneous alternariosis, reported 29 cases, and no one was located in the face. Only two of the 29 were immunocompetent and the infection was located at the legs [10,12]. Referring to Table 1, Robb CW et al. reported a facial location of alternariosis in a 6 years-old-child with a good outcome [14]. Hattab et al. reported a case of rhinosinusitis with orbital involvement due to *Alternaria* in an immunocompetent patient having a history of allergic rhinosinusitis [6]. We describe here a confusing presentation of facial alternariosis with orbital extension in an immunocompetent patient.

The clinical appearance of the alternariosis cutaneous lesions is very variable and un-specific. Symptoms observed could be thickening, ulcerations, nodules, plaques, scales, and erosions which lead to diagnosis difficulties [1,2,10]. In our case, the unusual presentation caused a delayed diagnosis and inappropriate therapy with corticosteroids and antibiotics.

The diagnosis of alternariosis is essentially based on the histological and mycological analysis of a biopsy sample [1,12]. This is due to their frequent occurrence as laboratory contaminants [15].

Histology can reveal hyperkeratosis, parakeratosis, granulomatous inflammation as well as fungal elements with PAS stain [6]. Mycological culture shows white-brown mold colonies composed of septate hyphae and chains of conidia with transverse and longitudinal septations [1,12]. Schuermans recommend combining the bacterial and fungal culture of tissue, with the pathological and mycological study as a cornerstone of the diagnosis. The value added by the molecular diagnosis is not negligible [16].

In our case the mycological culture was contributive but it was complemented by PCR sequencing in biopsy tissue. Molecular biology allows the identification of *Alternaria* species. In our patient, we isolated *Alternaria alternata*. This species represents 80% of identified species isolated from cutaneous alternariosis in healthy individuals (Table 1). Indeed, the majority of cutaneous and subcutaneous infections are by *Alternaria alternata* followed by *Alternaria infectoria*, *Alternaria tenuissima*, *Alternaria alternatum*, and *Alternaria tenuis* [17].

Cutaneous alternariosis usually requires the combination of wide excisional surgery, prolonged antifungal therapy, and reduction of immunosuppression [5,6,10]. According to Table 1, itraconazole was the most prescribed molecule with a good evolution in 67% of cases (7/10). Besides, the combination of antifungals was frequently used in 55% of cases (5/10) with a good outcome. However, there are no standardized therapies for alternariosis. Itraconazole, voriconazole, posaconazole, and amphotericin B constitute the cornerstones of the

antifungal management of cutaneous and subcutaneous alternariosis based on clinical data available [17,18]. Terbinafine also has been used successfully in the treatment of cutaneous alternariosis. Combination antifungal therapy can be recommended in disseminated cases [17].

The outcomes are often favorable, but the fatal issue is possible especially in the immunocompromised patients [8–10,15]. In our case, the ambiguity of the clinical presentation, the unusual orbital location, and especially the immunosuppressive therapies provided delayed the diagnosis and worsened the prognosis.

In conclusion, the melanized fungus genus *Alternaria* is now an emerging cause of fungal disease in humans. We describe a rare case of orbital alternariosis in an immunocompetent patient with a confusing presentation. The use of mycological examination of tissue and the value added by the molecular diagnosis can remedy diagnosis difficulty.

Author statement

All persons who meet authorship criteria are listed as authors, and all authors certify that they have participated sufficiently in the work to take public responsibility for the content, including participation in the concept, design, analysis, writing, or revising of the manuscript.

Conflict of Interest

There are no conflicts of interest for any authors.

References

- [1] Pastor FJ, Guarro J. *Alternaria* infections: laboratory diagnosis and relevant clinical features. *Clin Microbiol Infect* 2008;14:734–46.
- [2] Patel RC, Helm M, Shimizu I. Cutaneous alternariosis in an immunocompetent patient. *Dermatol Online J* 2016;22(10). [PMID: 28329593].
- [3] Bajwa R, Wojciechowski AL, Hsiao C-B. Cutaneous alternariosis in a renal transplant patient successfully treated with posaconazole: case report and literature review. *Med Mycol Case Rep* 2017;15:16–20.
- [4] Lyke KE, Miller L, Towne WG, Merz NS. A case of cutaneous ulcerative alternariosis: rare association with diabetes mellitus and unusual failure of itraconazole treatment. *Clin Infect Dis* 2001;32:1178–87.
- [5] Alina Y. Lou, Todd J. Wannemuehler et al., Orbital apex syndrome caused by *Alternaria* species: A novel invasive fungus and new treatment paradigm. *Orbit*. (Doi: 10.1080/01676830.2019.1582071).
- [6] Z. Hattab, N. Ben Lasfar et al., *Alternaria alternata* infection causing rhinosinusitis and orbital involvement in an immunocompetent patient. *New Microbes and New Infections*, <https://doi.org/10.1016/j.nmni.2019.100561>.
- [7] González-Vela MC, Armesto S, Unda-Villafuerte F, Val-Bernal JF. Cutaneous infection with *Alternaria triticina* in a Bilateral lung transplant recipient. *Actas Dermosifiliogr* 2014;105(8):e51–4.
- [8] Ioannidou D, Maraki S, Kru "ger Krasagakis S, Stefanidou M, Krasagakis K, Alexandrakis M, et al. Cutaneous alternariosis revealing acute myeloid leukaemia in an adult patient. *Mycoses* 2004;47:227–30.
- [9] Saegeman VS, Dupont LJ, Verleden GM, Lagrou K. *Paecilomyces lilacinus* and *Alternaria infectoria* cutaneous infections in a sarcoidosis patient after double-lung transplantation. *Acta Clin Belg* 2012;67:219–21.
- [10] Hu W, Ran Y, Zhuang K, Lama J, Zhang C. *Alternaria arborescens* infection in a healthy individual and literature review of cutaneous alternariosis. *Mycopathologia* 2015;179(1–2):147–52. [PMID:25370461].
- [11] Gürcan S, Pişkin S, Kiliç H, Temelli BA, Yalçın O. [Cutaneous infection caused by *Alternaria alternata* in an immunocompetent host]. *Mikrobiyoloji Bul* 2009;43(1):163–7. [PMID:19334395].
- [12] Matson DR, Eudy JD, Matson SC. Cutaneous alternariosis in an adolescent patient. *Pediatr Dermatol* 2010;27:98–100.
- [13] Ono M, Nishigori C, Tanaka C, Tanaka S, Tsuda M, Miyachi Y. Cutaneous alternariosis in an immunocompetent patient: analysis of the internal transcribed spacer region of rDNA and Brm2 of isolated *Alternaria alternata*. *Br J Dermatol* 2004;150(4):773–5. [PMID:15099381].
- [14] Robb CW, Malouf PJ, Rapini RP. Four cases of dermatomycosis: superficial cutaneous infection by *Alternaria* or *Bipolaris*. *Cutis* 2003;72(4):313–6. 319. [PMID:14604084].

- [15] Gomes J, Vilarinho C, Duarte Mda L, Brito C. Cutaneous phaeohyphomycosis caused by *Alternaria alternata* unresponsive to itraconazole treatment. *Case Rep Dermatol Med* 2011;2011:385803 <https://doi.org/10.1155/2011/385803>
- [16] Schuermans W, Hoet K, Stessens L, Meeuwissen J, Vandepitte A, Van Mieghem A, et al. Molecular identification of cutaneous alternariosis in a renal transplant patient. *Mycopathologia* 2017;182:873–7. <https://doi.org/10.1007/s11046-017-0166-0>
- [17] Chowdhary A, Meis JF, Guarro J, de Hoog GS, Kathuria S, Arendrup MC, Arikian-Akdagli S, Akova M, Boekhout T, Caira M, Guinea J, Chakrabarti A, Dannaoui E, van Diepeningen A, Freiberger T, Groll AH, Hope WW, Johnson E, Lackner M, Lagrou K, Lanternier F, Lass-Flörl C, Lortholary O, Meletiadis J, Muñoz P, Pagano L, Petrikos G, Richardson MD, Roilides E, Skiada A, Tortorano AM, Ullmann AJ, Verweij PE, Cornely OA, Cuenca-Estrella M, European Society of Clinical Microbiology and Infectious Diseases Fungal Infection Study G, European Confederation of Medical M. ESCMID and ECMM joint clinical guidelines for the diagnosis and management of systemic phaeohyphomycosis: diseases caused by black fungi. *Clin Microbiol Infect* 2014;20(Suppl. 3):47–75. <https://doi.org/10.1111/1469-0691.12515>
- [18] Sharkey PK, Graybill JR, Rinaldi MG, Stevens DA, Tucker RM, Peterie JD, Hoepfich PD, Greer DL, Frenkel L, Counts GW. Itraconazole treatment of phaeohyphomycosis. *J Am Acad Dermatol* 1990;23(3 Pt 2):577–86. [PMID:2170477].
- [19] Dessinioti C, Soumalevris A, Papadogeorgaki E, Athanasopoulou V, Christofidou E, Antoniou C, Stratigos AJ. Cutaneous alternariosis in an immunocompetent patient successfully treated with oral fluconazole. *Eur J Dermatol* 2013;23(4):545–7. [PMID:24001697].
- [20] Williams C, Layton AM, Kerr K, Kibbler C, Barton RC. Cutaneous infection with an *Alternaria* sp. in an immunocompetent host. *Clin Exp Dermatol* 2008;33(4):440–2. [PMID:18312460].