

# Multimodality imaging in macular telangiectasia 2: A clue to its pathogenesis

Lihteh Wu

Macular telangiectasia type 2 also known as idiopathic perifoveal telangiectasia and juxtafoveolar retinal telangiectasis type 2A is an acquired bilateral neurodegenerative macular disease that manifests itself during the fifth or sixth decades of life. It is characterized by minimal dilatation of the parafoveal capillaries with graying of the retinal area involved, a lack of lipid exudation, right-angled retinal venules, refractile deposits in the superficial retina, hyperplasia of the retinal pigment epithelium, foveal atrophy, and subretinal neovascularization (SRNV). Our understanding of the disease has paralleled advances in multimodality imaging of the fundus. Optical coherence tomography (OCT) images typically demonstrate the presence of intraretinal hyporeflective spaces that are usually not related to retinal thickening or fluorescein leakage. The typical fluorescein angiographic (FA) finding is a deep intraretinal hyperfluorescent staining in the temporal parafoveal area. With time, the staining may involve the whole parafoveal area but does not extend to the center of the fovea. Long-term prognosis for central vision is poor, because of the development of SRNV or macular atrophy. Its pathogenesis remains unclear but multimodality imaging with FA, spectral domain OCT, adaptive optics, confocal blue reflectance and short wave fundus autofluorescence implicate Müller cells and macular pigment. Currently, there is no known treatment for this condition.

**Key words:** Choroidal neovascularization, idiopathic juxtafoveal telangiectasis, juxtafoveal retinal telangiectasia, lutein, macular edema, macular pigment, macular telangiectasia, Müller cells, parafoveal telangiectasis, perifoveal telangiectasis, retinal angiomatous proliferation, retinal telangiectasis, subretinal neovascularization, zeaxanthin

Many ocular and systemic conditions may manifest retinal telangiectasis or abnormal dilation of the retinal capillary network. In 1982, Gass and Oyakawa<sup>[1]</sup> were the first to identify patients with retinal telangiectasis limited to the parafoveal area with no apparent specific cause. They named this condition idiopathic juxtafoveolar retinal telangiectasis (IJRT) and classified it into four groups. Over the years, others have referred to this condition as idiopathic parafoveal retinal telangiectasis.<sup>[1]</sup> In 1993, Gass and Blodi<sup>[2]</sup> further modified this classification by dividing the eyes into three groups and each group was further subdivided into two other sub-groups. In an attempt to simplify the Gass-Blodi classification, Yannuzzi *et al.*<sup>[3]</sup> divided IJRT into two broad groups: Aneurysmal telangiectasia or idiopathic macular telangiectasia type 1 (MacTel 1) and perifoveal telangiectasis, also known as idiopathic (MacTel 2). Eyes with MacTel 2 were further subdivided into the nonproliferative stage characterized by telangiectasia and foveal atrophy; and the proliferative stage characterized by the presence of subretinal neovascularization (SRNV).<sup>[3]</sup>

Our understanding of MacTel 2 has paralleled advances in multimodality imaging of the ocular fundus. For many years, MacTel 2 was considered as primary retinovascular disease based on the fluorescein angiographic (FA) findings. Multimodality imaging has provided new insights into the pathogenesis of this condition.

Asociados de Macula, Vitreo y Retina de Costa Rica, San Jose, Costa Rica

**Correspondence to:** Dr. Lihteh Wu, Asociados de Macula, Vitreo y Retina de Costa Rica, San Jose, Costa Rica. E-mail: LW65@cornell.edu

**Manuscript received:** 11.09.14; **Revision accepted:** 26.05.15

Access this article online

Website:

www.ijo.in

DOI:

10.4103/0301-4738.159864

Quick Response Code:



## Clinical Findings

Most patients complain of nonspecific symptoms such as mild blurring of vision, positive scotoma, difficulty in reading and metamorphopsia.<sup>[4-7]</sup> Initially, the disease is characterized by relatively good visual acuities of  $\geq 20/30$ .<sup>[8,9]</sup> The earliest ophthalmoscopic changes seen in MacTel 2 are rather subtle and may be missed easily. The first sign is a mild grayish discoloration of the retina with loss of retinal transparency temporal to the fovea. At this point, telangiectatic vessels will be absent or barely evident on clinical examination. FA is often necessary to demonstrate the abnormal juxtafoveolar capillary network.<sup>[3,8,10]</sup> With disease progression, this grayish discoloration surrounds the parafoveal retina in an oval configuration.<sup>[2,3,10]</sup> In addition, slightly dilated and blunted retinal venules that extend at right angles appear in the temporal parafoveal retina. Multiple, crystalline, golden, tiny, refractile deposits near the inner retinal surface are a common finding occurring in up to 45% of eyes.<sup>[1,2,10,11]</sup> These deposits are usually found near the telangiectasis and do not seem to correlate with the severity of the disease.<sup>[11]</sup> Intraretinal round yellow spot lesions measuring between 100  $\mu\text{m}$  and 300  $\mu\text{m}$  in diameter similar to those seen in the adult form of vitelliform foveomacular dystrophy or Best's disease occur in up to 5% of cases of MacTel 2.<sup>[2,12-14]</sup> Stellate foci of intraretinal pigmented black plaques composed of hyperplastic retinal pigment epithelium (RPE) cells may develop along the right angled vessels. A lamellar macular hole may develop as the result of focal atrophy of the foveolar retina. These lamellar holes are characterized by a distinct, often circular margin and central retinal thinning that does not extend beyond the edges of the capillary free zone.<sup>[1-3,15,16]</sup> Full-thickness macular holes have also been reported in MacTel 2.<sup>[17-22]</sup>

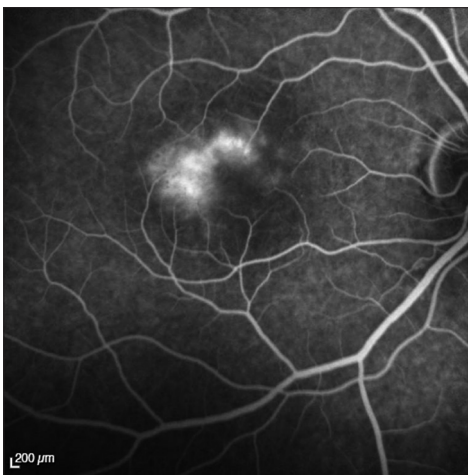Typically, there is no lipid exudation or hemorrhages associated with MacTel 2 unless SRNV is present.<sup>[2,9]</sup> SRNV usually develops in the vicinity of the intraretinal pigment plaques. Once present, SRNV is characterized by a rapid loss of vision, subretinal hemorrhage, cystoid macular edema, lipid hard exudates, disciform scarring, and retinochoroidal anastomosis.<sup>[3,13]</sup> Unlike choroidal neovascularization in age-related macular degeneration (AMD), SRNV in MacTel 2 is not usually accompanied by a RPE detachment.<sup>[3]</sup> Furthermore, the size of SRNV on MacTel 2 is small in comparison to AMD.<sup>[2]</sup>

### Fluorescein Angiography

Dilated ectatic perifoveal capillaries that leak dye in the parafoveal temporal areas are the typical FA findings in MacTel 2. In the early stages of the disease, the early phases of the angiogram are characterized by minimal or no evidence of capillary dilatation. The late phases are characterized by mild staining of the temporal parafoveal retina. This staining spares the foveal center. As the disease progresses, the capillary dilatation and permeability changes in the outer retina extend beyond the temporal parafoveal area to completely surround the fovea. This is manifested as a late oval-shaped parafoveal hyperfluorescence [Fig. 1].<sup>[2]</sup> The fluorescein leakage is not related to cystic spaces.<sup>[3]</sup> FA may also demonstrate dilated right-angle vessels. Intraretinal and/or subretinal anastomosis may arise from these vessels.<sup>[3]</sup> The foveal avascular zone in eyes with MacTel 2 is significantly reduced in size when compared to normal eyes.<sup>[23]</sup> The stellate hyperpigmented plaques typically block fluorescence. SRNV, when present, usually develops in the vicinity of the stellate hyperpigmented plaques.<sup>[2,8,13]</sup> The SRNV appears to originate from the deep retinal circulation and is characterized by early and late fluorescein leakage.<sup>[3,24]</sup>

### Indocyanine Green Angiography

Indocyanine green angiography (ICG-A) is the imaging modality of choice of the choroidal circulation. There are no MacTel 2 specific findings on ICG-A.<sup>[25]</sup> This should not come as a surprise since MacTel 2 spares the choroid and choriocapillaris.



**Figure 1:** Late frame from a fluorescein angiogram of an eye with macular telangiectasia type 2 showing the typical late leakage that does not involve the foveal center

### Optical Coherence Tomography

Optical coherence tomography (OCT) has played a key role in deepening our understanding of MacTel 2 by demonstrating the structural changes that occur in this disease. Unlike other retinal vascular disorders such as diabetic macular edema and branch retinal vein occlusion, OCT has shown that angiographic areas of leakage in MacTel 2 do not correlate with the presence of cystoid macular edema<sup>[16,26,27]</sup> or retinal thickening [Fig. 2].<sup>[16,27-29]</sup> In fact, foveal thickness is decreased in most patients with MacTel 2.<sup>[7,26-28,30-32]</sup>

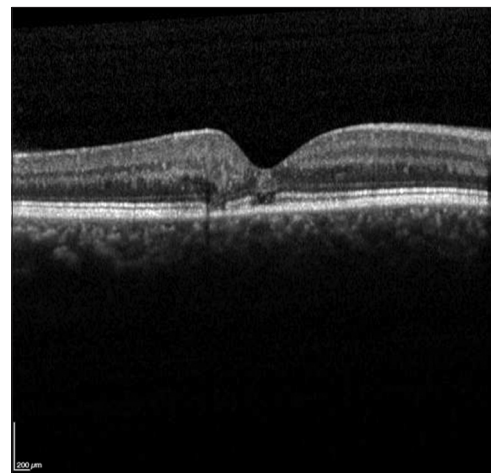
In addition, intraretinal hyporeflective spaces that are usually not related to retinal thickening or FA leakage are commonly seen.<sup>[16,27-31,33-35]</sup> The depth, size and location of these spaces influence macular function more than their mere presence.<sup>[7]</sup> Several different names for these lesions, including internal limiting membrane drape, cyst, cystoid or pseudo-cystoid space, have been used in the literature.<sup>[16,28]</sup>

Several investigators have described spectral-domain (SD)-OCT abnormalities of the outer retina.<sup>[16,34,36-38]</sup> All of these descriptions probably refer to the same pathologic process but at different stages of the disease.<sup>[36]</sup> Round, oval or comma-shaped hyper reflective spots in the outer parafoveal layers have been described to occur prior to any FA changes.<sup>[36,37]</sup> Alterations of the outer plexiform layer that have been described as “wrinkling” toward the outer retina have also been reported.<sup>[34]</sup> Thinning, disruption or loss of the photoreceptor layer particularly on the temporal side of the fovea and extending to the whole fovea in advanced cases are common SD-OCT findings [Fig. 2].<sup>[16,27,31,35,38]</sup>

More recently, Chhablani *et al.*<sup>[39]</sup> reported that in eyes with MacTel 2 the ganglion cell-inner plexiform layers are thinned suggesting a neurodegenerative process.

### Confocal Blue Reflectance

Confocal blue reflectance (CBR) imaging is a fast, safe, noninvasive imaging modality that captures the fundus reflectance after illuminating it with a confocal blue light of 488 nm emitted by a scanning laser ophthalmoscope (SLO). Unlike FA, there are no intervening barrier filters.<sup>[22]</sup> In eyes



**Figure 2:** Spectral domain optical coherence tomography showing disruption of the ellipsoid line

with MacTel 2, CBR imaging demonstrates an increased reflectance in an oval parafoveal pattern that is slightly larger than the area of late phase FA hyperfluorescence [Fig. 3].<sup>[22,34,40]</sup>

## Fundus Autofluorescence

Short wavelength fundus autofluorescence (SW-FAF) images of the posterior pole of the eye are obtained in a similar fashion to FA. The only difference is that there is no fluorescein injection. Briefly, the fundus is illuminated with confocal blue light of 488 nm emitted by SLO. The images are captured after the reflected light is filtered through a barrier filter of 520 nm. SW-FAF of the normal eye shows a central dark area caused by the light absorption by both RPE melanin and macular pigment.<sup>[41]</sup> Lutein and zeaxanthin are the two carotenoids that constitute the macular pigment. They accumulate primarily in the macular photoreceptor axons. In the parafoveal region, the inner and outer plexiform layers manifest the greatest concentration of macular pigment whereas in the fovea the greatest concentration would be in Henle's layer.<sup>[42]</sup>

One of the earliest changes reported in MacTel 2 is an increased SW-FAF signal in the foveal region [Fig. 4].<sup>[43]</sup> Initially, eyes exhibit a triangular segment of reduced macular pigment in the temporal fovea and central accumulation of macular pigment.<sup>[44]</sup> Then, there is further expansion of the triangular segment and disappearance of the central accumulation.<sup>[45]</sup>

## Adaptive Optics

As a wavefront of light passes through the pupil, ocular aberrations are normally induced. The quality of the image formed on the retina is diminished by these aberrations. Adaptive optics (AO) corrects these ocular aberrations and improves transverse resolution in retinal imaging.<sup>[46]</sup> AO allows high-resolution photoreceptor imaging.<sup>[46-48]</sup>

Adaptive optics documents disruption of the normal cone mosaic pattern in eyes with MacTel 2. Instead of the normal cone mosaic, eyes with MacTel 2 exhibit a lower cone density and ring-like or patchy dark areas on AO imaging. These abnormalities were even present in areas with normal retinal vasculature that strongly suggests that the neural degeneration precedes the vascular changes.<sup>[49]</sup> The dark areas on AO imaging corresponded to the late FA leakage. In some eyes, these AO

dark areas occurred in areas without FA leakage. Disruption of the ellipsoid line on SD-OCT was also associated with the dark regions on AO imaging.<sup>[49]</sup>

## Histopathology

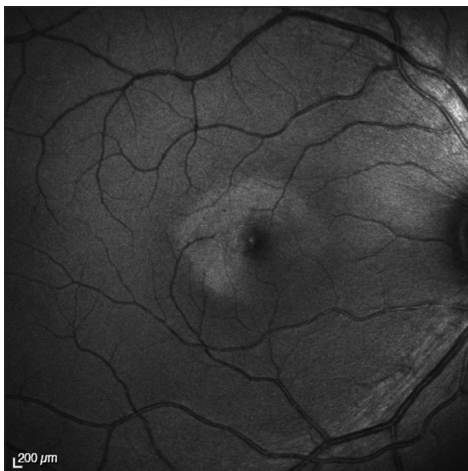There are currently only two clinicopathologic studies of confirmed MacTel 2 cases reported in the literature.<sup>[50,51]</sup> Luteal pigment was characteristically absent in these eyes. In addition, immunohistochemical analysis demonstrated the loss of perifoveal Müller cells. Interestingly, there was a topographical correlation between areas of macular pigment absence and areas of Müller cell depletion.<sup>[50]</sup> Loss of the ellipsoid line seen in SD-OCT was correlated with rod depletion.<sup>[51]</sup> Macular pigment loss occurs prior to the ellipsoid abnormalities seen on SD-OCT.<sup>[51]</sup>

## Animal Models

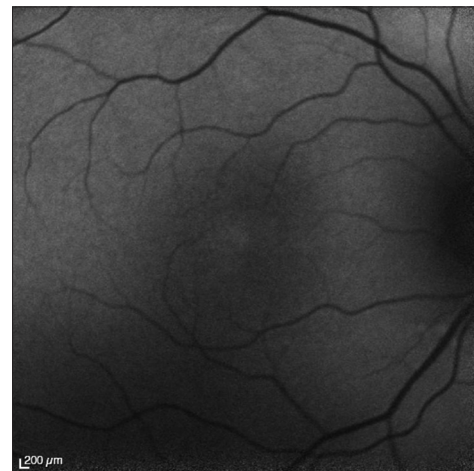
A transgenic mouse model with conditional ablation of Müller cells has been developed.<sup>[52]</sup> These animals exhibit photoreceptor apoptosis, retinal telangiectasis, breakdown of the blood retinal barrier and intraretinal neovascularization.

## Pathogenesis

All the available evidences point to the Müller cell as a central player in MacTel 2. The findings on AO imaging clearly demonstrates that neural degeneration precedes retinal vascular involvement.<sup>[49]</sup> The increased SW-AF signal in the fovea also precedes the FA changes. Histopathological findings show that the RPE is healthy in MacTel 2.<sup>[53,54]</sup> Thus, the increased SW-AF signal is most likely due to the depletion of luteal pigment rather than an increased lipofuscin accumulation in the RPE. Müller cells serve as a retinal reservoir for xanthophyll. Therefore any pathological process that involves Müller cells will affect the luteal pigment.<sup>[55]</sup> The increased CBR signal also implicates Müller cells. The increased CBR may be explained by four different mechanisms. First, since the absorption maximum of macular pigment is in the range of blue light at approximately 460 nm, decreased absorption or increased reflection of the blue light may be secondary to a decrease in macular pigment in the parafoveal area.<sup>[22,56]</sup> Second, Müller cells span the entire retinal thickness and may serve as optical fibers that allow transmission with a minimal reflection of light across the retina. Any pathological involvement of Müller cells would interrupt this mechanism and decrease



**Figure 3:** Increased confocal blue reflectance



**Figure 4:** Increased short wave fundus autofluorescence

transmission and increase reflectance.<sup>[57]</sup> Third, disruption of the normal architecture of the neurosensory retina coupled with the presence of edema may increase retinal reflectance. This does not seem to be the case in MacTel 2 since increased CBR may present without any corresponding OCT findings.<sup>[34]</sup> Finally, defective storage or metabolism of macular pigment may cause the formation of highly reflective crystalline deposits in the neurosensory layers. This may lead to an increased CBR.<sup>[22]</sup> So far, there have been no reports of such crystalline deposition but it may well be that these deposits are below the current detection level threshold of 7  $\mu\text{m}$  of axial resolution.<sup>[34]</sup>

Since Müller cells play an important role in the structural integrity of the fovea, the SD-OCT findings of hyporeflective spaces may well be cavitory spaces representing Müller cell loss rather than fluid-filled cystic spaces.<sup>[3]</sup> In addition, Müller cells help provide nutrition to the surrounding retinal neurons and also play a role in inducing and maintaining the integrity of the blood retinal barrier.<sup>[55]</sup> Their processes are intimately related to the retinal blood vessels in the outer plexus. The transgenic mouse model with conditional ablation of Müller cells demonstrates all the clinical findings seen in MacTel 2.<sup>[52]</sup>

## Unresolved Issues

- It remains unclear why some eyes develop SRNV and others do not.
- It remains unclear as to why the temporal parafoveal region is affected first.
- There are currently no treatment options for this disease with the exception of anti-vascular endothelial growth factor agents for eyes with SRNV.

## Take Home Message

- MacTel 2 is a primary neurodegenerative macular disease with secondary vascular involvement.

## Future Directions

- Development of the therapeutic agents that rescue Müller cells to test this hypothesis.
- Observations using new imaging tools such as OCT angiography with its ability to image the deeper retinal capillary plexus will undoubtedly provide new insights in the progression of the disease.

## Salient Features

- One of the earliest changes reported in MacTel 2 is an increased SW-FAF signal in the foveal region
- CBR imaging demonstrates an increased reflectance in an oval parafoveal pattern that is slightly larger than the area of late phase FA hyperfluorescence
- AO imaging clearly demonstrates that neural degeneration precedes retinal vascular involvement
- Clinicopathological correlation demonstrates that there is loss of perifoveal Müller cells that topographically correlate with areas of luteal pigment loss
- A transgenic mouse model with conditional ablation of Müller cells exhibits many of the clinical findings seen in MacTel 2.

## Literature Search

A search on MEDLINE and old MEDLINE using multiple search words including retinal telangiectasis, juxtafoveal telangiectasis,

parafoveal telangiectasis, and macular telangiectasia was performed on August 31, 2014. Articles and book chapters cited in the reference lists of articles obtained by this method were reviewed and included when considered appropriate. Relevant articles published in the English, French and Spanish languages in peer-reviewed journals were also included.

## References

1. Gass JD, Oyakawa RT. Idiopathic juxtafoveal retinal telangiectasis. *Arch Ophthalmol* 1982;100:769-80.
2. Gass JD, Blodi BA. Idiopathic juxtafoveal retinal telangiectasis. Update of classification and follow-up study. *Ophthalmology* 1993;100:1536-46.
3. Yannuzzi LA, Bardal AM, Freund KB, Chen KJ, Eandi CM, Blodi B. Idiopathic macular telangiectasia. *Arch Ophthalmol* 2006;124:450-60.
4. Charbel Issa P, Holz FG, Scholl HP. Metamorphopsia in patients with macular telangiectasia type 2. *Doc Ophthalmol* 2009;119:133-40.
5. Charbel Issa P, Helb HM, Rohrschneider K, Holz FG, Scholl HP. Microperimetric assessment of patients with type 2 idiopathic macular telangiectasia. *Invest Ophthalmol Vis Sci* 2007;48:3788-95.
6. Finger RP, Charbel Issa P, Fimmers R, Holz FG, Rubin GS, Scholl HP. Reading performance is reduced by parafoveal scotomas in patients with macular telangiectasia type 2. *Invest Ophthalmol Vis Sci* 2009;50:1366-70.
7. Charbel Issa P, Helb HM, Holz FG, Scholl HP, MacTel Study Group. Correlation of macular function with retinal thickness in nonproliferative type 2 idiopathic macular telangiectasia. *Am J Ophthalmol* 2008;145:169-75.
8. Ryan SJ. *Retina*. 4<sup>th</sup> ed. Philadelphia: Elsevier Mosby; 2006. p. 1409-15.
9. Casswell AG, Chaine G, Rush P, Bird AC. Paramacular telangiectasis. *Trans Ophthalmol Soc U K* 1986;105 (Pt 6):683-92.
10. Abujamra S, Bonanomi MT, Cresta FB, Machado CG, Pimentel SL, Caramelli CB. Idiopathic juxtafoveal retinal telangiectasis: Clinical pattern in 19 cases. *Ophthalmologica* 2000;214:406-11.
11. Moisseiev J, Lewis H, Bartov E, Fine SL, Murphy RP. Superficial retinal refractile deposits in juxtafoveal telangiectasis. *Am J Ophthalmol* 1990;109:604-5.
12. Margalit E, Apte RS, Sadda SR. Idiopathic parafoveal telangiectasis associated with a foveal pseudovitelliform lesion. *Br J Ophthalmol* 2002;86:1455-6.
13. Gass JD. *Stereoscopic Atlas of Macular Diseases: Diagnosis and Treatment*. 4<sup>th</sup> ed. Vol. 1. St. Louis: Mosby; 1997. p. 504-12.
14. Díaz-Rodríguez EJ. Group 2A idiopathic parafoveal telangiectasis. *Arch Soc Esp Oftalmol* 2005;80:541-5.
15. Patel B, Duvall J, Tullo AB. Lamellar macular hole associated with idiopathic juxtafoveal telangiectasia. *Br J Ophthalmol* 1988;72:550-1.
16. Cohen SM, Cohen ML, El-Jabali F, Pautler SE. Optical coherence tomography findings in nonproliferative group 2a idiopathic juxtafoveal retinal telangiectasis. *Retina* 2007;27:59-66.
17. Olson JL, Mandava N. Macular hole formation associated with idiopathic parafoveal telangiectasia. *Graefes Arch Clin Exp Ophthalmol* 2006;244:411-2.
18. Charbel Issa P, Scholl HP, Gaudric A, Massin P, Kreiger AE, Schwartz S, *et al*. Macular full-thickness and lamellar holes in association with type 2 idiopathic macular telangiectasia. *Eye (Lond)* 2009;23:435-41.
19. Gregori N, Flynn HW Jr. Surgery for full-thickness macular hole in patients with idiopathic macular telangiectasia type 2. *Ophthalmic Surg Lasers Imaging* 2010;41:1-4.
20. Koizumi H, Slakter JS, Spaide RF. Full-thickness macular hole formation in idiopathic parafoveal telangiectasis. *Retina* 2007;27:473-6.

21. Shukla D. Evolution and management of macular hole secondary to type 2 idiopathic macular telangiectasia. *Eye (Lond)* 2011;25:532-3.
22. Charbel Issa P, Berendschot TT, Staurengi G, Holz FG, Scholl HP. Confocal blue reflectance imaging in type 2 idiopathic macular telangiectasia. *Invest Ophthalmol Vis Sci* 2008;49:1172-7.
23. Mansour AM, Schachat A. Foveal avascular zone in idiopathic juxtafoveal telangiectasia. *Ophthalmologica* 1993;207:9-12.
24. Soheilian M, Tavallali A, Peyman GA. Identification of intraretinal neovascularization by high-speed indocyanine green angiography in idiopathic perifoveal telangiectasia. *Ophthalmic Surg Lasers Imaging* 2007;38:167-9.
25. Niskopoulou M, Balaskas K, Leung I, Sallo FB, Clemons TE, Bird AC, *et al.* Is indocyanine green angiography useful for the diagnosis of macular telangiectasia type 2? *Br J Ophthalmol* 2013;97:946-8.
26. Surguch V, Gamulescu MA, Gabel VP. Optical coherence tomography findings in idiopathic juxtafoveal retinal telangiectasis. *Graefes Arch Clin Exp Ophthalmol* 2007;245:783-8.
27. Koizumi H, Iida T, Maruko I. Morphologic features of group 2A idiopathic juxtafoveal retinal telangiectasis in three-dimensional optical coherence tomography. *Am J Ophthalmol* 2006;142:340-3.
28. Paunescu LA, Ko TH, Duker JS, Chan A, Drexler W, Schuman JS, *et al.* Idiopathic juxtafoveal retinal telangiectasis: New findings by ultrahigh-resolution optical coherence tomography. *Ophthalmology* 2006;113:48-57.
29. Sanchez JG, Garcia RA, Wu L, Berrocal MH, Graue-Wiechers F, Rodriguez FJ, *et al.* Optical coherence tomography characteristics of group 2A idiopathic parafoveal telangiectasis. *Retina* 2007;27:1214-20.
30. Gupta V, Gupta A, Dogra MR, Agarwal A. Optical coherence tomography in group 2A idiopathic juxtafoveal telangiectasis. *Ophthalmic Surg Lasers Imaging* 2005;36:482-6.
31. Gaudric A, Ducos de Lahitte G, Cohen SY, Massin P, Haouchine B. Optical coherence tomography in group 2A idiopathic juxtafoveal retinal telangiectasis. *Arch Ophthalmol* 2006;124:1410-9.
32. Lee HC, Liu M, Ho AC. Idiopathic juxtafoveal telangiectasis in association with celiac sprue. *Arch Ophthalmol* 2004;122:411-3.
33. Albin TA, Benz MS, Coffee RE, Westfall AC, Lakhpanl RR, McPherson AR, *et al.* Optical coherence tomography of idiopathic juxtafoveal telangiectasia. *Ophthalmic Surg Lasers Imaging* 2006;37:120-8.
34. Bottoni F, Eandi CM, Pedenovi S, Staurengi G. Integrated clinical evaluation of Type 2A idiopathic juxtafoveal retinal telangiectasis. *Retina* 2010;30:317-26.
35. Fallano KA, Ibrahim M, Nguyen QD, Do DV. Progressive changes from idiopathic macular telangiectasia seen with spectral domain optical coherence tomography. *Can J Ophthalmol* 2010;45:649-50.
36. Baumüller S, Charbel Issa P, Scholl HP, Schmitz-Valckenberg S, Holz FG. Outer retinal hyperreflective spots on spectral-domain optical coherence tomography in macular telangiectasia type 2. *Ophthalmology* 2010;117:2162-8.
37. Barthelmes D, Sutter FK, Gillies MC. Differential optical densities of intraretinal spaces. *Invest Ophthalmol Vis Sci* 2008;49:3529-34.
38. Maruko I, Iida T, Sekiryu T, Fujiwara T. Early morphological changes and functional abnormalities in group 2A idiopathic juxtafoveal retinal telangiectasis using spectral domain optical coherence tomography and microperimetry. *Br J Ophthalmol* 2008;92:1488-91.
39. Chhablani J, Rao HB, Begum VU, Jonnadulla GB, Goud A, Barteselli G. Retinal ganglion cells thinning in eyes with nonproliferative idiopathic macular telangiectasia type 2A. *Invest Ophthalmol Vis Sci* 2015;56:1416-22.
40. Charbel Issa P, Finger RP, Helb HM, Holz FG, Scholl HP. A new diagnostic approach in patients with type 2 macular telangiectasia: confocal reflectance imaging. *Acta Ophthalmol* 2008;86:464-5.
41. Schmitz-Valckenberg S, Holz FG, Bird AC, Spaide RF. Fundus autofluorescence imaging: Review and perspectives. *Retina* 2008;28:385-409.
42. Trieschmann M, van Kuijk FJ, Alexander R, Hermans P, Luthert P, Bird AC, *et al.* Macular pigment in the human retina: Histological evaluation of localization and distribution. *Eye (Lond)* 2008;22:132-7.
43. Wong WT, Forooghian F, Majumdar Z, Bonner RF, Cunningham D, Chew EY. Fundus autofluorescence in type 2 idiopathic macular telangiectasia: Correlation with optical coherence tomography and microperimetry. *Am J Ophthalmol* 2009;148:573-83.
44. Zeimer MB, Padge B, Heimes B, Pauleikhoff D. Idiopathic macular telangiectasia type 2: Distribution of macular pigment and functional investigations. *Retina* 2010;30:586-95.
45. Clemons TE, Gillies MC, Chew EY, Bird AC, Peto T, Figueroa MJ, *et al.* Baseline characteristics of participants in the natural history study of macular telangiectasia (MacTel) MacTel Project Report No 2. *Ophthalmic Epidemiol* 2010;17:66-73.
46. Liang J, Williams DR, Miller DT. Supernormal vision and high-resolution retinal imaging through adaptive optics. *J Opt Soc Am A Opt Image Sci Vis* 1997;14:2884-92.
47. Povazay B, Hofer B, Torti C, Hermann B, Tumlinson AR, Esmaeelpour M, *et al.* Impact of enhanced resolution, speed and penetration on three-dimensional retinal optical coherence tomography. *Opt Express* 2009;17:4134-50.
48. Massamba N, Querques G, Lamory B, Querques L, Souied E, Soubrane G. *In vivo* evaluation of photoreceptor mosaic in type 2 idiopathic macular telangiectasia using adaptive optics. *Acta Ophthalmol* 2011;89:e601-3.
49. Ooto S, Hangai M, Takayama K, Arakawa N, Tsujikawa A, Koizumi H, *et al.* High-resolution photoreceptor imaging in idiopathic macular telangiectasia type 2 using adaptive optics scanning laser ophthalmoscopy. *Invest Ophthalmol Vis Sci* 2011;52:5541-50.
50. Powner MB, Gillies MC, Tretiaeh M, Scott A, Guymer RH, Hageman GS, *et al.* Perifoveal müller cell depletion in a case of macular telangiectasia type 2. *Ophthalmology* 2010;117:2407-16.
51. Powner MB, Gillies MC, Zhu M, Vevis K, Hunyor AP, Fruttiger M. Loss of Müller's cells and photoreceptors in macular telangiectasia type 2. *Ophthalmology* 2013;120:2344-52.
52. Shen W, Fruttiger M, Zhu L, Chung SH, Barnett NL, Kirk JK, *et al.* Conditional Müllercell ablation causes independent neuronal and vascular pathologies in a novel transgenic model. *J Neurosci* 2012;32:15715-27.
53. Eliassi-Rad B, Green WR. Histopathologic study of presumed parafoveal telangiectasis. *Retina* 1999;19:332-5.
54. Green WR, Quigley HA, De la Cruz Z, Cohen B. Parafoveal retinal telangiectasis. Light and electron microscopy studies. *Trans Ophthalmol Soc U K* 1980;100:162-70.
55. Gass JD. Müller cell cone, an overlooked part of the anatomy of the fovea centralis: Hypotheses concerning its role in the pathogenesis of macular hole and foveomacular retinoschisis. *Arch Ophthalmol* 1999;117:821-3.
56. Snodderly DM, Brown PK, Delori FC, Auran JD. The macular pigment. I. Absorbance spectra, localization, and discrimination from other yellow pigments in primate retinas. *Invest Ophthalmol Vis Sci* 1984;25:660-73.
57. Franze K, Grosche J, Skatchkov SN, Schinkinger S, Foja C, Schild D, *et al.* Müller cells are living optical fibers in the vertebrate retina. *Proc Natl Acad Sci U S A* 2007;104:8287-92.

**Cite this article as:** Wu L. Multimodality imaging in macular telangiectasia 2: A clue to its pathogenesis. *Indian J Ophthalmol* 2015;63:394-8.

**Source of Support:** Nil. **Conflict of Interest:** None declared.