

# Epicardial appendage ooze causing pericardial tamponade after left atrial appendage device implantation



Karen P. Phillips, MBBS, FHRS,\* Christopher Smith, MBBS,<sup>†</sup> Michelle Butler, MBBS,\* Anders Taylor, MBBS,\* Terri Hall, BSc, MBBS\*

From \*HeartCare Partners, GenesisCare, Brisbane, Queensland, Australia, and <sup>†</sup>Greenslopes Private Hospital, Brisbane, Queensland, Australia.

## Introduction

Pericardial tamponade is a serious complication of left atrial appendage (LAA) device occlusion reported in approximately 1%–3% of contemporary implant registries.<sup>1,2</sup> The root cause of most pericardial effusions within 7 days of the procedure has generally been determined to be cardiac perforation due to transeptal puncture or manipulation of delivery equipment or the closure device.<sup>3</sup> The cause of some pericardial effusions, however, has not been clearly defined.<sup>3</sup> This case outlines a novel etiology for delayed pericardial effusion and cardiac tamponade postimplant of the WATCHMAN LAA occlusion device (Boston Scientific, Natick, MA).

## Case report

An 84-year-old woman was referred for LAA device closure after recovery from a posterior inferior cerebellar artery–territory ischemic stroke. She had a history of paroxysmal nonvalvular atrial fibrillation with comorbidities of hypertension, morbid obesity, obstructive sleep apnea requiring continuous positive airway pressure treatment, and compensated cirrhosis of the liver. She had previously been withdrawn from oral anticoagulation in 2015 because of recurrent severe iron deficiency anemia and overt gastrointestinal bleeding from portal hypertensive gastropathy and bleeding hyperplastic polyps.

Informed consent was obtained from the patient for the procedure. She was initiated on warfarin and aspirin. The

international normalized ratio was 1.8 on the day of the implant procedure. The maximal LAA dimension was measured as 20 mm (range 15–20 mm) at the 135° angle on intraprocedural transesophageal echocardiographic (TEE) imaging. A 24-mm WATCHMAN device was implanted successfully in a chicken-wing LAA morphology under general anesthesia and TEE guidance. The procedure was technically straightforward, with a single device and single deployment required to achieve a good device position and stability with no peridevice leak (see [Figure 1](#)). The achieved device compression was 9%. The patient was in sinus rhythm, and protamine sulfate was administered to completely reverse heparin. No pericardial effusion was noted at the completion of the procedure, and the total procedure time was 60 minutes.

Five hours postprocedure, the patient was detected with severe hypotension (cuff blood pressure 50/30 mm Hg) on routine nursing observations. The assessment showed that she was bradycardic at 45 beats/min with warm peripheries, but on questioning she did have pericardial pain (described as left shoulder pain worsened with inspiration). An urgent echocardiogram showed a small pericardial effusion without tamponade features but with severe dynamic left ventricular outflow tract obstruction causing systolic anterior motion of the mitral valve and new moderately severe mitral regurgitation. She was judged to likely have had a vasovagal reaction to the pericardial pain, and fluid administration and vasopressor boluses (metaraminol) quickly improved her hemodynamics. Intravenous dopamine infusion was subsequently required to maintain her blood pressure. Serial echocardiographic reassessment showed enlargement of the pericardial effusion with eventual features of tamponade 11 hours postprocedure, and she underwent emergency pericardiocentesis. Three hundred milliliters of dark blood was aspirated from the pericardial space and a pigtail drain left in situ. The fluoroscopic appearances of the device appeared unchanged from those postimplant. She was transferred to the intensive care unit for further management. A decision was made not to reverse the warfarin effects initially on the basis of the

**KEYWORDS** Device occlusion; Left atrial appendage; Nonvalvular atrial fibrillation; Pericardial tamponade; WATCHMAN (Heart Rhythm Case Reports 2018;4:350–352)

This work was supported by Abbott Medical (formerly St. Jude Medical). Dr Phillips received consultancy fees and honoraria for presentation, clinical proctorship, and advisory board participation from Boston Scientific and St. Jude Medical. **Address reprint requests and correspondence:** Dr Karen P. Phillips, Ramsay Specialist Centre, Suite 212, Newdegate St, Greenslopes, Brisbane, QLD 4120, Australia. E-mail address: [kphillips@heartcarepartners.com.au](mailto:kphillips@heartcarepartners.com.au).

**KEY TEACHING POINTS**

- A sound understanding of the potential etiologies and time course of pericardial tamponade after left atrial appendage occlusion procedures is required to guide appropriate management.
- This case demonstrates the potential for micropoint bleeding from the epicardial surface of the left atrial appendage to cause subacute pericardial tamponade after device implantation.
- Considerations for the management of pericardial tamponade from micropoint left atrial appendage bleeding should include reversal of any anticoagulation and antiplatelet therapy and attention to elevation in left atrial pressure.

literature on the management of pericardial tamponade after catheter ablation for atrial fibrillation, indicating that it was probably not necessary in the majority of cases<sup>4</sup> and because the level was subtherapeutic.

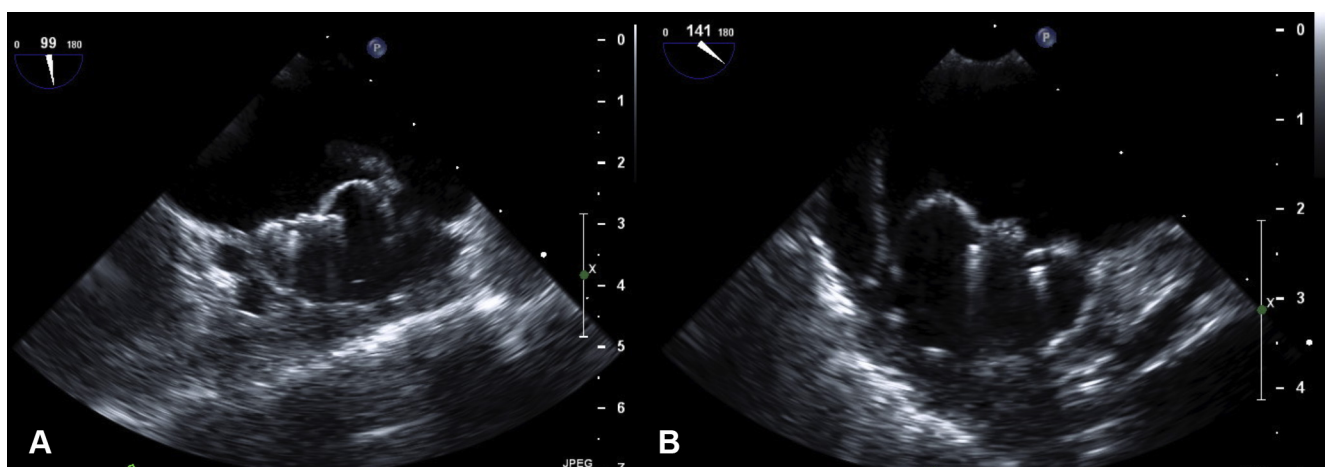
The following day the patient again became suddenly hypotensive and a repeat echocardiogram showed recurrent pericardial tamponade. It became apparent that the pericardial pigtail catheter had become occluded. The pericardial drain was unblocked and a further 250 mL of blood aspirated. Because of recurrent features of cardiogenic shock, a decision was made to proceed with surgical exploration to determine the cause of ongoing bleeding. Her warfarin was reversed with prothrombin complex concentrate immediately before surgery. Via median sternotomy the pericardial space and LAA surface were explored. A moderate amount of fresh blood was noted in the pericardium but no hematoma. On intraoperative TEE imaging, the device was still identified to be in the same position as immediately after the implant

procedure. The LAA surface and left atrium were carefully explored by palpation by the surgeon. There was no evidence for extrusion or penetration of WATCHMAN device struts or barbs on palpation. After suctioning the existing blood, no focal source of ongoing bleeding or cardiac perforation could be identified. The source of bleeding was determined to be the ooze around the base of the LAA. FLOSEAL Hemostatic Matrix (Baxter, Deerfield, IL) and Surgicel Fibrillar Absorbable Hemostat (Ethicon, Somerville, NJ) were applied to the LAA surface, and after a period of observation the chest closed with a pericardial drain.

The patient stabilized hemodynamically, with gradual recovery of an acute kidney injury and resolution of the dynamic left ventricular outflow tract obstruction and mitral regurgitation. Unfortunately she struggled with multifactorial respiratory failure after extubation on day 4 and required intermittent periods on bilevel noninvasive ventilation support to manage severe hypercapnia. She became progressively deconditioned and on day 14 requested withdrawal of active treatment and died peacefully within 24 hours.

**Discussion**

This is the first case report of subacute pericardial tamponade after LAA device closure being caused by acute micropoint bleeding and ooze from the epicardial surface of the LAA. The commonly accepted and well-documented cause of pericardial tamponade during LAA device occlusion is cardiac perforation from instrumentation of the left atrium or LAA (related to transseptal puncture or manipulation of device or delivery equipment in the left atrium or LAA).<sup>3</sup> Other reported causes include delayed cardiac or vascular perforation<sup>5,6</sup> due to penetration of device strut or fixation hooks. The tissue of the LAA is well-known for being fragile and extremely thin in parts.<sup>7</sup> This case appears to demonstrate that placement of a WATCHMAN device and engagement of the barbs into the tissue of the LAA can result in micropoint bleeding from the epicardial surface of the LAA that can lead



**Figure 1** Transesophageal echocardiographic images from the WATCHMAN implant at the end of the procedure at the  $\sim 99^\circ$  angle (A) and  $\sim 141^\circ$  angle (B) demonstrating satisfactory occlusion criteria.

to pericardial effusion and tamponade. The delayed onset of the effusion several hours postprocedure and the slow accumulation and reaccumulation of the effusion are significant observations relevant to the unique etiology in this case. Factors that increase left atrial pressure (or more particularly LAA pressure) postimplant might also affect the propensity for bleeding. The effect of the acute occlusion of the appendage orifice in sinus rhythm and the consequences of the left ventricular outflow tract obstruction and new mitral regurgitation in this case may have been factors in the rate of bleeding.

The role of combined anticoagulation (international normalized ratio 1.8) and aspirin likely contributed to the extent and duration of bleeding in this case. In particular, the authors believe that earlier reversal of warfarin may have avoided cardiac surgical exploration for this patient. Further consideration also needs to be given to the appropriate antithrombotic regimen that should be prescribed for patients undergoing LAA device closure who may already be at increased risk of bleeding complications.<sup>8</sup>

## Conclusion

This case expands our knowledge of the causes of pericardial tamponade after LAA device closure. Consideration should be given to reversal of anticoagulation and antiplatelets and persistent conservative management with pericardial percutaneous drainage before a decision to proceed with cardiac surgical exploration in select cases of delayed pericardial

effusion. The subacute timing of the effusion and the slow rate of accumulation of the effusion or ongoing bleeding may be clues to micropoint bleeding from the epicardial surface of the LAA.

## References

1. Boersma LV, Schmidt B, Betts TR, Sievert H, Tamburino C, Teiger E, Pokushalov E, Kische S, Schmitz T, Stein KM, Bergmann MW. Implant success and safety of left atrial appendage closure with the WATCHMAN device: periprocedural outcomes from the EWOLUTION registry. *Eur Heart J* 2016; 37:2465–2474.
2. Tzikas A, Shakir S, Gafoor S, et al. Left atrial appendage occlusion for stroke prevention in atrial fibrillation: multicentre experience with the AMPLATZER Cardiac Plug. *EuroIntervention* 2016;11:1170–1179.
3. Reddy VY, Holmes DR, Doshi SK, Neuzil P, Kar S. Safety of percutaneous left atrial appendage closure: results from the Watchman Left Atrial Appendage System for Embolic Protection in Patients With AF (PROTECT AF) clinical trial and the Continued Access Registry. *Circulation* 2011;123:417–424.
4. Latchamsetty R, Gautam S, Bhakta D, Chugh A, John RM, Epstein LM, Miller JM, Michaud GF, Oral H, Morady F, Jongnarangsin K. Management and outcomes of cardiac tamponade during atrial fibrillation ablation in the presence of therapeutic anticoagulation with warfarin. *Heart Rhythm* 2011;8:805–808.
5. Zwimer J, Bayer R, Hädrich C, Bollmann A, Klein N, Dreßler J, Ondruschka B. Pulmonary artery perforation and coronary air embolism—two fatal outcomes in percutaneous left atrial appendage occlusion. *Int J Legal Med* 2017;131:191–197.
6. Sepahpour A, Ng MK, Storey P, McGuire MA. Death from pulmonary artery erosion complicating implantation of percutaneous left atrial appendage occlusion device. *Heart Rhythm* 2013;10:1810–1811.
7. Beigel R, Wunderlich NC, Ho SY, Arsanjani R, Siegel RJ. The left atrial appendage: anatomy, function, and noninvasive evaluation. *JACC Cardiovasc Imaging* 2014;7:1251–1265.
8. Tung MK, Ramkumar S, Cameron JD, Pang B, Nerlekar N, Kotschet E, Alison J. Retrospective cohort study examining reduced intensity and duration of anticoagulant and antiplatelet therapy following left atrial appendage occlusion with the WATCHMAN device. *Heart Lung Circ* 2017;26:477–485.