



# Successful treatment of neurologic injury after complex spinal surgery with hyperbaric oxygen therapy: a case report

Connor T. A. Brenna<sup>1^</sup>, Shawn Khan<sup>2</sup>, Rita Katznelson<sup>3,4</sup>, Katherine Marseu<sup>3,4</sup>

<sup>1</sup>Department of Anesthesiology & Pain Medicine, University of Toronto, Toronto, ON, Canada; <sup>2</sup>Faculty of Medicine, University of Toronto, Toronto, ON, Canada; <sup>3</sup>Hyperbaric Medicine Unit, Toronto General Hospital, Toronto, ON, Canada; <sup>4</sup>Department of Anesthesia and Pain Management, Toronto General Hospital, University of Toronto, Toronto, ON, Canada

*Contributions:* (I) Conception and design: All authors; (II) Administrative support: K Marseu; (III) Provision of study materials or patients: R Katznelson, K Marseu; (IV) Collection and assembly of data: CTA Brenna, S Khan; (V) Data analysis and interpretation: CTA Brenna, S Khan; (VI) Manuscript writing: All authors; (VII) Final approval of manuscript: All authors.

*Correspondence to:* Katherine Marseu, MD, FRCPC. Department of Anesthesia and Pain Management, Toronto General Hospital, University of Toronto, Toronto, ON, Canada; Hyperbaric Medicine Unit, Toronto General Hospital, 200 Elizabeth Street, 3EN-464, Toronto, Ontario, Canada. Email: katherine.marseu@uhn.ca.

**Background:** Neurologic injury is relatively common in the context of spinal surgery, and is often treated with physiotherapy, pharmacotherapy, or surgical intervention. Emerging evidence supports a possible role for hyperbaric oxygen therapy (HBOT) in the treatment of peripheral and spinal nerve injuries. We describe the successful use of HBOT in improving neurologic recovery after complex spine surgery with new-onset postoperative unilateral foot drop.

**Case Description:** A 50-year-old woman was found to have new right-sided foot drop and L2-S1 motor deficits following complex thoracolumbar revision spinal surgery. She received standard conservative management for a provisional diagnosis of acute traumatic nerve ischemia, but demonstrated no neurologic improvement. On postoperative day four, after other avenues of treatment were exhausted, she was referred for HBOT. The patient received a total of twelve sessions of HBOT at 2.0 absolute atmospheres (ATA) of pressure, for 90 minutes (including two air breaks) per session, before transfer to a rehabilitation facility.

**Conclusions:** The patient displayed marked neurologic improvement after the first hyperbaric session, and further recovery thereafter. She concluded therapy with a significantly improved range of motion and lower limb power, ability to ambulate, and pain control. HBOT was associated with a rapid, sustained improvement when applied in this case as a salvage therapy for persistent postoperative neurologic deficit. Mounting evidence supports the consideration of hyperbaric therapy as a standard adjunct treatment for traumatic neurologic injury.

**Keywords:** Hyperbaric oxygen therapy (HBOT); traumatic nerve injury; neurologic deficit; spine surgery; case report

Submitted Jan 25, 2023. Accepted for publication Apr 25, 2023. Published online May 24, 2023.

doi: 10.21037/jss-23-12

View this article at: <https://dx.doi.org/10.21037/jss-23-12>

## Introduction

Neurologic injury is a recognized complication of spine surgery, with an incidence of approximately 1% across

a variety of spinal procedures (1,2). New neurologic deficits after surgery range from temporary paresthesiae to permanent quadriplegia (2), and these adverse events are associated with significant postoperative morbidity

<sup>^</sup> ORCID: 0000-0002-6126-3897.

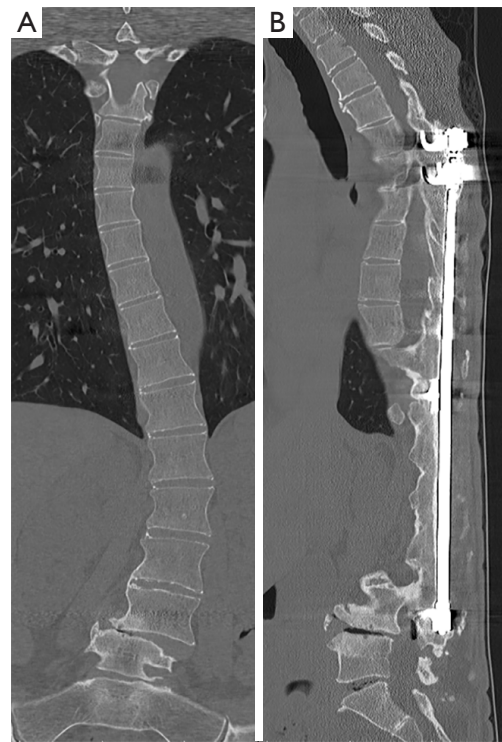and mortality (1). Patients suffering these complications will often receive imaging and electrophysiological studies to identify possible etiologies (3), followed by physiotherapeutic, pharmacologic, and/or surgical interventions with the aim of restoring nerve function (4,5).

Hyperbaric oxygen therapy (HBOT) is a treatment in which patients undergo serial exposures to supra-atmospheric ambient pressures of 100% oxygen within a hyperbaric chamber, to enhance the delivery of oxygen to tissues (6). There is growing evidence among recent animal and human studies to support the use of HBOT in treating neurologic injury (7-13). We present this case in accordance with the CARE reporting checklist (available at <https://jss.amegroups.com/article/view/10.21037/jss-23-12/rc>) (14).

### Case presentation

A 50-year-old woman with a history of scoliosis presented with progressive neurogenic claudication and pain related to T5-L4 spinal stenosis and L4-L5 degenerative spondylolisthesis. She had previously undergone scoliosis surgery 36 years prior, with a Harrington rod placed from T5-L4 (*Figure 1*). Given her worsening symptoms, she was consented for revision spinal surgery.

The complex operation encompassed removal of the Harrington rod, bilateral decompression of L2-S1,



**Figure 1** Preoperative computed tomography of the thoracic and lumbar spine. (A) Coronal and (B) sagittal computed tomography scans (in the bone window range of densities) obtained prior to the operation, demonstrating chronic scoliotic curvature, severe degenerative changes, and placement of the preexisting Harrington rod.

### Highlight box

#### Key findings

- A 50-year-old woman emerged from complex revision spine surgery with new unilateral foot drop and L2-S1 neurologic deficits. She underwent twelve cycles of HBOT beginning on postoperative day four, and experienced immediate neurologic improvement and sustained functional recovery.

#### What is known and what is new?

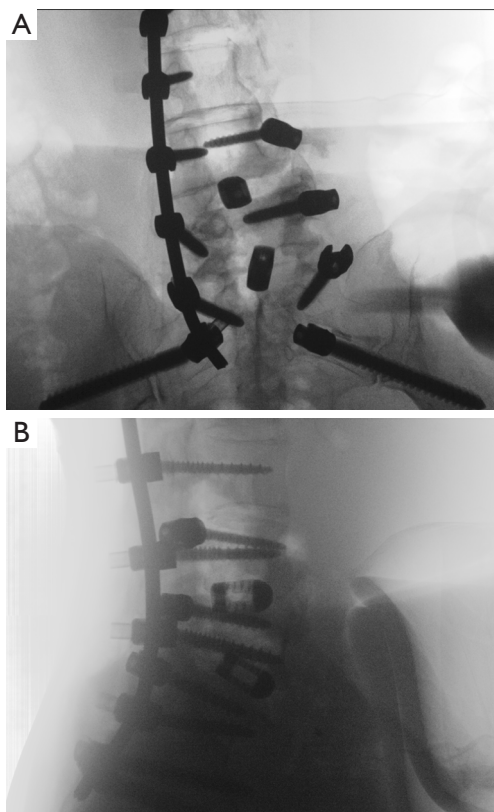
- HBOT has a good safety profile and appears promising in the salvage of ischemic nerve tissue.
- Animal model evidence supports the potential for HBOT to feature in the treatment of neurologic injury following spine surgery.
- The use of HBOT for human spinal cord injury, as in this report, has seldom been described.

#### What is the implication, and what should change now?

- HBOT should be considered in the management of unresolving postoperative neurological injury.
- Research into the mechanisms and role of HBOT in treating perioperative nerve injury is an ongoing research priority.

discectomy and posterior lumbar interbody fusion of L4-S1, osteotomy of L2-L4, and T5-sacrum instrument fusion. This was performed in the prone position under total intravenous anesthesia, with dedicated neurophysiological monitoring. The surgery was complicated by 3.5 liters of blood loss. The patient received five units of packed red blood cells, 750 milliliters of intraoperatively salvaged autologous blood, and 6 grams of fibrinogen. Her hemoglobin remained greater than 90 grams/liter on serial intraoperative measurements, and her blood pressure was maintained within 20% of her baseline throughout the operation with intravenous administrations of phenylephrine and ephedrine.

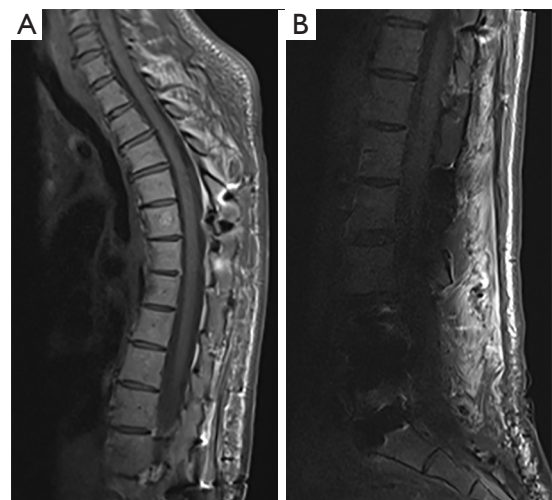
Six hours into the operation, an interbody cage was placed between the cleared L5 and S1 vertebral discs. Neuromonitoring revealed a sudden decrease in right-sided somatosensory evoked potentials (SSEPs) and motor evoked potentials (MEPs) in the tibialis anterior and



**Figure 2** Intraoperative O-arm cone-beam computed tomography of the lumbar spine. (A) Coronal and (B) sagittal cone-beam computed tomography scans obtained intraoperatively to confirm the correct placement of an L5-S1 interbody cage.

gastrocnemius regions, as well as a change in left-sided spontaneous potentials. The cage and relevant nerve roots were inspected both visually and radiographically (using intraoperative cone-beam computed tomography; *Figure 2*) and, without an identified cause for the persistent change in MEPs and SSEPs, the surgery was completed. The patient was awoken from general anesthesia and extubated in the operating room.

A postoperative neurological assessment revealed a new, right-sided foot drop. The patient underwent an MRI spine which ruled out thecal sac/cord compression and spinal hematoma (*Figure 3*). However, she experienced ongoing right leg weakness and was unable to significantly flex or extend her right foot or toes. The patient received inpatient physiotherapy for a provisional diagnosis of acute traumatic nerve injury, but experienced no improvement. On postoperative day (POD) four, she was referred to a tertiary hyperbaric medicine unit for consideration of HBOT ‘salvage

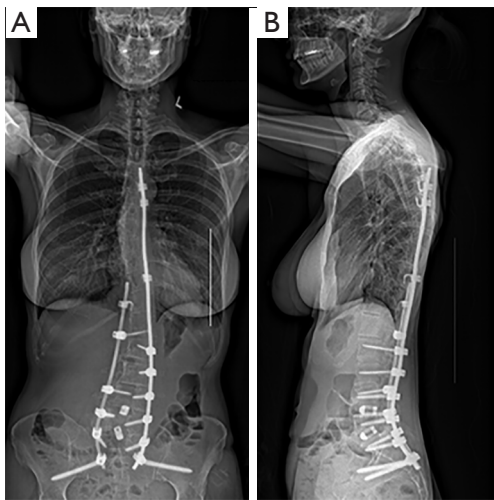


**Figure 3** Postoperative spinal magnetic resonance imaging. (A) Cervical/thoracic and (B) lumbar spine magnetic resonance imaging obtained immediately postoperatively, demonstrating no acute cord compression/spinal canal complication or hematoma within the limits of extensive hardware artifact.

therapy’ given the presumed etiology (acute traumatic ischemia) of her nerve paresis. The patient provided informed consent to proceed with a trial of HBOT and began daily inter-hospital transfers to facilitate this on POD 4.

Motor function in each extremity was graded prior to HBOT and after each session using the American Spinal Injury Association (ASIA) International Standards of Neurological Classification of Spinal Cord Injury (ISNCSCI) (15). The patient underwent twelve daily sessions of HBOT at a pressure of 2.0 absolute atmospheres (ATA), for 90-minutes, with two air-breaks. These were tolerated well without complication. Dramatic improvement of her right lower limb motor function was observed immediately after the first treatment, and continued over the course of HBOT. In addition to improved lower limb range of motion and power, the patient experienced improvement in both pain control and the ability to ambulate.

On POD 19, after the completion of twelve HBOT sessions, the patient was discharged to a rehabilitation facility. Continued daily transfer for HBOT was not possible, due to logistical complexity and the Covid-19 pandemic. All parties agreed that with the level of improvement observed, it was appropriate to stop hyperbaric treatments at this point. The patient underwent spinal rehab for 33 days and made further improvements



**Figure 4** Three-foot spine X-rays obtained seven months postoperatively. (A) Posterior-anterior and (B) lateral standing three-foot spine X-rays performed in follow-up seven months postoperatively, demonstrating stable vertebral alignment and hardware positioning. Mild mid-thoracic scoliosis (convex to right) and thoracolumbar scoliosis (convex to left) are unchanged from earlier postoperative films.

in mobility and functional independence, before she was ultimately discharged home. Surgical follow-up at seven months postoperatively demonstrated that the patient had grade five power on dorsiflexion and inversion, grade four on long toe extension and hip adduction, and grade three on long toe flexion and plantarflexion. A three-foot spine X-ray obtained at this follow-up demonstrated sustained improvement in vertebral alignment (*Figure 4*). At her final follow-up 2 years postoperatively, all muscle groups exhibited grade five power except for long toe extension on the right side, which remained diminished (scored as grade three).

All procedures performed in this study were in accordance with the ethical standards of the institutional and/or national research committee(s) and with the Helsinki Declaration (as revised in 2013). Written informed consent was obtained from the patient for publication of this case report and accompanying images. A copy of the written consent is available for review by the editorial office of this journal.

## Discussion

Neurologic injury during spine surgery can result from

direct transection of exposed spinal nerves or compression by either surgical instruments or expanding hematomas in the postoperative period (16-19). Indirectly, it can stem from nerve ischemia in the context of vascular compression, thrombosis, edema, or sustained hypotension (16,17,19,20). The incidence of iatrogenic spinal injury varies by type of surgery, with aortic and endovascular operations accounting for a majority of cases, and its natural history is heterogeneous with some of the poorest outcomes observed in the context of ischemic injuries of the thoracic spinal cord (21). Strategies for the management of iatrogenic cord injury have not yet reached consensus, although early radiologic evaluation to rule out reversible cord compression or misplaced instrumentation, aggressive blood pressure management to avoid secondary injury caused by hypotension, and rehabilitation are the current mainstays of evaluation and treatment (21,22).

HBOT is expected to improve ischemic neurologic injury by enhancing plasma and tissue concentrations of oxygen, which may spare the penumbra of an ischemic nerve, while also driving a cascade of protective biochemical changes (5). The circumstances of the presented case are suggestive of traumatic ischemia-reperfusion nerve injury during the operative course, contributing to a postoperative neurologic deficit and making it an appropriate target for HBOT. Additionally, it is worth considering that adhesions following the patient's prior, extensive spine operation almost four decades prior may have left the nerve roots in a state of increased vulnerability, especially to traction. There are few reports describing HBOT in the context of acute human neurologic injury, but there is a compelling mechanistic rationale for its use in the optimization of tissue healing: emerging work has identified functions of HBOT in reducing inflammation (23), reversing tissue hypoxia (24), activating stem cells (25), and inducing angiogenesis (26). While these mechanisms might explain a direct, restorative effect for injured nervous tissue, the efficacy of HBOT may also be mediated by its improvement of surgical wound edema arising after ischemia (5,20) and potentially contributing to nerve compression.

Animal studies have provided evidence in support of HBOT in the treatment of peripheral nerve injury and spinal cord injury (7,8,13). Similarly, there is emerging evidence for HBOT in treating human nerve injury (11,12), comprising various levels of evidence ranging from individual case reports to emerging meta-analyses. One case report describes rapid and sustained recovery from neurologic deficits following emergent thoracolumbar

decompression and fusion with five sessions of HBOT at 2.4–2.8 ATA (9), while another reports significant improvement in a professional football player who underwent thoracic decompression and fusion for a complete spinal cord injury with adjunct treatments of HBOT (30 sessions at 2.4 ATA) and omega-3 fatty acids (27). A small cohort of seven patients who underwent HBOT for spinal cord injury following complex aortic repair demonstrates complete recovery in two patients and partial recovery in three (10), and a recent systematic review by Naik and colleagues describes complete or nearly-complete neurologic recovery in six of a further eight patients receiving HBOT as an adjunct treatment for iatrogenic spinal injury (21). A randomized controlled trial published by Sun and colleagues reports significant neurologic improvement of acute spinal cord injury managed with HBOT in addition to conventional therapy, accompanied by a reduction of plasma inflammatory biomarkers high mobility group box 1 and nuclear factor kappa-B (28). Finally, a recent meta-analysis of this randomized controlled trial along with ten others evaluating neurologic outcomes of spinal cord injury after HBOT, published by Huang and colleagues, ascribes a positive effect on both motor and sensory recovery to HBOT, although the included trials are small (the total number of patients receiving HBOT was 442) and all were vulnerable to some form of experimental bias (29).

Taken together, this growing body of evidence supports a plausible role for HBOT helping to restore viable tissue and mitigate acute neurologic deficits following spinal surgery. However, there are only sparse reports of HBOT used in the context of human spinal cord injury, and very few describing its application in the treatment of iatrogenic injury to a spinal root in the context of complex spinal surgery. Several core limitations remain in the current state of clinical evidence for HBOT's application in the treatment of iatrogenic spinal injury, including a precise understanding of the therapeutic mechanisms accountable for its effectiveness. In addition, the optimal treatment protocols have yet to be elucidated, including the number of sessions, ambient treatment pressure, period of time after injury within which it should be initiated, and whether HBOT should be considered a first-line therapy (where available) or reserved as salvage therapy when traditional management for this phenomenon has been unsuccessful (13).

The present case illustrates an improvement of postoperative neurologic injury associated with HBOT. Because HBOT may be unfamiliar or difficult to access

in some centers, its potential for use in postoperative spinal cord dysfunction has not been widely recognized; consequently, in this case, it was suggested as a 'salvage therapy' after routine care had failed. The case is limited in its ability to attribute this improvement wholly to HBOT (versus natural progression of the patient's foot drop), although neurologic recovery bore a plausible/coherent, strong, and temporal relationship with the first hyperbaric exposure.

## Conclusions

The application of HBOT as an adjunct, 'salvage therapy' for postoperative neurologic injury following complex spine surgery is illustrated in this case. The present report adds to a small, growing body of literature suggesting that HBOT may hold promise in the restoration of damaged neural tissue. However, the mechanism by which HBOT may regenerate neurological deficits is not yet well-understood. Further inquiry into the effect of HBOT on both central and peripheral nerve injuries, and its possible role in their treatment, are critical research priorities.

## Acknowledgments

An earlier version of this case was presented at the Canadian Undersea and Hyperbaric Medical Association (CUHMA) annual meeting in November, 2021.

*Funding:* None.

## Footnote

*Reporting Checklist:* The authors have completed the CARE reporting checklist. Available at <https://jss.amegroups.com/article/view/10.21037/jss-23-12/rc>

*Peer Review File:* Available at <https://jss.amegroups.com/article/view/10.21037/jss-23-12/prf>

*Conflicts of Interest:* All authors have completed the ICMJE uniform disclosure form (available at <https://jss.amegroups.com/article/view/10.21037/jss-23-12/coif>). RK is a co-owner of Rouge Valley Hyperbaric Medical Center. The other authors have no conflicts of interest to declare.

*Ethical Statement:* The authors are accountable for all aspects of the work in ensuring that questions related to the accuracy or integrity of any part of the work are

appropriately investigated and resolved. All procedures performed in this study were in accordance with the ethical standards of the institutional and/or national research committee(s) and with the Helsinki Declaration (as revised in 2013). Written informed consent was obtained from the patient for publication of this case report and accompanying images. A copy of the written consent is available for review by the editorial office of this journal.

*Open Access Statement:* This is an Open Access article distributed in accordance with the Creative Commons Attribution-NonCommercial-NoDerivs 4.0 International License (CC BY-NC-ND 4.0), which permits the non-commercial replication and distribution of the article with the strict proviso that no changes or edits are made and the original work is properly cited (including links to both the formal publication through the relevant DOI and the license). See: <https://creativecommons.org/licenses/by-nc-nd/4.0/>.

## References

1. Thirumala P, Zhou J, Natarajan P, et al. Perioperative neurologic complications during spinal fusion surgery: incidence and trends. *Spine J* 2017;17:1611-24.
2. Hamilton DK, Smith JS, Sansur CA, et al. Rates of new neurological deficit associated with spine surgery based on 108,419 procedures: a report of the scoliosis research society morbidity and mortality committee. *Spine (Phila Pa 1976)* 2011;36:1218-28.
3. Goyal A, Wadgera N, Srivastava DN, et al. Imaging of traumatic peripheral nerve injuries. *J Clin Orthop Trauma* 2021;21:101510.
4. Lee SK, Wolfe SW. Peripheral nerve injury and repair. *J Am Acad Orthop Surg* 2000;8:243-52.
5. Sanchez EC. Hyperbaric oxygenation in peripheral nerve repair and regeneration. *Neurol Res* 2007;29:184-98.
6. Tibbles PM, Edelsberg JS. Hyperbaric-oxygen therapy. *N Engl J Med* 1996;334:1642-8.
7. Bajrović FF, Sketelj J, Jug M, et al. The effect of hyperbaric oxygen treatment on early regeneration of sensory axons after nerve crush in the rat. *J Peripher Nerv Syst* 2002;7:141-8.
8. Topuz K, Colak A, Cemil B, et al. Combined hyperbaric oxygen and hypothermia treatment on oxidative stress parameters after spinal cord injury: an experimental study. *Arch Med Res* 2010;41:506-12.
9. Wilson JRF, Schiavo S, Middleton WJ, et al. The Treatment of Perioperative Spinal Cord Injury With Hyperbaric Oxygen Therapy: A Case Report. *Spine (Phila Pa 1976)* 2020;45:E1127-31.
10. Parotto M, Ouzounian M, Fedorko L, et al. Hyperbaric oxygen therapy for spinal cord ischaemia after complex aortic repair - a retrospective review. *Anaesthesiol Intensive Ther* 2018;50:103-9.
11. Ince B, Ismayilzada M, Arslan A, et al. Does hyperbaric oxygen therapy facilitate peripheral nerve recovery in upper extremity injuries? A prospective study of 74 patients. *Eur J Trauma Emerg Surg* 2022;48:3997-4003.
12. Akan S, Temel C, Yilmaz O, et al. Hyperbaric oxygen therapy in peroneal nerve damage due to lithotomy position. *Ann Med Res* 2019;26:1714-6.
13. Brenna CTA, Khan S, Katznelson R, et al. The role of hyperbaric oxygen therapy in the management of perioperative peripheral nerve injury: a scoping review of the literature. *Reg Anesth Pain Med* 2022;rapm-2022-104113.
14. Gagnier JJ, Kienle G, Altman DG, et al. The CARE Guidelines: Consensus-based Clinical Case Reporting Guideline Development. *Glob Adv Health Med* 2013;2:38-43.
15. American Spinal Injury Association. International Standards for Neurological Classification of SCI (ISNCSCI). 2019.
16. Ghobrial GM, Williams KA Jr, Arnold P, et al. Iatrogenic neurologic deficit after lumbar spine surgery: A review. *Clin Neurol Neurosurg* 2015;139:76-80.
17. Garreau de Loubresse C. Neurological risks in scheduled spinal surgery. *Orthop Traumatol Surg Res* 2014;100:S85-90.
18. Glotzbecker MP, Bono CM, Wood KB, et al. Postoperative spinal epidural hematoma: a systematic review. *Spine (Phila Pa 1976)* 2010;35:E413-20.
19. Cramer DE, Maher PC, Pettigrew DB, et al. Major neurologic deficit immediately after adult spinal surgery: incidence and etiology over 10 years at a single training institution. *J Spinal Disord Tech* 2009;22:565-70.
20. Nylander G, Lewis D, Nordström H, et al. Reduction of postischemic edema with hyperbaric oxygen. *Plast Reconstr Surg* 1985;76:596-603.
21. Naik A, Moawad CM, Houser SL, et al. Iatrogenic spinal cord ischemia: A patient level meta-analysis of 74 case reports and series. *N Am Spine Soc J* 2021;8:100080.
22. Daniels AH, Hart RA, Hilibrand AS, et al. Iatrogenic Spinal Cord Injury Resulting From Cervical Spine Surgery. *Global Spine J* 2017;7:84S-90S.
23. Wilson HD, Wilson JR, Fuchs PN. Hyperbaric oxygen treatment decreases inflammation and mechanical

- hypersensitivity in an animal model of inflammatory pain. *Brain Res* 2006;1098:126-8.
24. Choudhury R. Hypoxia and hyperbaric oxygen therapy: a review. *Int J Gen Med* 2018;11:431-42.
  25. Shandley S, Wolf EG, Schubert-Kappan CM, et al. Increased circulating stem cells and better cognitive performance in traumatic brain injury subjects following hyperbaric oxygen therapy. *Undersea Hyperb Med* 2017;44:257-69.
  26. Tal S, Hadanny A, Sasson E, et al. Hyperbaric Oxygen Therapy Can Induce Angiogenesis and Regeneration of Nerve Fibers in Traumatic Brain Injury Patients. *Front Hum Neurosci* 2017;11:508.
  27. Maroon JC, Faramand A, Agarwal N, et al. Management of thoracic spinal cord injury in a professional American football athlete: illustrative case. *J Neurosurg Case Lessons* 2021;2:CASE21206.
  28. Sun L, Zhao L, Li P, et al. Effect of hyperbaric oxygen therapy on HMGB1/NF- $\kappa$ B expression and prognosis of acute spinal cord injury: A randomized clinical trial. *Neurosci Lett* 2019;692:47-52.
  29. Huang L, Zhang Q, Fu C, et al. Effects of hyperbaric oxygen therapy on patients with spinal cord injury: A systematic review and meta-analysis of Randomized Controlled Trials. *J Back Musculoskeletal Rehabil* 2021;34:905-13.

**Cite this article as:** Brenna CTA, Khan S, Katznelson R, Marseu K. Successful treatment of neurologic injury after complex spinal surgery with hyperbaric oxygen therapy: a case report. *J Spine Surg* 2023;9(2):209-215. doi: 10.21037/jss-23-12