

## Research Paper

# Bone Inflammation, Bone Infection and Dental Implants Failure: Histological and Cytological Aspects Related to Cement Excess

Marco Tatullo<sup>1</sup>✉, Massimo Marrelli<sup>2</sup>, Filiberto Mastrangelo<sup>3</sup>, Enrico Gherlone<sup>3</sup>

1. Biomedical Section, Tecnologica Research Institute, Crotone, Italy.
2. Maxillofacial Unit, Calabrodental clinic, Crotone, Italy.
3. Department of Oral Science, "Vita e Salute" San Raffaele University, Milan, Italy.

✉ Corresponding author: Marco Tatullo, Scientific Director. Tecnologica Research Institute, Biomedical Section, St. E. Fermi - 88900 Crotone, Italy. Phone/Fax: 0039-3498742445 / 0039-0962930414. Email:marco.tatullo@tecnologicasrl.com.

© Ivyspring International Publisher. This is an open access article distributed under the terms of the Creative Commons Attribution (CC BY-NC) license (<https://creativecommons.org/licenses/by-nc/4.0/>). See <http://ivyspring.com/terms> for full terms and conditions.

Published: 2017.01.17

## Abstract

**Background:** Dental implant failure can recognize several causes and many of them are quite preventable with the right knowledge of some clinical critical factors. Aim of this paper is to investigate about the histological aspects related to dental implants failure in such cases related to cement excess, how such histological picture can increase the risk of bacterial infections and how the different type of cement can interact with osteoblasts in-vitro.

**Methods:** We randomly selected 5 patients with a diagnosis of dental implant failure requiring to be surgically removed: in all patients was observed an excess of dental cement around the failed implants. Histological investigations were performed of the perimplant bone. Cell culture of purchased human Osteoblasts was performed in order to evaluate cell proliferation and cell morphology at 3 time points among 3 cement types and a control surface.

**Results:** Dental cement has been related to a pathognomonic histological picture with a foreign body reaction and many areas with black particles inside macrophage cells. Finally, cell culture on different dental cements resulted in a lower osteoblasts survival rate.

**Conclusions:** It is appropriate that the dentist puts a small amount of dental cement in the prosthetic crown, so to avoid the clinical alterations related to the excess of cement.

Key words: implant failure, osteoblasts, osseointegration.

## Introduction

Dental implantology is commonly considered the best treatment for tooth replacement. Several studies have been carried out on biological and mechanical factors related to osseointegration and survival of dental implants.<sup>1</sup>

Nowadays, patients prefer to have a fixed implant-supported prosthesis, in fact, this clinical solution is able to ensure a good aesthetics and a greater comfort in comparison with removable prosthesis; moreover, it's widely reported in the scientific literature that implant prostheses show long

lasting clinical outcomes.<sup>2</sup>

Despite implantology is rapidly developing and many surgical protocols are constantly improving, many potential complications might compromise the overtime stability of dental implants: premature implant failures are mainly related to bacterial infections, even if such adverse outcomes are the result of many co-factors, moreover, the presence of fixtures and other foreign bodies can lead to a local inflammation that could increase the risk of bacterial infections.<sup>3,4</sup>

Implant cementation as a means of attaching the coronal restoration to the implant fixture is a well-known protocol and widely used by prosthodontists. The advantages of this protocol are related to the good esthetics, to the passivity of fit and to the lower complexity of this protocol. Among the few disadvantages, is common to find an excess of dental cement around the implant site: this clinical situation is usually resolved with a mechanical removal of cement excess, but it's not unusual to find this foreign material under the gingival tissue, often associated to a marked tissue inflammation and to the formation of gingival pockets.<sup>5</sup>

Aim of this paper is to describe the histological aspects related to dental implants failure due to cement excess and if such histological picture can increase the risk of bacterial infections; moreover, we will investigate about the behaviour of human osteoblasts cultured on substrates coated with different cements.

## Material and Methods

We randomly selected from our database at Calabrodental clinic the most recent cases of patients with a diagnosis of dental implant failure, requiring to undergo to implant surgery. We only included healthy male patients (n=5), with a mean age of 54±8, who reported implant failure after a prosthetic restoration with cemented crowns. Only cement-retained prostheses on implants have been selected. The study was conducted in compliance with the "Ethical principles for medical research involving human subjects" of Helsinki Declaration. The study was conducted in accordance with Italian laws and regulations. Calabrodental ethics committee specifically approved this study (CBD2016-01). Patients gave their informed consent to use their data and histological images.

Dental implants located in periodontally compromised sites were surgically removed only after having tried every attempt finalized to obtain the implant survival. Patients gave their informed consent to the planned surgical procedures, furthermore they gave the written availability to reuse the histological pictures of their case for research purposes.

The histological samples of peri-implant bone tissue were stored in Formaline and analyzed in a private histology laboratory.

### Sample fixation

Samples were fixed in 10% Formalin solution, neutral buffered for 48h.

## Bone demineralization

Demineralization of bone tissue was performed by using Formic Acid and Sodium Citrate mixed together and added with distilled water. Our protocol needs 2 weeks to properly demineralize bone tissue; after this time, 2 more days are necessary to dehydrate tissues with alcoholic solutions and 1 more day is necessary to include the samples in Paraffin.

## Tissues staining

Hematoxylin-Eosin staining was used to analyze the harvested samples.

## Specimens

With the aim to evaluate cell behavior on 3 different cement types, we selected 3 glass-ionomer cements for this purpose: two among the most used glass-ionomer cements were termed "A" and "B", while a resin modified glass-ionomer cement was termed "C". Tissue culture plate (TCP) was assumed to be the control for these in-vitro experiments. Specimens were created in lab, under GLP conditions, in agreement with the manufacturer's suggestions.

## Cell culture

Human osteoblasts (hOBs) and osteoblast medium (ObM) were purchased from ScienCell Research Laboratories (San Diego, CA, USA). hOBs were plated and incubated at 37°C with 5% CO<sub>2</sub>.

## Cell Proliferation

Selected specimens were investigated with cell proliferation assay. We directly put 50\*10<sup>3</sup> hOBs on 6-well plates with a growth area 9.5cm<sup>2</sup>: 3 specimens were placed in 3 different wells filled with ObM, instead 1 well was empty and was marked as control. Cell counting was performed at day 1, day 3 and day 5. Cell proliferation assays were performed in triplicate.

Results were evaluated as the mean±Standard Deviation. One-way analysis of variance (ANOVA) and by Student's t-test were considered reliable to find statistical significance. P values less than 0.05 were considered as statistically significant (\*).

## Results

### Histological results

The histological slices obtained from samples were analyzed by hematoxylin-eosin staining. Inside the histological picture, have been detected hyperchromic areas, with several polymorphic fragments of exogenous materials that showed a tending to black pigmentation. These black fragments were identified as particles left from the excess cement and scattered throughout the fibrous stroma (**Figure**

1). Such areas were infiltrated by inflammatory cells and multinucleated giant cells, describing both an acute immediate as well as a delayed tissue reaction. Furthermore, it has been described a linear inflammatory infiltrate along the inner mucosal surface surrounding fibrous tissue, containing residual necrotic bone (**Figure 2**). The pathological picture matched with a diagnosis of acute together with chronic inflammatory infiltrate, containing rich areas of exogenous material likely to be cement particles. Energy dispersive X-ray spectroscopy (EDX) analysis was also conducted and it confirmed that the acellular material was cement particles. The histological diagnosis was granulomatous reaction caused by foreign body. Such particles could carry inside them bacteria aggregate able to induce a strong inflammatory reaction and, consequently, a stronger reaction to such foreign bodies.

### Cell proliferation assay results

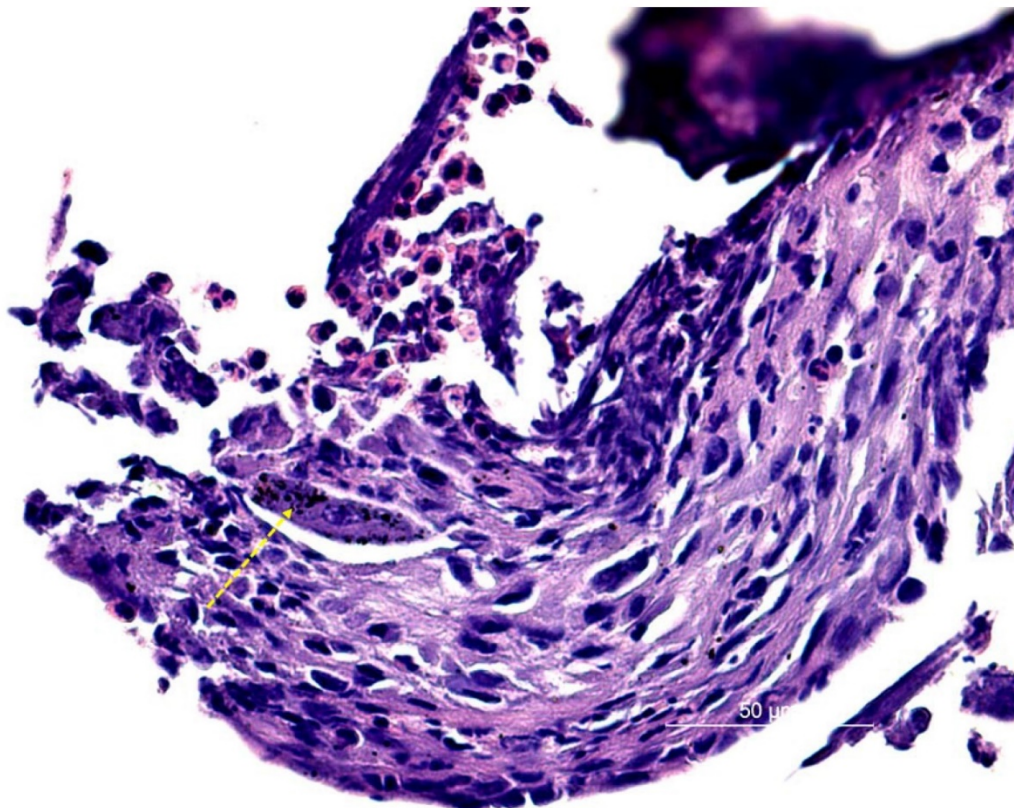
Cell Proliferation assay has highlighted that while hOBs cultured on TCPs showed a growing curve from day1 to day5, conversely, all the tested specimens reported data at day3 and day5 which confirmed the negative proliferation rate of all the

hOBs cultured on such tested specimens. Specifically, "A" specimen and "B" specimen showed a more marked trend to preserve the cell survival in the early stage of cell culturing, on the other side, "C" specimen demonstrated a slightly less ability to maintain over time the cell viability (**Figure 3**). Cell morphology was maintained definitely unchanged from day1 to day5, as showed in figure 3.

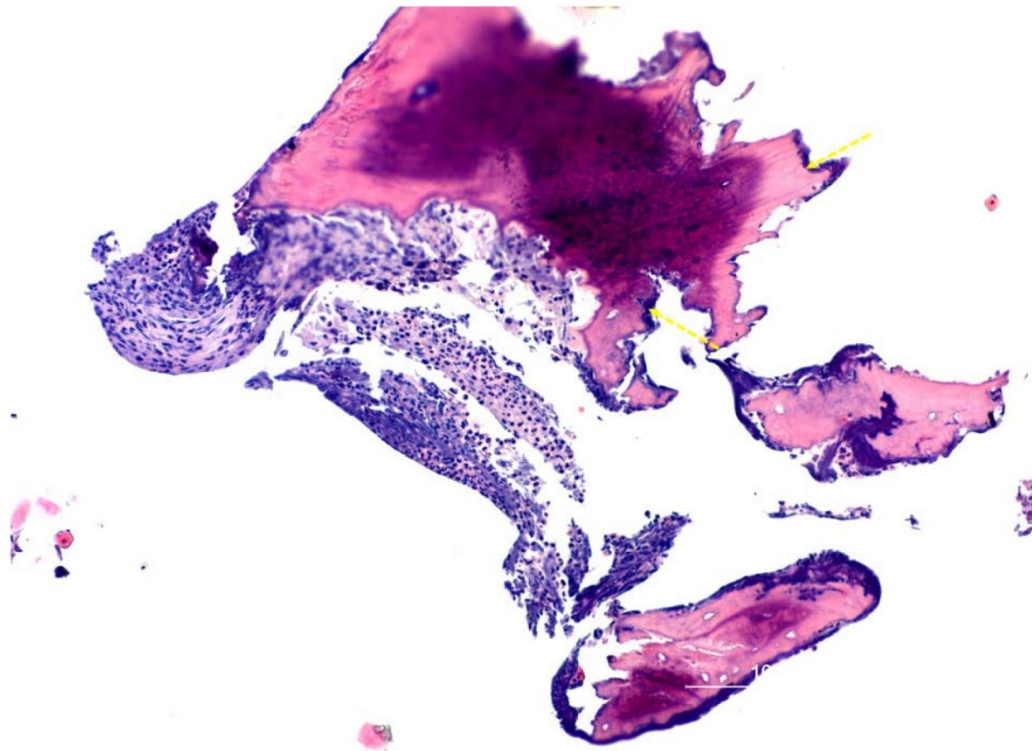
The overall assessment of these in-vitro data is that the samples are made from biomaterials that have demonstrated a low affinity with the cell viability, and this could preliminarily justify why a cement excess is able to induce a so severe inflammatory response and a so scarce reparatory reaction by the surrounding tissues.

### Discussion

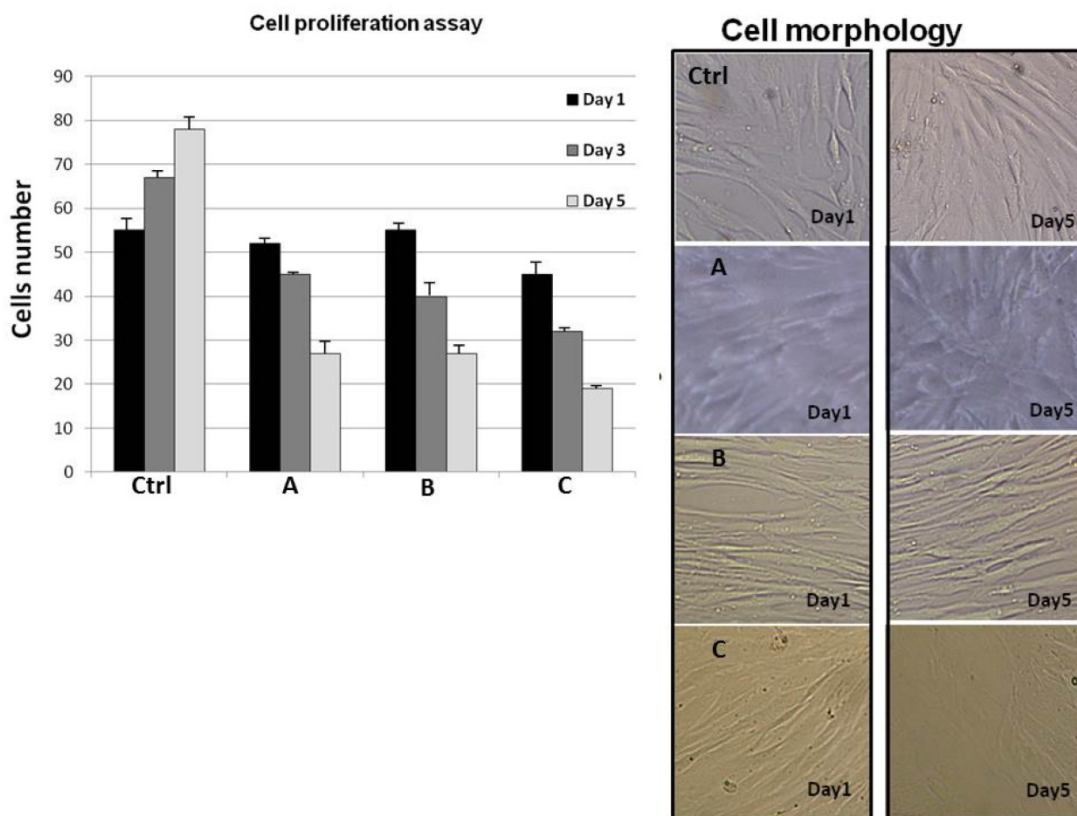
The ever growing quality of dental implants osseointegration has made the implant-supported dental prostheses the golden choice in the treatment of a partial or total tooth loss.<sup>6</sup> Cemented implant prostheses are widely used by prosthodontists and the performance of such prosthetic rehabilitations are widely studied and reported in the literature.<sup>7</sup>



**Figure 1:** Intratissutal and intracellular accumulation of hyperchromic particles representing multiple foci of exogenous cement (see the arrow). Surrounding stroma is infiltrated by acute and chronic inflammatory cells.



**Figure 2:** Hematoxylin and eosin-stained section at the bone interface: we can see inflammatory infiltrate and wide portions of residual necrotic bone (see the arrows).



**Figure 3:** Cell proliferation assay. Human Osteoblasts were placed into Osteoblasts Medium in 4 wells and each of the specimens in 3 different wells, while 1 well was leaved empty and was marked as control. Cell count was performed at day 1, day 3 and day 5. Cell proliferation assays were performed in triplicate. Cell morphology. Human Osteoblasts were cultured on 3 glass-ionomer cements to assess if the cell phenotype was different between day1 and day5 time point: the used glass-ionomer cements were named A, B and C. Control was assumed to be the tissue culture plate.

Implant failures can be related to several different causes. Literature reports early implant failures when the implant load is premature, or after the application of an excessive load without to wait the right bone formation. After achieving a good implant osseointegration, the common causes of implant failure are related to different and synergic factors, furthermore, some important causes are to relate to systemic diseases, cigarette smoking, bruxism, low levels of patient compliance or idiopathic causes. Among all, the most reported and well documented cause of implant failure is related to mechanical and microbiological factors.<sup>8-10</sup> Gatti *et al.* marked out the criteria according to which clinicians can distinguish two different types of perimplantitis.<sup>11</sup> According to these criteria, high plaque index, presence of dental pockets, progressive bone loss starting from the marginal portion of the implant with simultaneous epithelial growth, tissues suppuration, presence of numerous polymorphonucleated cells and plasma cells prevalence, may be indicative of a bacteria sustained perimplantitis. The presence of tooth mobility, low plaque index, pain or pressure sensitivity, absence of infection signs, absence of significant marginal bone loss, granulating tissue surrounding the whole implant, prevalence of macrophages at the level of the new formed fibrous tissue, are instead, indicative of a critical situation near to the implant failure.<sup>12</sup>

Cemented implants are used to be subjected to cementation step that often lead to a variable amount of cement retained between the prosthetic crown and the biological surrounding tissues.<sup>13</sup> The ability of the dentist is related to the right dosage of cement inside the crown, in order to avoid an excess that could be displaced in the most deep perimplant spaces, where is of course more difficult to remove it with manual instruments or professional hygiene.<sup>14</sup> Moreover, the quality of the design and application of dental prosthesis is also important to reduce the cement related problems: in fact, cement-retained implants with marginal misfit were associated with an early crestal bone loss than accurately fitted crowns after a mean of 3 years in function.<sup>15</sup>

In our study it was stressed out the biological role of cements which showed a bad influence on cell viability: this result is quite confirmed by the literature, where a number of studies focused on the in vitro cytotoxicity of glass ionomer cements have highlighted how many commonly used cements can influence the local cell behaviour.<sup>16</sup>

Moreover, it's not secondary the role played by dental cement in creating the right environment able to host the bacterial growth. In fact, although the scientific literature has demonstrated the slight

antibacterial activity of many glass-ionomer cements<sup>17,18</sup>, it's also remarkable that such antibacterial activity is time-dependent and that in the long period the cement excess represents a material with several niches where to find bacterial aggregates able to start a local infection. Within the physiological variability among different patients, the scientific literature has widely reported that the dental cements are easily contaminated by several bacteria largely present in the oral microbioma. The most represented bacteria are the *Streptococcus*, particularly *Streptococcus sanguinis* and *mutans*, *Porphyromonas gengivalis*, *Prevotella* and *Actinomyces*: the presence of such bacteria is typically related to gingival diseases and low implant-survival.

Studies on this topic have highlighted how *Treponema forsythia* and *Treponema denticola* showed an increased abundance in the presence of excess cement compared to patients without excess cement.<sup>19</sup>

Furthermore, literature has reported many cases where the clinical pictures of perimplantitis were associated with histological pictures showing inflammation and oxidative stress leading to mucositis and perimplantitis, with serious concerns about the role of such procedure in relation to the implant survival rate.<sup>4,20,21</sup> Finally, other general health *noxae* could be a *primum movens* for implant failure, as reported in the literature.<sup>22,23</sup>

In the cases previously reported, it has been demonstrated that the inflammatory response is linked to a foreign body reaction, thus, the removal of any excess cement at the crown restoration cannot be underestimated. In vitro models have shown the difficulty of a proper control of cement removal: the radiological investigation allows a non-invasive assessment of the site with the possibility of identifying the excess cement, but the visibility depends on the type of cement used.

## Conclusions

In the literature, have already been described cases of implant failures caused by the excessive presence of dental cement; histologically, this clinical condition is associated with the presence of a strong inflammation by foreign body, with the presence of black areas caused by an accumulation of exogenous material. Foreign bodies are likely to be carriers for bacteria which certainly will increase the local inflammation around the implants. Finally, it was shown that the dental cement leads to a lower survival of osteoblasts. In this light, it is appropriate that the dentist puts a small amount of dental cement during the prosthesis insertion, moreover, it is appropriate to remove cement excess around the implant compounds. Given that the literature has

correlated the cement excess with flogosis episodes of soft tissues around the cement-retained prosthesis, in the recent years many techniques have been developed to reduce the use of cement without reducing the efficacy of its use. This article is a further confirmation that such prosthetic stage should be performed with attention and with high precision so to avoid to compromise the entire prosthetic rehabilitation.

## Competing Interests

The authors have declared that no competing interest exists.

## References

- Mahato N, Wu X, Wang L. Management of peri-implantitis: a systematic review, 2010-2015. *Springerplus*. 2016;5:105.
- Marrelli M, Falisi G, Apicella A, Apicella D, Amantea M, Cielo A, Bonanome L, Palmieri F, Santacroce L, Giannini S, Di Fabrizio E, Rastelli C, Gargari M, Cuda G, Paduano F, Tatullo M. Behaviour of dental pulp stem cells on different types of innovative mesoporous and nanoporous silicon scaffolds with different functionalizations of the surfaces. *J Biol Regul Homeost Agents*. 2015;29:991-997.
- Baqain ZH, Moqbel WY, Sawair FA. Early dental implant failure: risk factors. *Br J Oral Maxillofac Surg*. 2012;50(3):239-243.
- Inchingolo F, Tatullo M, Abenavoli FM, Marrelli M, Inchingolo AD, Palladino A, Inchingolo AM, Dipalma G. Oral piercing and oral diseases: a short time retrospective study. *Int J Med Sci*. 2011;8(8):649-652.
- Pontoriero R, Tonelli MP, Carnevale G, Mombelli A, Nyman SR, Lang NP. Experimentally induced perimplant mucositis. A clinical study in humans. *Clin Oral Implants Res*. 1994;5:254-259.
- Watzek G. Oral implants--quo vadis? *Int J Oral Maxillofac Implants*. 2006;21(6):831-832.
- Monje A, Galindo-Moreno P, Tözüm TF, Suárez-López Del Amo F, Wang HL. Into the Paradigm of Local Factors as Contributors for Peri-implant Disease: Short Communication. *Int J Oral Maxillofac Implants*. 2016;31(2):288-292.
- Esposito M, Hirsch JM, Lekholm U, Thomsen P. Biological factors contributing to failures of osseointegrated oral implants. (I). Success criteria and epidemiology. *Eur J Oral Sci*. 1998;106:527-551.
- Snider TN, Cottrell D, Batal H. Summary of current consensus on the effect of smoking on implant therapy. *J Mass Dent Soc*. 2011;59(4):20-22.
- Yeung SC. Biological basis for soft tissue management in implant dentistry. *Aust Dent J*. 2008;53 Suppl 1:S39-42.
- Gatti C, Gatti F, Chiapasco M, Esposito M. Outcome of dental implants in partially edentulous patients with and without a history of periodontitis: a 5-year interim analysis of a cohort study. *Eur J Oral Implantol*. 2008;1(1):45-51.
- Froum SJ, Rosen PS. A proposed classification for peri-implantitis. *Int J Periodontics Restorative Dent*. 2012;32(5):533-540.
- Korsch M, Obst U, Walther W. Cement-associated peri-implantitis: a retrospective clinical observational study of fixed implant-supported restorations using a methacrylate cement. *Clin Oral Implants Res*. 2014;25(7):797-802.
- Korsch M, Robra BP, Walther W. Predictors of excess cement and tissue response to fixed implant-supported dentures after cementation. *Clin Implant Dent Relat Res*. 2015;17 Suppl 1:e45-53.
- Chen CJ, Papaspyridakos P, Guze K, Singh M, Weber HP, Gallucci GO. Effect of misfit of cement-retained implant single crowns on crestal bone changes. *Int J Prosthodont*. 2013;26(2):135-137.
- Selimović-Dragaš M, Huseinbegović A, Kobašlija S, Hatibović-Kofman S. A comparison of the in vitro cytotoxicity of conventional and resin modified glass ionomer cements. *Bosn J Basic Med Sci*. 2012;12(4): 273-278.
- Marrelli M, Tatullo M, Dipalma G, Inchingolo F. Oral infection by *Staphylococcus aureus* in patients affected by White Sponge Nevus: a description of two cases occurred in the same family. *Int J Med Sci*. 2012;9(1):47-50.
- Friedl KH, Schmalz G, Hiller KA, Shams M. Resin-modified glass ionomer cements: fluoride release and influence on *Streptococcus mutans* growth. *Eur J Oral Sci*. 1997;105(1):81-85.
- Socransky SS, Haffajee AD. Periodontal microbial ecology. *Periodontol 2000*. 2005;38:135-187.
- Korsch M, Robra BP, Walther W. Cement-associated signs of inflammation: retrospective analysis of the effect of excess cement on peri-implant tissue. *Int J Prosthodont*. 2015;28(1):11-18.
- Inchingolo F, Marrelli M, Annibaldi S, Cristalli MP, Dipalma G, Inchingolo AD, Palladino A, Inchingolo AM, Gargari M, Tatullo M. Influence of endodontic treatment on systemic oxidative stress. *Int J Med Sci*. 2013;11(1):1-6.
- Annibaldi S, Pranno N, Cristalli MP, La Monaca G, Polimeni A. Survival Analysis of Implant in Patients With Diabetes Mellitus: A Systematic Review. *Implant Dent*. 2016;25(5):663-674.
- Baj A, Lo Muzio L, Lauritano D, Candotto V, Mancini GE, Gianni AB. Success of immediate versus standard loaded implants: a short literature review. *J Biol Regul Homeost Agents*. 2016;30(2):183-188.