



Blastic natural killer cell lymphoma/leukaemia in a cat

Miyuki Hirabayashi¹, James K Chambers¹,
 Mei Sugawara², Aki Ohmi², Hajime Tsujimoto³,
 Hiroyuki Nakayama^{1,2} and Kazuyuki Uchida¹

Journal of Feline Medicine and Surgery Open Reports
 1–8

© The Author(s) 2019

Article reuse guidelines:

sagepub.com/journals-permissions

DOI: 10.1177/2055116919863080

journals.sagepub.com/home/jfmsopenreports

This paper was handled and processed by the European Editorial Office (ISFM) for publication in *JFMS Open Reports*



Abstract

Case summary A 7-year-old mixed-breed cat presented with subcutaneous oedema and erythema extending from the right axilla to the abdomen. Fine-needle aspiration of the subcutaneous lesion revealed large, atypical, round cells. A clonality analysis for the T-cell receptor-gamma and immunoglobulin heavy chain genes showed no clonal rearrangement. The presumed diagnosis was lymphoma and the cat was treated with prednisolone and L-asparaginase but died 78 days after initial treatment. At necropsy, an oedematous subcutaneous mass in the right axilla, hepatomegaly, splenomegaly and lymphadenopathy of the mediastinum and left axilla were observed. Histopathological examination revealed diffuse infiltration of large atypical round cells in the subcutaneous mass, liver, spleen, lymph nodes and bone marrow. Immunohistochemically, the tumour cells were strongly positive for CD56, and negative for CD3, CD20, CD79a, CD57, granzyme B and perforin. Based on these findings, the cat was diagnosed with blastic natural killer (NK) cell lymphoma/leukaemia.

Relevance and novel information Here, we report the pathological and clinical findings of NK cell lymphoma/leukaemia in a cat. The antibody for human CD56, a diagnostic marker for human NK cell neoplasms, showed cross-reactivity with feline CD56 by immunohistochemistry and Western blotting analysis. The antibody could be a useful diagnostic marker for feline NK cell neoplasms.

Keywords: NK cell lymphoma/leukaemia; CD56

Accepted: 19 June 2019

Introduction

Natural killer (NK) cell neoplasms are rare both in humans and in animals. In humans and rodents, NK cells have been characterised by the expression of CD56 and the absence of surface CD3 and T-cell receptor (TCR). NK cells arise from the same lymphocyte precursor cell as T cells and B cells. NK progenitor cells express CD34 and CD10, as well as other myeloid and lymphoid progenitor cells. Immature NK cells express CD56 and lack CD34 and CD10 expression, and eventually express CD16 and CD57 during maturation. CD56, CD16 and CD57 are used as markers for diagnosing NK cell neoplasms in humans.^{1–4}

In animals, there have been a few studies on the immunophenotypes and functions of NK cells.^{5–7} In dogs and cats, NK cells are negative for surface CD3 by flow

cytometry,^{7–9} but an antibody that specifically labels surface CD3 is not available for immunohistochemistry on formalin-fixed paraffin embedded sections. Therefore, NK cell neoplasms have been diagnosed tentatively in

¹Laboratory of Veterinary Pathology, Graduate School of Agricultural and Life Sciences, University of Tokyo, Tokyo, Japan

²Veterinary Medical Center, Graduate School of Agricultural and Life Sciences, University of Tokyo, Tokyo, Japan

³Laboratory of Veterinary Internal Medicine, Graduate School of Agricultural and Life Sciences, University of Tokyo, Tokyo, Japan

Corresponding author:

Kazuyuki Uchida DVM, PhD, Laboratory of Veterinary Pathology, Graduate School of Agricultural and Life Sciences, University of Tokyo, 1-1-1 Yayoi, Bunkyo-ku, Tokyo 113-8657, Japan
 Email: auchidak@mail.ecc.u-tokyo.ac.jp



Creative Commons Non Commercial CC BY-NC: This article is distributed under the terms of the Creative Commons

Attribution-NonCommercial 4.0 License (<http://www.creativecommons.org/licenses/by-nc/4.0/>) which permits non-commercial use, reproduction and distribution of the work without further permission provided the original work is attributed as specified on the SAGE and Open Access pages (<https://us.sagepub.com/en-us/nam/open-access-at-sage>).

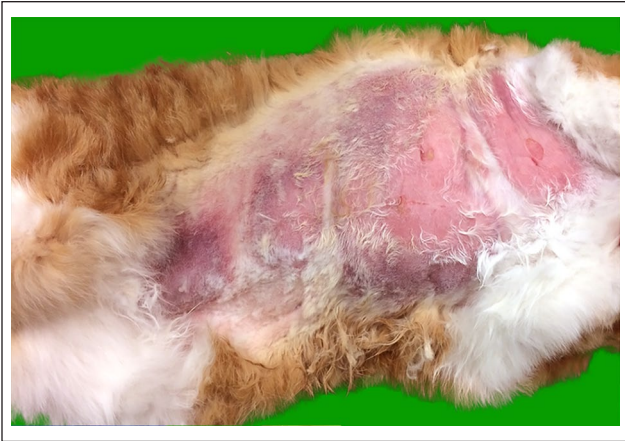

Figure 1 Skin. Alopecia and severe erythema of the ventral abdomen and right axilla

cases of non-T, non-B lymphoma/leukaemia.¹⁰ There has been only one case report of blastic NK cell leukaemia in a dog, which was diagnosed based on the detection of CD56 mRNA expression by a reverse transcription PCR analysis.⁸

Here, we report pathological and clinical findings of NK cell lymphoma/leukaemia in a cat. The immunohistochemical findings of the neoplastic cells revealed that CD56 can be used as a marker for feline NK cell neoplasm in routine histopathological examinations.

Case description

A 7-year-old neutered male, mixed-breed cat presented with subcutaneous oedema and erythema of the right axilla extending to the abdomen, and swelling of the right forelimb (Figure 1). Clinical examinations revealed mild fever (39.7°C) and a subcutaneous soft mass (3.0 × 2.0 cm) on the back. A complete blood count revealed anaemia (packed cell volume [PCV] 26%) and thrombocytopenia (96,000 platelets/ μ l) (Table 1). A blood smear examination revealed a small number of large atypical round cells. The cells had small-to-moderate amounts of basophilic cytoplasm and large nuclei with finely diffused chromatin and several nucleoli. The cells rarely contained fine azurophilic granules in the cytoplasm (supplementary Figure 1). Examinations for feline immunodeficiency virus antibodies and feline leukaemia virus antigens were not performed. Thoracic and abdominal radiography and abdominal ultrasonography showed no significant findings. Cytological analysis with fine-needle aspiration from the subcutaneous lesion of the right axilla and the dorsal subcutaneous mass revealed the presence of large atypical round cells. The cells had small-to-moderate amounts of basophilic cytoplasm and irregular nuclear membranes, and were occasionally binucleated (Figure 2). The nucleus had one or several distinct nuclei with finely diffused chromatin. Azurophilic granules

were not observed in the cytoplasm. The cells were thought to be lymphoid cells and the presumed diagnosis was lymphoma. A PCR-based clonality analysis for TCR-gamma (TCR γ) and immunoglobulin heavy chain (IgH) genes with DNA extracted from the subcutaneous lesions revealed no clonal rearrangement of both genes. All PCR products were assessed by heteroduplex analysis as previously described.^{11,12}

The cat was treated with prednisolone at a dose of 1.0–1.5 mg/kg/day and L-asparaginase at a dose of 400 U/kg, four times in total at various intervals. The treatment led to a transient improvement of oedema and regression of the dorsal mass. However, the cat died after 78 days of initial treatment owing to loss of appetite, severe anaemia (PCV 8.9%) and liver dysfunction. A complete necropsy was performed on the day. At necropsy, the cat presented with severe jaundice and an oedematous subcutaneous mass in the right chest. Moderate hepatomegaly, splenomegaly, lymphadenopathy of the mediastinal (1.2 × 0.8 cm) and left axilla (0.8 × 0.8 cm), and haemorrhage in multiple organs were also observed (Figure 3).

The subcutaneous tumour tissue, visceral organs and brain were fixed in 10% neutral-buffered formalin, embedded in paraffin, sectioned at 4 μ m thickness, and stained with haematoxylin and eosin. Immunohistochemistry was performed using primary antibodies listed in Table 2. The following normal tissues without lesions were used as positive controls: normal thymus, spleen, lymph node, bone marrow, liver, intestine and brain. A horseradish peroxidase (HRP)-labelled polymer system (EnVision+ System; Dako) was used as a secondary antibody. Labelled complexes were visualised with the 3,3'-diaminobenzidine chromogen, and the sections were counterstained with haematoxylin. Double immunofluorescence was performed on normal thymus, spleen and liver tissues of cats to detect CD56⁺ and CD3⁻ cells. Alexa 488-conjugated donkey anti-mouse IgG (1:200; Invitrogen) and Alexa 594-conjugated donkey anti-rabbit IgG (1:200; Invitrogen) were used as secondary antibodies and counterstained with 4',6-diamidino-2-phenylindole (Vector Laboratories). Western blotting analysis was performed to confirm the reactivity with an appropriate molecular weight antigen of anti-CD56 and anti-CD57 antibodies using feline and canine brain tissues.¹⁸ The membranes were incubated with each antibody (1:1000) at 4°C overnight, and then incubated with HRP-conjugated sheep anti-mouse IgG (1:5000) (Bethyl Laboratories, Montgomery, TX) at room temperature for 1 h.

Histologically, extensive necrosis, oedema and focal infiltration of large atypical round cells were observed in the subcutaneous mass (Figure 4). The tumour cells had scarce cytoplasm, an irregular nuclear membrane, coarse nuclear chromatin and a distinct nucleolus. The cells were occasionally binucleated, and anisocytosis and

Table 1 Complete blood cell count results

Laboratory parameter		Reference interval
RBC ($\times 10^4/\mu\text{l}$)	526	500–1000
HCT (%)	26	30.0–45.0
Hb (g/dl)	8.1	8.0–15.0
MCV (fl)	44.3	39.0–55.0
MCH (pg)	15.4	12.5–17.5
MCHC (g/dl)	34.8	31–35
Reticulocytes ($\times 10^4/\mu\text{l}$)	2.3	1.0–11.0
Platelets ($\times 10^4/\mu\text{l}$)	9.6	20–80
WBC ($/\mu\text{l}$)	11,160	5500–19,500
Neutrophils ($/\mu\text{l}$)	10,044	2500–12,500
Lymphocytes ($/\mu\text{l}$)	167	1500–7000
Monocytes ($/\mu\text{l}$)	335	0–850
Eosinophils ($/\mu\text{l}$)	0	0–1500
Basophils ($/\mu\text{l}$)	558	Rare
Other ($/\mu\text{l}$)*	56	–

*Large atypical round cells

RBC = red blood cells; HCT = haematocrit; Hb = haemoglobin; MCV = mean cell volume; MCHC = mean cell haemoglobin concentration; WBC = white blood cells

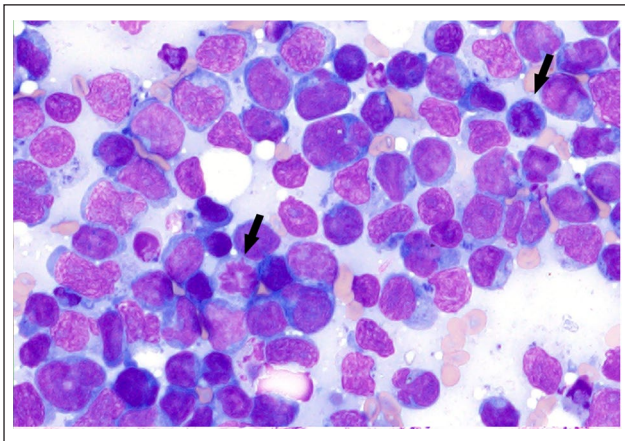


Figure 2 Subcutaneous fine-needle aspirate. Large atypical round cells with basophilic cytoplasm, irregular nuclear membrane, a distinct nucleolus and occasional mitotic figures (arrows). Wright Giemsa ($\times 1000$ magnification)

anisokaryosis were moderate. The nucleus of the tumour cell was approximately three times the diameter of a red blood cell. The tumour cells were also observed in the liver, spleen, bone marrow and lymph nodes of the mediastinal and left axilla. In the liver, the tumour cells were diffusely infiltrated (Figure 5). Multifocal haemorrhage and bile plugs in the capillary bile duct were also observed. In the spleen, neoplastic cells were diffusely infiltrated and replaced the red pulp, with multifocal haemorrhage. The bone marrow was hypoplastic and the tumour cells were diffusely infiltrated, comprising approximately 10% of nucleated cells (Figure 6). The tumour cells diffusely

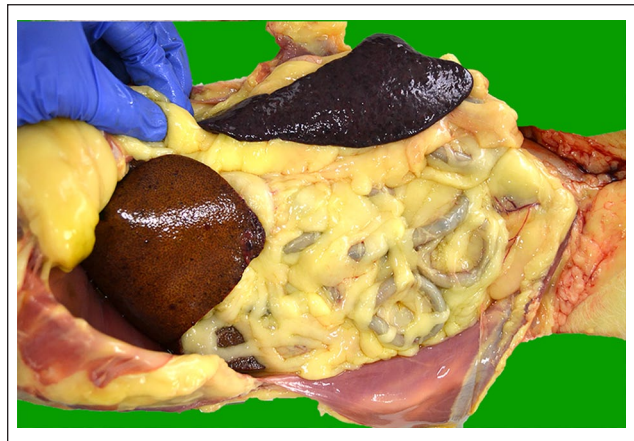

Figure 3 Abdominal cavity (right lateral recumbency). Jaundice of the adipose tissue and hepatosplenomegaly

infiltrated the sinus with haemorrhage in the mediastinal and left axilla lymph nodes. The number of mitotic figures was two per field ($\times 400$ magnification).

Immunohistochemically, in normal cat tissues, CD3 labelling was detected in the cell membrane and cytoplasm of lymphocytes (supplementary Figure 2). CD56⁺ lymphoid cells were detected in the thymus (Figure 7a), spleen and liver. CD57⁺ lymphoid cells were detected in the thymus (Figure 7b), intestinal mucosa, spleen and lymph node. In the brain, neuropil was positive for CD56 (supplementary Figure 3a) and CD57 (supplementary Figure 3b). CD34⁺ lymphoid cells were detected in the thymus (supplementary Figure 3c), spleen and lymph node. CD10⁺ lymphoid cells were detected in the

Table 2 Primary antibodies used in the present study

Antibody to	Host (clone)	Catalogue number	Dilution	Antigen retrieval	Source	Reactivity	References in feline tissue
CD3ε	Rabbit	IR503	Ready to use	Heat, pH 6.0	Dako, Tokyo, Japan	T cell	13, 14
CD20	Rabbit	RB-9013-P1	1:400	None	Thermo Fisher Scientific, Waltham, MA, USA	B cell	15
CD79a	Mouse (HM57)	M7051	1:50	Heat, pH 9.0	Dako, Tokyo, Japan	B cell	13, 14
Pax5	Rabbit	RB-9406-R7	Ready to use	Heat, pH 6.0	Thermo Fisher Scientific, Waltham, MA	B cell subset	15
BLA36	Mouse (A27-42)	MU231-JC	1:25	Heat, pH 6.0	BioGenex, Fremont, CA, USA	B cell subset	15
CD34	Goat	sc-7045	1:80	Heat, pH 6.0	Santa Cruz Biotechnology, Dallas, TX, USA	Haematopoietic progenitor cell, vascular endothelial cells	Supplementary Figure 3(c)
CD10	Mouse (56C6)	AM451-5M	Ready to use	Heat, pH 6.0	BioGenex, Fremont, CA, USA	Lymphocyte precursor cell, pre-B cell	Supplementary Figure 3(d)
CD56	Mouse (1G4)	LS-B12970-50	1:150	Heat, pH 6.0	LSBio, Seattle, WA, USA	NK cell, T-cell subset neurofilaments	6
CD57	Mouse (VC1.1)	C6680-100TST	1:500	Heat, pH 6.0	Sigma Adrich, Tokyo, Japan	NK cell/T-cell subset neurofilaments	6
CD117	Rabbit	A4502	1:100	Heat, pH 6.0	Dako, Tokyo, Japan	Mast cell	16
Granzyme B	Rabbit	E2580	1:100	Heat, pH 6.0	Spring Bioscience, Pleasanton, CA, USA	NK cell/T-cell subset	13
Perforin	Mouse (5B10)	ab89821	1:20	Heat, pH 9.0	Abcam, Cambridge, UK	NK cell/T-cell subset	14
HLA-DR	Mouse (TAL 1B5)	sc-53319	1:50	Heat, pH 6.0	Santa Cruz Biotechnology, Dallas, TX	MHC class II antigen presenting cell	17
Iba-1	Rabbit	019-19741	1:250	Heat, pH 6.0	Wako, Osaka, Japan	Macrophage, dendritic cells	17
CD204	Mouse (SRA -C6)	KT022	1:50	Heat, pH 9.0	Trans Genic, Kobe, Japan	Monocyte, macrophage, dendritic cells	Supplementary Figure 3(e)
Myeloperoxidase	Rabbit	A0398	1:500	Heat, pH 6.0	Dako, Tokyo, Japan	Myeloid cell	Supplementary Figure 3(f)

NK = natural killer; MHC = major histocompatibility complex

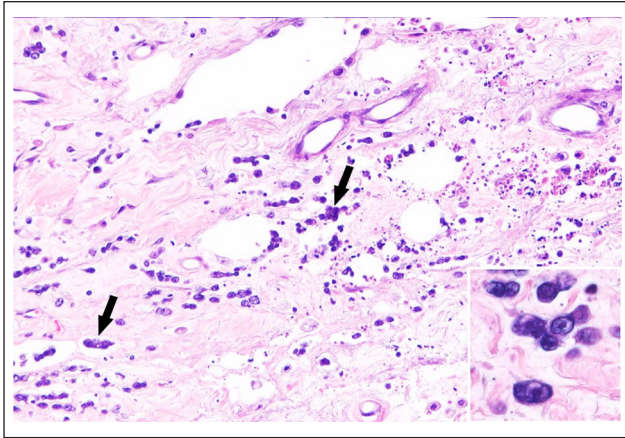


Figure 4 Skin. Infiltration of lymphoid tumour cells in the subcutaneous tissue (arrows). Inset: Neoplastic cells have scarce cytoplasm and irregularly shaped nucleus with a distinct nucleolus. Haematoxylin and eosin ($\times 200$ magnification)

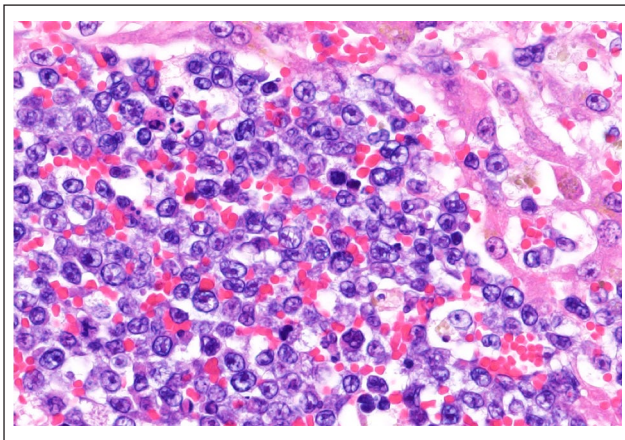


Figure 5 Liver. The tumour cells with markedly disrupted hepatic architecture, forming densely cellular sheets. Haematoxylin and eosin ($\times 400$ magnification)

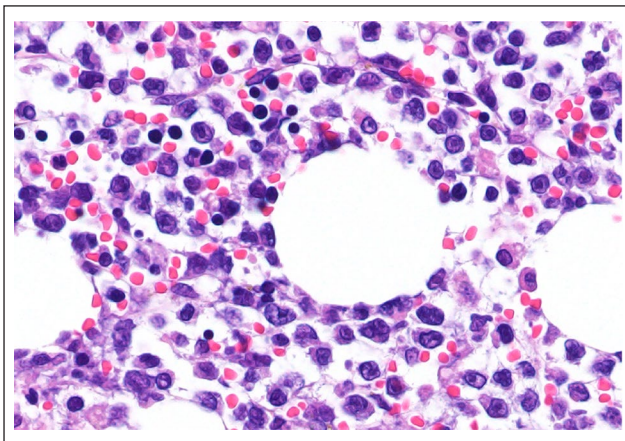


Figure 6 Bone marrow. Diffuse infiltration of lymphoid tumour cells. Haematoxylin and eosin ($\times 400$ magnification)

thymus, spleen, lymph node (supplementary Figure 3d) and bone marrow. Monocytes, macrophages and interstitial dendritic cells were positive for CD204 (supplementary Figure 3e). Myeloid cells in bone marrow (supplementary Figure 3f), neutrophils, monocytes and macrophages were positive for myeloperoxidase. In the present cat, the cell membrane of tumour cells was strongly positive for CD56 (Figure 8a) but negative for a T-cell-associated marker (CD3) (Figure 8b), B-cell-associated markers (CD20, CD79a, Pax5 and BLA36), macrophage/histiocyte markers (Iba-1 and CD204), a major histocompatibility complex class II antigen presenting cell marker (HLA-DR), mast cell-associated marker (CD117), a myeloid cell-associated marker (myeloperoxidase), haematopoietic progenitor-associated marker (CD34), lymphocyte precursor cell-associated markers (CD10), mature NK cell marker (CD57) and cytotoxic cell markers (granzyme B and perforin).

In double immunofluorescence, CD56⁺ CD3⁻ lymphoid cells were detected in the thymus (supplementary Figure 4a–c), spleen and liver. By Western blotting analysis, in both brain samples of cat and dog, anti-CD56 antibody labelled bands of 100–120 kDa, 140 kDa and 180 kDa, and anti-CD57 antibody labelled a band of 110 kDa, consistent with the molecular weights of CD56 and CD57 (Figure 9).

Discussion

The present cat was clinically diagnosed with lymphoma/leukaemia based on the results of cytology; however, a clonality analysis for TCR γ and IgH genes showed no clonal rearrangement. Post-mortem histopathological examination revealed a systemic infiltration of the blastic tumour cells that were positive for CD56 and negative for T-cell marker, B-cell markers, macrophage/histiocyte markers, mast cell-associated marker, myeloid cell-associated marker and haematopoietic progenitor-associated markers. Most of the tumour cells did not contain fine azurophilic granules in the cytoplasm, and the tumour cells were negative for granzyme B and perforin.

CD56, known as neuronal cell adhesion molecule, is one of the immunoglobulin superfamily of cell adhesion molecules and is composed of various isoforms (CD56 120, 140 and 180 kDa). Expression of CD56 is found in various organs, including nervous tissue, neuromuscular junction and the neuroendocrine system, and in blood cells such as NK cells and NK T cells.⁵ In addition, CD56 may be expressed in some feline myeloid leukaemias and plasma cell myeloma, and thus staining of CD56 should be interpreted together with other panels of antibodies to determine the cell lineage.¹⁹ In our study, anti-human CD56 antibody showed cross-reactivity with feline CD56 by Western blotting analysis. In our case, according to morphology and immunophenotype

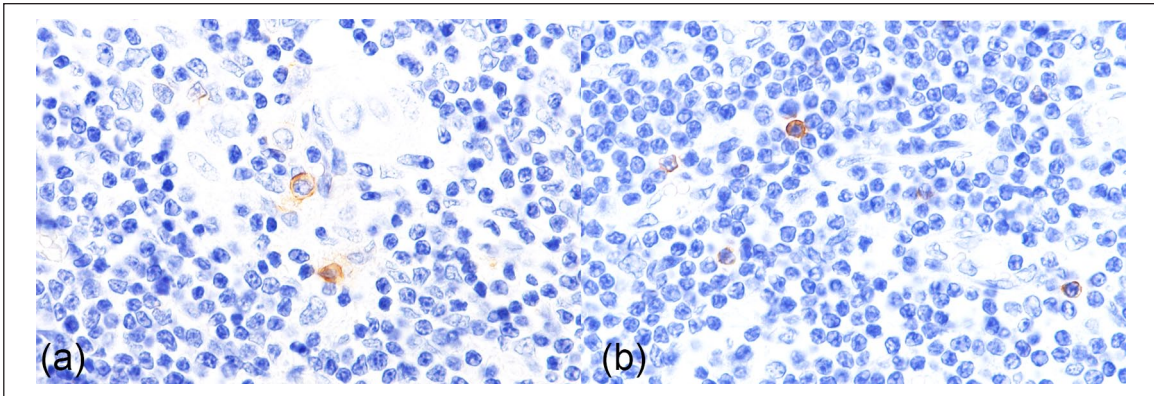


Figure 7 Normal thymus. (a) CD56⁺ lymphoid cells are occasionally observed. Immunohistochemistry (IHC) for CD56 ($\times 400$ magnification). (b) CD57⁺ lymphoid cells are occasionally observed. IHC for CD57 ($\times 400$ magnification)

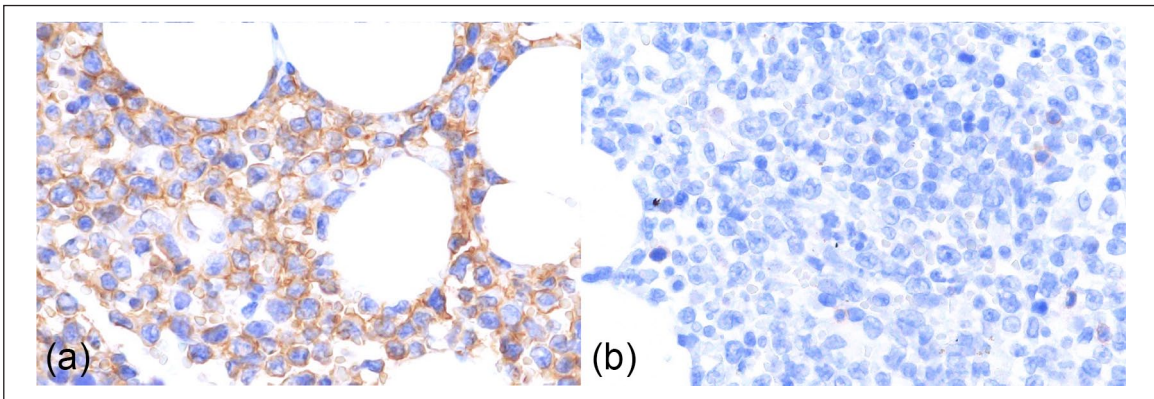


Figure 8 Bone marrow. Blastic natural killer cell lymphoma/leukaemia. (a) Strong membranous reactivity for CD56 is present in all neoplastic cells. Immunohistochemistry (IHC) for CD56 ($\times 400$ magnification). (b) No CD3 labelling is detected in tumour cells. IHC for CD3 ($\times 400$ magnification)

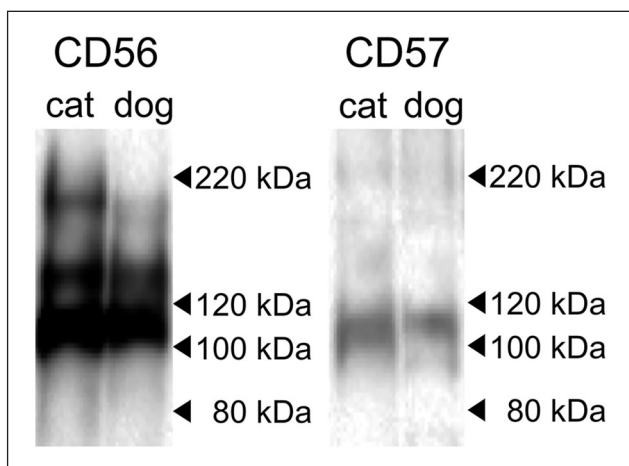


Figure 9 Western blot analysis. In brain samples from a cat and dog, anti-CD56 antibody labelled bands of 100–120 kDa, 140 kDa and 180 kDa (a), and anti-CD57 antibody labelled a band of 110 kDa (b)

of tumour cells, the cat was diagnosed with lymphoproliferative neoplasm of an NK cell phenotype.

In humans, NK cells are characterised by CD56⁺ and surface CD3⁻ immunophenotype. Cytoplasmic CD3 is expressed by the active state of the NK cell.²⁰ When NK cells are activated and express cytoplasmic CD3, negative staining for surface CD3 is important to distinguish them from NK T cells. The phenotype of NK cell changes during differentiation. NK cell precursors develop in the primary lymphoid organs, and migrate to the secondary lymphoid tissues. During differentiation, proliferative NK cells strongly express CD56 (CD56^{bright} NK cell), and the terminal differentiation involves downregulation of CD56, expression of CD57 and acquisition of cytotoxic function such as granzyme B and perforin.^{2,21}

According to the 2017 World Health Organization (WHO) classification of human haematopoietic and lymphoid tumours, NK cell tumours are classified into extranodal NK/T-cell lymphoma (ENKL), aggressive NK cell

leukaemia (ANKL), chronic lymphoproliferative disorder of NK cells (CLPD-NK) and NK lymphoblastic (blastic NK cell) leukaemia/lymphoma (BNKL).¹⁹ NK cell tumours are positive for CD56, negative for surface CD3 and variably positive for cytoplasmic CD3.^{4,19,22} For cytotoxicity, ENKL, ANKL and CLPD-NK show cytotoxic phenotype; BNKL does not. ENKL is the most common type in humans and it affects the upper aerodigestive tract (nasal type), although other sites such as the skin and gastrointestinal tract may be occasionally involved (extranasal).^{23,24} ANKL involves the peripheral blood, bone marrow, liver, spleen and other organs. CLPD-NK is a provisional entity characterised by a chronic increase in the peripheral blood NK cell count. BNKL shows an aggressive clinical course, involving initially the skin/soft tissue and then systemic proliferation of tumour cells. The tumour cells show an immature blastic NK phenotype, which is characterised by the absence of cytoplasmic granule, CD56⁺, membrane-CD3⁻ and granzyme B⁻.^{1,22}

According to the WHO classification of haematopoietic tumours of domestic animals, NK cell tumours are classified as 'NK-cell chronic lymphocytic leukaemia' in the category of large granular lymphocyte proliferative disorders. The tumour is characterised by moderate lymphocytosis that is negative for CD3 and morphologically overlaps with T-cell chronic lymphocytic leukaemia, as well as aggressive NK cell leukaemia.²⁵⁻²⁷ However, the clinical manifestation, blastic morphology and immunophenotype of the tumour cells in the present case correspond to those of human BNKL. In the present case, although it is difficult to differentiate lymphoma and lymphoid leukaemia, the initial lesion of the subcutaneous mass and the proportion of tumour cell (approximately 10%) in the bone marrow suggest blastic NK cell lymphoma.

Conclusions

The present study shows that an NK cell tumour should be considered as a differential in feline lymphoid neoplasms of non-B and non-T-cell origin. Moreover, CD56 could be a useful diagnostic marker for feline NK cell neoplasms, and additional studies will be needed to evaluate the use of it in diagnostic immunohistochemistry.

Acknowledgements We thank Mr TE Kishimoto and Mrs N Ushio.

Conflict of interest The authors declared no potential conflicts of interest with respect to the research, authorship, and/or publication of this article.

Funding The authors received no financial support for the research, authorship, and/or publication of this article.

Ethical approval This work involved the use of client-owned animals only, and followed established internationally

recognised high standards ('best practice') of individual veterinary clinical patient care. Ethical approval from a committee was not therefore needed.

Informed consent Informed consent (either verbal or written) was obtained from the owner or legal guardian of the animal described in this work for the procedures undertaken.

Supplementary material The following files are available:

Figure S1: Blastic NK cell lymphoma/leukaemia, cat. Blood smear examination. The cells rarely contained azurophilic cytoplasmic granules (arrow). Wright Giemsa ($\times 1000$ magnification)

Figure S2: Normal tissues, cat. Lymph node. CD3 labelling was detected in the cell membrane and cytoplasm of lymphocytes. Immunohistochemistry (IHC) for CD3 ($\times 400$ magnification)

Figure S3: Normal tissues, cat. (a) Brain. Strong labelling for CD56 is present in neuropil. IHC for CD56 ($\times 400$ magnification).

(b) Brain. Neuropils are positive for CD57. IHC for CD57 ($\times 400$ magnification).

(c) Thymus. Membranous labelling is detected in large lymphoid cells with an antibody for CD34. IHC for CD34 ($\times 400$ magnification).

(d) Lymph node. Membranous labelling for CD10 is detected in small-to-medium lymphoid cells. IHC for CD10 ($\times 400$ magnification).

(e) Lymph node. Cytoplasmic and membranous reactivity for CD204 is present in macrophages. IHC for CD204 ($\times 400$ magnification).

(f) Bone marrow. Light granular cytoplasmic labelling is detected in myeloid cells with an antibody for myeloperoxidase. IHC for myeloperoxidase ($\times 400$ magnification)

Figure S4: Normal thymus, cat. Double immunofluorescence for CD56 and CD3, 4',6-diamidino-2-phenylindole nuclear counter staining (blue).

(a) Small numbers of cells express CD56 (green labelling).

(b) Most cells express CD3 (red labelling).

(c) A merged image shows that CD56⁺ cells do not express CD3

References

- 1 Bayerl MG, Rakozy CK, Mohamed AN, et al. **Blastic natural killer cell lymphoma/leukaemia: a report of seven cases.** *Am J Clin Pathol* 2002; 117: 41-50.
- 2 Cichocki F, Miller JS, Anderson SK, et al. **Epigenetic regulation of NK cell differentiation and effector functions.** *Front Immunol* 2013; 4: 55.
- 3 Freud AG, Becknell B, Roychowdhury S, et al. **A human CD34(+) subset resides in lymph nodes and differentiates into CD56bright natural killer cells.** *Immunity* 2005; 22: 295-304.
- 4 Greer JP and Mosse CA. **Natural killer-cell neoplasms.** *Curr Hematol Malig Rep* 2009; 4: 245-252.
- 5 Bonkobara M, Sato T, Takahashi N, et al. **Characterization of cDNA and the genomic sequence encoding canine neural-cell adhesion molecule, CD56/N-CAM.** *Vet Immunol Immunopathol* 2005; 107: 171-176.
- 6 Joling P, Broekhuizen R, de Weger RA, et al. **Immunohistochemical demonstration of cellular antigens of the cat defined by anti-human antibodies.** *Vet Immunol Immunopathol* 1996; 53: 115-127.
- 7 Vermeulen BL, Devriendt B, Olyslaegers DA, et al. **Natural killer cells: frequency, phenotype and function in healthy cats.** *Vet Immunol Immunopathol* 2012; 150: 69-78.

- 8 Bonkobara M, Saito T, Yamashita M, et al. **Blastic natural killer cell leukaemia in a dog – a case report.** *Vet J* 2007; 174: 659–662.
- 9 McDonough SP and Moore PF. **Clinical, hematologic, and immunophenotypic characterization of canine large granular lymphocytosis.** *Vet Pathol* 2000; 37: 637–646.
- 10 Snead EC. **Large granular intestinal lymphosarcoma and leukaemia in a dog.** *Can Vet J* 2007; 48: 848–851.
- 11 Werner JA, Woo JC, Vernau W, et al. **Characterization of feline immunoglobulin heavy chain variable region genes for the molecular diagnosis of B-cell neoplasia.** *Vet Pathol* 2005; 42: 596–607.
- 12 Moore PF, Woo JC, Vernau W, et al. **Characterization of feline T cell receptor gamma (TCRG) variable region genes for the molecular diagnosis of feline intestinal T cell lymphoma.** *Vet Immunol Immunopathol* 2005; 106: 167–178.
- 13 Moore PF, Rodriguez-Bertos A and Kass PH. **Feline gastrointestinal lymphoma: mucosal architecture, immunophenotype, and molecular clonality.** *Vet Pathol* 2012; 49: 658–668.
- 14 Neta M, Naigamwalla D and Bienzle D. **Perforin expression in feline epitheliotropic cutaneous lymphoma.** *J Vet Diagn Invest* 2008; 20: 831–835.
- 15 Yoshino Y, Chambers JK, Nakamori T, et al. **Primary cerebellar lymphoma with Hodgkin lymphoma-like morphology in a cat.** *J Vet Diagn Invest* 2017; 29: 707–710.
- 16 Morini M, Bettini G, Preziosi R, et al. **C-kit gene product (CD117) immunoreactivity in canine and feline paraffin sections.** *J Histochem Cytochem* 2004; 52: 705–708.
- 17 Ide T, Uchida K, Tamura S, et al. **Histiocytic sarcoma in the brain of a cat.** *J Vet Med Sci* 2010; 72: 99–102.
- 18 Matsumoto I, Nakashima K, Goto-Koshino Y, et al. **Immunohistochemical profiling of canine intestinal T-cell lymphomas.** *Vet Pathol* 2019; 56: 50–60.
- 19 Swerdlow SH, Campo E, Harris NL, et al. **WHO classification of tumours of haematopoietic and lymphoid tissues.** 4th ed. Lyon: IARC Press, 2017.
- 20 Lanier LL, Chang C, Spits H, et al. **Expression of cytoplasmic CD3 epsilon proteins in activated human adult natural killer (NK) cells and CD3 gamma, delta, epsilon complexes in fetal NK cells. Implications for the relationship of NK and T lymphocytes.** *J Immunol* 1992; 149: 1876–1880.
- 21 Freud AG and Caligiuri MA. **Human natural killer cell development.** *Immunol Rev* 2006; 214: 56–72.
- 22 Suzuki R, Nakamura S, Suzumiya J, et al. **Blastic natural killer cell lymphoma/leukaemia (CD56-positive blastic tumour): prognostication and categorization according to anatomic sites of involvement.** *Cancer* 2005; 104: 1022–1031.
- 23 Ahn HK, Suh C, Chuang SS, et al. **Extranodal natural killer/T-cell lymphoma from skin or soft tissue: suggestion of treatment from multinational retrospective analysis.** *Ann Oncol* 2012; 23: 2703–2707.
- 24 Au WY, Weisenburger DD, Intragumtornchai T, et al. **Clinical differences between nasal and extranasal natural killer/T-cell lymphoma: a study of 136 cases from the International Peripheral T-Cell Lymphoma Project.** *Blood* 2009; 113: 3931–3937.
- 25 Valli V, Jacobs R, Parodi A, et al. **Histopathological classification of hematopoietic tumors of domestic animals.** 2nd ed. Washington, DC: Armed Forces Institute of Pathology Press, 2002.
- 26 Valli VE. **T-cell and NK-cell Neoplasms.** In: Valli VE (ed). *Veterinary comparative hematopathology.* Ames, IA: Blackwell Press, 2007, pp 275–365.
- 27 Valli VE, San Myint M, Barthel A, et al. **Classification of canine malignant lymphomas according to the World Health Organization criteria.** *Vet Pathol* 2011; 48: 198–211.