



OPEN ACCESS

Effects of the re-esterified triglyceride (rTG) form of omega-3 supplements on dry eye following cataract surgery

Jongyeop Park,¹ Young-Sik Yoo,² Eunhae Shin,¹ Gyule Han,¹ Kyungyoon Shin,³ Dong Hui Lim ,^{1,4} Tae-Young Chung ¹

For numbered affiliations see end of article.

Correspondence to

Dong Hui Lim, Department of Ophthalmology, Samsung Medical Center, Sungkyunkwan University School of Medicine, 81 Irwon-Ro, Gangnam-gu, Seoul 06351, Republic of Korea; donghui.lim@samsung.com and Tae-Young Chung, Department of Ophthalmology, Samsung Medical Center, Sungkyunkwan University School of Medicine, 81 Irwon-Ro, Gangnam-gu, Seoul 06351, Republic of Korea; tychung@skku.edu

JP and Y-SY contributed equally as co-first authors. DHL and T-YC contributed equally as co-corresponding authors.

Received 8 June 2020
Revised 17 July 2020
Accepted 17 August 2020
Published Online First
11 September 2020

ABSTRACT

Background/Aims To evaluate the clinical outcomes of the systemic re-esterified triglyceride (rTG) form of omega-3 fatty acids in patients with dry eye symptoms after cataract surgery.

Methods This prospective comparative cohort study comprised 66 patients complaining of new-onset non-specific typical dry eye 1 month after uncomplicated cataract surgery. Subjects were randomly allocated into control and omega-3 groups based on administration of the systemic rTG form of omega-3 fatty acids for 2 months, in addition to use of artificial teardrop. Ocular surface parameters (Schirmer's test, tear break-up time, corneal staining score and matrix metalloproteinase-9 (MMP-9)) and subjective questionnaire results (Ocular Surface Disease Index (OSDI)) and Dry Eye Questionnaire (DEQ) for dry eye were evaluated before and after omega-3 supplementation.

Results Two months after omega-3 supplementation, the Oxford score was lower in the omega-3 group than in the control group. There was an improvement of subjective symptom scores of OSDI and DEQ in the omega-3 group (both $p < 0.05$). The ratio of increasing MMP-9 level in the omega-3 group was lower than that in the control group ($p = 0.027$).

Conclusion The rTG form of omega-3 supplementation might be related to reduction of ocular surface inflammation rather than secretion of tears, and it might be effective for non-specific typical dry eye after uncomplicated cataract surgery.

Trial registration Number NCT04411615.

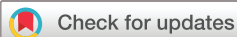INTRODUCTION

Dry eye disease (DED) is a multifactorial inflammatory disorder that can lead to decreased visual quality, damage to the ocular surface, discomfort and overall reduction in quality of life.^{1 2} Current strategies for DED management include enhancing tear volume and quality, reducing ocular inflammation, treating underlying eyelid disease, and modification of diet and lifestyle.² The essential fatty acids, including the omega-3 fatty acids eicosapentaenoic acid (EPA) and docosahexaenoic acids (DHA), are considered promising dietary supplements for DED. Omega-3 is known to modulate the arachidonic acid pathway and reduce the inflammatory response.³ It biases prostaglandin metabolism towards the production of anti-inflammatory eicosanoids, which limit and resolve inflammation.³

Several studies reported that omega-3 is beneficial to DED treatment.^{4–9} However, the results from previous randomised clinical trials evaluating changes of subjective symptoms and objective ocular surface parameters to understand the effect of omega-3 on DED showed inconsistencies.^{10–13} Some studies showed that the omega-3 supplement alleviated dry eye symptoms and improved both tear quality and quantity.^{11 13–16} Other clinical trials showed that omega-3 did not significantly improve ocular surface parameters, such as tear break-up time (TBUT) and Schirmer's score.^{8 17} A recent large study (the DREAM trial) reported omega-3 as having no benefit for patients with DED.¹⁷ Although there is no definitive evidence regarding the efficacy of omega-3 supplementation for relief of symptoms or resolution of signs of DED, the American Academy of Ophthalmology Preferred Practice Pattern guidelines state that omega-3 supplementation may be beneficial.¹⁸ Furthermore, the Tear Film & Ocular Surface Society Dry Eye Workshop (DEWS II) recommended omega-3 supplementation as one of the potential dietary modifications for DED.¹⁹

The DREAM trial differed in patient selection, restriction of other DED treatments and duration of treatment, which might have caused the heterogeneous results and controversies for the effect of omega-3 on DED.¹⁷ Additionally, type, dosage and form of omega-3 supplements should be considered. Not all omega-3 supplements have the same relative bioavailability.³ Major types of omega-3, such as EPA and DHA, may be present in ethyl ester (EE) form, triglyceride (TG) form, as free fatty acid, or as phospholipid.³ It has been suggested that the form in which the omega-3 is consumed may affect its relative bioavailability. The superior bioavailability of TG over EE forms of omega-3 has been identified by several researchers.^{20 21} The TG form of omega-3 is better tolerated with fewer gastrointestinal side effects than the EE form.²² Re-esterification is a process that removes the artificially induced alcohol in chemically modified EE fish oil to create a more natural form (TG form) of omega-3. The re-esterified triglyceride (rTG) form of omega-3 is not only better tolerated with fewer gastrointestinal side effects, but it is also better absorbed than the EE form of omega-3.²³

Multiple studies have investigated the effects of omega-3 supplements in the treatment of DED. They differed in the types and form of omega-3



© Author(s) (or their employer(s)) 2021. Re-use permitted under CC BY-NC. No commercial re-use. See rights and permissions. Published by BMJ.

To cite: Park J, Yoo Y-S, Shin E, et al. *Br J Ophthalmol* 2021;**105**:1504–1509.

supplements, and the types of DED also differed. To our knowledge, just one research investigated the effect of omega-3 supplementation on dry eye following uncomplicated cataract surgery.⁶ Accordingly, the present study aimed to evaluate the clinical outcomes of the systemic rTG form of omega-3 in patients with non-specific typical DED that developed after uncomplicated cataract surgery.

MATERIALS AND METHODS

This prospective study was conducted in accordance with the tenets of the Declaration of Helsinki and was approved by the Ethical Committee of Samsung Medical Center (IRB no. 2020-01–150). All participants provided written informed consent to participate. Patients with newly developed dry eye symptoms at 1 month after uncomplicated cataract surgery were enrolled in this study. All patients were performed of traditional phacoemulsification and posterior chamber IOL (intraocular lens) implantation without femtosecond laser. All surgeries were performed with same technique under topical anaesthesia (suture-less cataract surgeries through a clear corneal incision of 2.8 mm with the implantation of foldable IOL within the capsular bag). The post-surgical drug regimen was same in all patients and consisted of antibiotics (gatifloxacin eye-drops 4 times per day for 1 month) and steroid drops (loteprednol acetate 4 times per day for 1 month). At 1 month after uneventful cataract surgeries, some patients complained of dry eye and irritation symptoms, even though the complete vision has been restored. Among them, those who stated that they did not have any dry eye symptoms before cataract surgery were enrolled. In other words, the patients who developed dry eye symptoms after cataract surgery were included. The dry eye symptoms included non-specific typical subjective discomfort, such as ocular dryness, foreign body sensation, burning, itching, red eye, photophobia or blurring of vision after cataract surgery.

The following subjects were excluded: those who used any eye-drops other than artificial tear at any time during the follow-up, including topical antibiotics and corticosteroids which should be routinely used only for 1 month after cataract surgery; those who took systemic medication, which might affect ocular surface; subjects with any surgical or medical history including refractive corneal laser ablation, contact lens use and systemic disease that are associated with DED (including diabetes, Sjogren's syndrome and rheumatoid disease) before cataract surgery; and those with any ocular complications during the follow-up period after cataract surgery.

The included subjects were randomly allocated using a computer-generated random number table into two groups based on administration of the systemic rTG form of omega-3: omega-3 group, who received omega-3 supplementation (two tablets two times per day for 2 months) that contained a total of 1680 mg of EPA/506 mg of DHA rTG form of omega-3 (PRN Dry Eye Omega Benefits softgels; PRN Physician Recommended Nutraceuticals, Plymouth Meeting, Pennsylvania, USA) along with artificial teardrops (New Hyaluni 0.15%; Taejoon, Seoul, Korea) (four times per day) for 2 months, and the control group, in whom dry eyes were controlled by artificial teardrops four times a day for 2 months without omega-3 supplementation.

Measurement outcomes

Ocular surface parameters of TBUT, Schirmer's test, Oxford score and matrix metalloproteinase-9 test (MMP-9) and subjective questionnaire responses were measured to evaluate objective and subjective dry eye symptoms, respectively. All subjects

underwent examination in the same order as follows: MMP-9 measurement, TBUT, Oxford scoring and the anaesthetised Schirmer's test. After all the ocular examinations, each patient was asked to complete the Ocular Surface Disease Index (OSDI) and 5-Item Dry Eye Questionnaire (DEQ).

MMP-9 level was assessed using the InflammDry test (Quidel Corp, San Diego, California, USA) at baseline and 8 weeks. For a more detailed evaluation of MMP-9 levels, the semiquantitative method of grading the intensity of the InflammDry test result line signals was adopted, as published by Park *et al.*^{24 25} For samples with positive results, we graded the intensity of the test result using a grading index referring to the manufacturer's instructions. As more vivid red line indicates a higher MMP-9 concentration in the tear film, the positive red line was compared with the grading index to classify the result as trace-positive, weak-positive, positive and strong-positive. Three well-trained observers (JP, Y-SY and KS) individually interpreted the InflammDry grading result, masked to subject characteristics. The result was confirmed when the interpretations of at least two of the observers were identical. Corneal staining was evaluated with fluorescein using the Oxford grading scale from 0 to 5 (0: no staining, 5: severe staining).

Patients completed the standard questionnaires for OSDI and DEQ, which are structured instruments to quantify severity of dry eye symptoms. The OSDI questionnaire was scored from 0 to 100 (100 being the most severe disease), and the DEQ questionnaire was scored from 0 to 22 (22 being the most severe state).

Statistical analysis

All categorical variables were summarised by treatment group with frequency and percentage of subjects in each category. Descriptive statistics (mean \pm SD) were used to summarise most efficacy data including that of continuous variables. The sex distribution was compared with the χ^2 test. Wilcoxon signed-ranked test was used to analyse within-group changes. χ^2 test was used to assess treatment differences for the MMP-9 positive enzyme biomarker categorical variable. All statistical analyses were conducted using SPSS (IBM SPSS Statistics for Windows, Version 22.0. Armonk, New York, USA).

RESULTS

A total of 68 subjects were screened eligible for the study. Two subjects dropped out over the course of 8 weeks in the omega-3 group. No adverse effects of omega-3 supplementation were observed during the follow-up. Ultimately, a total of 66 subjects completed the study and were included. The mean age was 65.47 \pm 13.67 years, and 63.6% (42/66) were women. Thirty-two patients were assigned to the omega-3 group, who received rTG form omega-3 supplementation with artificial teardrops for the treatment of dry eye symptoms, and 34 patients were assigned to the control group, who did not take omega-3 supplements. The demographic data and baseline characteristics are described in [table 1](#).

At baseline evaluations, there were no significant differences in Schirmer's test, TBUT and Oxford score between the two groups ($p=0.958$, 0.386 and 0.534, respectively ([table 2](#))). OSDI and DEQ scores were higher in the omega-3 group than in the control group ($p<0.001$ and <0.001 , respectively).

At 8 weeks of follow-up, no significant difference was measured in the change from baseline for TBUT in both groups ([table 2](#)). Mean TBUT in the control group was 3.71 \pm 1.66 s, which changed after treatment to 3.62 \pm 1.83 s ($p=0.834$). Mean TBUT in the omega-3 group changed from 3.40 \pm 1.20 at baseline to

Table 1 Baseline characteristics between the control and omega-3 groups

	Control group (n=34) (artificial tears without rTG form of omega-3)	Omega-3 group (n=32) (artificial tears with rTG form of omega-3)	P value
Age (years)	66.28±15.14	64.56±11.96	0.135
Sex (women, %)	22 (64.7%)	20 (62.5%)	0.195
TBUT (s)	3.71±1.66	3.40±1.20	0.386
Schirmer's test (mm)	9.56±5.97	9.97±7.09	0.958
Oxford score	0.94±0.65	1.16±1.05	0.534
OSDI score	13.15±8.98	24.06±12.58	<0.001
DEQ score	7.59±3.88	13.13±5.30	<0.001
MMP-9 grade, negative/positive (trace/weak/positive/strong)	9/25 (20/1/2/2)	12/20 (14/2/1/3)	0.430

DEQ, Dry Eye Questionnaire; MMP-9, matrix metalloproteinase-9; OSDI, Ocular Surface Disease Index; rTG, re-esterified triglyceride; TBUT, tear break-up time. Bold values denote statistical significance at the $p < 0.05$ level.

Table 2 Comparison of parameters used to evaluate dry eye in the control and omega-3 groups

		Baseline	8 weeks	P value
TBUT (s)	Control	3.71±1.66	3.62±1.83	0.834
	Omega-3	3.40±1.20	3.81±1.48	0.170
	P value	0.386	0.641	
Schirmer's test (mm)	Control	9.56±5.97	10.53±7.65	0.639
	Omega-3	9.97±7.09	12.41±7.76	0.065
	P value	0.958	0.324	
Oxford score	Control	0.94±0.65	0.76±0.55	0.184
	Omega-3	1.16±1.05	0.44±0.62	0.004
	P value	0.534	0.027	
OSDI score	Control	13.15±8.98	14.74±11.29	0.450
	Omega-3	24.06±12.58	17.84±10.45	0.007
	P value	<0.001	0.252	
DEQ score	Control	7.59±3.88	7.24±4.86	0.653
	Omega-3	13.13±5.30	9.35±5.95	0.004
	P value	<0.001	0.121	

DEQ, Dry Eye Questionnaire; OSDI, Ocular Surface Disease Index; TBUT, tear break-up time. Bold values denote statistical significance at the $p < 0.05$ level.

3.81±1.48 s at 8 weeks ($p=0.170$). Also, no significant difference was measured in the change of Schirmer's score in both groups (table 2). In the control group, it changed from 9.56±5.97 mm at baseline to 10.53±7.65 mm after treatment ($p=0.639$). In the omega-3 group, the Schirmer's score changed from 9.97±7.09 mm at baseline to 12.41±7.76 mm at 8 weeks ($p=0.065$).

Oxford score at baseline was 0.94±0.65 in the control group and 1.16±1.05 in the omega-3 group ($p=0.534$). At 8 weeks of follow up, the mean Oxford score did not change significantly in the control group ($p=0.184$). However, Oxford score significantly decreased from 1.16±1.05 to 0.44±0.62 in the omega-3 group ($p=0.004$, figure 1). Also, the changes in Oxford score from the baseline were significantly different between the groups (table 3).

At the 8-week follow-up visit, there was a statistically significant change in OSDI score in the omega-3 group decreasing from 24.06±12.58 to 17.84±10.45 ($p=0.007$). However, no significant change was measured in OSDI score in the control group from baseline at 8 weeks ($p=0.450$, figure 2A). A significant reduction from baseline was measured in OSDI score in omega-3 group (-6.22±12.26) versus control group (+1.58±12.07) ($p=0.011$, table 3). Also, there was a significant change in DEQ score in the omega-3 group decreasing from 13.13±5.30 to 9.35

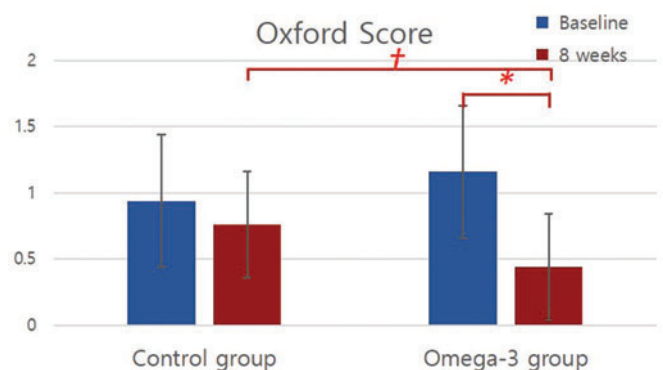


Figure 1 Objective parameters used to evaluate dry eye after uncomplicated cataract surgery. The Oxford corneal staining score results at pretreatment and post-treatment in the control group and the omega-3 group. *P value <0.05 (intragroup comparison). †P value <0.05 (intergroup difference).

Table 3 Changes of parameters from baseline in control group and omega-3 group

	Control group	Omega-3 group	P value
TBUT (s)	-0.09±2.56	0.41±1.65	0.440
Schirmer's test (mm)	0.57±7.04	2.54±7.52	0.369
Oxford score	-0.14±0.78	-0.63±1.16	0.037
OSDI score	1.58±12.07	-6.22±12.26	0.011
DEQ score	-0.36±4.57	-3.78±6.91	0.020

DEQ, Dry Eye Questionnaire; OSDI, Ocular Surface Disease Index; TBUT, tear break-up time. Bold values denote statistical significance at the $p < 0.05$ level.

±5.95 ($p=0.004$); no significant change was measured in DEQ score in the control group during the same period ($p=0.653$) (figure 2B). A significant improvement of DEQ score from baseline was measured in omega-3 group (-3.78±6.91) compared with control group (-0.36±4.57) ($p=0.020$, table 3).

Of the 34 patients in the control group, 25 (73.5%) tested positive and 9 (26.5%) negative for MMP-9 overall at baseline. More specifically, 9 (26.5%) patients were negative, 20 (58.8%) trace-positive, 1 (2.9%) weak-positive, 2 (5.9%) positive and 2 (5.9%) strong-positive (table 1). After 8 weeks, the MMP-9 level showed a trend of overall increase with 4 (11.8%) negative, 3 (8.8%) trace-positive, 22 (64.7%) weak-positive, 4 (11.8%) positive and 1 (2.9%) strong-positive. Of the 32 patients in the omega-3 group, 20 (62.5%) tested positive, and 12 (37.5%) tested negative

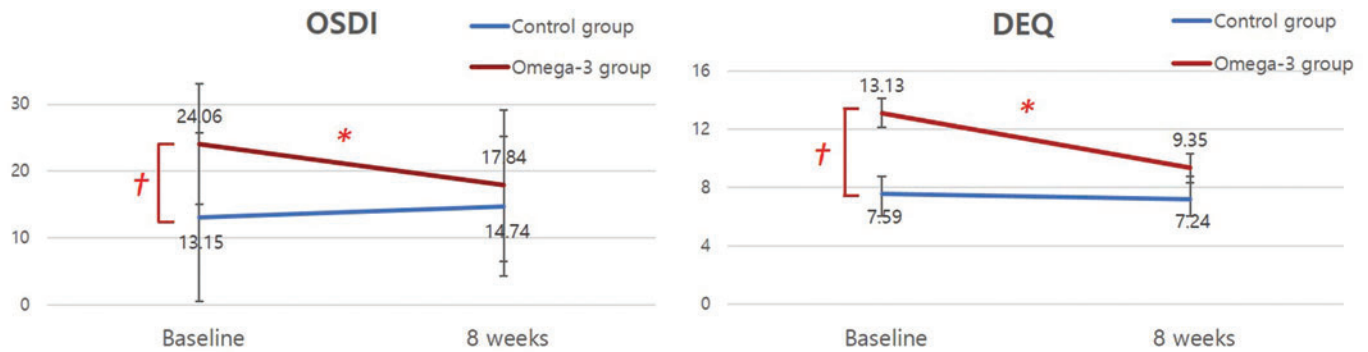


Figure 2 Subjective symptom scores reported at baseline and at the 8-week visit. The symptom score measured by Ocular Surface Disease Index (OSDI, A) and Dry Eye Questionnaire (DEQ, B) at pretreatment and post-treatment in the control group and the omega-3 group. *P value <0.05 (intragroup comparison). †P value <0.05 (intergroup difference).

for MMP-9 at baseline. Twelve (37.5%) patients were negative, 14 (43.8%) trace-positive, 2 (6.2%) weak-positive, 1 (3.1%) positive and 3 (9.4%) strong-positive (table 1). After treatment, 14 (43.8%) patients were negative, 12 (37.5%) trace-positive, 4 (12.5%) weak-positive, 1 (3.1%) positive and 1 (3.1%) strong-positive.

The MMP-9 level during the 8 weeks of treatment showed that the number of subjects with decreased MMP-9 level was significantly higher in the omega-3 group than in the control group ($p=0.027$, table 4).

DISCUSSION

The present study demonstrated the positive effect of the rTG type of omega-3 in the treatment of non-specific typical dry eye caused by uncomplicated cataract surgery. Systemic omega-3 supplementation improved subjective symptoms for dry eye. Oxford score and MMP-9 level, which are two of the objective parameters related to inflammation of the ocular surface, decreased after omega-3 supplementation.

Dry eye is an important complication of ocular surgeries, especially cataract surgeries. Patients undergoing cataract surgery tend to be elderly, and age may be a factor that exacerbates postsurgical dry eye.⁶ Dry eye after ocular surgery can negatively influence quality of life by causing a foreign body sensation, burning, itching, red eye, photophobia or blurring of vision. These symptoms can lead to patient complaints even after an uncomplicated cataract surgery.

The aetiology of dry eye after cataract surgery is not clearly understood; however, various mechanisms have been proposed that might affect the ocular surface environment after phacoemulsification and contribute to development of dry eye. Possible causes of dry eye include frequent use of eye-drops (which contains preservatives such as benzalkonium chloride) and topical anaesthesia during cataract surgery, exposure to light from the operating microscope and disruption of corneal innervation with corneal incision. Furthermore, surgery-induced inflammation is considered one of the most important triggers of postsurgical dry eye.^{26–29}

The rationale for omega-3 supplementation in management of DED may be explained by two different mechanisms of action. First, breakdown of omega-3 fatty acids results in anti-inflammatory molecules that suppress the inflammatory pathways found in DED.⁵ Specifically, DHA promotes synthesis of anti-inflammatory prostaglandins such as prostaglandin E3 and relieves dry eye symptoms.³⁰ An animal study revealed that omega-3 could modify the phospholipid composition of the lacrimal gland and inhibit local inflammation.³¹ Additionally, omega-3 increased lacrimal production by increasing lacrimal peroxidase activities.³² In addition to animal studies, multiple clinical studies have demonstrated the role of omega-3 supplements as an anti-inflammatory agent in treatment of DED, and they showed that omega-3 supplementation increased tear production.^{8 10 14 16} Another suggested mechanism of omega-3 in treatment of DED is changes in the fatty acid composition of meibomian glands, resulting in a secretion that contains increased levels of unsaturated fatty acids, which are in a liquid state at body temperature, thus preventing blockage of gland ducts and meibum stagnation. The increased quality of meibum reduces tear film evaporation and symptoms of DED.^{5 12 33 34} For these reasons, adding oral omega-3 supplements as an anti-inflammatory agent might be more helpful than artificial tears alone during the postoperative period after cataract surgery.

In the present study, reduction of MMP-9 level was significantly higher in the omega-3 group. MMP-9 is a proteolytic enzyme produced by stressed epithelial cells on the ocular surface in DED.³⁵ This enzyme is elevated in mild, moderate and severe cases of DED due to desiccation stress and reflects ocular surface inflammation.³⁵ The results from the present study suggested that supplementing the rTG type of omega-3 decreases ocular surface inflammation after cataract surgery and improves the damaged corneal epithelium. This result also supports a previous report that omega-3 directly reduces inflammation and decreases desiccative stress on the ocular surface epithelium.⁵

The changes in Schirmer's score and TBUT did not show significance in either group in the present study, although other studies with longer follow-up found significant improvement in TBUT.^{5 6} However, there was a trend towards TBUT improvement in the omega-3 group, and the mean change of Schirmer's test in the omega-3 group was clinically considerable (from 9.97 to 12.41). Considering that other studies with longer follow-up found significant improvement in TBUT or Schirmer's score, this discrepancy might be due to the short follow-up in the present study.^{5 6 14} We believe that significant changes in TBUT or Schirmer's score require longer follow-up to evaluate.

Table 4 Change in MMP-9 level after treatment in control and omega-3 groups

	MMP-9 level		P value
	Decreased	Increased	
Control group (n=34)	4	25	0.027
Omega-3 group (n=32)	9	12	

MMP-9, matrix metalloproteinase-9.

DEQ is a subset of five questions composed of frequency of ocular discomfort, ocular dryness, watery eye, late day intensity of discomfort and dryness. OSDI includes three subscales, which cover ocular discomfort, visual functions in daily activities and environmental triggers. The authors thought that the improvement in visual acuity associated with cataract surgery might affect the response to visual function domain of OSDI, eventually affecting the overall score of OSDI. Thus, both questionnaires were adopted to accurately assess the dry eye symptom. In this study, both OSDI and DEQ showed significant improvement after omega-3 supplementation. Especially, ocular discomfort, usually manifesting as foreign body sensation, ocular pain, sensitivity to light or fluctuation of vision after cataract surgery, is the common component of both OSDI and DEQ and showed significant improvement in the omega-3 group, but not in the control group.

The rTG type of omega-3 supplement showed the potential to control both the inflammation of the ocular surface and dry eye symptoms. To our knowledge, this is the first study evaluating the effect of the rTG type of omega-3 on cataract surgery-induced dry eye. The subjective symptoms measured by both OSDI and DEQ were improved in the omega-3 group, which is consistent with other studies.^{14–16} Epitropoulos *et al*⁵ reported that re-esterified omega-3 supplementation for 12 weeks was associated with significant improvement in tear osmolality, TBUT, MMP-9 and OSDI in patients with dry eye and MGD (meibomian gland dysfunction). Although use of the rTG form of omega-3 was not compared with other forms in the present study, the better bioavailability of the rTG form of omega-3 might be established from our short-term study results. Thus, we hypothesised that the rTG form of omega-3 supplementation has positive effects on ocular surface inflammation, thus improving ocular surface parameters and subjective symptoms in surgically induced non-specific typical dry eye.

Different postoperative periods before enrollment or exclusion of other treatments for management of DED can affect study results.^{7,17} The homogeneous characteristics of the study population in the present study could remove such possible confounding factors. All subjects in the present study were included at 1 month after cataract surgery, and no topical medication, except artificial teardrops, was used to control DED in both groups. As for limitations to our study, lack of placebo in the control group could affect the observed response. Although the patients were randomly distributed, the baseline OSDI and DEQ showed a significant difference between the two groups. So rather than directly comparing the two groups, the changes from baseline to post-treatment within each group were compared in this study. The small sample sizes in this study might have caused the differences in baseline characteristics. A subsequent, prospective, randomised, placebo-controlled study with a large population and a long follow-up period would give a better explanation of the effect of the rTG type of omega-3 on management of DED.

In conclusion, the results from this study demonstrated that oral ingestion of re-esterified omega-3 supplement for 8 weeks significantly improved the signs and symptoms of non-specific typical dry eye after uncomplicated cataract surgery. The beneficial effects of rTG omega-3 might be related to decreased inflammation of the ocular surface rather than increased secretion of tears. Dietary supplementation of re-esterified omega-3 could be added to postoperative management after cataract surgery to improve postsurgical dry eye syndrome.

Author affiliations

¹Ophthalmology, Samsung Medical Center, Sungkyunkwan University School of Medicine, Seoul, Korea (the Republic of)

²Ophthalmology, Uijeongbu St. Mary's Hospital, The Catholic University of Korea, Uijeongbu-si, Gyeonggi-do, Korea (the Republic of)

³Ophthalmology, Seongnam citizens medical center, Seongnam-si, Gyeonggi-do, Korea (the Republic of)

⁴Health Sciences and Technology, Samsung Advanced Institute for Health Sciences and Technology, Sungkyunkwan University, Seoul 06355, Korea (the Republic of)

Contributors DHL and T-YC contributed to conception and design of the study and Y-SY, GH, KS, DHL and T-YC conducted the study; (JP, Y-SY, ES, GH and KS) contributed to collection, management and interpretation of data; Y-SY contributed to data analysis; JP, Y-SY and ES contributed to writing of the article; DHL and T-YC contributed to preparation, review and approval of the manuscript. JP and Y-SY contributed equally to the manuscript as the co-first authors. DHL and T-YC contributed equally to the manuscript as the co-corresponding authors.

Funding This work was supported by a grant of Samsung Medical Center Research and Development Grant (#SMO120066) and a National Research Foundation of Korea grant funded by the Korean government's Ministry of Education (NRF-2020R1A2C2014139; Seoul, Korea) which was received by T-YC.

Competing interests None declared.

Provenance and peer review Not commissioned; externally peer reviewed.

Data availability statement No data are available.

Open access This is an open access article distributed in accordance with the Creative Commons Attribution Non Commercial (CC BY-NC 4.0) license, which permits others to distribute, remix, adapt, build upon this work non-commercially, and license their derivative works on different terms, provided the original work is properly cited, appropriate credit is given, any changes made indicated, and the use is non-commercial. See: <http://creativecommons.org/licenses/by-nc/4.0/>.

ORCID iDs

Dong Hui Lim <http://orcid.org/0000-0003-1543-7961>

Tae-Young Chung <http://orcid.org/0000-0002-1741-9196>

REFERENCES

- Lemp MA, Baudouin C, Baum J, *et al*. The definition and classification of dry eye disease: report of the definition and classification subcommittee of the international dry eye workshop (2007). *Ocul Surf* 2007;5(2):75–92.
- Herrero-Vanrell R, Peral A. International Dry Eye Workshop (DEWS). Update of the disease. *Arch Soc Esp Ophthalmol* 2007;82:733–4.
- Laidlaw M, Cockerline CA, Rowe WJ. A randomized clinical trial to determine the efficacy of manufacturers' recommended doses of omega-3 fatty acids from different sources in facilitating cardiovascular disease risk reduction. *Lipids Health Dis* 2014;13:99.
- Olenik A, Mahillo-Fernandez I, Alejandre-Alba N, *et al*. Benefits of omega-3 fatty acid dietary supplementation on health-related quality of life in patients with meibomian gland dysfunction. *Clin Ophthalmol* 2014;8:831–6.
- Epitropoulos AT, Donnerfeld ED, Shah ZA, *et al*. Effect of oral re-esterified omega-3 nutritional supplementation on dry eyes. *Cornea* 2016;35:1185–91.
- Mohammadpour M, Mehrabi S, Hassanzadeh N, *et al*. Effects of adjuvant omega-3 fatty acid supplementation on dry eye syndrome following cataract surgery: a randomized clinical trial. *J Curr Ophthalmol* 2017;29:33–8.
- Chi SC, Tuan HI, Kang YN. Effects of polyunsaturated fatty acids on nonspecific typical dry eye disease: a systematic review and meta-analysis of randomized clinical trials. *Nutrients* 2019;11:942.
- Wojtowicz JC, Butovich I, Uchiyama E, *et al*. Pilot, prospective, randomized, double-masked, placebo-controlled clinical trial of an omega-3 supplement for dry eye. *Cornea* 2011;30:308–14.
- Miljanovic B, Trivedi KA, Dana MR, *et al*. Relation between dietary n-3 and n-6 fatty acids and clinically diagnosed dry eye syndrome in women. *Am J Clin Nutr* 2005;82:887–93.
- Brignole-Baudouin F, Baudouin C, Aragona P, *et al*. A multicentre, double-masked, randomized, controlled trial assessing the effect of oral supplementation of omega-3 and omega-6 fatty acids on a conjunctival inflammatory marker in dry eye patients. *Acta Ophthalmol* 2011;89:e591–7.
- Deinema LA, Vingrys AJ, Wong CY, *et al*. A randomized, double-masked, placebo-controlled clinical trial of two forms of omega-3 supplements for treating dry eye disease. *Ophthalmology* 2017;124:43–52.
- Olenik A, Jimenez-Alfaro I, Alejandre-Alba N, *et al*. A randomized, double-masked study to evaluate the effect of omega-3 fatty acids supplementation in meibomian gland dysfunction. *Clin Interv Aging* 2013;8:1133–8.
- Bhargava R, Kumar P, Kumar M, *et al*. A randomized controlled trial of omega-3 fatty acids in dry eye syndrome. *Int J Ophthalmol* 2013;6:811–6.
- Kangari H, Eftekhari MH, Sardari S, *et al*. Short-term consumption of oral omega-3 and dry eye syndrome. *Ophthalmology* 2013;120:2191–6.
- Chinnery HR, Naranjo Golborne C, Downie LE. Omega-3 supplementation is neuro-protective to corneal nerves in dry eye disease: a pilot study. *Ophthalmic Physiol Opt* 2017;37:473–81.

- 16 Sheppard JD Jr., Singh R, McClellan AJ, *et al.* Long-term supplementation with n-6 and n-3 PUFAs improves moderate-to-severe keratoconjunctivitis sicca: a randomized double-blind clinical trial. *Cornea* 2013;32:1297–304.
- 17 Asbell PA, Maguire MG, Pistilli M, *et al.* n-3 fatty acid supplementation for the treatment of dry eye disease. *N Engl J Med* 2018;378:1681–90.
- 18 Akpek EK, Amscua G, Farid M, *et al.* Dry eye syndrome preferred practice pattern(R). *Ophthalmology* 2019;126:P286–P334.
- 19 Jones L, Downie LE, Korb D, *et al.* TFOS DEWS II management and therapy report. *Ocul Surf* 2017;15:575–628.
- 20 El Boustani S, Colette C, Monnier L, *et al.* Enteral absorption in man of eicosapentaenoic acid in different chemical forms. *Lipids* 1987;22:711–4.
- 21 Lawson LD, Hughes BG. Human absorption of fish oil fatty acids as triacylglycerols, free acids, or ethyl esters. *Biochem Biophys Res Commun* 1988;152:328–35.
- 22 Davidson MH, Johnson J, Rooney MW, *et al.* A novel omega-3 free fatty acid formulation has dramatically improved bioavailability during a low-fat diet compared with omega-3-acid ethyl esters: the ECLIPSE (Epanova(R)) compared to Lovaza(R)) in a pharmacokinetic single-dose evaluation) study. *J Clin Lipidol* 2012;6:573–84.
- 23 Dyerberg J, Madsen P, Moller JM, *et al.* Bioavailability of marine n-3 fatty acid formulations. *Prostaglandins Leukot Essent Fatty Acids* 2010;83:137–41.
- 24 Park JY, Kim BG, Kim JS, *et al.* Matrix metalloproteinase 9 point-of-care immunoassay result predicts response to topical cyclosporine treatment in dry eye disease. *Transl Vis Sci Technol* 2018;7:31.
- 25 Kim HR, Lee HK. The correlation between tear matrix metalloproteinase-9 concentration and clinical findings in dry eye disease. *J Korean Ophthalmol Soc* 2019;60:1140–7.
- 26 Iglesias E, Sajjani R, Levitt RC, *et al.* Epidemiology of persistent dry eye-like symptoms after cataract surgery. *Cornea* 2018;37:893–8.
- 27 Kasetsuwan N, Satitpitakul V, Changul T, *et al.* Incidence and pattern of dry eye after cataract surgery. *PLoS One* 2013;8:e78657.
- 28 Sajjani R, Raia S, Gibbons A, *et al.* Epidemiology of persistent postsurgical pain manifesting as dry eye-like symptoms after cataract surgery. *Cornea* 2018;37:1535–41.
- 29 Walker TD. Benzalkonium toxicity. *Clin Exp Ophthalmol* 2004;32:657.
- 30 Dawczynski J, Jentsch S, Schweitzer D, *et al.* Long term effects of lutein, zeaxanthin and omega-3-LCPUFAs supplementation on optical density of macular pigment in AMD patients: the LUTEGA study. *Graefes Arch Clin Exp Ophthalmol* 2013;251:2711–23.
- 31 Viau S, Maire MA, Pasquis B, *et al.* Efficacy of a 2-month dietary supplementation with polyunsaturated fatty acids in dry eye induced by scopolamine in a rat model. *Graefes Arch Clin Exp Ophthalmol* 2009;247:1039–50.
- 32 Andrade AS, Salomon TB, Behling CS, *et al.* Alpha-lipoic acid restores tear production in an animal model of dry eye. *Exp Eye Res* 2014;120:1–9.
- 33 Macsai MS. The role of omega-3 dietary supplementation in blepharitis and meibomian gland dysfunction (an AOS thesis). *Trans Am Ophthalmol Soc* 2008;106:336–56.
- 34 Tanaka H, Harauma A, Takimoto M, *et al.* Association between very long chain fatty acids in the meibomian gland and dry eye resulting from n-3 fatty acid deficiency. *Prostaglandins Leukot Essent Fatty Acids* 2015;97:1–6.
- 35 Chotikavanich S, de Paiva CS, Li de Q, *et al.* Production and activity of matrix metalloproteinase-9 on the ocular surface increase in dysfunctional tear syndrome. *Invest Ophthalmol Vis Sci* 2009;50:3203–9.