

The effect of femoral shortening in the treatment of developmental dysplasia of the hip after walking age

P. Castañeda¹
L. Moscona¹
K. Masrouha²

dysplasia of the hip after walking age. *J Child Orthop* 2019; 13:371-376. DOI: 10.1302/1863-2548.13.190029

Keywords: femoral shortening; outcome; developmental dysplasia of the hip; late presentation

Abstract

Purpose The optimal treatment for late-presenting developmental dysplasia of the hip (DDH) is controversial. High tension forces after hip reduction increase the pressure on the femoral head, potentially causing avascular necrosis. Femoral shortening (FS) is commonly used as a means to decrease the pressure on the femoral head. We examined the effect of FS on the outcomes of patients with late-presenting DDH.

Methods A total of 645 hips of a late-presenting DDH cohort treated with open reduction and iliac osteotomies were retrospectively reviewed; 328 hips had a FS performed (FS+) and 317 (FS-) had not. The mean age was 3.9 years (SD 1.55). We classified the hips with the Tönnis and International Hip Dysplasia Institute (IHDI) methods; and the Pediatric Outcomes Data Collection Instrument (PODCI), Iowa Hip Score (IHS) and Severin classification as outcome measurements.

Results The FS- group had higher scores in PODCI (median 95 points; interquartile range (IQR) 78 to 91) and IHS (median 91 points; IQR 64 to 88) than the FS+ group (PODCI: median 94 points; IQR 69 to 89 points; IHS: median 89 points; IQR 62 to 87). The mean Severin scores were similar (FS- 2.65; FS+ 2.5; $p = 0.93$) but the FS- group had higher rates of good and excellent outcomes (FS- 56%; FS+ 41%; $p < 0.00001$) and lesser dislocation rates (FS- 6%; FS+ 14%; $p = 0.16$).

Conclusion Although FS should be used when a hip cannot be reduced without undue tension, our results indicate that this procedure is not necessarily related to a better outcome.

Level of evidence: Therapeutic, Level III.

Cite this article: Castañeda P, Moscona L, Masrouha K. The effect of femoral shortening in the treatment of developmental

Introduction

Improvements in the diagnostic sensitivity of ultrasonography have decreased the rates of late developmental dysplasia of the hip (DDH), yet a large number of patients with DDH remain undiagnosed and untreated after walking age. While this is true globally, it is more concerning in developing countries, where children are frequently diagnosed well beyond walking age. The long-term results of surgical treatment for younger children are generally considered to be good.¹⁻⁵ However, there is no consensus regarding the ideal management of an older child with a dislocated hip and if surgical treatment produces worse results compared to no treatment.

Any kind of medical management should have the purpose of producing a better outcome when compared with the natural history of the condition being treated. The management of dislocated hips in older children has been fraught with complications including failure to achieve reduction, a high rate of avascular necrosis (AVN)^{6,7} and joint stiffness; while femoral head deformity, persistent subluxation and redislocation are also common. It is thought that AVN does not even occur in untreated patients, and in a natural history study of untreated patients by Crawford et al⁸ it was found that patients had very satisfactory clinical and functional results into middle, or even old, age.

One-stage correction of congenital dislocation of the hip has proven to yield satisfactory results in older children.⁹ However, the mean age at the time of surgery was five years and nine months, and the issue of determining an upper age limit for the safe reduction of a dislocated hip is still debated.

The principal problems encountered when treating these older hips are a high riding femoral head, contracted soft tissues, and a severely dysplastic acetabulum.¹⁰ These not only prevent reduction but can also result in increased pressure on the developing femoral head, leading to ischemia. Traction has been utilized as a means of maintaining perfusion¹⁰ but there is insufficient evidence to support its consistent use.¹¹ Femoral shortening (FS) has been proven to facilitate reduction and does not appear to increase the

¹ NYU Langone Orthopedic Hospital. Department of Pediatric Orthopaedic Surgery, New York, USA

² McMaster University Medical Center. Division of Orthopaedic Surgery, Hamilton, Ontario, Canada

Correspondence should be sent to P. Castañeda, NYU Langone Orthopedic Hospital. Department of Pediatric Orthopaedic Surgery. 301 East 17th St. New York, NY 10003, USA.
E-mail: pablo.castaneda@nyulangone.org

Table 1 Tönnis radiographic classification of developmental dysplasia of the hip

Tönnis classification	
I	The capital femoral ossification centre is medial to a vertical line through the superior acetabular rim (Perkins' or P-line)
II	Ossification centre is lateral to the vertical line but below the superior acetabular rim
III	Ossification centre is level with the superior acetabular rim
IV	Ossification centre is above the superior acetabular rim

prevalence of AVN of the femoral head.¹² The goal of operative treatment is achieving a stable, concentric reduction, with painless range of movement and function to obtain a durable hip into adulthood.¹¹⁻¹³ The procedure is, however, performed in a broad age range in the literature and multiple surgical procedures are added to FS as part of the treatment. Therefore, there are conflicting reports on the outcomes of those in whom a FS is performed. As such, we sought to examine the effect of FS on the outcomes of patients with late-presenting DDH.

Patients and methods

After approval by our institution's review board, we reviewed the hospital database to identify patients with unilateral DDH who had been diagnosed at 12 months of age. We scored the hips by the Tönnis (Table 1) and the International Hip Dysplasia Institute (IHDI) classifications.¹⁴⁻¹⁵ (Fig. 1)

We utilized the global function score of the Pediatric Outcomes Data Collection Instrument (PODCI) scale to determine the overall functional level of pediatric patients, whereas specific hip function and radiographic results were assessed with the Iowa Hip Score (IHS) and the Severin classification, respectively.¹⁶⁻¹⁸ All of the instruments have been previously validated in a similar population.¹⁹

All patients underwent one-stage open reduction and the majority had Salter (n = 421) or Pemberton (n = 106) osteotomies. A FS was added if the tension of the reduction was deemed excessive. Six paediatric orthopaedic surgeons were involved in the procedures. Patients were then assigned into two groups: those who had a FS performed (FS+) and those who had not (FS-). In all, 328 patients underwent a FS and 317 patients did not. The mean age of the FS+ cohort was 55 months (24 to 142), whereas for the FS- cohort mean age was 47 months (26 to 80).

We sought to have a reference of the effect of patient age on outcomes (i.e. the rate of favourable outcomes declines progressively in older patients) by measuring the Severin scores and the rate of subsequent surgery. Two sub-groups from the FS- cohort, based on patient age, were then sorted. After calculating the median age of the FS- cohort (M = 3.5 years), patients were assigned either to a group who were below the median age (n = 155;

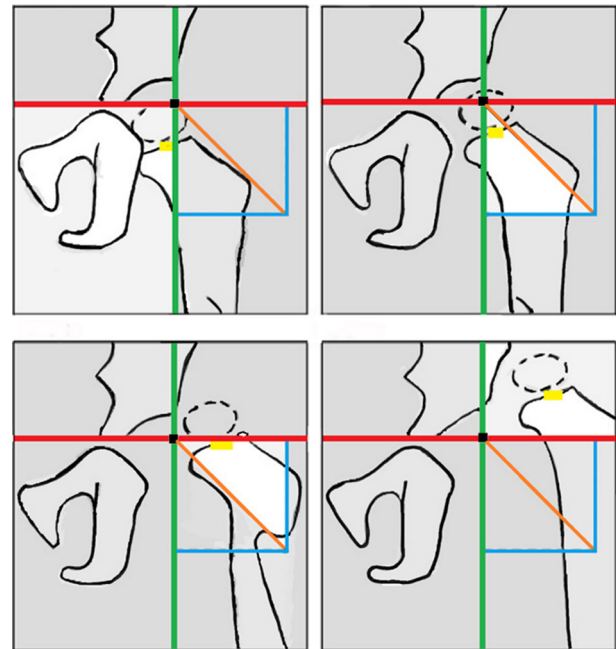


Fig. 1 International Hip Dysplasia Institute classification schematic drawing. Red, H or Hilgenreiner line runs horizontally from the most distal iliac ossification border at the triradiate cartilage; green, P or Perkins line runs perpendicular to the H-line at the superolateral margin of acetabular ossification; orange, D or diagonal line is a 45° diagonal line that separates the lower lateral quadrant into two equal sections; yellow, H-point is at the centre of the femoral metaphysis.

M = 2.36; SD 0.64; confidence interval (CI) 2.23 to 2.44) or above the median age (n = 162; M = 4.62; SD 1.06; CI 4.46 to 4.79). The mean follow-up was 8.2 years (6 to 14.8) and the follow-up rate was 100%. Patients with neuromuscular, syndromic or teratological hips were excluded.

Surgical technique

The operative protocol includes open reduction of the hip by a modified Smith-Petersen approach. A 5 cm incision is used 1 cm below the inguinal crease. Adductor longus and psoas releases are done if the abduction arc was < 45° or the hip was dislocatable at < 90° of extension, respectively. A derotational osteotomy is done if the hip was unstable in flexion, internal rotation and abduction.

The iliac apophysis is split and a sponge is placed in the external iliac wing. An interval between the rectus femoris and tensor fasciae latae is developed. Then the ilium is sharply divided. The rectus femoris and abductors are retracted to expose the capsule. A T-shaped capsulotomy with tag sutures placed at each corner of the capsule is used to aid joint exposure. After external rotation maneuvers, the ligamentum teres is released from the femoral head by tracing its acetabular origin. The psoas tendon is released in the lesser trochanter. A right-angle clamp is

Table 2 Patient characteristics

Characteristic	FS+	FS-	SD (CI) FS+; SD(CI) FS-	***Mann-Whitney U test; Fisher's exact test p-value
n (%)	328 (50.85)	317 (49.15)		
Mean age, yrs	4.74	3.5	1.69 (4.56 to 4.93); 1.44 (3.35 to 3.66)	< 0.0001
Sex, n (%)				0.74
Male	24 (7.3)	27 (8.5)	(0.05 to 0.11; 0.06 to 0.12)	
Female	304 (92.7)	290 (91.5)	(0.89 to 0.95; 0.88 to 0.94)	
Side (including bilateral cases), n (%)				0.28
Right	108 (33.3)	155 (48.9)	(0.28 to 0.38; 0.43 to 0.54)	
Left	220 (66.7)	162 (51.1)	(0.61 to 0.72; 0.46 to 0.57)	
Score (range)				
PODCI	91.31 (69 to 99)	93.38 (78 to 99)	6.75 (90.57 to 92.04); 4.93 (92.83 to 93.92)	< 0.0001
Iowa Hip Score	85.8 (62 to 96)	89.61 (64 to 97)	8.34 (84.70 to 86.51); 6.26 (88.91 to 90.29)	< 0.0001
Mean classification				
Tönnis	3.80	3.26	0.48 (3.75 to 3.85); 1.03 (3.15 to 3.38)	< 0.0001
IHDI	3.86	3.52	0.62 (3.79 to 3.93); 1.07 (3.41 to 3.64)	< 0.0001
Severin	2.52	2.53	1.36 (2.37 to 2.67); 1.44 (2.37 to 2.69)	0.9278
Mean follow-up of both groups, yrs (range)	8.2 (6.0 to 14.8)			
AVN	68 (53.5)	59 (46.5)		0.4965
Reintervention, n (%)	46 (14)	19 (6)		0.000706

*Mann-Whitney U test for means of independent groups; **Fisher's exact test for categorical variables; FS+, cohort treated with femoral shortening; FS-, cohort not treated with femoral shortening; CI, 95% confidence interval; PODCI, Pediatric Outcomes Data Collection Instrument; IHDI, International Hip Dysplasia Institute; AVN, avascular necrosis

placed in the transverse acetabular ligament to expose the acetabulum. After the pulvinar and transverse acetabular ligaments are released, attention is then turned into the tension of the reduction. We use a 'two fingers rule' to assess soft-tissue tension. If there is still excessive pressure, all the released structures are revised and FS incorporated into the derotational osteotomy. The amount of resection to produce shortening, typically 1 cm to 2 cm, is calculated from the overlap after performing the first femoral cut and reducing the femoral head. The degree of femoral anteversion is assessed by palpating the femoral neck axis through the wound and the femoral condyles. Derotation is then achieved by external rotation of the distal fragment until the patella is centered in the coronal plane. Varus is never intentionally produced. Capsulorrhaphy is completed with running absorbable suture by suturing the inferolateral and medial portions after excising the redundant superolateral capsule triangle.

Attention is then returned to the pelvis. After exposing the medial iliac wing, an osteotomy is completed with a Gigli saw between the anterosuperior and inferior iliac spines. Bone displacement is produced in a distal and lateral direction, followed by grafting of a triangular bone wedge from the iliac wing, and fixed with two 1.5-mm Kirschner-wires. Closure is achieved by repairing the iliac apophysis with the femorocutaneous nerve being protected.

We used a transarticular pin routinely to stabilize the hip reduction (n = 628; 97.4%). This was achieved with a percutaneous 2.0-mm Kirschner-wire through the greater trochanter, along the inferior third of the neck and into the non-weight-bearing area of the inferomedial aspect of the acetabulum.²⁰ The position of the wire was verified with fluoroscopic imaging.

Aftercare

The child was placed on a hip spica cast in 15° to 30° of flexion, 10° to 20° of abduction and 0° to 10° external rotation. The pin was removed at the three-week appointment and the cast was maintained for six weeks. A Batchelor or Petrie abduction cast were then used (n = 498; 77.3%) for six weeks, or the patients were taken out of the cast at six weeks (n = 147; 22.7%).

We did not prescribe any specific physical therapy, and gradual mobility was recovered with passive and active movements.

Statistical analysis

Statistical Package for the Social Sciences (SPSS) version 25 (IBM, Armonk, New York) and JMP version 14 (SAS Institute Inc., Cary, North Carolina) were used for analysis. After testing for the distribution of the samples, we employed the Mann-Whitney U-test to compare the means of independent groups and the Spearman ρ rho correlation test to quantify the association between continuous variables; in a non-Gaussian population. For categorical variables, differences between groups were assessed using Fisher's exact test. A p-value < 0.05 was considered to be significant.

Results

A total of 645 hips in 578 patients were studied. Demographic data is shown in Table 2. The mean follow-up was 8.2 years (6 to 14.8). All the procedures were performed in a single stage, except for 52 cases in which DDH was bilateral. In total, there were 127 (19.8%) hips with AVN. The rates of both groups were not significantly different (FS+ 68 (53.5%); FS- 59 (46.5%); p = 0.4965).

Table 3 Radiographic outcomes according to Severin score. Data presented as n (%)

Severin	FS+	FS-	Spearman rho test p-value*
1	56 (17)	86 (27)	0.14
2	79 (24)	123 (39)	0.04
3	7 (3)	-	N/A
4	79 (24)	89(28)	0.3
5	33 (10)	-	N/A
6	39 (12)	19 (6)	0.16

*Spearman ρ rho correlation test for continuous variables in non-Gaussian population; FS+, group treated with femoral shortening; FS-, group treated without femoral shortening; N/A, not available

Table 4 Clinical and radiographic outcomes according to Tönnis classification. Data presented as n (%)

Tönnis	FS+	FS-	Spearman rho test p-value*	PODCI	Iowa	Severin
1	0 (0)	44 (14)	N/A	97.3	96.7	2.1
2	13 (4)	6 (2)	0.4376	88/92	84/90	4/2
3	39 (12)	89 (28)	0.0174	92.1/86.5	90.3/84	2.12/3 (p = 0.04)
4	276 (84)	178 (56)	0.0002	93.7/89.6	90.2/86.4	2.50/2.8 (p = 0.003)

*Spearman ρ rho correlation test for continuous variables in non-Gaussian population; FS+, group treated with femoral shortening; FS-, group treated without femoral shortening; PODCI, Pediatric Outcomes Data Collection Instrument score; Iowa, Iowa Hip Score; Severin, Severin score; N/A, not available

After calculating the median age of the FS- group (M = 3.5 years; CI -0.23 to 0.41), we found no significant differences within the group in the outcomes of patients below the median age (FS-<) (n = 168; M = 2.38; SD 0.64; CI 2.29 to 2.48) and above the median age (FS->) (n = 149; M = 4.77; SD 0.98; CI 4.61 to 4.92) in Severin scores (FS- < (M = 2.57); FS- > (M = 2.42); p = 0.5875) or reintervention rates (FS- < (M = 2.57); FS- > (M = 2.42); p = 0.5875). The mean age between groups was significantly different (FS+ (M = 4.74); FS- (M = 3.50); p < 0.0001). The mean Severin score in Tönnis type IV hips (n = 454; FS+ (n = 276, M = 2.8); FS- (n = 178, M = 2.5); p = 0.003) (Tables 3 and 4), IHDI type IV hips (n = 575; FS+ (n = 315, M = 2.8); FS- (n = 260, M = 2.5); p = 0.02) and reintervention rates (FS+ (n = 46); FS- (n = 19); p = 0.0007) were all significantly different between the FS+ and FS- groups (Table 5). The Tönnis and IHDI classification schemes were strongly correlated ($\rho = 0.69$; p < 0.0001).

Discussion

The purpose of this study was to determine if the addition of FS to open reduction and innominate osteotomy in the treatment of patients with DDH produces a difference in outcomes when compared with those treated with open reduction and innominate osteotomy only.

Despite the critical role of FS in achieving satisfactory reduction if undue tension ensues in the operative

Table 5 Clinical and radiographic outcomes according to IHDI classification. Data presented as n (%)

IHDR	FS+	FS-	p-value*	PODCI	Iowa	Severin
1	13 (4)	47 (15)	0.0310	98.5/96.4	94.5/95.6	2/2.3
2	0 (0)	0 (0)	N/A	N/A	N/A	N/A
3	0 (0)	10 (3)	N/A	92	90	2.5
4	315 (96)	260 (82)	0.0105	92.4/88.7	89.7/84.5	2.4/2.8 (p = 0.02)

*Spearman ρ rho correlation test for continuous variables in non-Gaussian population FS+, group treated with femoral shortening; FS-, group treated without femoral shortening; PODCI, Pediatric Outcomes Data Collection Instrument score; Iowa, Iowa Hip score; Severin, Severin score; N/A, not available

treatment of dysplastic hips in older children, we did not observe improved results in children who had the osteotomy compared with those who did not. We hypothesize that one of the factors causing the FS+ group not achieving improved results was the limb-length discrepancy, and subsequently the residual limp that the shortening produces. The higher mean age of the FS+ group cannot be excluded as a key factor yielding poorer results; notwithstanding the fact that we did not consider age as an indication for shortening the femur and that we found no significant differences in the outcomes of the age subdivisions within the FS- cohort. However, we did have a low threshold to perform the procedure on IHDI or Tönnis type IV hips.

The rate of AVN in the study is similar to other reports^{21,22} and the association of FS with a higher rate of AVN has also been previously described.²³

A secondary objective of our paper was to determine if there is a preoperative classification system which carries prognostic value in the final outcome. Tönnis' classification, the most widely used classification, has prognostic impact,²⁴ but has also been criticized for depending on the presence of a central ossific nucleus and the difficulty in discerning between grades.²⁵ In an attempt to upgrade the scoring method²⁶ by improving its accuracy, the IHDI has developed a classification system²⁵ (Fig. 1) that has been reported as having a better inter- and intraobserver reliability than the Tönnis system²⁶ and being easier to use.²⁷ In our study, we noticed that hips fall into two main groups when scored with the IHDI classification: with 60 (9.3%) hips being considered type I, only ten (1.6%) hips considered type III and 575 (89.2%) hips being classified as type IV; this simplification has proved to be easy to use and have prognostic value; we do not believe that it should replace the Tönnis classification but can be used in conjunction when trying to compare similar preoperative conditions.

We believe that when a developmentally dislocated hip is encountered it should be evaluated on an individual basis and a number of factors should be taken into account including the child's age, the presence of

underlying pathology and the social and economic factors surrounding the case. Although it is impossible to determine a precise age for cutoff for attempting a reduction it should be noted that performing a FS does not compensate for neglected hips; the potential for remodelling is unpredictable after the age of three years.²⁸

The correlation of the age of detection of DDH and success in treatment has been widely published²⁹ but our results showed no significant difference in outcomes between both groups, provided they had a mean age that was significantly different. Perhaps the addition of FS conferred an improved outcome to the FS+ cohort, which in our country, where there is still relatively large number of patients who go undiagnosed into walking age, could prove to be a meaningful finding.

We detected several shortcomings in this study. After careful consideration, we decided to include every eligible patient consecutively instead of balancing the groups' mean age. As noted before, the mean age of the FS+ group is, perhaps inevitably, higher than that of the FS- group. Sankar et al³⁰ found patients older than three years 3.2-times more likely to require a FS osteotomy. Even if both groups had a mean age older than three years — a critical cutoff for acetabular remodelling — and our analysis within the FS- did not reveal worse outcomes in the older cohort, we recognize that the difference in the groups' mean age introduces a potential source of bias when comparing their results.

In addition, with six surgeons participating in this study, each having different perceptions of what 'high tension' constitutes after hip reduction, as well as individual technical variability; a potential source of bias is introduced.

Furthermore, the Severin classification has been pointed out as having poor interobserver agreement in some reports.³¹ This was perhaps offset by the fact that only one surgeon scored the outcomes of the reviewed hips. Moreover, the length of follow-up of our study precludes drawing bolder conclusions concerning the long-term influence of FS in dysplastic hips treated operatively.

Further research should be carried out into the long-term outcome of patients treated with a FS. The optimal age after which the addition of FS to the operative treatment of patients with DDH yields improved outcomes, remains to be determined.

Received 5 March 2019; accepted after revision 20 June 2019.

COMPLIANCE WITH ETHICAL STANDARDS

FUNDING STATEMENT

No benefits in any form have been received or will be received from a commercial party related directly or indirectly to the subject of this article.

OA LICENCE TEXT

This article is distributed under the terms of the Creative Commons Attribution-Non Commercial 4.0 International (CC BY-NC 4.0) licence (<https://creativecommons.org/licenses/by-nc/4.0/>) which permits non-commercial use, reproduction and distribution of the work without further permission provided the original work is attributed.

ETHICAL STATEMENT

Ethical approval: All procedures performed in studies involving human participants were in accordance with the ethical standards of the institutional and/or national research committee and with the 1964 Helsinki declaration and its later amendments or comparable ethical standards.

Informed consent: The research study and consent form have been explained clearly to the parent/legal guardian and study subject, if applicable. All questions have been satisfactorily answered. Verification of the understanding of the information conveyed was completed.

ICMJE CONFLICT OF INTEREST STATEMENT

None declared.

AUTHOR CONTRIBUTIONS

PC: Study design, Manuscript preparation, Performed surgeries and measurements.

LM: Study design, Manuscript preparation, Performed measurements, Statistical analysis.

KM: Performed measurements, Manuscript preparation.

REFERENCES

- Ashley RK, Larsen LJ, James PM.** Reduction of dislocation of the hip in older children: a preliminary report. *J Bone Joint Surg [Am]* 1972;54-A:545-550.
- Berkeley ME, Dickson JH, Cain TE, Donovan MM.** Surgical therapy for congenital dislocation of the hip in patients who are twelve to thirty-six months old. *J Bone Joint Surg [Am]* 1984;66-A:412-420.
- Coleman SS.** *Congenital Dysplasia and Dislocation of the Hip*. St. Louis: C. V. Mosby, 1978:95-154.
- Galpin RD, Roach JW, Wenger DR, Herring JA, Birch JG.** One-stage treatment of congenital dislocation of the hip in older children, including femoral shortening. *J Bone Joint Surg [Am]* 1989;71-A:734-741.
- Salter RB.** Innominate osteotomy in the treatment of congenital dislocation and subluxation of the hip. *J Bone Joint Surg [Br]* 1961;43-B:518-539.
- Gage JR, Winter RB.** Avascular necrosis of the capital femoral epiphysis as a complication of closed reduction of congenital dislocation of the hip. A critical review of twenty years' experience at Gillette Children's Hospital. *J Bone Joint Surg [Am]* 1972;54-A:373-388.
- Kalamchi A, MacEwen GD.** Avascular necrosis following treatment of congenital dislocation of the hip. *J Bone Joint Surg [Am]* 1980;62-A:876-888.
- Crawford AH, Mehlman CT, Slovek RW.** The fate of untreated developmental dislocation of the hip: long-term follow-up of eleven patients. *J Pediatr Orthop* 1999;19:641-644.
- Vallamshetla VRP, Mughal E, O'Hara JN.** Congenital dislocation of the hip. A re-appraisal of the upper age limit for treatment. *J Bone Joint Surg [Br]* 2006;88-B:1076-1081.
- Lai KA, Liu J, Liu TK.** Use of iliofemoral distraction in reducing high congenital dislocation of the hip before total hip arthroplasty. *J Arthroplasty* 1996;11:588-593.

11. **Schoenecker P, Strecker WB.** Congenital dislocation of the hip in children. Comparison of the effects of femora shortening and of skeletal traction in treatment. *J Bone and Joint Surg [Am]* 1984;66-A:21-27.
12. **Klisic P, Jankovic L.** Combined procedure of open reduction and shortening of the femur in treatment of congenital dislocation of the hips in older children. *Clin Orthop Relat Res* 1976; 119:60-69.
13. **MacEwen GD.** Treatment of congenital dislocation of the hip in older children. *Clin Orthop Relat Res* 1987;225:86-92.
14. **Narayanan U, Mulpuri K, Sankar WN, et al.** Reliability of a New Radiographic Classification for Developmental Dysplasia of the Hip. *J Pediatr Orthop* 2015;35(5):478-484.
15. **Tonnis D.** Indications and time planning for operative interventions in hip dysplasia in child and adulthood. *Z Orthop Ihre Grenzgeb* 1985; 123(4):458-461
16. **Daltroy L, Liang M, Fossel A, Goldberg M.** The POSNA pediatric musculoskeletal functional health questionnaire: report on reliability, validity, and sensitivity to change. *J Pediatr Orthop*. 1998;18(5):561-571.
17. **Larson CB.** Rating scale for hip disabilities. *Clin Orthop Relat Res*. 1963;31:85-93.
18. **Severin E.** Contribution to the knowledge of congenital dislocation of the hip joint. *Acta Chir Scand*. 1941;84(Suppl 63):1-142
19. **Pollet V, Van Dijk L, Reijman M, Castelein RMC, Sakkars RJB.** Long-term outcomes following the medial approach for open reduction of the hip in children with developmental dysplasia. *Bone Joint J* 2018;100-B:822-827.
20. **Castañeda P, Tejerina P, Nualart L, Cassis N.** The safety and efficacy of a transarticular pin for maintaining reduction in patients with developmental dislocation of the hip undergoing an open reduction. *J Pediatr Orthop* 2015;35:358-362.
21. **Nepple JJ, Martell JM, Kim YJ, et al.** Interobserver and intraobserver reliability of the radiographic analysis of femoroacetabular impingement and dysplasia using computer-assisted measurements. *Am J Sports Med* 2014;42:2393-2401.
22. **Sankar WN, Gornitzky AL, Clarke NMP, et al.** Closed reduction for developmental dysplasia of the hip: early-term results from a prospective, multicenter cohort. *J Pediatr Orthop* 2019;39:111-118.
23. **Spence G, Hocking R, Wedge JH, Roposch A.** Effect of innominate and femoral varus derotation osteotomy on acetabular development in developmental dysplasia of the hip. *J Bone Joint Surg [Am]* 2009;91-A:2622-2636.
24. **Kothari A, Grammatopoulos G, Hopewell S, Theologis T.** How does bony surgery affect results of anterior open reduction in walking-age children with developmental hip dysplasia? *Clin Orthop Relat Res* 2016;474:1199-1208.
25. **Narayanan U, Mulpuri K, Sankar WN, et al.** Reliability of a new radiographic classification for developmental dysplasia of the hip. *J Pediatr Orthop* 2015;35:478-484.
26. **Miao M, Cai H, Hu L, Wang Z.** Retrospective observational study comparing the international hip dysplasia institute classification with the Tonnis classification of developmental dysplasia of the hip. *Medicine (Baltimore)* 2017;96:e5902.
27. **Ramo BA, De La Rocha A, Sucato DJ, Jo CH.** A new radiographic classification system for developmental hip dysplasia is reliable and predictive of successful closed reduction and late pelvic osteotomy. *J Pediatr Orthop* 2018;38:16-21.
28. **Shin CH, Yoo WJ, Park MS, et al.** Acetabular remodeling and role of osteotomy after closed reduction of developmental dysplasia of the hip. *J Bone Joint Surg [Am]* 2016;98:952-957.
29. **Kotlarsky P, Haber R, Bialik V, Eidelman M.** Developmental dysplasia of the hip: what has changed in the last 20 years? *World J Orthop* 2015;6:886-901.
30. **Sankar WN, Tang EY, Moseley CF.** Predictors of the need for femoral shortening osteotomy during open treatment of developmental dislocation of the hip. *J Pediatr Orthop* 2009;29:868-871.
31. **Ward WT, Vogt M, Grudziak JS, et al.** Severin classification system for evaluation of the results of operative treatment of congenital dislocation of the hip. A study of intraobserver and interobserver reliability. *J Bone Joint Surg [Am]* 1997;79-A:656-663.