

Catheter ablation induced phrenic nerve palsy by pulsed field ablation—completely impossible? A case series

Francesco Pansera , Stefano Bordignon, Fabrizio Bologna, Shota Tohoku, Shaojie Chen, Lukas Urbanek, Boris Schmidt, and Kyoung-Ryul Julian Chun*

Agaplesion Markus Krankenhaus, Cardioangiologisches Centrum Bethanien, Wilhelm-Epstein-Straße 4, 60431 Frankfurt am Main, Germany

Received 7 December 2021; first decision 5 January 2022; accepted 30 August 2022; online publish-ahead-of-print 6 September 2022

Background

Pulsed field ablation (PFA) is a new feasible and safe method for the ablative treatment of cardiac arrhythmias, such as atrial fibrillation (AF). Through the use of electric fields, it causes pore-like openings in the cell's wall, leading to cell death. The most appealing characteristic of this new technique is its selectivity for cardiomyocytes and consequently its low risk of collateral damage to extracardiac tissues. We present three cases of a PFA-induced transient phrenic nerve (PN) injury documented during pulmonary vein isolation (PVI).

Case summaries

Three patients aged 55–81 years underwent PFA for symptomatic AF. Cases 1 and 3 were affected by paroxysmal AF without evidence of structural heart disease. Case 2 had persistent AF and ischaemic cardiomyopathy with preserved ejection fraction. We observed a transient right hemidiaphragm palsy during the delivery of impulses in the right superior pulmonary vein (Cases 1 and 2) and in the right inferior pulmonary vein (Case 3). The palsy lasted <1 min and was followed by spontaneous full recovery in all cases.

Discussion

Transient PN dysfunction can be observed following PFA in AF ablation. According to our initial experience, a full recovery of the PN function can be expected within seconds. We hypothesize a hyperpolarization of neuronal cells or a depletion of acetylcholine in the motoric endplate to explain this event. Further studies are required to understand the exact pathophysiological mechanism.

Keywords

Atrial fibrillation • Pulsed electric ablation • Phrenic nerve dysfunction • Pulmonary veins isolation • Case report • Case series

ESC Curriculum

5.3 Atrial fibrillation • 5.4 Atrial flutter • 5.5 Supraventricular tachycardia

Learning points

- Pulsed field ablation is a new ablative technique highly selective for cardiomyocytes, nevertheless transient phrenic nerve palsy can be observed. Hyperpolarization of neuronal cells or depletion of acetylcholine in motoric endplate are possible explanations but further studies are needed to clarify this phenomenon.
- The phrenic palsy was followed by full spontaneous recovery with a few seconds, confirming the safety of this new technique.

* Corresponding author: Tel: +39/3476091087, Email: j.chun@ccb.de

Handling Editor: Richard Ang

Peer-reviewers: Stefan Simovic; Robert Schönbauer

Compliance Editor: Daniel Tardo

Supplementary Material Editor: Jonathan Senior

© The Author(s) 2022. Published by Oxford University Press on behalf of the European Society of Cardiology.

This is an Open Access article distributed under the terms of the Creative Commons Attribution-NonCommercial License (<https://creativecommons.org/licenses/by-nc/4.0/>), which permits non-commercial re-use, distribution, and reproduction in any medium, provided the original work is properly cited. For commercial re-use, please contact journals.permissions@oup.com

Introduction

Pulsed field ablation (PFA) technology is also called irreversible electroporation (IRE) and offers some potential advantages over traditional thermal ablative techniques.¹ A major limitation of common ablation technologies refers to the non-selective nature of the destructive process with potential injuries to neighbouring structures. In particular, phrenic nerve (PN) palsy (PNP) is a typical complication during cryoballoon ablation. Conversely, IRE can create irreversible lesions, specifically in the myocardium, with a low incidence of damage to the extracardiac structures.² This new modality consists of microsecond electrical pulses applied across the cells to generate an electric field, causing the formation of permanent defects in the cell membrane. The permanent permeability of the cell membrane leads to changes in the cells' homeostasis and the death of the cell. Every tissue has a different specific field threshold that induces necrosis. Cardiomyocytes have the lowest threshold value (400 V/cm), and this may constrain collateral damage (e.g. oesophagus or PN). There is no coagulative necrosis, but evidence of myofiber disruption and inflammation, resulting in a more homogenous fibrotic remodelling than radiofrequency ablation. In addition, IRE is able to induce faster cell necrosis and therefore, the time of the procedures is shorter in comparison with other standard ablative techniques.³ Although nerve damage is not an expected complication during PFA, we can report the first three cases of transient self-recovering PNP related to this technique.

We performed pulmonary vein isolation (PVI) in the following cases with the PFA technique using our standard approach. The ablations were performed under conscious sedation with a bolus of midazolam and fentanyl followed by a continuous infusion of propofol, according to the position paper of the German Society of Cardiology on cardioanalgesedation.⁴ After a single transseptal puncture, we performed the pulmonary veins angiography with a multipurpose catheter. The Farawave ablation catheter was then positioned at all PVs ostia: left superior PV, left inferior PV, right inferior PV (RIPV), right superior PV (RSPV). Eight impulses were delivered for each pulmonary vein ostium. We isolated each vein during the first PFA erogation (2.0 kV) that was followed by seven more applications to reinforce the result (protocol 1 + 7). For each application, a train of five consecutive waveforms was delivered for a total of 2,5 application time. In each pulmonary vein ostium, we used two kinds of catheter configurations: four impulses were delivered in the 'flower' configuration, in which the catheter shape is fully open, and four impulses were delivered in the basket configuration, in which the catheter shape was partially closed (*Figure 1*). Pericardial effusion was excluded after the procedure and the access site was closed with a 'Figure 8' suture in all cases.

Timeline

Case presentations

Case 1

A 55-year-old male was referred to our department for symptomatic paroxysmal AF. His body mass index (BMI) was 22 (190 cm × 78 kg) with no history of previous heart disease. The patient had a good clinical status with no findings of heart failure. Arterial blood pressure was 120/80 mmHg at admission. The echocardiogram showed a structurally normal heart, with preserved ejection fraction (EF) (60%), no significant valvular diseases and the left atrial diameter was 44 mm. The patient was treated with beta-blockers and no other antiarrhythmic drugs. The patient had a low cardioembolic risk (CHA2DS2-VASc Score 0) and he was treated with low-molecular-weight-heparin for 3 weeks before the ablation and for 2 months after the ablation.

During the first application of PFA at the RSPV with 35 mm Farawave catheter, we noted a loss of function of the right sided PN (*Figure 2A and B; Supplementary material online, Videos 1 and 2*). We still completed all planned energy deliveries to the RSPV checking fluoroscopically the diaphragmatic movements after each application. We observed full recovery 6 s after the last application (*Figure 2C and D; Supplementary material online, Video 3*), therefore, PNP lasted ca. 40 s overall.

The procedure ended without side effects. The PN dysfunction was resolved completely and the pulmonary veins were all correctly electrically isolated. The procedure took 36 min. After the ablation, the same medical therapy was prescribed.

Case 2

A 68-year-old male was referred to our department for symptomatic persistent AF. His BMI was 26 (178 cm × 83 kg). He was affected by arterial hypertension and Type II diabetes, complicated by peripheral neuropathy. He had a history of coronary artery disease with previous percutaneous coronary revascularization. The patient had no signs and symptoms of congestive heart failure and arterial blood pressure was 140/80 mmHg at admission. The echocardiogram showed a preserved EF (55%) without abnormalities of the regional wall motion and no significant valvular diseases. His left atrial size was 41 mm. The patient was treated with beta-blockers, amiodarone, and apixaban.

We performed PVI via the PFA technique with our standard approach. In this case, we used the 31 mm Farawave catheter, eight impulses were delivered (1 + 7) at all PVs that were isolated after the first impulse (2.0 kV). During the employment of PFA at the RSPV, we noted the same transient palsy of the right PN, self-recovering after few seconds. The procedure was successful and no complications were observed. Amiodarone was disrupted after the ablation.

Patient number	Before the procedure	During the procedure
1	The patient is a 55-year-old male affected by symptomatic paroxysmal atrial fibrillation (AF). Pulmonary vein isolation with PFA was performed.	Transient right hemidiaphragm palsy was observed after the first application of the impulses at the RSPV. We still continue to deliver the eight planned impulses. We observed the full recovery of the hemidiaphragm function 6 s after the last application. The PNP lasted overall around 40 s.
2	The patient is a 68-year-old male with symptomatic persistent AF and ischaemic heart disease. Ablation of AF was performed with the PFA technique.	During the delivery of the pulses at the RSPV, a transient PN dysfunction of few seconds occurred, followed by spontaneous recovery.
3	An 81-year-old male affected by symptomatic paroxysmal AF underwent isolation of the pulmonary vein with PFA.	A transient PN dysfunction was observed during the erogation of impulses at the RIPV. In this case, the phrenic palsy lasted few seconds as well, followed by spontaneous full recovery.

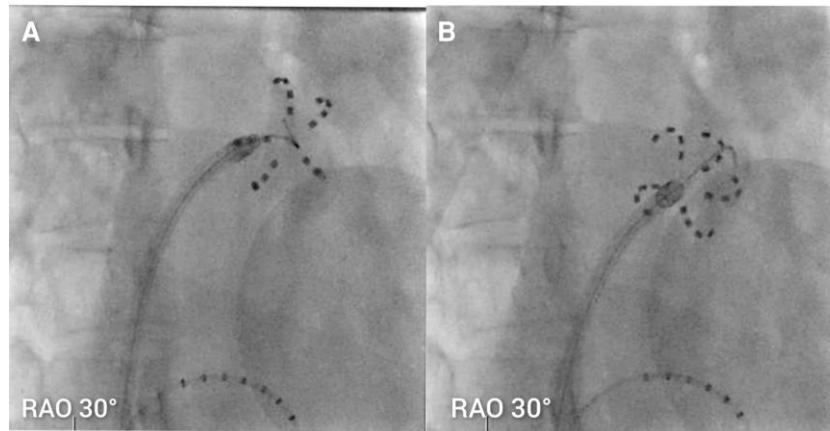


Figure 1 Farawave catheter in 'basket' (A) and 'flower' (B) configuration at pulmonary vein ostium.

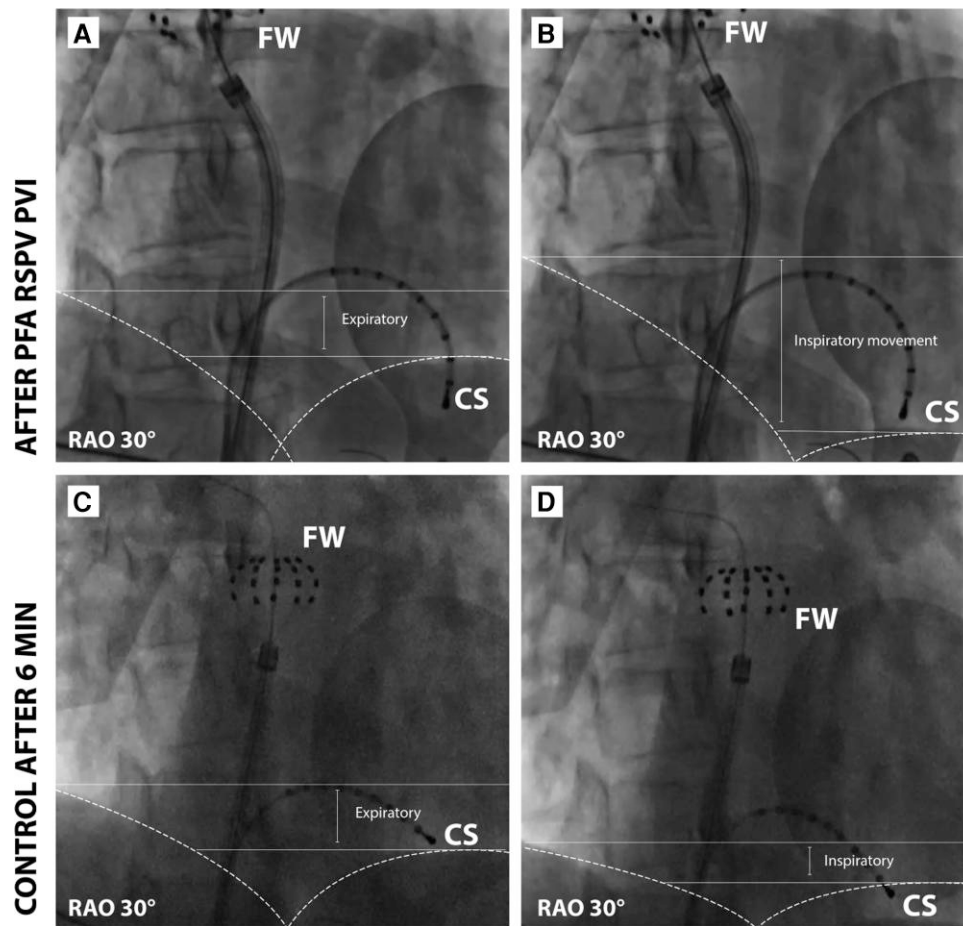


Figure 2 (A and B) Paradoxical movement of the right hemidiaphragm immediately after the application of the impulses. (C and D) Right and left hemidiaphragms contract synchronously after 6 s. FW, Farawave Catheter, CS Inquiry Catheter 10 mm in coronary sinus.

Case 3

A 81-year-old male with no history of heart disease was referred to our department for symptomatic paroxysmal AF. His BMI was 24 (192 cm × 87 kg). The patient had no signs and symptoms of congestive heart failure and arterial blood pressure was 130/70 mmHg at admission. His echocardiogram showed a structurally normal heart (the EF of the left ventricle was 60%) and left atrial diameter was 42 mm. The patient was treated with beta-blockers and edoxaban.

We performed PVI with the PFA technique according to our standard approach. With a 35 mm Farawave catheter, four impulses in the flower configuration and four in the basket configuration that were isolated after the first impulse (2.0 kV) were delivered in each pulmonary vein. During the delivery of pulses at the RIPV, a transient palsy of the right PN was documented, followed by a full recovery within few seconds. The same medical therapy was continued after the ablation.

Discussion

Pulsed field ablation induces selective myocytes necrosis, without collateral damages to other tissues such as the oesophagus, the PN, or the endothelial cells.^{2,3} In our case, we clearly documented a transient PN dysfunction causing a transient paresis of the right hemidiaphragm. This effect would not be expected, considering that application of PFE is highly selective for cardiomyocytes.

The response of nerve tissue to the IRE has not been clearly defined. In the last decade, different scientists studied the effects of IRE on nerve tissue. Onik et al.⁵ in their study on canine models, found that nerves were apparently preserved after the application of IRE pulses. Weil et al.⁶ performed a pilot study in this field with electrophysiological, histological, and functional analysis on sciatic nerve models of rats. They showed that nerves treated with IRE were damaged after immediate direct injury with a full recovery after 2 weeks. The pathophysiological changes were typical Wallerian degeneration and regeneration of axons.

According to the Seddon's classification, the mildest level of peripheral nerve damage is 'neurapraxia' (characterized by focal segmental demyelination at the site of injury without disruption of axon continuity and its surrounding connective tissues) that requires at least several weeks to obtain a complete functional recovery.⁷

In our case, the dysfunction was transient and passed within few seconds, so we assume a different pathophysiological mechanism based on this phenomenon.

We assume that the transient nerve dysfunction could be related to hyperpolarisation of the nerve. This hypothesis is sustained by previous experimental evidence. Rems et al. showed that IRE and its electric field create not only pores in the membrane lipid bilayer, but also electroconformational changes of the voltage-gated ion channels. An ionic imbalance through the membrane cell occurs, which later becomes hyperpolarized and unable to conduct action potentials (AP).⁸


A second possible explanation could be the effect of IRE on the motoric endplate. Conventionally, upon the arrival of an AP at the axon terminal, voltage-dependent calcium channels open and calcium flows from the extracellular fluid into the cell. This intracellular current triggers a biochemical cascade that induces the release of acetylcholine into the synaptic cleft that depolarizes the muscle fibres, leading to force generation. In this scenario, a transient perturbation of the Ca²⁺-ions flow induced by the electric field of IRE could lead to a decreased release of acetylcholine and to the subsequent inability to generate an effective muscular activation.⁹

Some authors suggested to test the PN by stimulation of the SVC before, during, and after performing the PFA application at the septal pulmonary veins.¹⁰ Due to the very short application time, this monitoring of the PN function was not performed in our series.

Conclusions

Transient PN dysfunction can be observed following PFA in AF ablation. According to our initial experience, a full recovery of the PN function can be expected within seconds. Pulsed field ablation appears to be a safe technique without long-term sequelae. Further studies and experience are needed to better evaluate the risk of PN damage as a clinical complication.

Lead author biography



Francesco Pansera is a cardiologist fellow at CCB in Markus Agaplesion Krankenhaus in Frankfurt am Main, Germany.

Supplementary material

Supplementary material is available at *European Heart Journal—Case Reports* online.

Acknowledgements

We thank the external reviewers for their helpful comments.

Slide sets: A fully edited slide set detailing this case and suitable for local presentation is available online as [Supplementary data](#).

Consent: The authors confirm that written consent for submission and publication of this case report, including images and associated text, has been obtained from the patients in line with the COPE guidance.

Conflict of interest: None declared.

Funding: None declared.

References

- Caluori G, Odehmalova E, Jadczyk T, Pesl M, Pavlova I, Valikova L, et al. AC pulsed field ablation is feasible and safe in atrial and ventricular settings: a proof-of-concept chronic animal study. *Front Bioeng Biotechnol* 2020;**8**:52357.
- van Driel VJHM, Neven K, van Wessel H, Vink A, Doevendans P, Wittkamp F. Low vulnerability of the right phrenic nerve to electroporation ablation. *Heart Rhythm* 2015;**12**. PMID 25998897. doi:10.1016/j.hrthm.2015.05.012.
- Reddy VY, Anic A, Koruth J, Petru J, Funasako M, Minami K, et al. Pulsed field ablation in patients with persistent atrial fibrillation. *J Am Col Cardiol* 2020;**76**:9.
- Tilz RR, Chun KRJ, Deneke T, Kelm M, Piorokowsky C, Sommer P, et al. Position paper of the German society of cardiology on cardioanalgesedation: focus on interventions in rhythmology. *Kardiologie* 2017;**11**:369–382.
- Onik G, Mikus P, Rubinsky B. Irreversible electroporation: implications for prostate ablation. *Technol Cancer Res Treat*;6:295–300.
- Wei L, Qingyu F, Zhenwei J, Xiuchun Q, Zhao L. The effects of Irreversible electroporation on Nerves. *PLoS One* 2011;**6**:e18831. doi:10.1371/journal.pone.0018831.
- Cuello CMC, De Jesus O, *Neurapraxia*. StatPearls [Internet]. PMID: 32809336 Bookshelf ID: NBK560501. Treasure Island, FL: StatPearls Publishing; 2022.
- Rems L, Kasimova MA, Testa I, Delemotte L. Pulsed electric fields create pores in the voltage sensors of voltage-gated ion channels. *Biophys J* 2020; **119**:190–205.
- Joshi RP, Mishra A, Xiao S, Pakhomov A. Model study of time-dependent muscle response to pulsed electrical stimulation. *Bioelectromagnetics* 2010;**31**:361–370.
- Verma A, Boersma L, Haines DE, Natale A, Marchlinski FE, Sanders P, et al. First-in-human experience and acute procedural outcomes using a novel pulsed field ablation system: the PULSED AF pilot trial. *Circ Arrhythm Electrophysiol* 2022;**15**:e010168.