

Revision hip arthroplasty as a treatment of Vancouver B3 periprosthetic femoral fractures without bone grafting

Jia-Qi Wang, You-Shui Gao¹, Jiong Mei, Zhi-Tao Rao, Shu-Qing Wang

ABSTRACT

Background: It is conventionally considered that bone grafting is mandatory for Vancouver B3 periprosthetic femoral fractures (PFF) although few clinical studies have challenged the concept previously. The aim of the current study was to investigate the radiographic and functional results of Vancouver B3 PFF treated by revision total hip or hemiarthroplasty (HA) in combination with appropriate internal fixation without bone grafting.

Materials and Methods: 12 patients with Vancouver B3 PFF were treated by revision THA/HA without bone grafting between March 2004 and May 2008. There were nine females and three males, with an average age of 76 years. PFFs were following primary THA/HA in nine patients and following revision THA/HA in three. Postoperative followup was 5.5 years on average (range, 3.5-6.5 years). At the final followup, radiographic results were evaluated with Beals and Tower's criteria and functional outcomes were evaluated using the Merle d'Aubigné scoring system.

Results: All fractures healed within an average of 20 weeks (range, 12-28 weeks). There was no significant deformity and shortening of the affected limb and the implant was stable. The average Merle d'Aubigné score was 15.8. Walking ability was regained in 10 patients without additional assistance, while 2 patients had to use crutches. There were 2 patients with numbness of lateral thigh, possibly due to injury to the lateral femoral cutaneous nerve. There were no implant failures, dislocation and refractures.

Conclusions: Revision THA/HA in combination with appropriate internal fixation without bone grafting is a good option for treatment of Vancouver B3 periprosthetic femoral fractures in the elderly.

Key words: Periprosthetic femoral fractures, hemiarthroplasty, total hip arthroplasty, internal fixation

INTRODUCTION

Advances in techniques of hip arthroplasty, including total hip arthroplasty (THA) and hemiarthroplasty (HA), have brought painless and functional activities for patients with degenerative, developmental and traumatic diseases of the hip joint. The number of patients with THA and HA is growing, the lifespan is increasing and the age

of patients is becoming younger, which results in increased rate of revision surgery. Currently periprosthetic femoral fractures (PFF) are the most frequent cause for a revision hip arthroplasty.^{1,2} A previous report from Mayo Clinic indicated that the incidence of PFF after primary THA was 1.1% and reached 4% for revision THA.³ In one 10 year followup study, Lindahl and associates found that the overall incidence of PFF was 0.64% on average.⁴

Departments of Orthopedic Surgery, Tongji Hospital, Tongji University, Shanghai 200065, ¹Shanghai Sixth People's Hospital, Shanghai Jiao Tong University, Shanghai 200233, China

Address for correspondence: Dr. You-Shui Gao,
Department of Orthopedic Surgery, Shanghai Sixth People's Hospital,
Shanghai Jiao Tong University, Shanghai 200233, China.
E-mail: gaoyoushui@gmail.com

The development of Vancouver classification system has benefited worldwide communications on the evaluation of PFF. Reliability and validity of the Vancouver classification has been confirmed, implant stability and bone quality was emphasized in the Vancouver classification system.⁵ Vancouver B3 fractures are those occurring around the stem or extending just below it in which the femoral component is loose and there is severe bone stock loss.² The treatment algorithm in these patients varies and is mostly influenced by the age and activity level of the patient.⁶ It is inevitable for Vancouver B3 fractures advancing to revision hip arthroplasty due to loosening of the femoral stem. Poor bone stock of Vancouver B3 fractures usually determines that bone grafting

Access this article online	
Quick Response Code:	Website: www.ijoonline.com
	DOI: 10.4103/0019-5413.118199

is recommended in addition to revision THA/HA. However, it is still a controversy whether bone grafting is essential, due to the development of novel implants and better concepts in internal fixation. In a recent report by Neumann *et al.*, the technique using a modular cementless stem without allografting is reliable for Vancouver B2 and B3 PFF.⁷

The aim of the current study is to retrospectively investigate the radiographic and functional results of Vancouver B3 PFF treated by our surgical technique. The study was approved by the local ethics committee.

MATERIALS AND METHODS

12 patients with Vancouver B3 PFF were treated by revision THA/HA without bone grafting between March 2004 and May 2008. The pattern of fractures was confirmed by radiographic features of deficient bone stock and loose femoral stem. There were nine females and three males, with an average age of 76 years (range, 69-88 years). PFFs were following primary THA/HA in nine patients, with an average interval from primary surgery to PFF of 10.1 years (range, 7-22 years). Three PFFs were following revision THA/HA, with the latest surgery-to-PFF interval of 4.5 years (range, 2-9 years). All fractures occurred following low energy falls [Table 1]. Eleven patients had abnormal gait posture before registration and 10 of them had confirmed loosening of the implants previously. However, all patients got slight moderate inguinal pain and restricted motion of the hip joint preoperatively.

Operative procedure

The patients were operated under general anesthesia

in supine position. The direct lateral approach was employed. It was not difficult to remove acetabular cup and loose femoral stem intraoperatively. Aseptic lymphocyte-dominated vasculitis-associated lesion (ALVAL) was not found in patients with metal prosthesis. However, abductor insufficiency was quite commonly seen. The fracture was repositioned and maintained using bone clamps. Cerclage was helpful to maintain proximal anatomy of the femur. The acetabular cup was impacted first in revision THA. Consequently, the trial femoral stem was used and the hip was reduced. Next, the length and alignment of the limb as well as the stability of the prosthesis were carefully evaluated. The original femoral stem was inserted through the fracture after a satisfactory hip reduction was restored. The longest stem was preferred to achieve the greatest stability and decrease secondary complications. Then, the clamps were removed and the fracture line was rechecked. For fractures near the trochanteric region, a great trochanter hook-plate and cable system was used to stabilize the fracture. Else, additional cerclage technique was employed to stabilize femur and the prosthesis. In three patients, internal fixation was not used due to distal stability and simple fracture pattern. Bone grafting was not employed. Intraoperatively, reaming and primary hematoma acted as bone graft material. Revision THA and HA were both performed on six patients each. The operation took an average time of 140 minutes (range 120-200 minutes). Average blood loss was 350 ml (range 300-600 ml).

Patients were allowed to take non weight bearing activities postoperatively. The time to bear weight was dependent on the physical status of the patient. The average partial

Table 1: Demographic characteristics of patients

Patient	Gender	Age (years)	Index operation	Cause of fracture	Interval between hip arthroplasty and fractures (years)	Operative treatment		Complications	Followup (years)
						Revision	Internal fixation		
1	M	83	Revised HA, cement	Falling	2	Stem	Cerclage	None	4.5
2	M	69	THA, cementless	Falling	11	THA	Cerclage	None	5
3	F	71	THA, cementless	Falling	22	THA	Cerclage+Plate	None	6
4	M	76	HA, cementless	Falling	9	Stem	Cerclage	None	6.5
5	F	77	THA, cementless	Falling	7	THA	Cerclage	Damage of LFCN	5
6	F	75	THA, cementless	Spontaneous	7	Stem	None	None	5.5
7	F	88	HA, cementless	Spontaneous	8	THA	None	None	3.5
8	F	80	THA, cementless	Falling	10	Stem	None	None	5
9	F	78	HA, cementless	Falling	8	Stem	Cerclage	Damage of LFCN	6
10	F	69	Revised THA, cement	Spontaneous	3	THA	Cerclage	None	6
11	F	77	Revised THA, cementless	Spontaneous	9	THA	Cerclage	None	6.5
12	F	71	HA, cementless	Falling	10	Stem	Cerclage	None	6

M=Male, F=Female, HA=Hemiarthroplasty, THA=Total hip arthroplasty, LFCN=Lateral femoral cutaneous nerve

weight bearing time was 12 days (range, 3-28 days). Time to full-weight bearing averaged 4 months postoperatively. At the final followup, radiographic results were evaluated using the Beals and Tower's criteria^{8,9} and functional outcomes were evaluated by the Merle d'Aubigné scoring system.

RESULTS

Postoperative followup averaged 5.5 years (range, 3.5-6.5 years). All fractures came to primary healing at an average of 20 weeks (range, 16-28 weeks). There was no deformity or significant shortening of the affected limb and the implant was stable [Figure 1]. According to Beals and Tower's criteria, the radiographic outcome was excellent. In terms of function, the average Merle d'Aubigné score was 15.8. Walking ability was regained in 10 patients without additional assistance, while two patients had to use crutches. There were two patients with numbness of the lateral thigh, possibly due to an injury of the lateral femoral cutaneous nerve (LFCN). There were no implant failures, dislocations or refractures. All patients were satisfied about the functional results [Figure 2].

DISCUSSION

For Vancouver B3 PFF, revision THA/HA is valid to restore a functional hip joint due to the presence of prosthetic loosening. There are various implants available for revision surgery, including cementless, cemented and modular dependent on the fracture pattern, treatment expectancy and physiological status of patient.¹⁰⁻¹² Cemented prosthesis is rarely used currently as nonunion may occur following cement leak. Extensive hydroxyapatite-coated

and long-stem prosthesis is preferred for Vancouver B3 fractures. Moreover, the prosthesis could be designed in a modular manner, which is beneficial for individual variance. The optimal matching of bone and the prosthesis is the prerequisite for success of the procedure. The technology of designing and manufacturing of various prosthesis is valuable for the restoration of distal stability; meanwhile, cerclage stabilization is helpful for maximal matching of proximal femur and prosthesis. Undoubtedly, to achieve stable femur-prosthesis structure is a matter of prime importance in revision surgery for PFF.

Traditionally, it is considered that bone grafting is critically important for Vancouver B3 fractures due to poor bone quality.^{13,14} Structural and unstructural bone grafting is usually recommended for periprosthetic femoral fractures, especially when significantly poor bone quality is confirmed. Allografting with bone plate is commonly used for Vancouver B3 fractures, to restore a stable bone-implant construct. Grafting of autologous cancellous bone and bone substitute is helpful for fracture union as well. However, incidental complications might accompany bone grafting. For allogenic bone grafting there is always a chance of transmission of pathogens besides the long time required for creeping substitution within the allograft. Allografts are not always available in developing countries. Autologous bone graft, which is usually harvested from the iliac crest, is an alternative means of available graft. However, the volume of cancellous bone from the ilium is limited. Intraoperative harvesting of iliac bone prolongs the operative and anesthetic time, which might increase perioperative risks in very old patients. Until now, there is a lack of randomized controlled studies to support bone grafting for Vancouver B3 fractures in terms of better

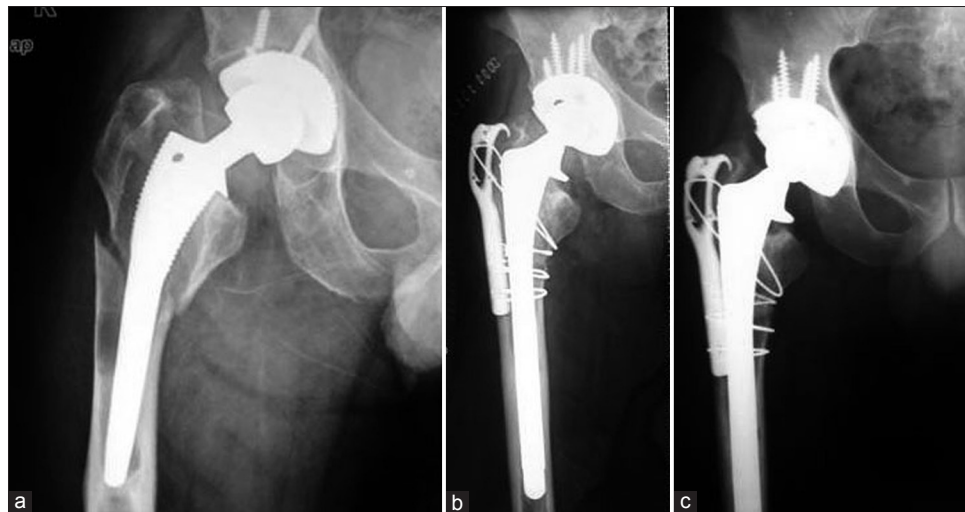


Figure 1: Anteroposterior radiograph of the hip (R) showing (a) periprosthetic femoral fracture, with loosening of the femoral stem and acetabular cup, breakage of screws as well as significant loss of bone mass. (b) The fracture was treated by revision total hip arthroplasty and hook-plate fixation without bone grafting. (c) Bone healing was achieved 16 weeks postoperatively

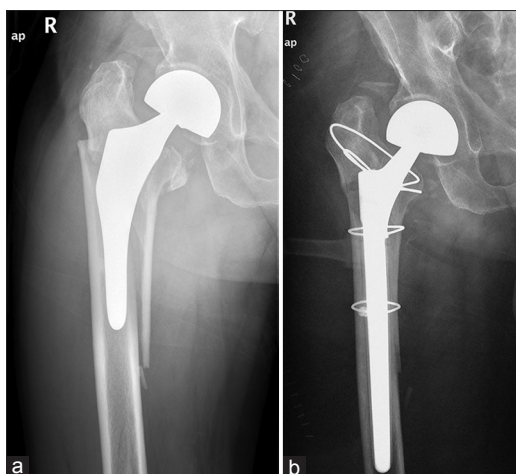


Figure 2: X-ray of right hip joint (anteroposterior view) showing (a) Vancouver B3 periprosthetic femoral fracture in a 76-year-old male patient (b) A revision hemiarthroplasty was performed and multiple cerclage were used to stabilize proximal fracture of the femur

clinical results and lower complications. In a recent study by Neumann et al.⁷, 53 hips with B2 and B3 fractures were treated using a distally fixed modular femoral stem without allografting and the technique was reliable with significant improvement of the Harris hip score and lower incidence of postoperative complications. Berry treated eight patients with Vancouver B3 fractures with a fluted tapered modular Ti grit-blasted femoral implant without strut allografting.¹⁵ Another investigation by Maury et al.¹⁶ found that the use of a proximal allograft for B3 fractures could provide a satisfactory result in terms of pain relief and functional outcome at 5 years. Biological options are an alternative method to enhance bone mass, however, they are not routinely employed.¹⁷

The principal aim of bone grafting is to supplement the stability of the bone-prosthesis complex, as well as to improve bone stock of the proximal femur. In our study, stable bone-prosthesis construct was achieved through intramedullary long stem implant and cerclage fixation. Although osteoporosis and deficient bone was seen, the stability of the hip joint and the fracture was good enough to facilitate early exercises, which might be the most efficacious stimulus for the improvement of bone quality. Intraoperatively, material obtained from reaming was used to cover the fracture line, which can further facilitate bone union. The hematoma and intramedullary materials might recruit circulating osteogenic precursor cells. However, the effect of bone grafting has to be investigated further due to a lack of randomized controlled studies. Bone grafting is unnecessary for stable fractures that are treated by indirect reduction and minimally invasive stabilization.¹⁸ Stable PFF could be managed by open reduction and stabilized by a plate-cable system as well as indirect reduction and stabilized by a locking plate and clinical results are

usually uneventful.¹⁹⁻²² The goal of surgical treatment is to achieve the stability of prosthesis, the union of fracture and early mobilization as well as decrease postoperative complications. A recent study indicated that intraoperative assessment of implant stability has to be emphasized.⁵ The critical reason for early failure in the treatment of PFF is mistaking Vancouver B2 and B3 (unstable implant) fractures for B1 fractures (stable implant). However, when bone grafting is not considered in revision surgery, the differences are not significant. PFFs with unstable implant in very old patients are inclined to be categorized as Vancouver B3 fractures for concomitant poor bone quality.

Currently, the direct lateral approach (Hardinge approach) is considered versatile for surgical management of the hip.²³ However, the variations of the LFCN have to be noted. Damage to the branches of the LFCN can yield abnormal sensations over the lateral thigh.^{24,25} However, we believe the direct lateral approach is beneficial for reducing early dislocation and facilitating functional exercises, especially for patients with multiple arthroplasties previously.

The limitation of our study is the low number of patients. Moreover, postoperative followup period is not long enough to verify long term clinical and functional results. Another limitation of the study is functional results were evaluated using Merle d'Aubigné scoring system. The scoring method is simple and easily understandable, which could be mailed to patients when they could not conform to regular clinical followup.

In conclusion, it is valid to manage Vancouver B3 periprosthetic femoral fractures through revision THA/HA in combination with appropriate internal fixation without bone grafting. Evidence-based studies are needed to investigate the value of bone grafting and the optimal protocol for managing for Vancouver B3 periprosthetic femoral fractures in the future.

REFERENCES

1. Lindahl H. Epidemiology of periprosthetic femur fracture around a total hip arthroplasty. *Injury* 2007;38:651-4.
2. Duncan CP, Masri BA. Fractures of the femur after hip replacement. *Instr Course Lect* 1995;44:293-304.
3. Berry DJ. Epidemiology: Hip and knee. *Orthop Clin North Am* 1999;30:183-90.
4. Lindahl H, Garellick G, Regnér H, Herberts P, Malchau H. Three hundred and twenty one periprosthetic femoral fractures. *J Bone Joint Surg Am* 2006;88:1215-22.
5. Nagvi GA, Baig SA, Awan N. Interobserver and intraobserver reliability and validity of the Vancouver classification system of periprosthetic femoral fractures after hip arthroplasty. *J Arthroplasty* 2012;27:1047-50.
6. Parvizi J, Vegari DN. Periprosthetic proximal femur fractures:

- Current concepts. *J Orthop Trauma* 2011;25:S77-S81.
7. Neumann D, Thaler C, Dorn U. Management of Vancouver B2 and B3 femoral periprosthetic fractures using a modular cementless stem without allografting. *Int Orthop* 2012;36:1045-50.
 8. Park SK, Kim YG, Kim SY. Treatment of periprosthetic femoral fractures in hip arthroplasty. *Clin Orthop Surg* 2011;3:101-6.
 9. Beals RK, Tower SS. Periprosthetic fractures of the femur: An analysis of 93 fractures. *Clin Orthop Relat Res* 1996;327:238-46.
 10. Masri BA, Meek RM, Duncan CP. Periprosthetic fractures evaluation and treatment. *Clin Orthop Relat Res* 2004;420:80-95.
 11. Springer BD, Berry DJ, Lewallen DG. Treatment of periprosthetic femoral fractures following total hip arthroplasty with femoral component revision. *J Bone Joint Surg Am* 2003;85:2156-62.
 12. Siegmeth A, Garbuz DS, Masri BA. Salvage procedures and implant selection for periprosthetic femoral fractures. *Injury* 2007;38:698-703.
 13. Tsiridis E, Spence G, Gamie Z, El Masry MA, Giannoudis PV. Grafting for periprosthetic femoral fractures: Strut, impaction or femoral replacement. *Injury* 2007;38:688-97.
 14. Lee SR, Bostrom MP. Periprosthetic fractures of the femur after total hip arthroplasty. *Instr Course Lect* 2004;53:111-8.
 15. Berry DJ. Treatment of Vancouver B3 periprosthetic femur fractures with a fluted tapered stem. *Clin Orthop Relat Res* 2003;417:224-31.
 16. Maury AC, Pressman A, Cayen B, Zalzal P, Backstein D, Gross A. Proximal femoral allograft treatment of Vancouver type-B3 periprosthetic femoral fractures after total hip arthroplasty. *J Bone Joint Surg Am* 2006;88:953-8.
 17. Tsiridis E, Gamie Z, Conaghan PG, Giannoudis PV. Biological options to enhance periprosthetic bone mass. *Injury* 2007;38:704-13.
 18. Ricci WM, Bolhofner BR, Loftus T, Cox C, Mitchell S, Borrelli J Jr. Indirect reduction and plate fixation, without grafting, for periprosthetic femoral shaft fractures about a stable intramedullary implant. *J Bone Joint Surg Am* 2005;87:2240-5.
 19. Shah NH, McCabe JP. Dall-Miles cable and plate system for periprosthetic femoral fracture. *Eur J Orthop Surg Traumatol* 2002;12:137-9.
 20. Kääh MJ, Stöckle U, Schütz M, Stefansky J, Perka C, Haas NP. Stabilisation of periprosthetic fractures with angular stable internal fixation: A report of 13 cases. *Arch Orthop Trauma Surg* 2006;126:105-10.
 21. Cebesoy O, Kose KC. Periprosthetic fractures of femur: LISS plate. *Arch Orthop Trauma Surg* 2006;126:427-8.
 22. Giannoudis PV, Kanakaris NK, Tsiridis E. Principles of internal fixation and selection of implants for periprosthetic femoral fractures. *Injury* 2007;38:669-87.
 23. Hungerford DS. Surgical approach in THA: The direct lateral approach is more practical and appealing. *Orthopedics* 2000;23:422.
 24. de Ridder VA, de Lange S, Popta JV. Anatomical variations of the lateral femoral cutaneous nerve and the consequence for surgery. *J Orthop Trauma* 1999;13:207-11.
 25. Ray B, D'Souza AS, Kumar B, Marx C, Ghosh B, Gupta NK, et al. Variations in the course and microanatomical study of the lateral femoral cutaneous nerve and its clinical importance. *Clin Anat* 2010;23:978-84.

How to cite this article: Wang J, Gao Y, Mei J, Rao Z, Wang S. Revision hip arthroplasty as a treatment of Vancouver B3 periprosthetic femoral fractures without bone grafting. *Indian J Orthop* 2013;47:449-53.

Source of Support: Nil, **Conflict of Interest:** None.

Author Help: Reference checking facility

The manuscript system (www.journalonweb.com) allows the authors to check and verify the accuracy and style of references. The tool checks the references with PubMed as per a predefined style. Authors are encouraged to use this facility, before submitting articles to the journal.

- The style as well as bibliographic elements should be 100% accurate, to help get the references verified from the system. Even a single spelling error or addition of issue number/month of publication will lead to an error when verifying the reference.
- Example of a correct style
Sheahan P, O'leary G, Lee G, Fitzgibbon J. Cystic cervical metastases: Incidence and diagnosis using fine needle aspiration biopsy. *Otolaryngol Head Neck Surg* 2002;127:294-8.
- Only the references from journals indexed in PubMed will be checked.
- Enter each reference in new line, without a serial number.
- Add up to a maximum of 15 references at a time.
- If the reference is correct for its bibliographic elements and punctuations, it will be shown as CORRECT and a link to the correct article in PubMed will be given.
- If any of the bibliographic elements are missing, incorrect or extra (such as issue number), it will be shown as INCORRECT and link to possible articles in PubMed will be given.