

Gastric perforation after duodenopancreatectomy

Henrik Bäcker*, Frank JP Beeres, Marco Rossi, Andreas Scheiwiller

Luzerner Kantonsspital, Spitalstrasse CH-6000 Lucerne 6, Switzerland



ARTICLE INFO

Keywords:

Mucormycosis
Duodenopancreatectomy
Whipple operation
Gastric
Perforation

ABSTRACT

Fungal and bacterial infections are often which may cause sepsis. Mucormycosis is an unfrequent, but often life-threatening disease. A timely diagnosis and treatment is the cornerstone of success. An increase in incidence can be expected, given an aging population and increasing incidence of obesity, diabetes and cancer.

We present a rare case where early diagnosis has helped to treat the patient mainly with antifungal therapy as surgical therapy has had high risk of complications.

1. Introduction

Mucormycosis is an infrequent disease which is mostly caused by *Rhizopus microsporus*. These zygomycetes are fast growing molds which produce pharmaceutically active rhizoxins or toxic rhizonins A and B [1]. The molds are distributed in plants and decaying materials [2]. Mucormycosis has been described in different organs: rhinocerebral, pulmonary, cutaneous, gastrointestinal and disseminated [3–5]. The infection occurs mostly in immune compromised patients. In the literature, the disease is most commonly described in patients with diabetes mellitus, cancer or after transplantation. The identification of this fungus is time consuming. Due to a high lethality an empirical therapy must be initiated as early as possible. The antemortem identification is between 23% and 50% of cases [6] and the mortality is described with 70–100% [7,8] mainly due to a perforation of luminal organs e.g. gastrointestinal tract.

The treatment varies from surgical interventions and conservative antifungal therapy [9,10].

2. Case

A 71-year old man presented to the hospital with stenosis and ulceration in the descending duodenum, highly suspicious for a pancreas head tumor. He had a history of diabetes mellitus type II and hypertension. A whipple operation was performed and histologic diagnosis revealed a duodenal carcinoma, infiltrating the pancreas. Because of leakage of the pancreatico-jejunal anastomosis after four days, a complete pancreatectomy was carried out and an antibiotic treatment with Piperacillin/Tazobactam was initiated. Due to a further clinical deterioration a CT-Scan was performed on day 18, which showed a collection on the subphrenical left side and in the pancreatic bed. A CT-

navigated drainage was inserted.

Bacteriology revealed *Staphylococcus epidermidis* in accumulation. Some days later a computertomographic control showed escape of per oral radiopaque material in the area of greater curvature– Fig. 2 – (day 25). On the same day an esophagogastrosopy was indicated which confirmed an atypical gastric perforation, of approximately 2 cm in diameter, at the dorsal gaster – Fig. 1.

The lesion was too large for an endoscopic intervention and the patient was considered to be too critical for a re-operation. Antibiotics (Piperacillin/Tazobactam) were continued.

Three days later (day 28), the provisional biopsy results showed fungi, most likely mucormycosis DD aspergillosis. Peripheral blood cultures were negative. The antibiotics were changed to Amoxicillin and Clavulanate 2,2 g every 8 h, and liposomal Amphotericin B 5 mg/kg body weight per day was installed.

The radiological drainage was efficient. An esophagogastrosopy was performed, showing a regressive ulcer of 8 mm after 3 weeks (day 39).

On day 42, we received the final histological results based on a broad-range fungal poly-chain-reaction (golden standard for detection of mucormycosis), stating that the fungi is a *rhizopus microsporus*. On the same day, the antifungal therapy could be adjusted to Posaconazol 200 mg every six hours.

Nearly two months after onset of the antibiotic therapy (day 63), it was terminated and another gastroscopic control was performed showing a complete regeneration of the gastric ulcer. Based on the diagnostic findings, the antifungal treatment was discontinued after a duration of 4 weeks in total (day 68). Table 1 summarizes the duration and dosage of the antibiotic/antifungal therapy.

* Corresponding author.

E-mail address: henrik.baecker@sports-med.org (H. Bäcker).

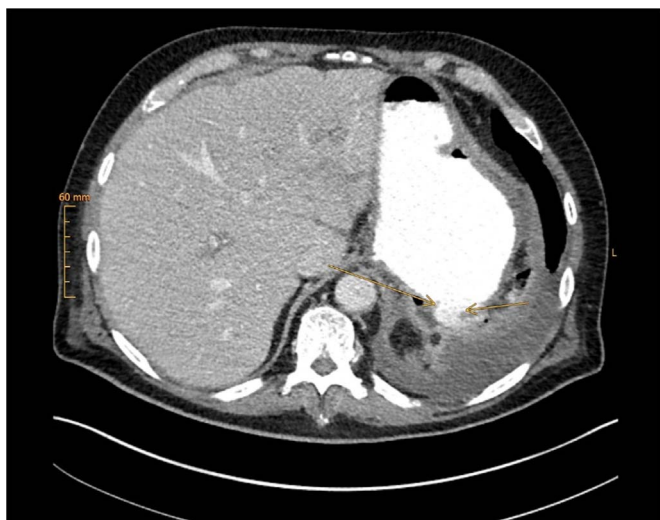


Fig. 1. Escape of radiopaque material indicated by the arrow.

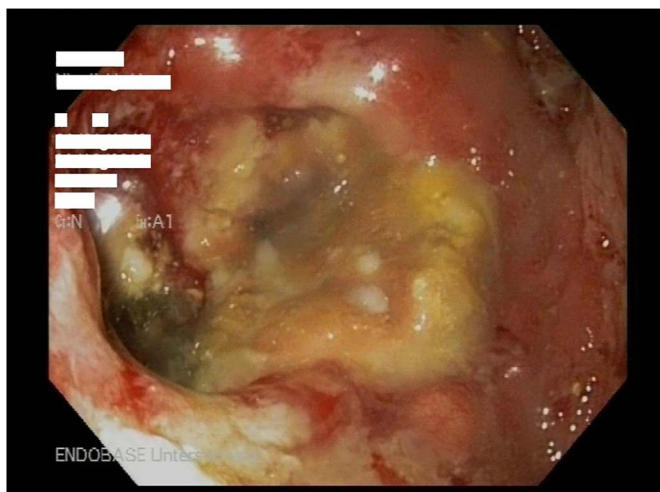


Fig. 2. Esophagogastroscope showing the gastric perforation.

Table 1
Antibiotic and antifungal therapy.

Medication	Dosage	Duration (days)	From – to (day) after whipple surgery
Piperacillin/Tazobactam	4.5 g every 8 h	24	4–28
Amoxicillin and Clavulanate	2.2 g every 8 h	35	28–63
Amphotericine B	5 mg/kg/day	13	28–41
Posaconazol	200 mg every 6 h	27	41–68

3. Discussion

Mucormycosis – formerly called zygomycosis – is an infrequent, but often life-threatening disease, mostly caused by *Rhizopus* microspores producing toxic rhizonins. These agents are opportunistic angioinvasive, and infarction of infected tissue is very typical for this invasive disease [11]. Most patients suffer from underlying disease such as diabetes mellitus, malignancies (mostly hematopoietic), transplantation, HIV infection, malnutrition or requiring corticoid medication. One reason may be neutropenia especially in people who have a malignancy or underwent chemotherapy. In diabetes it is rather associated multifactorial due to a microvascular disease and the architecture of the

sinuses [11]. Males are more affected than females however so far no explanation exists. One reason may be the protective role of estrogen in paracoccidioidomycosis [12]. Described locations of mucormycosis infection are rhinocerebral, pulmonary, cutaneous, gastrointestinal and disseminated disease. Gastrointestinal mucormycosis mainly affects the stomach, followed by colon, ileum and esophagus.

Patients often present with abdominal pain and hematemesis. Due to the tissue infarction, lesions present mostly as atypical necrotic ulcers leading to bleeding and perforation.

The prognosis is poor and in 70 to 100% lethal [11]. It depends on the individual risk factors such as kidney function and other comorbidities as well as the immediate initiation of antifungal therapy. Diagnosis relies upon the identification of the fungi by biopsy, histopathology, culture and polymerase chain reaction (PCR). PCR-based techniques often allow identification, even in culture negative cases however. They are however time consuming.

Treatment generally includes a surgical intervention and an antifungal therapy – Amphotericin B (from 5 mg/kg/day to 10 mg/kg/day) and/ or a lipid formulation e.g. Posaconazol (beginning with a loading dose of 2 × 300 mg on the first day, afterwards once a day) as a step-down therapy or for non-responders [11,13].

Due to the recent whipple operation followed after several days by a complete pancreatectomy, our patient was in a poor condition. An additional third surgical exploration within only a short timeframe was considered too risky and life-threatening.

The esophagogastroscope showed an atypical gastric ulcer partly necrotic and covered with fibrin. The preliminary result indicated the type of fungi, mucormycosis *DD aspergillus* on day 23. An empirical treatment with Amphotericin B was directly initiated as recommended in the literature [14,15]. When we received the final results on day 42, showing *rhizopus microsporus* based on a broad-range fungal poly chain reaction (two weeks after esophagogastroscope and initial diagnosis of the gastric perforation) the fungizid could be adjusted to Posaconazol. Because of these often time consuming procedures only 23–50% are identified ante mortem [14]. Consequently, provisional results are even very important in order to initiate an empirical therapy as soon as possible.

This case shows that a single antifungal therapy allows a complete regeneration of gastric perforation caused by invasive gastric mucormycosis. The gold standard of treatment is early surgical intervention, after clinical presentation which is recommended by most of the authors [3,5,11]. The single medication treatment should only be performed as last resort.

4. Conclusion

Gastric perforation and bleeding is a common disease and mostly caused by other entities. Mucormycosis is uncommon but important to keep in mind, because a timely diagnosis and treatment is the cornerstone for success in this often-deleterious disease. An increase in incidence can be expected given an aging population and increasing incidence of obesity, diabetes and cancer.

Conflict of interest

There are none.

Ethical form

There are no conflicts of interest. We have obtained a written and signed consent to publish the case report from the legal guardian.

References

[1] J. Jennessen, Kristian Fog Nielsen, J. Houbraken, E.K. Lyhne, J. Schnürer, J.C. Frisvad, R.A. Samson, Secondary metabolite and mycotoxin Production by the

- Rhizopus microsporus Group, *J. Agric. Food Chem.* 53 (5) (2005) 1833–1840, <http://dx.doi.org/10.1021/jf048147n>.
- [2] D. Garcia-Hermoso, E. Dannaoui, O. Lortholary, F. Dromer, Agents of systemic and subcutaneous mucormycosis and entomophthoromycosis, in: J. Versalovic, K.C. Carroll, G. Funke, J.H. Jorgensen, M.L. Landry, D.W. Warnock (Eds.), *Manual of Clinical Microbiology*, 10th ed., ASM press, Washington, DC, 2011, pp. 1880–1901.
- [3] A.S. Ibrahim, B. Spellberg, T.J. Walsh, D.P. Kontoyiannis, Pathogenesis of mucormycosis, *Clin. Infect. Dis.* 54 (S1) (2012) S16–S22.
- [4] G. Hamilos, G. Samonis, D.P. Kontoyiannis, Pulmonary mucormycosis, *Semin Respir. Crit. Care Med.* 32 (2011) 693–702.
- [5] J.A. Ribes, C.L. Vanover-Sams, D.J. Baker, Zygomycetes in human disease, *Clin. Microbiol. Rev.* 13 (2000) 236–301.
- [6] A. Nosari, P. Oreste, M. Montillo, et al., Mucormycosis in hematologic malignancies: an emerging fungal infection, *Haematologica* 85 (2000) 1068–1071.
- [7] L. Pagano, M. Offidani, L. Fianchi, et al., Mucormycosis in hematologic patients, *Haematologica* 89 (2004) 207–214.
- [8] R.M. Prabhu, R. Patel, Mucormycosis and entomophthoromycosis: a review of the clinical manifestations, diagnosis and treatment, *Clin. Microbiol. Infect.* 10 (Suppl 1) (2004) 31–47.
- [9] P. Pinto-Marques, D.M. Hockenbery, R.C. Hackman, D. Tapper, G.B. McDonald, Successful medical treatment of intestinal ulceration caused by *Rhizopus microsporus*, *Bone Marrow Transplant.* 32 (7) (2003) 739–740.
- [10] S.R. Thomson, P.G. Bade, M. Taams, V. Chrystal, Gastrointestinal mucormycosis, *Br. J. Surg.* 78 (8) (1991) 952–954.
- [11] M.M. Roden, T.E. Zaoutis, W.L. Buchanan, et al., Epidemiology and outcome of zygomycosis: a review of 929 reported cases, *Clin. Infect. Dis.* 41 (2005) 634.
- [12] A. Restrepo, M.E. Salazar, L.E. Cano, E.P. Stover, D. Feldman, D.A. Stevens, Estrogens inhibit mycelium-to-yeast transformation in the fungus *Paracoccidioides brasiliensis*: implications for resistance of females to paracoccidioidomycosis, *Infect. Immun.* 46 (1984) 346–353.
- [13] J.A. van Burik, R.S. Hare, H.F. Solomon, M.L. Corrado, D.P. Kontoyiannis, Posaconazole is effective as salvage therapy in zygomycosis: a retrospective summary of 91 cases, *Clin. Infect. Dis.* 42 (2006) e61–e65.
- [14] A. Nosari, P. Oreste, M. Montillo, et al., Mucormycosis in hematologic malignancies: an emerging fungal infection, *Haematologica* 85 (2000) 1068–1071.
- [15] P. Pinto-Marques, D.M. Hockenbery, R.C. Hackman, D. Tapper, G.B. McDonald, Successful medical treatment of intestinal ulceration caused by *Rhizopus microsporus*, *Bone Marrow Transplant.* 32 (7) (2003) 739–740.