

Case Report

Internal auditory canal exostosis: A technical case report

Lynn Mubita, Michael Seidman¹, Jack RockDepartments of Neurosurgery and ¹Otolaryngology, Henry Ford Hospital, Detroit, Michigan, USAE-mail: Lynn Mubita - lmubita1@hfhs.org; Michael Seidman - michael.seidman.md@flhosp.org; *Jack Rock - jrock1@hfhs.org

*Corresponding author

Received: 08 November 17 Accepted: 22 January 18 Published: 19 March 18

Abstract

Background: Exostoses of the internal auditory canal is a rare finding that may present with disabling symptoms of dizziness, hearing loss, and vestibular dysfunction based on the extent of cranial nerve compression. The purpose of this case report is to discuss the presentation and outcomes in a patient who presented with this disorder.

Case Description: A 19-year-old female presented to the neurotologist with left ear discomfort, pain with left lateral gaze, and dizziness. She underwent extensive evaluation including audiometric testing, videonystagmography, and neuroimaging, which confirmed left auditory and vestibular hypofunction and compression of the contents of the internal auditory canal from the exostosis. After extensive counseling, the patient elected to undergo a suboccipital craniectomy to remove the internal auditory canal exostosis. She experienced complete resolution of symptoms.

Conclusions: Exostoses of the internal auditory canal, although rare, can present with severe symptoms of dizziness, hearing loss, and vestibular hypofunction based on the extent of cranial nerve compression. Imaging, particularly with thin-cut computed tomography, is invaluable in making the correct diagnosis. Severe cases can be treated successfully with surgery with minimal or no complications and excellent outcome.

Key Words: Exostoses, exostosis, hearing loss, internal auditory canal, osteoma, vertigo

Video Available on:
www.surgicalneurologyint.com

Access this article online**Website:**www.surgicalneurologyint.com**DOI:**

10.4103/sni.sni_412_17

Quick Response Code:**BACKGROUND**

Exostoses of the internal auditory canal are rare, and sometimes seen only on postmortem examinations. Not to be confused with osteomas of the external auditory canal, which are slow-growing tumors that arise from the tympano-squamous suture, exostoses of the internal auditory canal are broad-based elevations found anywhere in the tympanic bone.^[1] They are less common than exostoses of the external auditory canal,^[5] which are readily encountered in standard otolaryngology clinics around the United States. Despite their rarity, when they occur, exostoses of the internal auditory canal can present with severe symptoms related to compression of

the cranial nerve seven and eight complex.^[3] Symptoms include decreased hearing, tinnitus, and vertigo, which can be disabling. Thus, the purpose of this report is to describe the clinical presentation, including signs and

This is an open access journal, and articles are distributed under the terms of the Creative Commons Attribution-NonCommercial-ShareAlike 4.0 License, which allows others to remix, tweak, and build upon the work non-commercially, as long as appropriate credit is given and the new creations are licensed under the identical terms.

For reprints contact: reprints@medknow.com

How to cite this article: Mubita L, Seidman M, Rock J. Internal auditory canal exostosis: A technical case report. *Surg Neurol Int* 2018;9:64.
<http://surgicalneurologyint.com/Internal-auditory-canal-exostosis-A-technical-case-report/>

symptoms, surgical approach, and postsurgical outcome in a patient who was treated at our institution with unilateral exostosis of the internal auditory canal.

CLINICAL PRESENTATION

A 19-year-old female presented to a Neurotologic colleague with a several-month history of discomfort of the left ear that was exacerbated on left lateral gaze. In addition, she experienced dizziness triggered on sitting up and physical activity. Audiometric testing revealed minimal, bilateral low-frequency hearing loss, and videonystagmography demonstrated a 67% reduced vestibular response in the left ear. These symptoms were significantly impacting her quality of life. Past medical history was notable for thoracic outlet syndrome. She was otherwise intact on neurological examination. Thin-cut temporal bone computed tomography (CT) and magnetic resonance imaging (MRI) [Figures 1 and 2] revealed an asymmetric narrowing of the left porus acousticus due to a bony overgrowth at the anterior inferior wall of the left internal auditory canal. Semicircular canals, vestibule, cochlea, and ossicles appeared intact. After discussion at the multidisciplinary skull base tumor board, it was decided to schedule her for a suboccipital craniectomy to remove the exostosis on the lower aspect of the internal auditory canal.

Surgery was performed in lateral position, with the left side up [Video 1]. A spinal drain was placed to aid with brain relaxation. A curvilinear incision was made behind the ear for a retromastoid approach. A standard suboccipital craniectomy was fashioned. The cisterna magna was decompressed by allowing cerebrospinal fluid to drain through the spinal drain. The brain was retracted medial and inferior to the seventh and eighth cranial nerve complex. After splitting the arachnoid, the exostoses were visible on the base of the porus acousticus below the anterior inferior cerebellar artery and appeared to be directly compressing the intermediate nerve. At this point, with the assistance of the neurotologic surgeon, the bone was drilled with a series of diamond drills until it was flat. Thereafter, Teflon was laid between the bone and the seventh and eighth cranial nerve complexes. Intraoperative monitoring

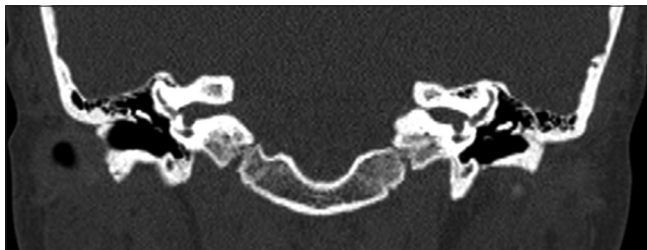

Figure 1: Coronal view showing the exostosis in the internal auditory canal. The red circle shows how the left is severely narrowed as compared to the right

of cranial nerves V, VII, and VIII remained unchanged at the end of the case.

Postoperatively, she was admitted to the neurosurgical intensive care unit where she was neurologically stable. Due to complaints of a low-pressure headache, she underwent blood patch with resolution of her headache. She was seen in follow-up 6 weeks later with neurosurgery and 7 weeks later in the neurotologic surgery clinic. She had mild discomfort around her left ear, but the episodes of dizziness as well as hearing difficulty had resolved. She remains symptom free and neurologically intact to this date.

DISCUSSION

Exostoses of the internal auditory canal are rare. The underlying cause of the exostoses is not understood.^[2] Diagnosis can be delayed and confused with other, more common pathologies seen by ENT and neurosurgery.^[4] Therefore, imaging, particularly with thin-cut CT is fundamental in arriving at a correct diagnosis. Exostoses can often be confused with osteomas of the internal auditory canal. Osteomas, which are slow-growing osseous tumors, typically present as solitary, pedunculated lesions extending into the internal auditory canal.^[6] On the other hand, exostoses present as a smooth-bordered, broad-based growth extending into the canal. Diagnosing either of the two can be aided with a tissue diagnosis obtained during surgery, but is not necessary. Treatment of exostoses of the internal auditory canal depends on the severity of symptoms and the extent of cranial nerve compression. In some mild cases, patients may be observed and their exostoses followed on serial imaging to monitor for development of nerve compression. Therefore, surgical treatment to decompress the exostoses is reserved for severe cases and in patients

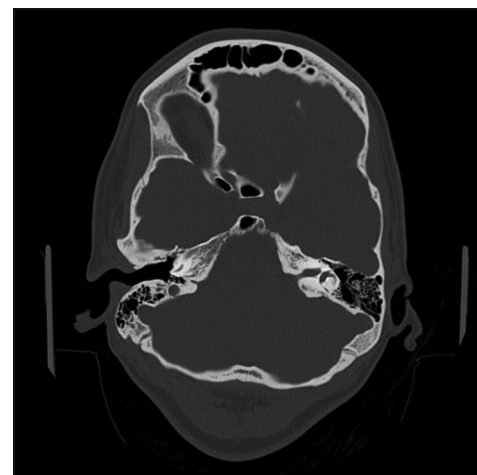


Figure 2: Axial view showing the exostosis in the internal auditory canal. The red circle shows the severe narrowing of the left internal auditory canal

with neurological deficit. Our patient, with severe symptoms that were negatively impacting her quality of life, elected to proceed with surgery.

CONCLUSION

Exostoses of the internal auditory canal, although rare, can present with disabling and severe symptoms of dizziness, hearing loss, and vestibular dysfunction based on the extent of cranial nerve compression. Imaging, particularly with thin-cut CT, is invaluable in making the correct diagnosis. Severe cases can be successfully treated with surgery with minimal complications and excellent outcome.

Declaration of patient consent

The authors certify that they have obtained all appropriate patient consent forms. In the form the patient(s) has/have given his/her/their consent for his/her/their images and other clinical information to be reported in the journal. The patients understand that their names and initials will not be published and due efforts will be

made to conceal their identity, but anonymity cannot be guaranteed.

Financial support and sponsorship

Nil.

Conflicts of interest

There are no conflicts of interest.

REFERENCES

1. Baik FM, Nguyen L, Doherty JK, Harris JP, Mafee MF, Nguyen QT. Comparative case series of exostoses and osteomas of the internal auditory canal. *Ann Otol Rhinol Laryngol* 2011;120:255-60.
2. Doan HT, Powell JS. Exostosis of the internal auditory canal. *J Laryngol Otol* 1988;102:173-5.
3. Nguyen LT, Baik FM, Doherty JK, Harris JP, Nguyen QT. Exostoses and osteomas of the internal auditory canal. *Laryngoscope* 2010;(Supplement 4):S215.
4. Polat C, Baykara M, Ergen B. Evaluation of internal auditory canal structures in tinnitus of unknown origin. *Clin Exp Otorhinolaryngol* 2014;7:160-4.
5. Turetsky A, Vines F, Clayman A. Surfer's ear: Exostoses of the external auditory canal. *Am J Neuroradiol* 1990;11:1217-8.
6. Wright A, Corbridge R, Bradford R. Osteoma of the internal auditory canal. *Br J Neurosurg* 1996;10:503-6.