

Operative management of pediatric urolithiasis

Jiakai Zhu, Timothy M. Phillips, Ranjiv I. Mathews

Brady Urological Institute, Johns Hopkins Hospital, Baltimore, MD, USA

ABSTRACT

Surgical management of urinary stones in children remains challenging due to the smaller caliber of the urinary tract. Specific instruments have been designed to overcome some of the issues related to pediatric stone management. Endoscopic and percutaneous modalities for stone management have been shown to be as safe and effective in providing stone clearance in children as in adults. Technologies that have been shown to be safe in adults are being miniaturized for use in children. The current literature regarding pediatric urolithiasis was reviewed in an effort to identify trends in operative management. Additionally, techniques used successfully at our institution are described. Although not an exhaustive review of all available modalities and instruments, this review will provide an overview of the current techniques for the management of pediatric urolithiasis.

Key words: Cystolithopaxy, cystoscopy, laser lithotripsy, pediatric, pediatric urolithiasis, percutaneous cystolithotomy, percutaneous nephrolithotomy, ureteroscopy

INTRODUCTION

The outcomes of surgical management of children with urinary tract stones has been described in the literature. Access to the urinary tract in children however, remains challenging. The smaller caliber of the urinary tract in children, does not allow the utilization of adult instruments. Consequently, many instruments have been specifically designed for use in children. Additionally, as experiences have increased in the management of pediatric urolithiasis, larger stones have been successfully managed with endoscopic instruments. All procedures in children require general anesthesia in order to be accomplished successfully. When positioning children, care should be taken to pad all pressure points so that nerve injury can be avoided and patients should be positioned so that all of the urinary tract can be evaluated.

For correspondence: Dr. Ranjiv I Mathews, Associate Professor of Pediatric Urology, Brady Urological Institute, John Hopkins Hospital, 148 Marburg, 600 North Wolfe Street, Baltimore, MD 21287. E-mail: RMathew1@jhmi.edu

Access this article online

Quick Response Code: 	Website: www.indianjurol.com
	DOI: 10.4103/0970-1591.74454

BLADDER ACCESS

Bladder stones have been commonly seen in underdeveloped countries, however, the widespread use of augmentation cystoplasty and other bladder reconstructive techniques that incorporate bowel segments into the urinary tract have led to a worldwide increase in incidence. Stones can be recurrent and may be large. Open stone procedures have essentially been supplanted by the use of minimally invasive techniques. No reduction in stone recurrence has been shown using minimally invasive techniques as compared to open procedures.^[1,2]

OPERATIVE TECHNIQUES: ENDOSCOPIC ACCESS

Urethral access in children should be performed with great care as the pediatric urethra, especially in boys, can be easily injured. A variety of instruments should be available for procedures so that all ages and sizes of children can be evaluated. To accommodate the various sizes of children that need to be treated, scopes ranging in size from 4.5 – 12Fr have been developed. It is important to know that a newborn male urethral meatus is approximately 7Fr.^[3] Meatal caliber increases in size with age such that by age three, 85% of the males would have a urethral meatus caliber of 10Fr.^[4] In newborn females up to one month of age, a 12Fr catheter can easily pass due to the influence of the mother's estrogens. However, by 12 to 18 months of age, smaller size instruments are needed.^[5]

Endoscopic evaluation of children is done under general

anesthesia. Patients are placed in dorsal lithotomy with all pressure points appropriately padded. All children are given prophylactic antibiotics prior to the procedure. The smallest available scopes are the 4.5Fr Wolf and 5F USA Series™ MR™. The working channels of these two scopes are between 2.4 to 3Fr respectively. The small working channels only make these scopes useful for diagnostic evaluation, insertion of guidewires or removal of stents. The next larger scope is the 7.5Fr Olympus pediatric rigid cystoscope with a 5Fr working channel. This working channel will accommodate one 5Fr or two smaller (2 and 3Fr) instruments. With instruments in the working channel, irrigation can be severely compromised. This scope is available with an offset telescope which allows the 5Fr port to be a straight channel [Figure 1]. All of the smaller scopes use a fiberoptic system and require video systems that have been calibrated for these scopes to obtain the best visualization. In most children requiring endoscopic management of stones, the larger 9.5–10Fr scopes are ideal. These scopes are available from many manufacturers and the offset lens systems allow for direct access using a 5–5.5Fr port. This permits introduction of many stone fragmentation devices as well as baskets and wires. Due to the small caliber of these scopes and fragmentation systems, only small stones (less than 1 cm) can be successfully managed with this strategy. When managing larger stones use of percutaneous techniques are more appropriate.

OPERATIVE TECHNIQUES: PERCUTANEOUS ACCESS

Percutaneous cystolithotomy has been safely performed for stones up to 5 cm in size. Furthermore, it is a safe technique in patients with reconstructed or closed bladder necks or patients with augmented bladders.^[6] In children with larger stone burdens, repeat procedures may allow complete stone clearance. In an effort to reduce complications associated with significant hypothermia in children, we limit the length of procedures to 2 hours, preferring to leave a percutaneous access and return for a second attempt at complete stone clearance.

The techniques are derived from percutaneous nephrolithotomy procedures. Preoperatively, patient's bladder and pelvic anatomy should be evaluated before planning for percutaneous cystolithotomy along with obtaining preoperative urine culture. Procedures are performed using general anesthesia and perioperative antibiotics. Patients are placed supine or in dorsal lithotomy if access to a normal urethra is desired. Percutaneous access to the bladder can in most cases be obtained under direct vision. When the urethra has not had prior reconstruction, a pediatric cystoscope can be used to fill the bladder and to determine the appropriate site for placement of the percutaneous access. Most patients can be managed with a midline access in the suprapubic region.

Availability of dual video systems allows both cystoscope and nephroscope to be used simultaneously. Following successful bladder neck reconstruction, the urethra should be accessed using the smallest scope possible. At our institution, this is the 4.5Fr diagnostic cystoscope. Percutaneous access can then be achieved under direct vision. If smaller cystoscopes are not available, then placement of a small-caliber catheter will allow the bladder to be filled to completion. In patients with a closed bladder neck or augmented bladder with urinary diversion, the bladder may be visualized and filled through the urinary stoma. Most children with a continent urinary stoma can have the bladder endoscopically accessed using a pediatric 10Fr cystoscope. The location for percutaneous access is chosen based on location of the stone. The reconstructed bladder may be fixed to the abdominal wall at the location of a prior suprapubic drainage tube or in the midline at the site of a prior incision. Care should be taken to prevent traversing bowel segments that may be adhered to the reconstructed bladder. Preoperative imaging with computerized tomography or magnetic resonance imaging may be helpful in preventing inadvertent bowel injury.

TRACT DILATION

Once the site is determined, a needle may be used to obtain percutaneous access. The site can then be dilated to an appropriate size using an Amplatz dilator set [Figure 2a]. Alternatively the Step™ radially dilating bladeless trocar (Autosuture / Covidien, Dublin, Ireland) can be used to dilate the tract. We use a standard 24Fr adult nephroscope for stone fragmentation and extraction. With larger stones, this permits rapid stone fragmentation and extraction. The Step system is used for laparoscopic access and the 10 mm sheath size permits use of the 24Fr nephroscope for stone fragmentation and extraction [Figure 2b]. Using the 10 mm sheath a laparoscopic bag can be used to entrap the entire stone that can then be fragmented within the bag without loss of stone fragments.^[7]

URETERAL AND RENAL ACCESS

Treatment for ureteral stones is the main indication for ureteral access and manipulation in children. The development of fiberoptic ureteroscopes has permitted ureteral access in younger children. Concerns of complications secondary to ureteroscopy in children have not been borne out by studies. Ureteral dilation does not increase the rate of ureteral stricture, ischemia, or cause significant vesicoureteric reflux (VUR).^[8-12] Schuster *et al.* performed ureteroscopies in 25 children following balloon dilation to 15Fr in all patients. Grade I VUR developed in two children but resolved within one month.^[13] Series of ureteroscopic treatment of ureteral stones showed stone-free rates of 86–100%.^[14-18] Stone clearance rates with ureteroscopy have been shown to be higher than with electrohydraulic shock wave lithotripsy

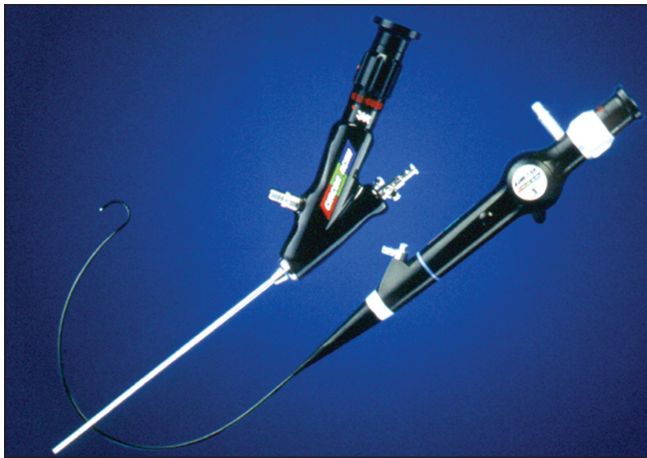


Figure 1: 7.5Fr offset cystoscopy and 6.9Fr flexible ureteroscope




Figure 2a: Amplatz dilator set used for serial dilation of percutaneous tract

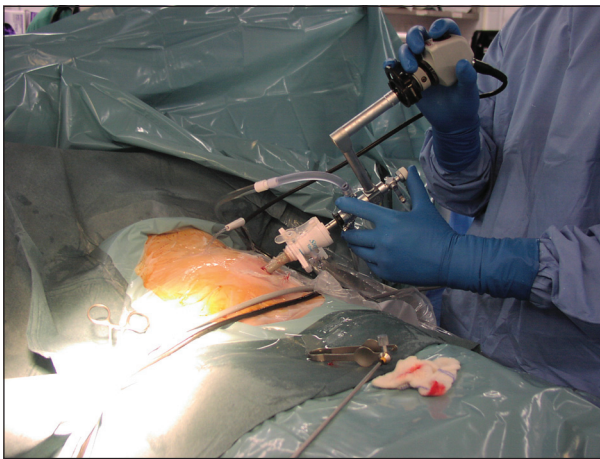

Figure 2b: Cystolithotomy access obtained through a 10mm sheath by using the Step™ radially dilating bladeless trocar

(ESWL). Overall, the complication rates of ureteral stricture, ischemia, and reflux are minimal and given the high success rates of stone clearance, ureteroscopic treatment of ureteral stones should be considered as a safe and effective first-line treatment option.

OPERATIVE TECHNIQUES

All pediatric ureteroscopic procedures are performed under general anesthesia. Prophylactic antibiotics are routinely used and the patient is placed in lithotomy position. An appropriate size offset cystoscope mentioned above (7.5, 9.5, 10, or 10.5Fr) is placed into the bladder for identification of the ureteral orifices. Under direct vision, a 0.035-inch guidewire is passed through the ureteral orifice and advanced beyond the ureteral stone to the renal pelvis. This process is always accomplished under fluoroscopic guidance. A straight or angled hydrophilic guidewire may be used if there is difficulty obtaining access to the renal pelvis either due to tortuosity of the ureter or ureteral stone impaction. If a guidewire is used,

it should be replaced with a standard wire to prevent loss of access. Use of a safety wire during ureteroscopic procedures in children is highly recommended. At times a guidewire may facilitate passage of the ureteroscope over the wire to the location of the calculus or into the renal pelvis. The ureteral orifice may be dilated by using an 8/10Fr coaxial dilator. If there is difficulty passing the 8/10 dilator at the three known areas of physiological narrowing: ureteral orifice, iliac vessels, and ureteropelvic junction; one may choose to balloon dilate the ureter. If there is continued difficulty with ureteral access then placement of a ureteral stent with later attempt at ureteroscopy is the safer alternative. Corcoran *et al.* have reported that physical parameters are not predictive of successful upper tract access.^[19] Lower ureteral stones may be accessed in the older children using semi-rigid ureteroscopes. For most upper ureteral and renal pelvic stones, the current available flexible ureteroscopes are the instruments of choice. The 6.9Fr flexible ureteroscope has a 3.6Fr working channel that will allow use of laser filaments or stone baskets and graspers [Figure 1]. The use of a ureteral access sheath will permit the ureter in the older child to be repeatedly accessed rapidly and with minimal trauma. The available ureteral access sheaths are made by Cook Medical: Flexor® Ureteral Access Sheath 9.5 or 12Fr internal diameter with starting length of 13 cm and by Applied Medical: Forté® HD Ureteral Access Sheath 12Fr with starting length of 20 cm. Limited studies addressing the use of ureteral access sheaths in children have demonstrated overall safety.^[20]

The most commonly used semi-rigid ureteroscope is the Wolf 6/7.5Fr self-dilating ureteroscope. Its safety has been well reported with minimal reports of ureteral injury. The 4.5Fr Wolf semi-rigid ureteroscope, also known as the Needle Scope is the smallest and newest pediatric ureteroscope. It has a 2.4Fr working channel and due to its small working channel size, only laser fibers can pass through the port.

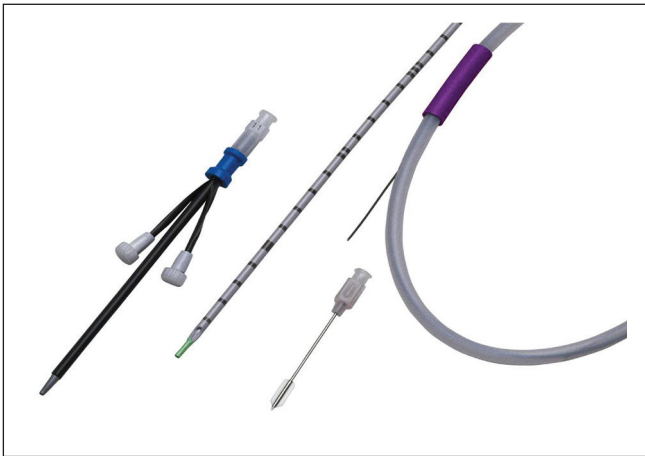

Figure 3a: Mini-perc instrument set

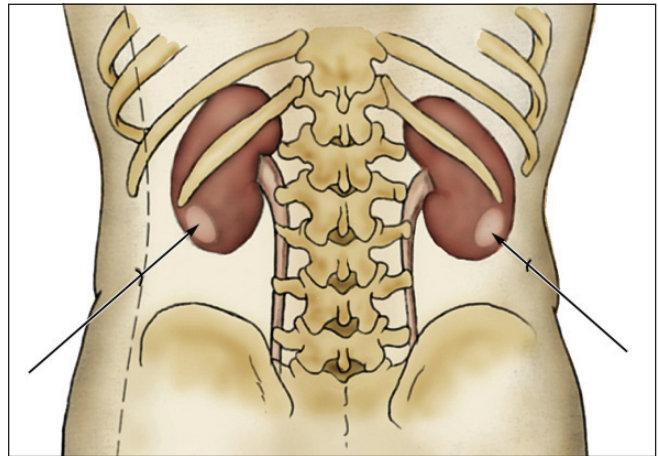


Figure 3b: Posterior axillary approach to obtaining percutaneous access (From: Lottmann H, Gagnadoux MF, Daudon M. Urolithiasis in children. In, Gearhart JP (ed). Pediatric Urology, 2nd edition. Philadelphia, Elsevier Saunders, 2010)

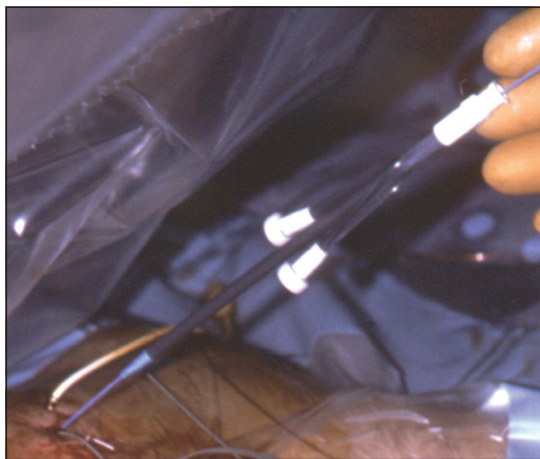


Figure 4a: Mini-perc access to the collecting system

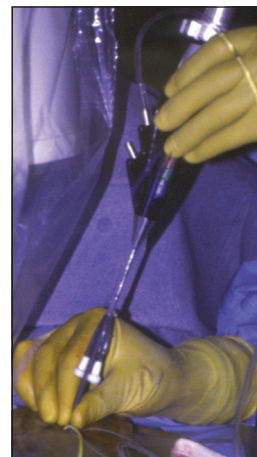


Figure 4b: Mini-perc access to the collecting system

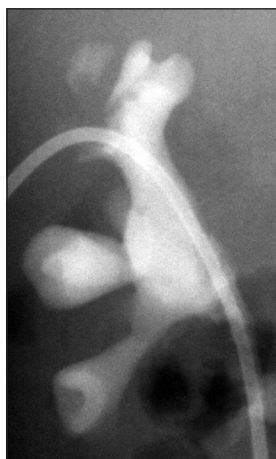

Figure 4c: After obtaining percutaneous access (In this case, through mini-perc access), one can easily and quickly evaluate the stone burden through a simple antegrade nephrostogram

PERCUTANEOUS NEPHROLITHOTOMY (PCNL)

The safety and efficacy of pediatric percutaneous nephrolithotomy (PCNL) has been well established.

Previous concerns of PCNL in children such as long-term renal damage, renal function impairment, bleeding, sepsis, and radiation exposure have been refuted by clinical reports demonstrating the overall safety of this operation. Dwaba *et al.* have shown no renal scarring in 65 patients on long-term follow up after PCNL.^[21] Mor *et al.* showed that there is no decrease in renal function after PCNL using radioisotope scans.^[22] Desai *et al.* showed that intraoperative hemorrhage during PCNL is correlated with the caliber and number of percutaneous tracts and proposed limiting the tract size to 22Fr to reduce blood loss.^[23] Furthermore, many studies have reported no increase in complications when tract size was less than 26Fr and acceptable rates of complication even when dilating tract size to 30Fr.^[24-26] The mini-perc 13Fr peel-away sheath (Cook Urological, Spencer, IN) was first introduced in 1998 and remains the smallest access sheath for PCNL today [Figure 3a]. The mini-perc has gained popularity due to its size, decreased risk of bleeding, and ease of use. The tract size however, does limit visibility and potentially increases operative time as stone fragments need

to be small prior to removal. To combat the disadvantages of the mini-perc and risk of bleeding with larger PCNL tracts, Bilen *et al.* found that access through a 20Fr sheath was an acceptable alternative.^[27] Ultrasound-guided access is a good alternative to fluoroscopy with the advantages of avoiding radiation exposure.^[28]

Percutaneous access may be obtained preemptively in a patient with an obstructed urinary system, or as the first step in the operative procedure. Use of preemptive access with the help of a trained interventional radiologist is of benefit in children who have significant deformities of the spine and concurrent changes in renal anatomy.

The indications for PCNL in children include large stone burden >2 cm or hard renal stones (HFU >900 on CT) between 1 to 2 cm, significant renal obstruction, urinary infection, failure of SWL and significant residual stones after open surgery.^[29] Of 16 reported studies of using PCNL in children, the stone-free rate ranged from 58–98.6% using access of 11 to 30Fr and treating children between three to nine years of age having stone size of 1.2 to 4.7 cm.^[18]

OPERATIVE TECHNIQUES

Children undergoing PCNL should be placed under general anesthesia and given prophylactic antibiotics after obtaining preoperative urine culture. Hypothermia is a significant risk during PCNL in children, consequently every effort should be made to monitor and maintain appropriate body temperature. Operative room temperature should be maintained in the range of 73.4 to 77°F along with use of warmed normal saline (95 to 96.8°F) for irrigation.^[6] Furthermore, warming blankets are used to cover parts of the body that are not in the operative field. When obtaining access at the time of the procedure, initial cystoscopy and placement of a ureteral stent that can be injected allow for delineation of the renal pelvis. A Foley catheter is left in place for bladder drainage. The patient is then positioned prone with all pressure points padded.^[24] Access to the desired calyx is obtained by using an 18 to 22-gauge spinal needle under fluoroscopic or ultrasonic guidance. Once the needle is in the parenchyma, no attempts should be made to redirect the needle. Commonly, the approach is along the posterior axillary line (a line drawn from the external extremity of the acromion to the posterior superior iliac spine)^[30] [Figure 3b]. For complex stones occupying multiple calices including stones >1 cm in the lower pole, the most advantageous access would be a supra-costal approach as it would be in line with the pelvis and ureter. This access allows visualization of the superior calyx and pelvis and straight access to the inferior calices.^[24] This access approach may also be used for treatment of proximal ureteral stones. After access is confirmed by injecting contrast through the needle into the calyx, a 0.035-inch

guidewire or glidewire as needed is passed through the needle into the collecting system and directed down the ureter and into the bladder. The needle is then removed and a small incision is made in the skin using a No. 11 scalpel next to the wire. Multiple options are available for tract dilation. The mini-perc system employs a dilator and sheath together that can be rapidly placed into the kidney [Figure 4a-b]. The mini-perc system also allows an initial evaluation of the extent of the stone burden [Figure 4c]. If on initial evaluation, stone burden exceeds the capacities of the mini-perc, then the tract can be dilated to permit larger instruments to be used. The Amplatz rigid dilator system may be used as well; however, the small renal pelvis in the child can be easily injured if care is not taken to limit the excursion of the dilator. Balloon dilation tends to be less traumatic and can be rapidly accomplished.

Nephroscopic visualization can be achieved using the pediatric cystoscopes (10Fr), adult nephroscopes (24–30Fr) or the flexible adult cystoscopes (17Fr). All these instruments allow for use of laser fibers, stone removal devices, and guidewires to be passed easily.

STONE FRAGMENTATION AND REMOVAL

There are four methods of stone fragmentation depending on their location, composition, endoscopic instrumentation, and surgeon's preferences. The main principle is to fragment the stones into a small enough size to be easily and safely retrieved outside of the genitourinary tract. The four main methods for stone fragmentation are laser lithotripsy, ultrasonic lithotripsy, ballistic/pneumatic lithotripsy, and electrohydraulic lithotripsy. Each method has its own set of unique applications along with disadvantages and advantages. Once the stones have been fragmented, they are removed via stone baskets, graspers, and forceps.

LASER LITHOTRIPSY

Laser lithotripsy has become the treatment of choice in pediatric endourology given its safety profile, effectiveness of stone fragmentation, flexibility of the optic fibers, and its small optic fiber calibers (250, 320, and 550 microns). The Holmium: yttrium-aluminum-garnet (YAG) 20W laser is a pulse laser that breaks up the stones via a photo-thermal process. There is no risk of ocular injury in case of an accidental exposure, but there is a risk of thermal injury to the tissue or guidewires.^[31]

When using the Holmium laser the following principles should be followed:

- (1) Maintain constant fluid irrigation to preserve good visualization and avoid accidental adjacent tissue injury
- (2) Laser fiber's tip must contact the stone for efficacious fragmentation
- (3) Initial laser settings are 0.6 to 0.7 joules at 8 to 10 Hertz



Figure 5a: Ultrasonic lithotripor

- (4) Coagulation of bleeding vessels is possible by pointing the tip of the laser fibers 0.2-0.4mm from the vessel
- (5) "Popcorn" technique can be applied to reduce the size of a group of small stones by increasing the frequency of the laser pulsation resulting in a weak acoustical shock wave that move the stones against each other and to the tip of the laser fiber
- (6) When approaching a large renal or ureteral stone, attempts should be made to slowly shave the stone size from outside to inside, which can reduce the number of fragments.

Holmium laser fibers can be passed through various endoscopic instruments. The small fiber caliber (250 microns = 0.25 mm = 0.75Fr) allows it to be easily passed through virtually any cystoscopic, ureteroscopic, and nephroscopic working channel. Furthermore, it is particularly effective on cystine stones. The disadvantages of Holmium laser are that the fiber tip may occasionally break during laser lithotripsy, accidental thermal injury to the urothelium, and photo-thermal energy can affect the chemical composition of the small stone fragments. For example, calcium oxalate monohydrate may become calcium carbonate, struvite may become ammonium carbonate and magnesium carbonate, cystine stones may become cystine and free sulfur, and uric acid may release cyanide.^[31] Although no detectable cyanide toxicity has ever been documented.

ULTRASONIC LITHOTRIPSY

Ultrasonic lithotripsy transmits high-frequency vibrations along a rigid metal probe to the tip of the probe that is in contact with the stone. This process requires a rigid cystoscopy for bladder stones, rigid ureteroscopy for distal or proximal ureteral stones, and a nephroscope for percutaneous nephrolithotomy [Figure 5a]. The center of the metal probe is hollow, which in turn allows for suctioning of stone fragments. Since this is a high-frequency vibration instrument, the temperature increases along




Figure 5b: Nitinol zero tip basket

the probe which could be cooled through the irrigation fluid flowing through the center of the metal probe. It is important to reduce contact of the metal probe with tissue to reduce thermal injuries to the surrounding tissues. In addition, ultrasonic lithotripters are not as effective against hard stones composed of cystine and calcium oxalate monohydrate. Many probe sizes are available including 5Fr that can fit through the pediatric cystoscopes. Care should be taken to prevent bending and breakage of the probes during surgery.

BALLISTIC/PNEUMATIC LITHOTRIPSY

Ballistic/Pneumatic lithotripsy involves use of pure mechanical hammer that is transmitted along a 2.4Fr metal probe that can be easily inserted through any rigid 3Fr working channel. The benefit of ballistic/pneumatic lithotripters is that they are more effective on harder stones and less expensive than laser fibers.^[32] However, a rigid scope must be used to accommodate the probe. Recent advance in technology has allowed a marriage between ultrasonic and pneumatic lithotripters. Boston Scientific Co. makes the LithoClast[®] Ultra which combines the technology of pneumatic and ultrasonic lithotripsy. This device provides improved stone fragmentation and reduces operative time. It is most useful for treatment of large renal stones. In addition, the LithoClast[®] Ultra comes in four different sizes which can be used in the bladder, ureter, and kidney.

ELECTROHYDRAULIC LITHOTRIPSY

The Electrohydraulic lithotripter is made of coaxial flexible probe (1.6 to 5F) connected to a shock wave generator. This device can be used with flexible ureteroscopes. The generator is placed close to the calculus to permit fragmentation. However, it has slowly fallen out of favor especially for treatment of ureteral stones due to the high rate of ureteral perforation.^[33] Additionally, when used in the augmented bladder, care should be taken to prevent

the probe from contacting the bladder wall and creating a significant rupture.

EXTRACTION DEVICES

There are many different commercially available baskets. The shaft of the basket varies in size from 1.5 to 4.5Fr with open basket diameter of 1 to 2 cm. They are available in two lengths, 65 cm and 115 cm. The tip of the baskets have a variety of designs, ranging from helical, to spiral, to triangular. The shapes of the baskets are specifically designed for retrieval of stones in different parts of the genitourinary tract. For example, the nitinol zero tip basket allows for retrieval of renal calyceal stones without causing damage to the tissue while the nitinol helical NForce® made by Cook Medical is designed for maximal radial dilation during stone retrieval in the ureter [Figure 5b]. All the baskets should be used with caution as entrapment of tissue and ureteral avulsion are potential complications.

Three-pronged graspers are the most commonly used graspers for stone retrieval. They come in different sizes and shapes as well. These graspers have a shaft diameter in the range of 2.8 to 5Fr with overall length of 40 to 115 cm and a grasper diameter of 5 to 20 mm. These graspers can be used transurethrally or percutaneously. For larger bladder or renal stones, rat tooth or alligator forceps may be used to retrieve the stones; however, their application is often restricted to retrieval of stones through large percutaneous accesses. Graspers are less likely to cause ureteral injury as there is less potential for tissue entrapment.

CONCLUSION

Improvement in technology has increasingly made endoscopic and percutaneous management of urolithiasis in children the treatment of choice. Better stone clearance and reduction in complications has made these modalities more efficacious than ESWL. Although complete stone removal in a single procedure should be the goal for management, increasing potential for complications by prolonged intervention should be avoided. Patients and families should be counseled at the outset that stone removal may require more than one procedure and re-evaluation to ensure complete stone removal may be required. Having fluoroscopic equipment and a wide variety of endoscopic equipment available is crucial for successful stone management.

REFERENCES

1. Salah MA, Holman E, Khan AM, Toth C. Percutaneous cystolithotomy for pediatric endemic bladder stone: experience with 155 cases from 2 developing countries. *J Pediatr Surg* 2005;40:1628-31.
2. Barbancho DC, Fraile AG, Sánchez RT, Díaz ML, Otero JR, Vázquez FL, *et al.* Minimally invasive endourological management of urinary tract calculi in children. *Cir Pediatr* 2008;21:15-8.
3. Allen JS, Summers JL, Wilkerson JE. Meatal calibration of newborn

- boys. *J Urol* 1972;107:498.
4. Elder JS. Congenital anomalies of the genitalia. In: Walsh PC, editors. *Campbell's Urology*, 6th ed. Philadelphia, Saunders: 1992. p. 1920-38.
5. Smith AB, Adams LL. Insertion of indwelling urethral catheters in infants and children: a survey of current nursing practice. *Pediatr Nurs* 1998;24:229-34.
6. Schuster TK, Smaldone MC, Averch TD, Ost MC. Percutaneous nephrolithotomy in children. *J Endourol* 2009;23:1699-705.
7. Jarrett TW, Pound CR, Kavoussi LR. Stone entrapment during percutaneous removal of infection stones from a continent diversion. *J Urol* 1999;162:775.
8. Caione P, De Gennaro M, Capozza N, Zaccara A, Appetito C, Lais A, *et al.* Endoscopic manipulation of ureteral calculi in children by rigid operative ureterorenoscopy. *J Urol* 1990;144:484-5.
9. Jayanthi VR, Arnold PM, Koff SA. Strategies for managing upper tract calculi in young children. *J Urol* 1999;162:1234.
10. El-Assmy A, Hafez AT, Eraky I, El-Nahas AR, El-Kappany HA. Safety and outcome of rigid ureteroscopy for management of ureteral calculi in children. *J Endourol* 2006;20:252-5.
11. Satar N, Zeren S, Bayazit Y, Aridoğan IA, Soyupak B, Tansuğ Z. Rigid ureteroscopy for the treatment of ureteral calculi in children. *J Urol* 2004;172:298-300.
12. Herndon CD, Viamonte L, Joseph DB. Ureteroscopy in children: is there a need for ureteral dilation and postoperative stenting? *J Pediatr Urol* 2006;2:290-3.
13. Schuster TG, Russell KY, Bloom DA, Koo HP, Faerber GJ. Ureteroscopy for the treatment of urolithiasis in children. *J Urol* 2002;167:1813.
14. De Dominicis M, Matarazzo E, Capozza N, Collura G, Caione P. Retrograde ureteroscopy for distal ureteric stone removal in children. *BJU Int* 2005;95:1049.
15. Tan AH, Al-Omar M, Denstedt JD, Razvi H. Ureteroscopy for pediatric urolithiasis: an evolving first-line therapy. *Urology* 2005;65:153.
16. Minevich E, Defoor W, Reddy P, Nishinaka K, Wacksman J, Sheldon C, *et al.* Ureteroscopy is safe and effective in prepubertal children. *J Urol* 2005;174:276.
17. Van Savage JG, Palanca LG, Andersen RD, Rao GS, Slaughenhaupt BL. Treatment of distal ureteral stones in children: similarities to the american urological association guidelines in adults. *J Urol* 2000;164:1089.
18. Smaldone MC, Corcoran AT, Docimo SG, Ost MC. Endourological management of pediatric stone disease: present status. *J Urol* 2009;181:17-28.
19. Corcoran AT, Smaldone MC, Mally D, Ost MC, Bellinger MF, Schneck FX, *et al.* When is prior ureteral stent placement necessary to access the upper urinary tract in prepubertal children? *J Urol* 2008;180:1861-64.
20. Singh A, Shah G, Young J, Sheridan M, Haas G, Upadhyay J. Ureteral access sheath for the management of pediatric renal and ureteral stones: a single center experience. *J Urol* 2006;175:1080-82.
21. Dawaba MS, Shokeir AA, Hafez AT, Shoma AM, El-Sherbiny MT, Mokhtar A, *et al.* Percutaneous nephrolithotomy in children: early and late anatomical and functional results. *J Urol* 2004;172:1078-81.
22. Mor Y, Elmasry YE, Kellett MJ, Duffy PG. The role of percutaneous nephrolithotomy in the management of pediatric renal calculi. *J Urol* 1997;158:1319-21.
23. Desai MR, Kukreja RA, Patel SH, Bapat SD. Percutaneous nephrolithotomy for complex pediatric renal calculus disease. *J Endourol* 2004;18:23-7.
24. Farhat WA, Kropp BP. Surgical treatment of pediatric urinary stones. *AUA update series* 2007;26:21-28.
25. Samad L, Aquil S, Zaidi Z. Pediatric percutaneous nephrolithotomy: setting new frontiers. *BJU Int* 2006;97:359-63.
26. Unsal A, Resorlu B, Kara C, Bozkurt OF, Ozyuvali E. Safety and Efficacy of Percutaneous Nephrolithotomy in Infants, Preschool Age, and Older Children With Different Sizes of Instruments. *Urology* 2009;74:77.
27. Bilen CY, Koçak B, Kitirci G, Ozkaya O, Sarikaya S. Percutaneous

- nephrolithotomy in children: lessons learned in 5 years at a single institution. *J Urol* 2007;177:1867-71.
28. Desai M, Ridhorkar V, Patel S, Bapat S, Desai M. Pediatric percutaneous nephrolithotomy: assessing impact of technical innovations on safety and efficacy. *J Endourol* 1999;12:259-364.
 29. Mishra SK, Ganpule A, Manohar T, Desai MR. Surgical management of pediatric urolithiasis. *Indian J Urol* 2007;23:428-34.
 30. Lottmann H, Gagnadoux MF, Daudon M. Urolithiasis in children. In: Gearhart JP, editors. *Pediatric Urology*, 2nd ed. Philadelphia: Elsevier Saunders; 2010. p. 653.
 31. Chan KF, Vassar CJ, Pfefer TJ, Teichman JM, Glickman RD, Weintraub ST, *et al.* Holmium:YAG laser lithotripsy: A dominant photothermal ablative mechanism with chemical decomposition of urinary calculi. *Lasers Surg Med* 1999;25:22-37.
 32. Aghamir SK, Mohseni MG, Ardestani A. Treatment of ureteral calculi with ballistic lithotripsy. *J Endourol* 2003;17:887-90.
 33. Hofbauer J, Hobarth K, Marberger M. Electrohydraulic versus pneumatic disintegration in the treatment of ureteral stones: a randomized, prospective trial. *J Urol* 1995;153:623-62.

How to cite this article: Zhu J, Phillips TM, Mathews RI. Operative management of pediatric urolithiasis. *Indian J Urol* 2010;26:536-43.
Source of Support: Nil, **Conflict of Interest:** None declared.