

- uveitis clinic in India. *Int Ophthalmol* 1996-1997;20:223-8.
2. Dandona L, Dandona R, John RK, McCarty CA, Rao GN. Population based assessment of uveitis in an urban population in southern India. *Br J Ophthalmol* 2000;84:706-9.
 3. Rathinam SR, Namperumalsamy P. Global variation and pattern changes in epidemiology of uveitis. *Indian J Ophthalmol* 2007;55:173-83.
 9. Williams GJ, Brannan S, Forrester JV, Gavin MP, Paterson-Brown SP, Purdie AT, *et al.* The prevalence of sight-threatening uveitis in Scotland. *Br J Ophthalmol* 2007;91:33-6.
 10. Sugita M, Enomoto Y, Nakayma S. Epidemiological study on endogenous uveitis in Japan. Proceedings of the 3rd International Symposium on Uveitis, Brussels, Belgium: 1992. p. 24-7.

Surgical choroidal neovascular membrane removal in the era of anti-vascular endothelial growth factor agents

Manish Nagpal, Kamal Nagpal, Vikram Mehta

Intravitreal anti-vascular endothelial growth factor (VEGF) agents have obtained acceptance as the mainstay in the management strategy of subfoveal choroidal neovascular membranes (CNVM) due to varying etiologies. Few drawbacks include need for repeated intravitreal injections, with its adjunct risks, and the lack of a predefined treatment end point, which can cause doubts and uncertainty in the mind of the patient. Furthermore, it remains a significant financial burden for the patient.

Herein we report our data of three patients who were reluctant for further re-injections of anti-VEGF agents and were therefore offered surgical removal of the CNVM by submacular surgery as an alternative treatment plan.

Key words: Anti-vascular endothelial growth factor, choroidal neovascular membrane, submacular surgery

Indian J Ophthalmol: 2009;57:146-148

Retina Foundation, Ahmedabad, India

Correspondence to Dr. Manish Nagpal, Retina Foundation, Shahibaug, Ahmedabad-380 004, Gujarat, India. E-mail: drmanishnagpal@yahoo.com

Manuscript received: 07.02.08; Revision accepted: 19.05.08

DOI: 10.4103/0301-4738.45507 - PMID: 19237791

The efficacy of intravitreal anti-vascular endothelial growth factor (VEGF) agents for treatment of choroidal neovascular membranes (CNVMs) of varying etiologies as the first line of treatment, has been adequately proven by numerous trials and studies.^[1-5] The need for repeated injections suggests that the neovascular complexes (especially those with mature smooth muscle and pericyte support, the architectural component of CNVM) are not extinguished but lie dormant so long as the neovascular drive from VEGF is quelled.^[6] This could be based on the dual component model of CNVM pathogenesis—vascular and extravascular component.^[7] Both components have the potential for inducing tissue damage individually and in concert. Anti-VEGF drugs attack the vascular component with some secondary, indirect effect on the extravascular component, presumably due to induced ischemia.

Patients often receive intravitreal injections on a regular monthly (pegaptanib, ranibizumab) or quarterly (bevacizumab) basis for several months to years with an improvement or stability of their condition. However, absence of a predefined endpoint in terms of the duration of treatment and the total number of injections required is vexing to a select few patients.

Some of the concerns include frequent follow-up visits, exposure to repeated risk of endophthalmitis, vitreous hemorrhage, retinal detachment, cataract formation and other known complications of intravitreal injections, which are albeit rare. Furthermore, there is a significant financial burden of repeated procedures and the cost of the drug. Here, we present our data of three patients who, when faced with the ambiguity and dilemma related to these issues felt reluctant to continue with re-injections. They were then offered surgical removal of CNVM as an alternative treatment after a full explanation of the pros and cons of the same.

Case Reports

Case 1

A 55-year-old male patient presented to us with complaints of decreased vision and metamorphopsia, in the left eye for three weeks. He was treated in the past elsewhere with intravitreal bevacizumab thrice for CNVM secondary to age-related macular degeneration (AMD), at four-weekly intervals. He reported temporary subjective improvement post injections. Last injection was received ten weeks before he visited us. Upon examination, his best corrected visual acuity was 20/120, in the left eye with normal anterior segment findings. Posterior segment clinical examination and optical coherence tomography (OCT) revealed subfoveal CNVM of half disc diameter (DD) size, with minimal subretinal blood [Fig. 1A and B]. The need for a repeat intravitreal injection of bevacizumab was explained to the patient. Upon refusal for the same, the option of surgical removal was discussed with the patient. Following a detailed informed consent, he underwent the procedure. Six months postoperative, his preoperative vision of 20/120 was maintained and no intra- or postoperative complications were encountered [Fig. 1C and D].

Case 2

A 58-year-old male patient, a known case of neovascular AMD, was treated with intravitreal bevacizumab four weeks prior to his first visit to us, elsewhere. He was dissatisfied with the treatment and reported no subjective improvement post injection. At presentation, his visual acuity was 20/120 in the right eye with a subfoveal CNVM with hemorrhage, of size 1 DD [Fig. 2A and B]. Patient refused management with further injections. Following a detailed discussion and informed consent, he underwent surgical removal of the CNVM. At six months postoperative duration, he maintained a vision of 20/120 without any intra- or postoperative complications [Fig. 2C and D].

Case 3

A 35-year-old male patient with idiopathic CNVM OS, was

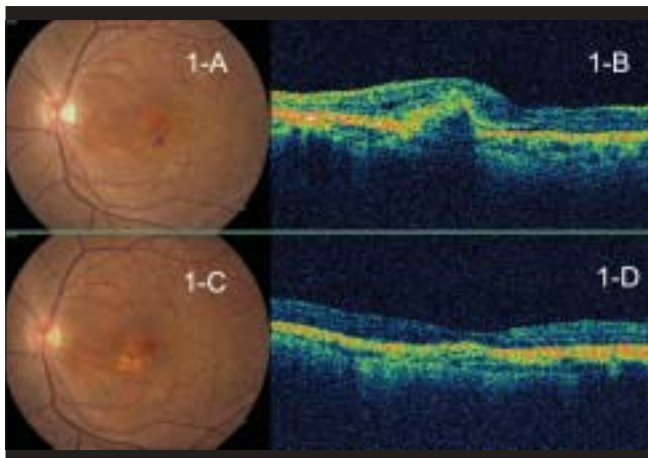


Figure 1: (A and B) Case 1 Color fundus photograph and OCT showing small subfoveal CNVM with minimal subretinal hemorrhage despite previous intravitreal injections of bevacizumab. (C and D) Two months post surgical CNVM removal color fundus photograph and OCT showing absence of CNVM with some scarring and restoration of normal foveal contour with stabilized vision

treated by us with two injections of intravitreal bevacizumab, at three month intervals. We noted temporary improvement in visual acuity following injections. Five months following the second injection his vision decreased to 20/120 from 20/30. Posterior segment clinical examination and OCT revealed active subfoveal CNVM, sized 1.5-2 DD with some sub-retinal hemorrhage. The need for repeated injection was explained to the patient. On refusal for the same, the option of surgical removal was discussed with the patient. Following detailed informed consent, he underwent the surgical procedure with vision stabilizing to 20/120 at final follow-up, six months post surgery. No intra- or postoperative complications were encountered.

Surgical technique

Standard 20-gauge three-port pars plana vitrectomy including posterior hyaloid removal was done. Through a small retinotomy away from the center of the fovea, CNVM removal was performed with a long beaked forceps. Posterior pole was temporarily tamponaded with perfluorocarbon liquid. Screening of the periphery was carried out followed by a fluid air exchange and closure. Patients maintained face down position for three days.

Discussion

Certain clinical or histopathological features may diminish the efficacy of intravitreal anti-VEGF agents on CNVMs.^[8] Patients who do not respond satisfactorily to these agents face a dilemma due to the pros and cons of the treatment, as outlined above.

Surgical CNVM removal was studied by the submacular surgery trial (SST) group which began a decade back when the only established modality of treatment was laser photocoagulation. The study concluded that submacular surgery did not improve or preserve visual acuity for 24 months in more eyes than just observation, however, at one-year follow-up, 34% eyes had stabilized or improved vision in cases of neovascular AMD.^[9] Eyes eligible for SST had large

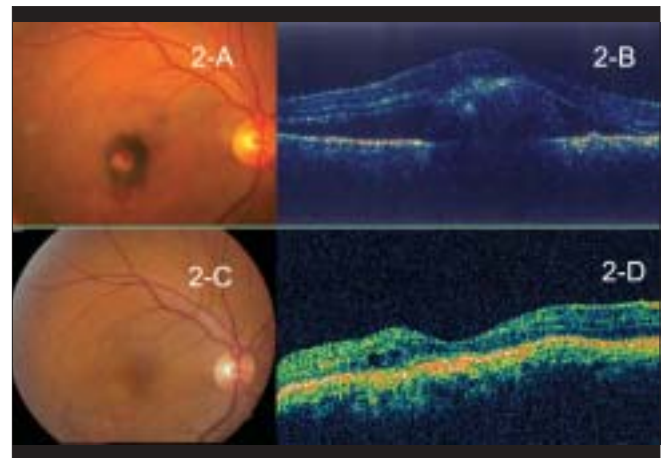


Figure 2: (A and B) Case 2 Color fundus photograph and OCT showing small subfoveal CNVM with subretinal hemorrhage despite previous intravitreal injection of bevacizumab. (C and D) One month post surgical CNVM removal color fundus photograph and OCT showing absence of CNVM with some scarring and restoration of normal foveal contour with stabilized vision

membranes with poor visual acuity and no previous treatment. Our three cases had relatively smaller membranes with no scarring, patients who refused repeat intravitreal injections, and desired an alternative treatment for their condition. The duration between surgical treatment and the last injection was 75 days, 30 days and 150 days respectively in the three cases. Intra- and postoperative course was uneventful in all three cases. Preoperative vision was maintained at six months following surgery.

The SST group reported that 77% eyes had some residual blood after surgery and in a small proportion of cases it was severe enough to cause elevation of the retina.^[9] In our experience intraoperatively, the CNVMs were non/minimally vascular and did not bleed from the bed while removal. We postulate that this may be an effect of the previous anti-VEGF priming to the membrane.^[10]

To conclude, we observed that surgical removal of CNVM may have a role in stabilizing deteriorating vision in selected cases of small non-scarred classic CNVM, when repeated intravitreal anti-VEGF injections are declined by the patient. However, preoperative counseling and visual prognosis should be clearly emphasized to the patients. If surgery is planned, anti-VEGF may also reduce the risk of hemorrhage during surgical excision.

References

1. Gragoudas ES, Adamis AP, Cunningham ET Jr, Feinsod M, Guyer DR, VEGF Inhibition Study in Ocular Neovascularization Clinical Trial Group. Pegaptanib for neovascular age-related macular degeneration. *N Engl J Med* 2004;351:2805-16.
2. Avery RL, Pieramici DJ, Rabena MD, Castellarin AA, Nasir MA, Giust MJ. Intravitreal bevacizumab (Avastin) for neovascular age-related macular degeneration. *Ophthalmology* 2006;113:363-72.
3. Spaide RF, Laud K, Fine HF, Klancnik JM, Meyerle CB, Yannuzzi LA, *et al.* Intravitreal bevacizumab treatment of choroidal neovascularization secondary to age-related macular degeneration. *Retina* 2006;26:383-90.
4. Ferrara N, Damico L, Shams N, Lowman H, Kim R. Development of ranibizumab, an anti-vascular endothelial growth factor antigen binding fragment: As therapy of neo-vascular age-related macular degeneration. *Retina* 2006;26:859-70.
5. Rosenfeld PJ, Brown DM, Heier JS, Boyer DS, Kaiser PK, Chung CY, *et al.* Ranibizumab for neovascular age-related macular degeneration. *N Engl J Med* 2006;355:1419-31.
6. Erber R, Thurnher A, Katsen AD, Groth G, Kerger H, Hammes HP. Combined inhibition of VEGF and PDGF signaling enforces tumor vessel regression by interfering with pericyte-mediated endothelial cell survival mechanisms. *FASEB J* 2004;18:338-40.
7. Spaide RF. Perspectives: Rationale for combination therapies for choroidal neovascularisation. *Am J Ophthalmol* 2006;141:149-56.
8. Lux A, Llacer H, Heussen FM, Joussen AM. Non-responders to bevacizumab (Avastin) therapy of choroidal neovascular lesions. *Br J Ophthalmol* 2007;91:1318-22.
9. Submacular surgery trials (SST) Research group. Surgery for subfoveal choroidal neovascularisation in age-related macular degeneration: Ophthalmic findings, SST report no 11. *Ophthalmology* 2004;111:1967-80.
10. Gibran SK, Sachdev A, Stappeler T, Newsome R, Wong D, Hiscott P. Histological findings of a choroidal neovascular membrane removed at the time of macular translocation in a patient previously treated with intravitreal bevacizumab treatment (Avastin). *Br J Ophthalmol* 2007;91:602-4.