

## CASE REPORT

# Premortem diagnosis of pathologically confirmed sporadic Creutzfeldt-Jakob disease

Elina T Ziukelis<sup>1</sup>  | Vasu Keshav Sharma<sup>2,3</sup> | James J Gome<sup>2,4</sup>

<sup>1</sup>St Vincent's Health Australia, Melbourne, Vic, Australia

<sup>2</sup>South West Healthcare, Warrnambool, Vic, Australia

<sup>3</sup>Health Imaging Services, Warrnambool, Vic, Australia

<sup>4</sup>Deakin University, Burwood, Vic, Australia

## Correspondence

Elina Ziukelis, St Vincent's Health Australia, Melbourne, Victoria, Australia.  
Email: elinaziukelis@gmail.com

## Funding information

The authors received no funding for this work and have no conflicts of interest to declare.

## Abstract

Sporadic Creutzfeldt-Jakob disease should be considered in any case of rapid neuropsychiatric decline. While neuropathological examination of a brain biopsy specimen remains the only definitive diagnostic method and real-time quaking-induced conversion tests have simplified premortem diagnosis, careful evaluation of magnetic resonance imaging can provide readily accessible clues.

## KEY WORDS

Acute medicine, genetics, geriatric medicine, neurology, psychiatry

## 1 | INTRODUCTION

Prion diseases are caused by the neurotoxic accumulation of misfolded prion protein. Accumulation or “seeding” occurs exponentially as misfolded prion protein induces normal cellular prion protein to misfold.<sup>1,2</sup> Sporadic Creutzfeldt-Jakob disease (sCJD) accounts for the vast majority of prion disease cases but is rare, occurring in approximately 1 in 1 million per year worldwide.<sup>3</sup> The clinical syndrome associated with sCJD is characterized by rapid neuropsychiatric decline leading to akinetic mutism and death within one year of symptom onset.<sup>4</sup> There are no curative treatments available.

We describe a case presenting with neuropsychiatric and neurological symptoms that suggested dysfunction in both cortical and subcortical regions of the brain. We describe the process by which we diagnosed him premortem with probable sCJD. We discuss the evidence base for diagnostic tools we used with reference to the 2018 Centers for Disease

Control and Prevention (CDC) diagnostic criteria for sCJD<sup>5</sup> (Figure 1).

## 2 | CASE DESCRIPTION

A 70-year-old previously independent man presented to a regional emergency department with a one-month history of progressive unsteadiness on his feet. At the time of presentation, he required support just to stand. He also described episodes of diplopia, lasting 3–4 minutes and resolving spontaneously 1–2 times per day. Recent review by an optometrist had been unremarkable. On enquiry, the patient and his wife also admitted he had experienced recent memory impairment and significant behavioral changes. These included hyperphagia, emotional lability, and impulsivity, consistent with frontal lobe syndrome. He denied vertigo, nausea, or vomiting. He also denied headaches, neck stiffness, or

This is an open access article under the terms of the Creative Commons Attribution-NonCommercial-NoDerivs License, which permits use and distribution in any medium, provided the original work is properly cited, the use is non-commercial and no modifications or adaptations are made.

© 2021 The Authors. *Clinical Case Reports* published by John Wiley & Sons Ltd.

## Definite Sporadic Creutzfeldt-Jakob Disease

Diagnosed by standard neuropathological techniques; and/or immunocytochemically; and/or Western blot confirmed protease-resistant PrP; and /or presence of scrapie-associated fibrils.

## Probable Sporadic Creutzfeldt-Jakob Disease

Neuropsychiatric disorder plus positive RT-QuIC in cerebrospinal fluid (CSF) or other tissues

OR

Rapidly progressive dementia; and at least two out of the following four clinical features:

1. Myoclonus
2. Visual or cerebellar signs
3. Pyramidal/extrapyramidal signs
4. Akinetic mutism

AND a positive result on at least one of the following laboratory tests

- a typical EEG (periodic sharp wave complexes) during an illness of any duration
- a positive 14-3-3 CSF assay in patients with a disease duration of less than 2 years
- High signal in caudate/putamen on magnetic resonance imaging (MRI) brain scan or at least two cortical regions (temporal, parietal, occipital) either on diffusion-weighted imaging (DWI) or fluid attenuated inversion recovery (FLAIR)

AND without routine investigations indicating an alternative diagnosis.

## Possible Creutzfeldt-Jakob Disease

Progressive dementia; and at least two out of the following four clinical features:

1. Myoclonus
2. Visual or cerebellar signs
3. Pyramidal/extrapyramidal signs
4. Akinetic mutism

AND absence of positive result for any of the 4 tests above that would classify a case as “probable”

AND duration of illness less than two years

AND without routine investigations indicating an alternative diagnosis.

photophobia. He had worked with meat for most of his life but had never been overseas. He did not have incontinence. He denied any upper limb incoordination. He had not consumed alcohol for 34 years. His father had been diagnosed with Parkinson's disease at age 68, but he had no other family history of neurological disease.

On examination, he demonstrated a severely ataxic gait. Romberg's test was negative and evidenced severe truncal ataxia. The patient required support from the examiner to stand with eyes open. Despite denying any difficulty utilizing his upper limbs, he had bilateral dysidiadokinesia and dysmetria. He also had mild rigidity in his upper limbs and was globally hyporeflexic. Glabellar tap test was positive. There was no clonus. Full power was preserved throughout all four limbs. Sensation including proprioception and vibration sense was also preserved. Cranial nerve examination was unremarkable. While the patient was oriented, able to follow three-stage commands and behaviorally appropriate during examination, further bedside cognitive testing revealed subtle impairments. The patient failed serial seven subtraction testing despite repeated instructions. He recalled only one out of three objects after five minutes, even after prompting with

a choice of three objects for each he could not recall. On a clock-drawing test, he failed to set the time to “ten past five,” instead leaving marks next to the numbers 10, 2, and 5 after much deliberation.

In summary, our patient presented with rapidly progressive ataxia, intermittent diplopia, and new cognitive and behavioral disturbance. There were both cerebellar and extrapyramidal signs on examination. Given the patient's vascular risk factors including ischemic heart disease, type 2 diabetes mellitus, hypertension, and hypercholesterolemia, an ischemic event was considered but thought inconsistent with the gradual onset of ataxia and diversity of additional symptoms. Given a history of prostate cancer and skin melanoma, a paraneoplastic etiology was initially strongly favored. Other differential diagnoses included atypical infection, autoimmune disease, toxicity, metabolic derangement, and prion disease.

Blood tests were unremarkable. Creatinine, liver enzymes, blood sugar level, electrolytes, and thyroid function were normal. Vitamin B12 and folate were replete. Inflammatory markers were not elevated. Cryptococcus, Toxoplasma, HIV, and Syphilis serologies were negative. ANA, ENA, and anti-dsDNA were normal. Anti-neuronal, anti-VGKC, anti-LG-1,

**FIGURE 1** 2018 Centers for Disease Control and Prevention (CDC) diagnostic criteria for Sporadic Creutzfeldt-Jakob Disease<sup>5</sup>

anti-Caspr-2, anti-GQ-1, anti-GM-1, and anti-GAD antibodies were not detected. Copper and ceruloplasmin levels were also normal. Initial tests on cerebrospinal fluid (CSF) were equally unremarkable. Opening pressure was at the upper limit of normal (20 cm H<sub>2</sub>O). Biochemistry was bland. Gram stain showed no bacteria, and culture was negative. Cytology showed no features of malignancy. Herpes and Enterovirus PCR were negative. Anti-neuronal, anti-NMDA, anti-GABA, and anti-AMPA antibodies were not detected. A computed tomography (CT) noncontrast scan of the brain performed in the emergency department was unremarkable. A CT of the chest, abdomen, and pelvis showed no evidence of malignancy.

Our patient was admitted and treated empirically with 300 mg intravenous thiamine thrice daily while awaiting further diagnostic work-up. A magnetic resonance imaging (MRI) scan with T2-weighted, fluid-attenuated inversion recovery (FLAIR), and diffusion-weighted imaging (DWI) sequences was obtained. When this showed new symmetric hyperintensity in the basal ganglia (on T2, FLAIR, and DWI) as well as subtle hyperintensity of the insular cortex, frontal cortical rim, and cerebellar folia (on DWI) (Figure 2), further investigations to support prion disease were pursued. Electroencephalography (EEG) was normal. The CSF was positive for 14–3–3 protein, and total Tau protein was also elevated with a concentration of 5714 pg/ml. A real-time quaking-induced conversion (RT-QuIC) test performed on CSF was positive, strongly suggesting a diagnosis of sCJD. Before these results were returned, pulsed methylprednisolone was trialed for three days without effect. The patient returned home to receive palliative care, and his symptoms progressed rapidly. He died approximately three months after symptom onset.

Results of a postmortem examination confirmed the diagnosis of CJD. Neuropathologic changes were most pronounced in the cerebellum. Family also consented to performance of genetic testing on the patient's blood, which revealed no pathogenic mutation to suggest a genetic form of CJD.

### 3 | DISCUSSION

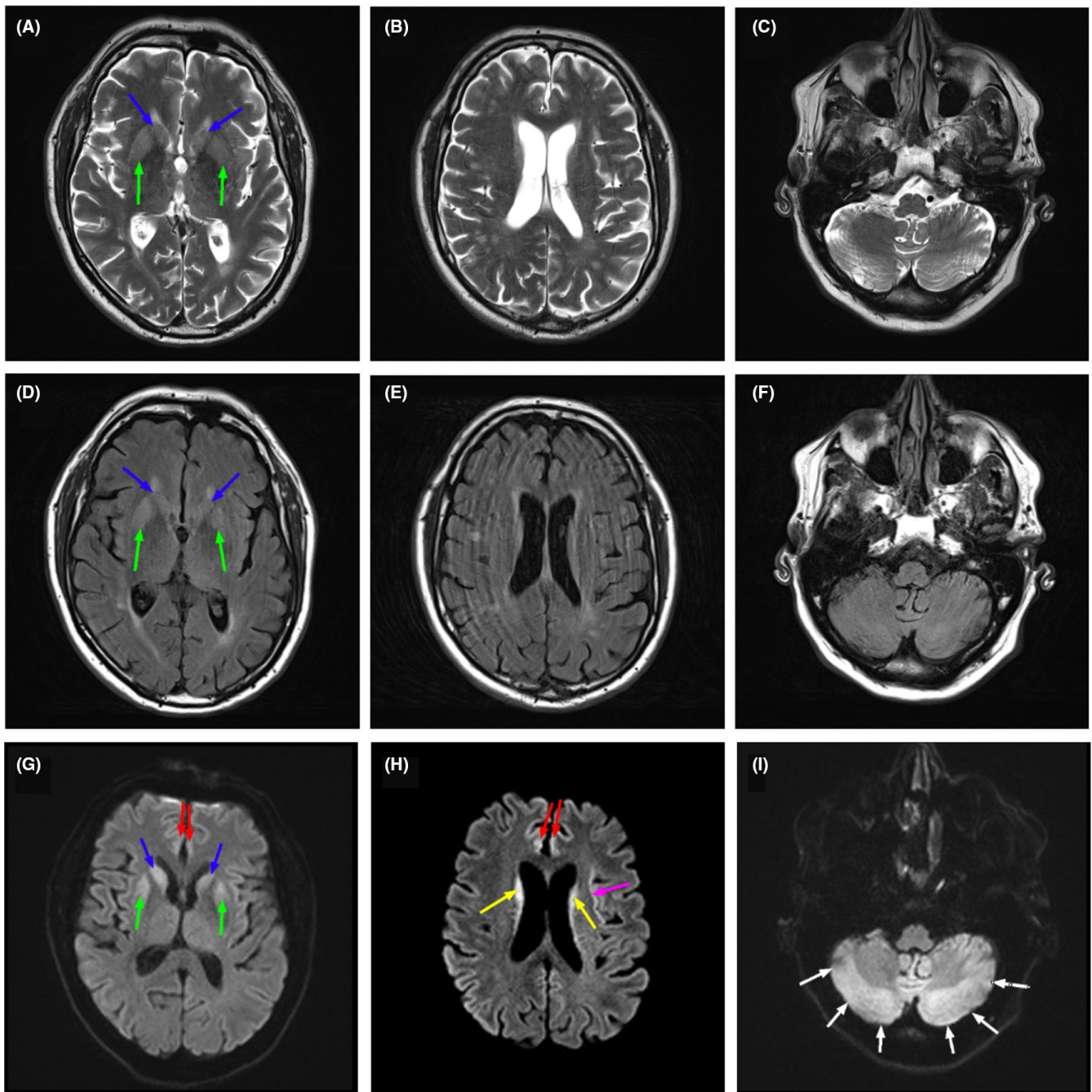
The presence of neuropsychiatric disorder is a consistent feature of sCJD and required for its premortem diagnosis<sup>5</sup> (Figure 1). Progression is typically rapid, helping to distinguish it from other forms of dementia. However, specific neuropsychiatric signs and symptoms are highly heterogeneous. Memory loss, impaired attention, frontal lobe syndrome, aphasia, apraxia,<sup>6</sup> psychotic symptoms, and/or mood disorder<sup>7</sup> may occur alongside equally heterogeneous neurological symptoms. Common neurological symptoms include ataxia and myoclonus, which is classically provoked by startle.

Corticospinal tract involvement, extrapyramidal symptoms, sleep disturbance, and a diverse range of visual symptoms are also well-recognized,<sup>8–10</sup> including the intermittent diplopia experienced by our patient.<sup>9</sup> The myriad of possible signs and symptoms generates a spectrum of presentations of sCJD. As the rarity of the disease limits clinicians' exposure to it, if classical symptoms are missing or obscured by lesser-known ones the diagnosis may not be considered. Accordingly, it is not uncommon for the diagnosis to be missed or delayed.<sup>11</sup>

In our case, early neuropsychiatric symptoms were overshadowed by more overt neurological symptoms. The patient's primary complaint had been his debilitating ataxia. Only on purposeful enquiry and with assistance from his wife was a simultaneous neuropsychiatric decline revealed. In other cases, psychiatric symptoms have been more prominent and patients have presented initially to mental health services.<sup>12</sup> The breadth of our patient's deficits reflected abnormal function in neuroanatomically disparate regions and rendered our initial differential diagnoses and investigations appropriately broad.

Careful exploration of differential diagnoses is essential because definitive diagnosis of sCJD can only be made on neuropathological examination of a brain biopsy specimen,<sup>5</sup> usually performed postmortem due to risk of iatrogenic transmission. The importance of thorough initial investigations is illustrated by a retrospective review of brain autopsies referred to US National Prion Disease Pathology Centre between 2006 and 2009. Of 1,106 cases referred with a suspected diagnosis of prion disease, 352 did not show pathological features consistent with the diagnosis. Of note, the most common diseases misdiagnosed as prion diseases were Alzheimer's Disease and Vascular Dementia, which occasionally progress quickly. However, most concerning is that 71 cases showed features of treatable disease. These included a variety of immune-mediated, neoplastic, and infectious diseases as well as three cases of Wernicke's Encephalopathy.<sup>13</sup> In addition to causing premature withdrawal of care, unwarranted suspicion of prion disease may limit diagnostic options including brain biopsy and place unnecessary emotional burden on family members. Similarly to the presence of a neuropsychiatric disorder, exclusion of reversible causes is integral to premortem diagnosis of sCJD<sup>5</sup> (Figure 1).

EEG, lumbar puncture, and MRI can all help to exclude reversible disease as well as form evidence of CJD. Both EEG and markers of neuronal injury in the CSF are less useful for the latter purpose since emergence of MRI and methods of detecting prion seeding activity. The classic EEG finding of periodic sharp wave complexes (PSWCs) occurs in approximately two thirds of patients during the course of illness<sup>14–16</sup> and is up to 91% specific for CJD.<sup>15</sup> However, a positive result is significantly less likely in the early stage of clinical disease than the final stage.<sup>16</sup> The sensitivity of elevated CSF protein 14–3–3 appears to be less variable across



**FIGURE 2** Axial T2-weighted [(A), (B), and (C)], fluid-attenuated inversion recovery [(D), (E), and (F)], and diffusion-weighted [(G), (H), and (I)] images showing hyperintensity of the caudate nucleus (blue arrows), putamen (green arrows), frontal cortical rim (red arrows), corona radiata (yellow arrows), insular cortex (purple arrow), and cerebellum (white arrows) approximately five weeks after symptom onset. Note that only abnormalities in the basal ganglia are evident on all three sequences. Confluent periventricular hyperintensity on FLAIR [(E)] is nonspecific, often seen with chronic white matter ischemia which could be superimposed on the periventricular abnormality clearly evident on diffusion-weighted imaging (yellow arrows). Abnormalities of the cortical rim, insula cortex, and cerebellum are evident only on diffusion-weighted imaging

stages of disease.<sup>16</sup> A systematic review showed that elevated 14–3–3 has a sensitivity of 92% and a specificity of 80% for a diagnosis of sCJD.<sup>17</sup> Diseases that are most likely to produce false positives are readily clinically distinguishable from sCJD.<sup>8</sup> However, important differential diagnoses for sCJD including other forms of dementia and encephalitis have been associated with elevated 14–3–3.<sup>8,18</sup> CSF protein Tau appears

to have similar sensitivity and specificity to 14–3–3<sup>8</sup> and elevation of both may enhance diagnostic accuracy<sup>19</sup> but Tau has not been incorporated into diagnostic criteria.

Development of the RT-QuIC test<sup>20</sup> has greatly facilitated diagnosis of sCJD. In this test, a sample of cerebrospinal fluid is added to a mixture of recombinant prion protein and fluorescent dye. Any misfolded prion protein

in the cerebrospinal fluid will induce misfolding of the recombinant prion protein and result in accumulation of polymers, a process hastened by shaking of the mixture. Dye binds the polymers, such that their gradual accumulation will result in a gradual increase in fluorescence. In effect, the test confirms prion seeding activity from which the presence of misfolded prion protein in the CSF can be inferred. It is 96% sensitive and 100% specific for sporadic CJD.<sup>21</sup> Accordingly, a positive RT-QuIC test in association with neuropsychiatric decline makes the diagnosis of sCJD probable<sup>5</sup> (Figure 1). However, this remains a novel test for a rare disease.

More readily available MRI is a highly valuable tool in the diagnosis of sCJD. In our case, it heightened suspicion of the disease and expedited the RT-QuIC test. MRI changes associated with sCJD have been reported to precede the onset of significant symptoms.<sup>22,23</sup> The characteristic changes are bilateral T2-FLAIR hyperintense signal and restricted diffusion on DWI in the basal ganglia and the rim of the cerebral cortex. The basal ganglia changes preferentially affect the caudate and putamen and are usually but not always symmetrical. The cortical changes are seen as hyperintense signal in the gyri, known as “cortical ribboning,” and typically spare the perirolandic fissure.<sup>24</sup> Signal intensity progresses with disease,<sup>25</sup> and cortical atrophy is seen in end-stages.<sup>26</sup> DWI is most sensitive, followed by FLAIR and T2 sequences.<sup>26,27</sup> It is thought that diffusion restriction results from neuritic microvacuolization associated with spongiform degeneration.<sup>28</sup> Sensitivity of DWI for sCJD is shown to be 95% or more in some studies.<sup>29-31</sup> It also has the fortunate advantage of being the quickest sequence to obtain, minimizing motion artifacts in demented patients who may not tolerate stillness<sup>32</sup> or indeed other investigations.

Remarkably, restricted diffusion can spare the cerebellum even when there are clear cerebellar signs on assessment by an experienced neurologist.<sup>33</sup> Elevated diffusion in the cerebellum has instead been noted on quantitative apparent diffusion coefficient quantitative (ADC) diffusion imaging, as well as increased CSF volumes using volumetric-based imaging (VBM) techniques<sup>24</sup> consistent with cerebellar atrophy. Cohen and colleagues<sup>33</sup> postulated that fluid shifts associated with atrophy may increase diffusivity while only weakly affecting T2. This may explain why our patient showed only subtle cerebellar changes on imaging, despite profound cerebellar dysfunction on examination.

Of note, inter-rater variability of identification of characteristic MRI changes is high.<sup>34</sup> Cortical changes are often missed.<sup>35</sup> In our patient's case, cortical changes were subtle (Figure 2), only evident on DWI and appreciated only with the benefit of hindsight. Characteristic changes are also nonspecific<sup>24</sup> and need to be interpreted in the context of the whole clinical picture, though careful scrutiny of images may help to narrow differential diagnoses. For example, differential

diagnoses for the basal ganglia hyperintensities seen in our patient include Extrapontine Osmotic Demyelination, Epstein-Barr Virus Encephalitis, Auto-immune Encephalopathy, Autosomal Dominant Striatal Degeneration, Wilson Disease, and Wernicke's Encephalopathy. However, many of these are either more prominent or only seen on T2 and FLAIR and rarely involve the cortex.<sup>24</sup> In the context of additional clinical findings supporting the diagnosis, our patient's MRI was strongly suggestive of sCJD. This is reflected in the diagnostic guidelines. Any of characteristic MRI changes, elevation of 14–3–3 in CSF, or PSWCs on EEG make the diagnosis of sCJD probable when it occurs in the setting of rapid neuropsychiatric decline and typical neurological symptoms<sup>5</sup> (Figure 1).

We were able to make a diagnosis of probable diagnosis of sCJD during the patient's life, enabling timely end-of-life care. Our diagnosis was based on MRI findings, CSF positive for 14–3–3 protein, and clinical signs and symptoms. Postmortem neuropathology confirmed our diagnosis. It should be noted that rare genetic forms of CJD may resemble sCJD both clinically and pathologically. Sporadic and genetic forms can only be clearly distinguished with genetic testing, which in this case confirmed sCJD.

## 4 | CONCLUSIONS

Clinicians should consider sCJD whenever the cardinal feature of rapid neuropsychiatric decline is noted. Prompt consideration is necessary to facilitate timely diagnosis, education, and planning toward end-of-life care. Performance of investigations and return of results may scarcely keep pace with clinical progression of disease.

While EEG and CSF proteins 14–3–3 and Tau remain valuable tools to support the diagnosis and RT-QuIC provides greater certainty, careful evaluation of the cortical rim as well as the caudate and putamen on readily accessible DWI may reveal changes in very early disease. Exclusion of reversible disease remains essential. Clinicians should take care not to prematurely narrow the focus of their investigations.

## ACKNOWLEDGEMENTS

We thank Dr Christine Stehman (coordinator of the Australian National CJD Registry, national surveillance unit for CJD) for her assistance with neuropathology, genetic testing, and RT-QuIC data as well as her contributory support of the patient and his family. We thank Professor Catriona A McLean AO (Director, Anatomical Pathology, Alfred Health; Professor, Dept of Medicine CCS, Monash University; Professor, Howard Florey Neurosciences Institute; Director, Victorian Brain Bank Network (VBBN); Director, Victorian Neuromuscular laboratory service (VNLS)) for performing and reporting the postmortem examination.

The first submission of this case study has been published online as a preprint via Authorea: <https://www.authorea.com/users/388447/articles/503251-pre-mortem-diagnosis-of-sporadic-creutzfeldt-jakob-disease-in-practice>.

### AUTHOR CONTRIBUTIONS

Dr Elina T Ziukelis: involved in conception and design, acquisition and analysis of clinical data, and drafting of the manuscript. Dr Vasu Keshav Sharma: assisted with conception and design of imaging-related parts of the manuscript, acquisition and analysis of imaging data, and revision of imaging-related parts of the manuscript. Dr James J Gome: performed conception and design, acquisition and analysis of clinical data, and revision of the manuscript.

### CONSENT STATEMENT

Published with written consent of the patient and his family.

### DATA AVAILABILITY STATEMENT

Data sharing not applicable to this article as no datasets were generated or analysed during the current study. Anonymised laboratory data and medical reports related to diagnosis of the patient are available upon request.

### ORCID

Elina T Ziukelis  <https://orcid.org/0000-0001-6914-8546>

### REFERENCES

- Brown K, Mastrianni JA. The prion diseases. *J Geriatr Psychiatry Neurol.* 2010;23(4):277-298.
- Sandberg MK, Al-Doujaily H, Sharps B, et al. Prion neuropathology follows the accumulation of alternate prion protein isoforms after infective titre has peaked. *Nat Commun.* 2014;5:4347. <https://doi.org/10.1038/ncomms5347>.
- Ladogana A, Puopolo M, Croes EA, et al. Mortality from Creutzfeldt-Jakob disease and related disorders in Europe, Australia, and Canada. *Neurology.* 2005;64(9):1586-1591.
- Iwasaki Y. Creutzfeldt-Jakob disease. *Neuropathology.* 2016;37(2):174-188.
- Centers for Disease Control and Prevention. CDC's diagnostic criteria for Creutzfeldt-Jakob Disease (CJD). 2018.
- Krasianski A, Bohling GT, Heinemann U, et al. Neuropsychological symptoms in sporadic Creutzfeldt-Jakob disease patients in Germany. *J Alzheimers Dis.* 2017;59:329-337.
- Thompson A, MacKay A, Rudge P, et al. Behavioral and psychiatric symptoms in prion disease. *Am J Psychiatry.* 2014;171:265-274.
- Liberski PP. (Ed.). *Prion diseases.* Vol 129. New York, NY: Springer New York; 2017. Neuromethods. <https://link.springer.com/book/10.1007/978-1-4939-7211-1>.
- Lueck CJ, McIlwaine GG, Zeidler M. Creutzfeldt-Jakob disease and the eye. II. Ophthalmic and neurophthalmic features. *Eye.* 2000;14:291-301.
- Landolt HP, Glatzel M, Blattler T, et al. Sleep-wake disturbances in sporadic Creutzfeldt-Jakob disease. *Neurology.* 2006;66(9):1418-1424.
- Paterson RW, Torres-Chae CC, Kuo AL, et al. Differential diagnosis of Jakob-Creutzfeldt disease. *Arch Neurol.* 2012;69(12):1578-1582.
- Wall CA, Rummans TA, Aksamit AJ, Krahn LE, Pankratz VS. Psychiatric manifestations of Creutzfeldt-Jakob disease: A 25-year analysis. *J Neuropsychiatry Clin Neurosci.* 2005;17(4):489-495.
- Chitravis N, Jung RS, Kofskey DM, et al. Treatable neurological disorders misdiagnosed as Creutzfeldt-Jakob disease. *Ann Neurol.* 2011;70(3):437-444.
- Steinhoff BJ, Racker S, Herrendorf G, et al. Accuracy and reliability of periodic sharp wave complexes in Creutzfeldt-Jakob disease. *Arch Neurol.* 1996;53(2):162-166.
- Steinhoff BJ, Zerr I, Glatting M, Schulz-Schaeffer W, Poser S, Kretschmar HA. Diagnostic value of periodic complexes in Creutzfeldt-Jakob disease. *Ann Neurol.* 2004;56:702-708.
- Collins SJ, Sanchez-Juan P, Masters CL, et al. Determinants of diagnostic investigation sensitivities across the clinical spectrum of sporadic Creutzfeldt-Jakob disease. *Brain.* 2006;129:2278-2287.
- Muayqil T, Gronseth G, Camicioli R. Evidence-based guideline: Diagnostic accuracy of CSF 14-3-3 protein in sporadic Creutzfeldt-Jakob disease: report of the guideline development subcommittee of the American Academy of Neurology. *Neurology.* 2012;79(14):1499-1506.
- Otto M, Wiltfang J, Cepek L, et al. Tau protein and 14-3-3 protein in the differential diagnosis of Creutzfeldt-Jakob disease. *Neurology.* 2002;58(2):192-197.
- Zanusso G, Fiorini M, Ferrari S, et al. Cerebrospinal fluid markers in sporadic Creutzfeldt-Jakob disease. *Int J Mol Sci.* 2011;12:6281-6292.
- Atarshi R, Sano K, Satoh K, Nishida N. Real-time quaking-induced conversion. *Prion.* 2011;5(3):150-153.
- Zanusso G, Monaco S, Pocchiari M, Caughey B. Advanced tests for early and accurate diagnosis of Creutzfeldt-Jakob disease. *Nat Rev Neurol.* 2016;12(6):325-333.
- Ukisu R, Kushihashi T, Kitanosono T, et al. Serial diffusion-weighted MRI of Creutzfeldt-Jakob disease. *Am J Roentgenol.* 2005;184:560-566.
- Alvarez FJ, Bisbe J, Bisbe V, Dávalos A. Magnetic resonance imaging findings in pre-clinical Creutzfeldt-Jakob disease. *Int J Neurosci.* 2005;115(8):1219-1225.
- Fragoso DC, da Mota Gonsalves Filho AL, Pacheco FP, et al. Imaging of Creutzfeldt-Jakob disease: Imaging patterns and their differential diagnosis. *Radiographics.* 2017;37(1):234-257.
- Macfarlane RG, Wroe SJ, Collinge J, Yousry TA, Jager HR. Neuroimaging findings in human prion disease. *J Neurol Neurosurg Psychiatry.* 2007;78:664-670.
- Collie DA, Sellar RJ, Zeidler M, Colchester ACF, Knight R, Will RG. MRI of Creutzfeldt-Jakob disease: Imaging features and recommended MRI protocol. *Clin Radiol.* 2001;56:726-739.
- Caobelli F, Cobelli M, Pizzocaro C, Pavia M, Magnaldi S, Guerra UP. The role of neuroimaging in evaluating patients affected by Creutzfeldt-Jakob disease: A systematic review of the literature. *J Neuroimaging.* 2015;25:2-13.
- Mittal S, Farmer P, Kalina P, Kingsley PB, Halperin J. Correlation of diffusion-weighted magnetic resonance imaging with neuropathology in Creutzfeldt-Jakob disease. *Arch Neurol.* 2002;59(1):128-134.

29. Tschampa HJ, Kallenberg K, Kretschmar HA, et al. Pattern of cortical changes in sporadic Creutzfeldt-Jakob disease. *Am J Neuroradiol.* 2007;28:1114-1118.
30. Bahn MM, Parchi P. Abnormal diffusion-weighted magnetic resonance images in Creutzfeldt-Jakob disease. *Arch Neurol.* 1999;56:577-583.
31. Demaere P, Sciot R, Robberecht W, et al. Accuracy of diffusion-weighted MR imaging in the diagnosis of sporadic Creutzfeldt-Jakob disease. *J Neurol.* 2003;250:222-225.
32. Kallenberg K, Schulz-Schaeffer WJ, Jastrow U, et al. Creutzfeldt-Jakob disease: Comparative analysis of MR imaging sequences. *Am J Neuroradiol.* 2006;27:1459-1462.
33. Cohen OS, Hoffman C, Lee H, Chapman J, Fulbright RK, Prohovnik I. MRI detection of the cerebellar syndrome in Creutzfeldt-Jakob disease. *Cerebellum.* 2009;8:373-381.
34. Young GS, Geschwind MD, Fischbein NJ, et al. Diffusion-weighted and fluid-attenuated inversion recovery imaging in Creutzfeldt-Jakob disease: High sensitivity and specificity for diagnosis. *Am J Neuroradiol.* 2005;26:1551-1562.
35. Carswell C, Thompson A, Lukic A, et al. MRI findings are often missed in the diagnosis of Creutzfeldt-Jakob disease. *BMC Neurol.* 2012;12:153.

**How to cite this article:** Ziukelis ET, Sharma VK, Gome JJ. Premortem diagnosis of pathologically confirmed sporadic Creutzfeldt-Jakob disease. *Clin Case Rep.* 2021;9:e04461. <https://doi.org/10.1002/ccr3.4461>