

Available online at www.sciencedirect.com
ScienceDirect
journal homepage: www.elsevier.com/locate/radcr

Case Report

Dual phase ^{18}F -FP CIT PET and $^{99\text{m}}\text{Tc}$ - ECD SPECT findings of Huntington's disease^{☆,☆☆}

KyungAh Chun, MD, PhD*

Department of Nuclear Medicine, Yeungnam University Hospital, Namgu Daemyung 5-dong 317-1, 705-717, Daegu, Korea

ARTICLE INFO

Article history:

Received 6 March 2022

Revised 27 March 2022

Accepted 30 March 2022

ABSTRACT

Fluorine-18 N-3-fluoropropyl-2-beta-carboxymethoxy-3-beta-(4-iodophenyl) nortropine (^{18}F - FP CIT) has been used for the differential diagnosis of atypical parkinsonian disorders, and Technetium 99m ethyl cysteinate dimer ($^{99\text{m}}\text{Tc}$ - ECD) has been used for evaluation of cerebral blood flow. A 60-year-old female with a history of Huntington's disease (HD) with full mutation of cytosine-adenine-guanine (GAG) 18/43 repeats underwent early and late ^{18}F - FP CIT positron emission tomography/computed tomography (PET/CT) and $^{99\text{m}}\text{Tc}$ - ECD single-photon emission computed tomography (SPECT). The ^{18}F -FP CIT PET/CT showed decreased uptake in both basal ganglia, both frontal and parietotemporal lobes at early images, and decreased presynaptic dopamine transporter (DAT) binding in both ventral & posterior putamen at late images. $^{99\text{m}}\text{Tc}$ - ECD SPECT showed decreased perfusion in both basal ganglia, both frontal and temporal lobes. Early ^{18}F - FP CIT PET/CT and $^{99\text{m}}\text{Tc}$ - ECD SPECT images showed similar findings in Huntington's disease.

© 2022 The Authors. Published by Elsevier Inc. on behalf of University of Washington.

This is an open access article under the CC BY-NC-ND license

(<http://creativecommons.org/licenses/by-nc-nd/4.0/>)

Introduction

Huntington's disease (HD) is an autosomal dominant neurodegenerative disorder containing an amplified number of (CAG)_n trinucleotide repeats and pathologically characterized by neuronal loss and neuroreceptor alterations in the striatum, including a reduction in dopamine receptor density. The clinical picture includes motor impairments, cognitive dys-

function, personality change, and susceptibility to mental disorders [1–5].

Early FP CIT imaging reflects perfusion and Laere et al. [6] reported that dual-tracer DAT imaging and perfusion SPECT in combination with discrimination analysis allowed accurate differentiation of the most common forms of Parkinsonism. No direct comparative study of $^{99\text{m}}\text{Tc}$ -ECD perfusion SPECT and early phase (perfusion) ^{18}F -FP-CIT PET has been performed in Huntington's disease, though they are

☆ Acknowledgment: No funding received.

☆☆ Competing Interest: KyungAh Chun declare that he has no conflict of interest.

* Corresponding author.

E-mail address: cka52@yumail.ac.kr

<https://doi.org/10.1016/j.radcr.2022.03.109>

1930-0433/© 2022 The Authors. Published by Elsevier Inc. on behalf of University of Washington. This is an open access article under the CC BY-NC-ND license (<http://creativecommons.org/licenses/by-nc-nd/4.0/>)

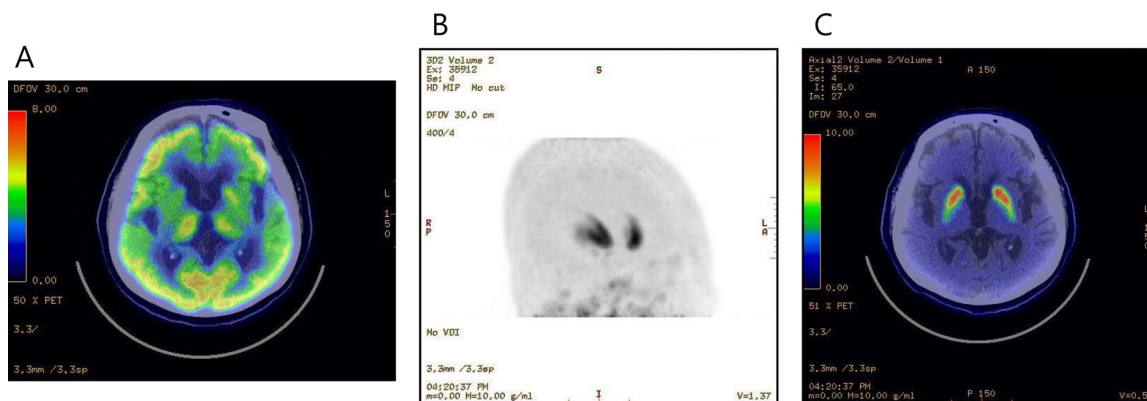


Fig. 1 – Early (A) and late (B, C) ^{18}F -FP CIT PET/CT images were obtained 10 minutes and 3 hours after intravenous injection to assess striatal DAT binding patterns. Early ^{18}F -FP CIT PET/CT showed decreased uptake in both basal ganglia, both frontal and parietotemporal lobes. Decreased presynaptic DAT binding in both ventral & posterior putamen at late MIP (maximum intensity projection) and transaxial images.

considered to be well correlated because both reflect perfusion. In the present case, the author compared perfusion ^{18}F -FP-CIT PET/CT and $^{99\text{m}}\text{Tc}$ -ECD perfusion SPECT in a patient with HD.

Case presentation

A 60-year-old woman with a history of the left hand and leg tremors complained of gait disturbance about 10 years ago and symptoms more progressed. Abnormal behavior and psychotic symptoms also developed. She had a full mutation of cytosine-adenine-guanine (CAG) 18/43 repeats via polymerase chain reaction (PCR) and fragment analysis. Previous studies reported that loss of presynaptic terminals or a reduced expression of dopamine transporter in the nigrostriatal dopaminergic system in Huntington's disease [2]. Both atrophy and loss of substantia nigra neurons have been reported to occur in HD and found that a significant nigrostriatal dysfunction does occur in HD as assessed by means of ^{123}I -FP-CIT SPECT [3,7]. She underwent ^{18}F -FP CIT PET/CT for the differentiation of parkinsonism. Antiparkinsonian drugs has been stopped 12 hours before the scan and perfusion image acquisition was performed within 10 minutes of intravenously injecting 185 MBq of ^{18}F -FP CIT. Late ^{18}F -FP CIT PET/CT images were obtained 3 hours after intravenous injection to assess striatal DAT binding patterns (Fig. 1). Early ^{18}F -FP CIT PET/CT showed decreased uptake in the both basal ganglia, both frontal and parietotemporal lobes (A). Decreased presynaptic DAT binding in both ventral & posterior putamen at late MIP and transaxial images (B, C). $^{99\text{m}}\text{Tc}$ -ECD SPECT images were obtained 30 minutes after injecting $^{99\text{m}}\text{Tc}$ -ECD 925 MBq (25 mCi) using

a SPECT camera. Patient was imaged in a standardized manner (supine, dimly lit room, low noise). $^{99\text{m}}\text{Tc}$ -ECD SPECT images showed decreased perfusion in both basal ganglia, both frontal and temporal lobes. (Fig. 2).

Discussion

Brain metabolism, postsynaptic dopaminergic function, and phosphodiesterase 10A levels were proven to be powerful in assessing disease progression. However, no single technique may be currently considered an optimal biomarker and an integrative multimodal imaging approach combining different techniques should be developed in HD [4]. ^{18}F -FP-CIT PET shows a rapid tracer uptake increase in the brain and early perfusion uptake of FP CIT in dopamine-poor regions (e.g., cerebral cortex and cerebellum) peaks around 10 minutes after injection [8]. Furthermore, early imaging within 10 minutes of injecting ^{18}F -FP-CIT well represents perfusion flow and mimics glucose metabolism in the brain. The presence of striatal hypometabolism is a consistent finding in HD patients, who also show reduced cortical cerebral metabolic rate of glucose (CMRglc), involving in particular, the frontal and temporal lobe [9] and our case shows decreased uptake in both basal ganglia, both frontal and parietotemporal lobes at early perfusion FP CIT images.

Perfusion imaging with ECD or HMPAO may also be helpful because regional cerebral perfusion is usually coupled to cerebral metabolism [10,11]. Previous studies reported that Huntington patients have bilaterally decreased uptake of $^{99\text{m}}\text{Tc}$ -d,l-hexamethylpropylamine oxime (HMPAO) brain perfusion SPECT in the basal ganglia regions involving the heads of

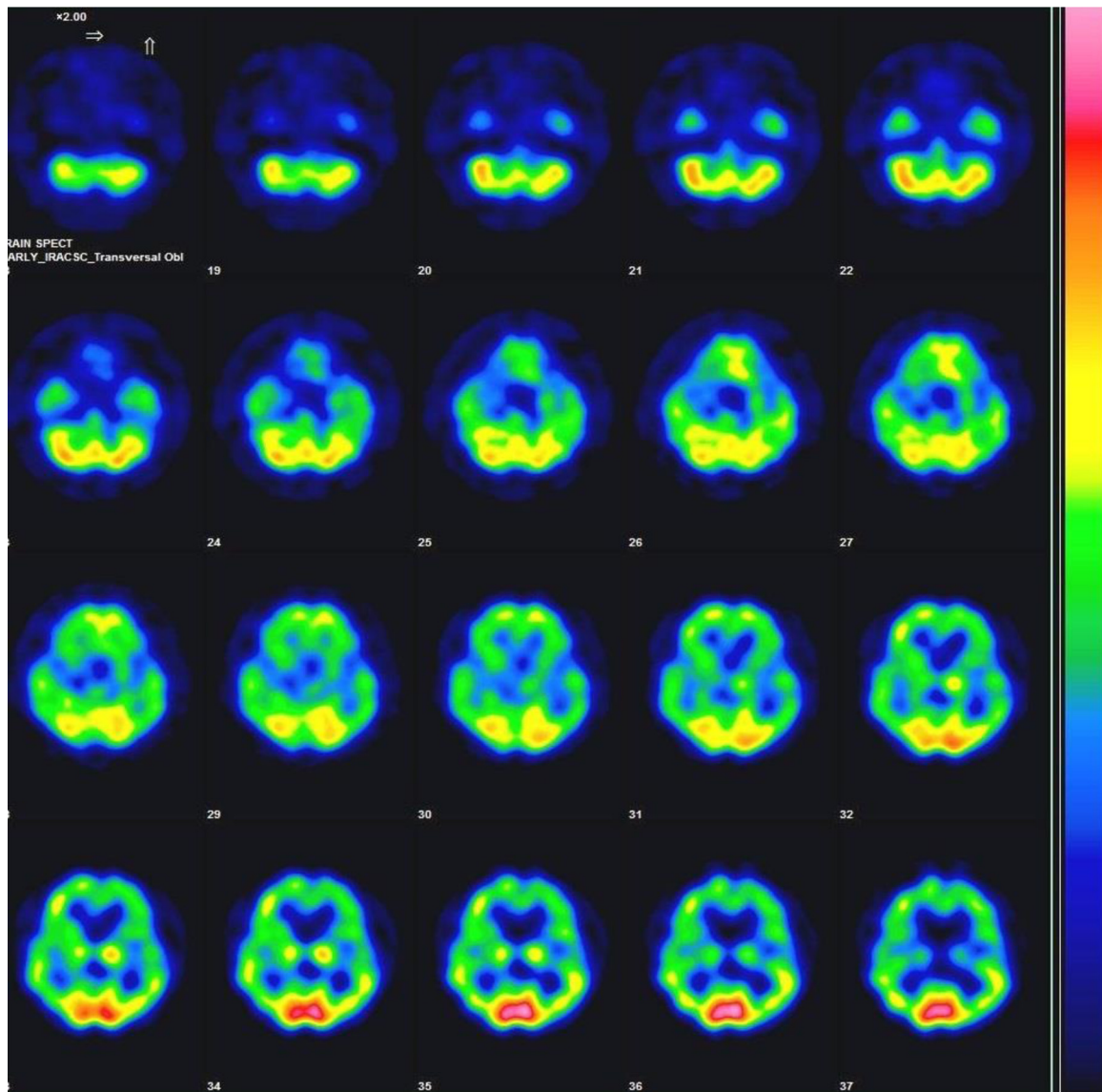


Fig. 2 – ^{99m}Tc-EGD SPECT images showed decreased perfusion in both basal ganglia, both frontal and temporal lobes at transaxial images.

the caudate nuclei and adjacent structures, which reflects decreased neuronal function [5,12]. Also reported decreased uptake in caudate and lentiform nuclei and in the cerebral cortex, especially in the frontal and parietal areas [13]. Accurate diagnoses often require FDG PET or perfusion SPECT and DAT imaging, but there are inconveniences, such as the radiation exposures and high costs involved [8].

Accordingly, the present case showed perfusion FP CIT PET/CT uptake was similar to cerebral perfusion EGD SPECT uptake, a single tracer dual-phase FP CIT PET test might help the differentiation of HD.

Patient consent

Informed consent was obtained.

REFERENCES

- [1] Ginovart N, Lundin A, Farde L, Halldin C, Bäckman L, Swahn CG, et al. PET study of the pre- and post-synaptic dopaminergic markers for the neurodegenerative process in Huntington's disease. *Brain* 1997;120:503–14.
- [2] Gruber B, Kłaczko G, Jaworska M 1, Krzysztos-Russjan J, Anuszczyńska EL, Zielonka D, et al. Huntington' disease—imbalance of amino acid levels in plasma of patients and mutation carriers. *Ann Agric Environ Med Actions* 2013;20(4):779–83.
- [3] Kiferle L, Mazzucchi S, Unti E, Pesaresi I, Fabbri S, Nicoletti V, et al. Nigral involvement and nigrostriatal dysfunction in Huntington's disease: evidences from an MRI and SPECT study. *Parkinsonism Relat Disord* 2013;19(9):800–5.
- [4] Pagano G, Nicolini F, Politis M. Current status of PET imaging in Huntington's disease. *Eur J Nucl Med Mol Imaging* 2016;43(6):1171–82.

-
- [5] Ichise M, Toyama H, Fornazzari L, Ballinger JR, Kirsh JC. Iodine-123-IBZM dopamine D2 receptor and technetium-99m-HMPAO brain perfusion SPECT in the evaluation of patients with and subjects at risk for Huntington's disease. *J Nucl Med* 1993;34(8):1274–81.
- [6] Van Laere K, Casteels C, De Ceuninck L, Vanbilloen B, Maes A, Mortelmans L, et al. Dual-tracer dopamine transporter and perfusion SPECT in differential diagnosis of parkinsonism using template-based discriminant analysis. *J Nucl Med* 2006;47(3):384–92.
- [7] Gamez J, Lorenzo-Bosquet C, Cuberas-Borrós G, Carmona F, Hernández-Vara J, Castelló J, et al. Does reduced [(123)I]-FP-CIT binding in Huntington's disease suggest pre-synaptic dopaminergic involvement? *Clin Neurol Neurosurg* 2010;112(10):870–5.
- [8] Hong CM, Ryu HS, Ahn BC. Early perfusion and dopamine transporter imaging using ¹⁸F-FP-CIT PET/CT in patients with parkinsonism. *Am J Nucl Med Mol Imaging* 2018;8(6):360–72.
- [9] Berti V, Pupi A, Mosconi L, et al. PET/CT in diagnosis of movement disorders. *Ann N Y Acad Sci* 2011;1228:93–108.
- [10] Jin S, Oh M, Oh SJ, Oh JS, Lee SJ, Chung SJ, et al. Additional value of early-phase ¹⁸F-FP-CIT PET image for differential diagnosis of atypical Parkinsonism. *Clin Nucl Med* 2017;42(2):e80–7.
- [11] Jin S, Oh M, Oh SJ, Oh JS, Lee SJ, Chung SJ, et al. Differential diagnosis of parkinsonism using dual-phase F-18 FP-CIT PET imaging. *Nucl Med Mol Imaging* 2013;47(1):44–51.
- [12] Nagel JS, Ichise M, Holman BL. The scintigraphic evaluation of Huntington's disease and other movement disorders using single photon emission computed tomography perfusion brain scans. *Semin Nucl Med* 1991;21(1):11–23.
- [13] Hasselbalch SG, Oberg G, Sørensen SA, Andersen AR, Waldemar G, Schmidt JF, et al. Reduced regional cerebral blood flow in Huntington's disease studied by SPECT. *J Neurol Neurosurg Psychiatry* 1992;55(11):1018–23.