

Retrospective multifactorial analysis of *Pythium keratitis* and review of literature

Bharat Gurnani, Josephine Christy, Shivananda Narayana, Purushothama Rajkumar, Kirandeep Kaur¹, Joseph Gubert²

Purpose: The aim of this work was to study the demographic profile, clinical diagnostic features, challenges in management, treatment outcomes, and ocular morbidity of microbiological culture-proven *Pythium keratitis* in a tertiary eye care hospital in South India. **Methods:** Retrospective analysis of microbiologically proven *Pythium keratitis* patients was performed at a tertiary eye center from October 2017 to March 2020. Demographic details, risk factors, microbiological investigations, clinical course, and visual outcomes were analyzed. **Results:** Thirty patients were analyzed. The mean age was 43.1±17.2 years. Most common risk factors were history of injury in 80% and exposure to dirty water in 23.3%. Visual acuity at baseline was 20/30 to perception of light (PL). The most common clinical presentation was stromal infiltrate and hypopyon in 14 (46.6%) patients each. The microbiological confirmation was based on culture on blood agar and vesicles with zoospores formation with incubated leaf carnation method. Seven (23.3%) patients improved with topical 0.2% Linezolid and topical 1% Azithromycin, 19 (63.3%) patients underwent Therapeutic keratoplasty (TPK) and 4 were lost to follow-up. Seven (23.3%) patients had graft reinfection, and 3 (10%) developed endophthalmitis. The final visual acuity was 20/20- 20/200 in 6 (20%) patients, 20/240-20/1200 in 5 (16.6%) patients, hand movement to positive perception of light in 16 patients and no perception of light (Pthisis Bulbi) in 3 (10%) patients. **Conclusion:** *P. insidiosum keratitis* is a rapidly progressive infectious keratitis with prolonged and relapsing clinical course. It usually results in irreparable vision loss in majority of the patients. Prompt diagnosis, clinical awareness, and specific treatment options are needed for successfully managing this devastating corneal disease.

Key words: Furrowing, *Pythium insidiosum*, *Pythium keratitis*, tentacles, zoospore

Pythium is an Oomycete, also called as parafungus since it causes sight-threatening keratitis in the eye that closely resembles fungal keratitis.^[1] It belongs to Phylum Straminipila, Class Oomycetes, Order Pythiales, and Family Pythiaceae.^[1] The incidence of systemic pythiosis dates back to 1884 where it was first described in British veterinarians,^[1] whereas ocular infection was primarily reported in Thailand,^[2] Australia,^[3] USA^[3] and Israel^[4] in 2009. It has gained importance in recent years owing to the rare presentation, difficult diagnosis by routine microbiological methods, poor visual prognosis due to an absence of response to the conventional antifungals owing to lack of ergosterol in the cell wall, high recurrence rate and associated ocular morbidity.^[5] It is possible that we were missing these cases earlier by falsely labelling them as unidentified fungi or cases diagnosed as fungal according to microscopy but with no growth on culture.^[1] The majority of patients require surgical treatment in the form of therapeutic keratoplasty and the visual outcome is usually poor.^[1-3,5] Hasika

et al. in their retrospective analysis of 71 patients showed that the existing anti-fungal agents are not effective against *Pythium* infections.^[1] It is believed that many of the infections in India, might have been unrecognized due to lack of awareness about identification techniques.^[6] Systemic infections in humans with *Pythium* have also been reported with high rates of morbidity and mortality.^[7] Diagnosis and treatment still remains difficult because of the virulent nature of this organism.^[7] *Pythium keratitis* has added to the corneal blindness due to microbial keratitis globally and is an important area of concern since it doesn't scar easily and afflicted patients require multiple keratoplasty with prolonged recovery time.^[6,7] Early diagnosis, prompt treatment and meticulous follow-up are essential to reduce the burden of *Pythium keratitis*. Reports from South India have featured since 2010, paving the way to increased knowledge about diagnosing techniques like zoospore demonstration and DNA sequencing.^[7] Medical treatment with antibacterial antibiotics including tigeccycline, macrolides, tetracyclines, and linezolid have been studied with susceptibility in animal studies.^[5,8,9] Bagga *et al.* in the prospective trial,

Cornea and Refractive Surgery Services, ¹Pediatric Ophthalmology and Squint Fellow and ²Department of Microbiology, Aravind Eye Hospital and Post Graduate Institute of Ophthalmology, Cuddalore Main Road, Thalavukuppam, Pondicherry, India

FP1680- Adjudged as the Best Paper of Session (BPOS) Cornea 1- All Indian Ophthalmic Conference (AIOC) 2020 Gurugram

Correspondence to: Dr. Bharat Gurnani, Consultant, Cornea and Refractive Services, Aravind Eye Hospital and Post Graduate Institute of Ophthalmology, Cuddalore Main Road, Thalavukuppam, Pondicherry 05 007, India. E-mail: drgurnanibharat25@gmail.com

Received: 03-Jun-2020

Revision: 31-Oct-2020

Accepted: 29-Nov-2020

Published: 30-Apr-2021

Access this article online

Website:

www.ijo.in

DOI:

10.4103/ijo.IJO_1808_20

Quick Response Code:



This is an open access journal, and articles are distributed under the terms of the Creative Commons Attribution-NonCommercial-ShareAlike 4.0 License, which allows others to remix, tweak, and build upon the work non-commercially, as long as appropriate credit is given and the new creations are licensed under the identical terms.

For reprints contact: WKHLRPMedknow_reprints@wolterskluwer.com

Cite this article as: Gurnani B, Christy J, Narayana S, Rajkumar P, Kaur K, Gubert J. Retrospective multifactorial analysis of *Pythium keratitis* and review of literature. Indian J Ophthalmol 2021;69:1095-101.

reported successful management of *Pythium* with Linezolid and Azithromycin.^[5] In this retrospective analysis, we report clinico-microbiological profile of a large case series of patients of *Pythium* keratitis presenting between October 2017 to March 2020 at our tertiary eye care referral centre in South India. The risk factors, demographics, clinical diagnostic dilemmas, microbiological profile, challenges faced in management and treatment outcomes were analysed along with review of literature of the previously published data. We have also aimed to propose a diagnostic and treatment flowchart for *Pythium* cases which will be of help to the all the ophthalmologists while dealing with this virulent infection [Fig. 1].

Methods

This was a retrospective observational study, done over a period of 30 months from October 2017 to March 2020 at our tertiary eye care hospital in South India. The study complied with the tenets of the Declaration of Helsinki. The study approval was obtained from the Institutional Review Board (IRB) of Institutional Ethical Committee (IEC) of Aravind Eye Hospital, Pondicherry (IRB approval number -AEH/PDY/EC/OA/90/2020). The medical case and microbiology records of all culture-positive *Pythium insidiosum* patients were obtained from Electronic Medical Records (EMR) data system [Fig. 1 - Diagnostic Flowchart]. The data was analysed

for the demographic profile, predisposing risk factors, clinical features, microbiological profile, response to medical and surgical treatment and visual outcome. The outcomes of our study were also compared with previously published literature.

The inclusion criteria were (1) All culture-positive *Pythium* cases, and (2) Post keratoplasty button culture-positive cases. The criteria for exclusions were: (1) Incomplete medical records, and (2) Absence of laboratory investigations despite clinical suspicion. The demographic, risk factors, anterior and posterior segments findings along with microbiological results were retrieved from the medical case records. At our center, routinely the corneal scrapings are performed under topical anesthesia using 0.5% proparacaine. These specimens include scrapings for smear examination (Grams stain and 10% potassium hydroxide wet mount) along with subsequent sequential scraping for culture on blood agar and potato dextrose agar. Additionally, zoospore formation of *Pythium insidiosum* was also confirmed by the incubated carnation leaf method.

The treatment was initiated according to clinical and microbiological evaluations. Since on smear examination, *Pythium* hyphae closely mimic fungal hyphae so before the culture results were available, the eyes with positive smears having hyphae were treated with hourly topical antifungals in the form of 5% Natamycin suspension, 1% Itraconazole or 1% Voriconazole. If the ulcer size was less than 4 mm x 4 mm, the eyes were treated

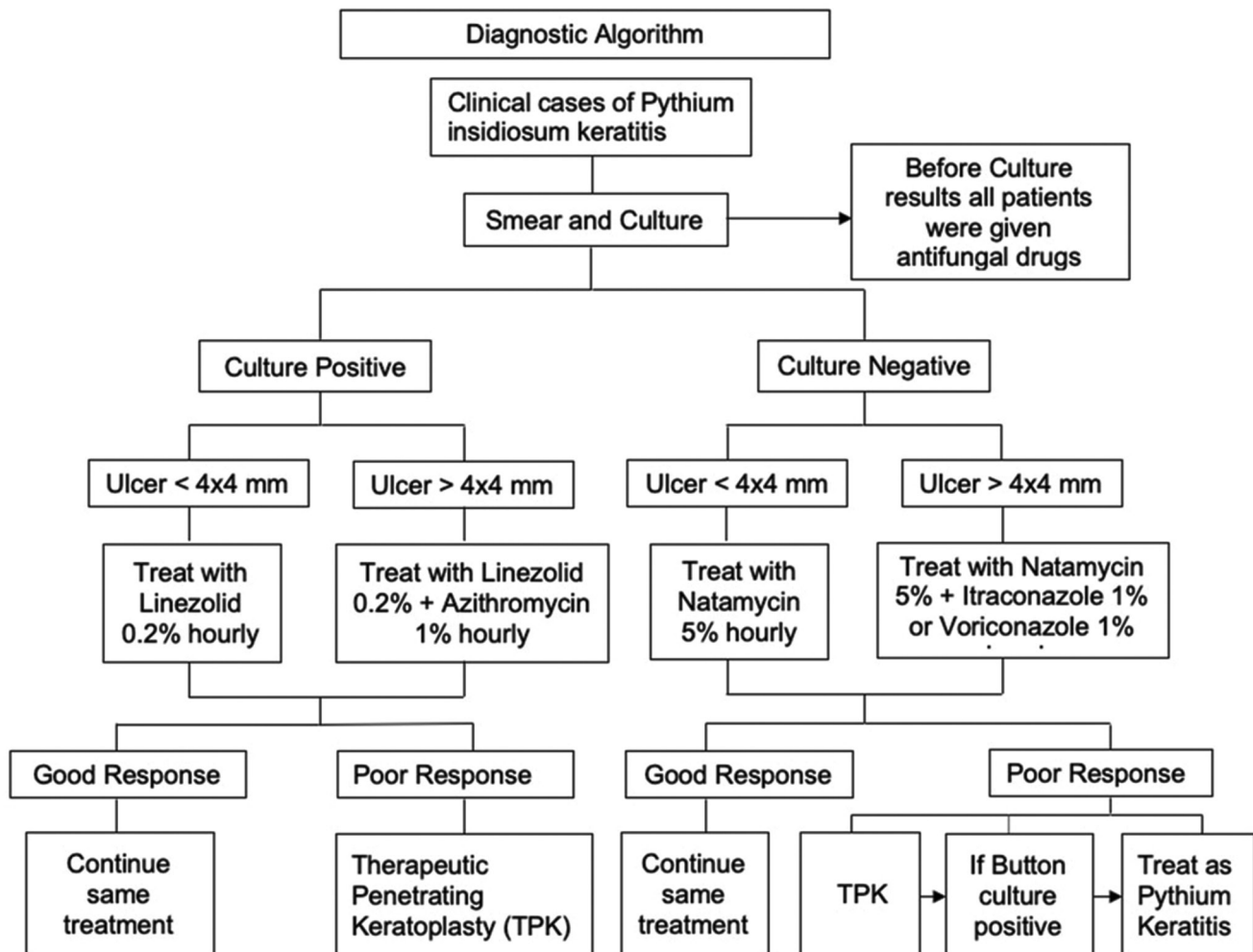


Figure 1: Diagnostic Algorithm for *Pythium* Keratitis

with monotherapy of 5% Natamycin hourly suspension during waking hours and if the ulcer size was more than 4 x 4 mm, they were treated with a combination of either 5% natamycin and 1% Itraconazole hourly or 5% Natamycin and 1% Voriconazole hourly during waking hours. After 5 days when the culture results were available, the flat, feathery colourless colony growth of the *Pythium* species on the blood agar prompted the possibility of *Pythium* which was further confirmed by zoospore formation on incubated carnation leaf. If the culture result was positive for *Pythium insidiosum* the patients were treated with topical Linezolid 0.2% hourly if the ulcer size was less than 4 x 4 mm and topical Linezolid 0.2% and Azithromycin 1% combination if the ulcer was more than 4 x 4 mm during waking hours.^[5] Patients with poor response despite adequate and appropriate antimicrobial therapy, corneal perforation, and non-resolving ulcers involving limbus were subjected to Therapeutic keratoplasty (TPK). The excised corneal button was also cultured on blood agar and potato dextrose agar and was processed for species identification. Postoperatively, all eyes were treated with topical Linezolid 0.2% alone or topical Linezolid 0.2% and Azithromycin 1% combination on an hourly basis for a minimum period of 3 weeks based on clinical picture preoperatively. Moreover, if the culture was positive but button culture was negative post keratoplasty, patients were started on steroids and antibiotic combination in the form 0.1% Dexamethasone or 1% Prednisolone with 0.5% Moxifloxacin after a minimum of 2 weeks of anti-*Pythium* therapy. However, if the culture was positive and button culture was also positive post keratoplasty, patients were started on steroids and antibiotic combination in the form 0.1% Dexamethasone or 1% Prednisolone with 0.5% Moxifloxacin after a minimum of 3 weeks of anti-*Pythium* therapy. On follow-up, the steroids were started in tapering doses under close observation only if there was no recurrence of infection postoperatively. Patients continued to be on maintenance dose of anti-*Pythium* therapy for at least 4 weeks after initiation of topical steroids and were closely monitored for development of re-infection. Those patients with active infection in the form of graft infiltrate or melt were taken for repeat TPK. Graft infections after the second TPK were conservatively treated with lateral tarsorrhaphy.

Literature review

The review of the literature was done using PubMed Central, Cochrane Library database, Google Scholar, and ePUB by using terminology *Pythium*, *Pythium* species, *Pythium keratitis*, *Pythium insidiosum*, *Pythium insidiosum* keratitis and outcomes of *Pythium keratitis*.

Results

A total of 30 patients were analyzed during the period of 30 months. The mean age of the patients was 43.1 ± 17.2 years and it ranged from 9 – 70 years. The male: female ratio was 3:2. The right eye was involved in 18 (60%) patients and left eye was involved in 12 (40%) patients. There were 14 (46.6%) farmers, 8 (26.6%) housewives, 8 (26.6%) students/software professionals. The most common risk factors were, history of injury in 24 patients (80%), and bathing in a pond in 7 patients (23.3%). The average time taken from the onset of symptoms to the presentation was 11.9 days. There was a presentation lag of <10 days in 16 (53.3%) patients, 10–20 days in 8 (26.6%) patients and >21 days in 6 (20%) patients. Visual acuity at presentation ranged from 20/30 to PL+ [Table 1a]. Based on severity grading of ulcers a total of 5 (16.6%) were mild ulcers, 13 (43.3%) were moderate and 12 (40%) fell into severe category. The mean size of ulcer was 23.04 ± 1.2 mm² with a range of 4-81 mm². The clinical features were patchy subepithelial dot-like infiltrates in 7 (23.3%) patients, stromal infiltrate with feathery margins in 11 (36.6%), subtotal infiltrate with peripheral furrowing in 5 (16.6%), tentacular projection in 4 (13.3%), thick endothelial plaque in 8 (26.6%), and total corneal melt in 4 (13.3%) patients. Hypopyon and anterior chamber exudates were present in 14 (46.6%) patients [Table 1b] [Fig. 2a-d]. Healing margins were present in 7 (23.3%) out of 30 patients. The characteristic ‘finger-like’ projections were seen in 4 (13.3%) patients. One patient had co-existing acanthamoeba cysts (diagnosed on culture on non-nutrient agar with *E. coli* overlay) with *Pythium* and was treated for mixed infection.

The smear examination of all patients on 10% KOH wet mount revealed slender hyaline hyphae on the first microscopic examination [Fig. 3a]. Numerous vesicles within the hyphae were observed. The culture results were analysed after 5 days, as flat feathery, colorless colony of *P. insidiosum* grow at 37°C on 5% sheep blood agar after 5 days [Fig. 3b, c]. A total of 22 (73.3%) patients were positive for *Pythium* in their first corneal scraping, 3 (10.7%) patients tested positive on repeat scraping, and 5 (17.8%) patients were identified late in their clinical course when the corneal button removed for keratoplasty turned positive for *Pythium*. Additionally, *Pythium* identification was also confirmed by Zoospore formation on incubated carnation leaf [Fig. 3d]. Before culture results were available 7 (23.3%) patients were treated with topical 5% Natamycin suspension hourly alone, 15 (50%) were treated with topical 5% Natamycin and 1% Voriconazole

Table 1a: Demographics, Risk Factors and Presenting Visual acuity

Parameter	Cases (%)		
	Males (M)	Females (F)	
Gender	18 (60%)	12 (40%)	
Age	0-25 years	26-50 years	51-75 years
	10 (33.33%)	10 (33.33%)	10 (33.33%)
	M- 6 F- 4	M-5 F-5	M-7. F-3
Occupation	Student/Software Student	Farmers	Housewives
	8 (28.5%)	14 (46.6%)	8 (26.6%)
	M- 6 F-2	M-12 F-2	F-8
Risk Factors	Injury	Exposure to dirty water	No history of injury
	24 (80%)	7 (23.3%)	6 (20%)
Presenting Visual Acuity	20/20-20/200	20/240-20/1200	<20/1200
Presentation Lag	8 (26.6%)	7 (23.3%)	15 (50%)
	<10 days	10-20 days	>21 days
	16 (53.3%)	8 (28.5%)	6 (20%)

hourly eye drops, and 8 (26.6%) patients were treated with 5% topical Natamycin eye drop and 1% Itraconazole. After culture results 11 (36.6%) were treated with topical 0.2% Linezolid and 19 (63.3%) patients were treated with topical 0.2% Linezolid and 1% Azithromycin eye drops combination [Table 2a, 2b].

A total of 7 (23.3%) patients healed with medical treatment, 19 (63.3%) underwent TPK and four were lost to follow-up. The graft reinfection was seen in 7 (23.3%) patients out of which 6 (20%) underwent repeat TPK [Fig. 4a-d]. The mean time from presentation to TPK was 11+/-1.4 days. The time for recurrence after TPK varied from 0 to 36 days with a means of 21.2 days. Adjunctive measures like tarsorrhaphy were done for recurrent graft melt in 4 patients and cyanoacrylate glue for perforation in 4 patients [Table 3a]. The average time of occurrence of perforation was 7 days after initial presentation. The most common complication was choroidal detachment in 9 (30%) patients followed by graft reinfection in 7 (23.3%) patients and none of the patients underwent evisceration. Endophthalmitis was noted in 3 (10%) patients [Table 3b].

Among the medically healed and TPK group, the average time taken for presentation was 4.6 days in the former and 14.18 days in the latter. Also, the average infiltrate size at presentation was smaller 14.4 mm² in the healed group and 40.12 mm² in the TPK group [Table 4]. The final visual acuity was 20/20- 20/200 in 6 (20%) patients, 20/240-20/1200 in 5 (16.6%) patients, hand movement to positive perception of light in 16 patients and no perception of light (Phthisis Bulbi) in 3 (10%) patients.

Discussion

P. insidiosum is an oomycete that morphologically exhibits features of branching, sparsely septate or aseptate filaments and cause severe vision-threatening keratitis.^[10] There have been reports of systemic pythiosis from all over the world.^[1,5,10-12] So we need to look the disease from a systemic point of view and also identify the systemic and ocular associations.^[13-17] The various forms of pythiosis include ocular, vascular, cutaneous/subcutaneous and disseminated.^[16] The important

systemic associations include thalassemia/hemoglobinopathy syndrome, aplastic anaemia, paroxysmal nocturnal haemoglobinuria (PNH), chronic arterial insufficiency syndrome^[14] and cavernous sinus thrombophlebitis.^[18] Ocular Pythiosis has been in the recent upsurge in the past 4-5 years and numerous studies have been published on similar literature.^[1,2,7,8,10,11] It is well known that the clinical features of Pythium keratitis closely mimic fungal keratitis and this is the probable reason why we were missing a major chunk of Pythium cases 4-5 years ago.^[1,2,7,11] Recently, a large proportion of studies have been reported from South India probably due to regional prevalence and improved diagnostic techniques.^[1,2,7,11,12]

Agarwal *et al.* in their study reported a total of 46 patients with 6 of them having history of vegetative matter injury and rest with no history of injury were either white-collared professionals, housewives or people from urban locals.^[10] Bagga *et al.* reported 40.4% as farmers, 23.6% were homemakers and 36.0% were students/office goers or of no known occupation.^[5] In our study, 14 (46.6%) patients were agricultural workers and 16 (53.3%) were housewives and software professional showing predominance of non-agricultural workers which agrees with Agarwal *et al.*^[10] and Bagga *et al.*^[5] Most of the corneal infiltrate in our study were stromal with feathery margins. Hasika *et al.*^[11]

Table 1b: Distribution of Clinical features

Parameter	Cases n (%)
Stromal infiltrate with feathery margins	11 (36.6%)
Corneal melt	4 (13.3%)
Subepithelial infiltrates	7 (23.3%)
Hypopyon/Anterior chamber exudates	14 (46.6%)
Endothelial plaque	8 (26.6%)
Peripheral furrowing	5 (16.6%)
Tentacular projections	4 (13.3%)

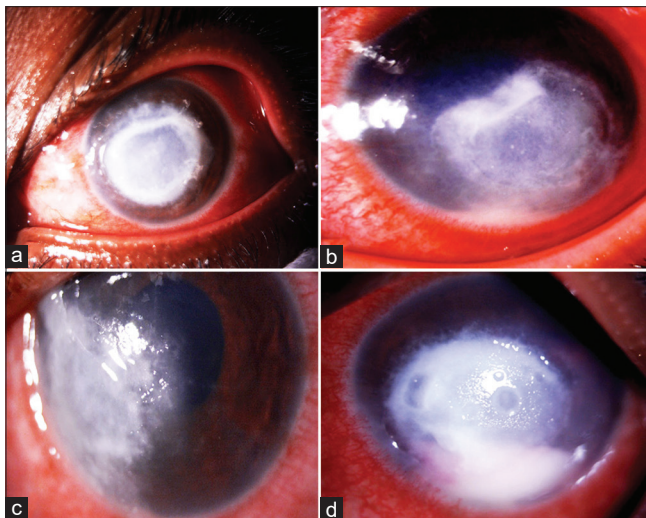


Figure 2: (a) Slit-lamp image of the cornea showing central, dense, greyish-white circular 8x8 mm infiltrate with peripheral tentacular projections (b) Image depicting diffuse white stromal infiltrates. In addition peripheral furrowing is seen in this image inferiorly from 4 o'clock to 6 o'clock hour (c) Image depicting diffuse white stromal infiltrates showing tendency for limbal spread (d) Image depicting diffuse white full thickness infiltrates along with anterior chamber hypopyon

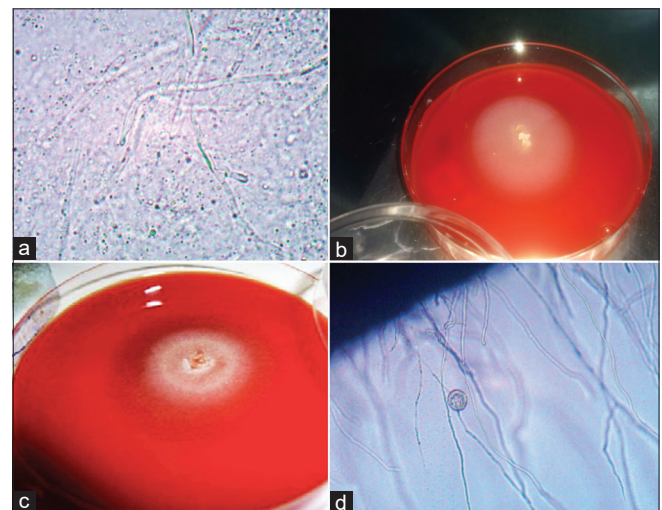


Figure 3: (a) 10% KOH wet mount preparation of corneal scraping of *Pythium insidiosum* showing linear elongated sparsely septate hyaline hyphae. A number of small vesicles within the hyphae are also observed (b) A 3-day old subculture of *P. insidiosum* at 37°C grown on 5% sheep blood agar (c) A 5-day old subculture of *P. insidiosum* at 37°C grown on 5% sheep blood agar^[29] (d) A small round vesicle with numerous zoospores that developed after 3 h of incubation before zoospore release (x10) using cultured leaf carnation method

Table 2a: Treatment Details

Parameter	Drugs used Cases (%)		
	Natamycin	Natamycin + Voriconazole	Natamycin + Itraconazole
Before culture results cases	7 (23.3%)	15 (50%)	8 (26.6%)
After culture result cases	Drugs used Cases (%)		
	Linezolid alone	Linezolid + Azithromycin	
	11 (36.6%)	19 (63.3%)	

Table 2b: Comparison of Linezolid vs Linezolid + Azithromycin group

	Linezolid alone 11 (36.6%)			Linezolid + Azithromycin 19 (63.3%)		
	20/20-20/200	20/240-20/1200	HM-PL+/PL-	20/20-20/200	20/240-20/1200	HM-PL+/PL-
Presenting visual acuity	20/20-20/200	20/240-20/1200	HM-PL+/PL-	20/20-20/200	20/240-20/1200	<20/1200
Cases n (%)	5 (16.6%)	6 (20%)	5 (45.5%)	3 (10%)	1 (3%)	15 (50%)
Final visual acuity	20/20-20/200	20/240-20/1200	HM-PL+/PL-	20/20-20/200	20/240-20/1200	HM-PL+/PL-
Cases n (%)	3 (27.2%)	3 (27.2%)	5 (45.5%)	3 (10%)	2 (6.6%)	14 (46.6%)
Corneal Scar		8 (72.7%)			11 (57.8%)	
Therapeutic Keratoplasty		6 (54.5%)			13 (68.4%)	
Repeat Therapeutic Keratoplasty		1 (9%)			5 (26.3%)	
Penetrating Keratoplasty		6 (54.5%)			8 (42.1%)	

Table 3a: Treatment Outcomes

Parameter	Cases (%)
Healed with Medical Treatment	7 (23.3%)
Therapeutic Keratoplasty	19 (63.3%)
Repeat Therapeutic Keratoplasty	6 (20%)
Glue + Bandage Contact Lens	4 (13.3%)
Tarsorrhaphy	4 (13.3%)
Lost to follow-up	4 (13.3%)

Table 3b: Complications Post Keratoplasty

Parameter	Cases
Choroidal Detachment	9 (30%)
Graft Reinfection	7 (23.3%)
Retinal Detachment	3 (10%)
Secondary Glaucoma	6 (20%)
Endophthalmitis	3 (10%)
Evisceration	0 (0%)

Table 4: Comparison of Treatment Groups

Parameter	Healed with Medical Treatment	Healed with Surgical Treatment
Cases	7 (23.3%)	19 (63.3%)
Presentation lag in days	4.2	13.5
Average infiltrate size in mm ²	14.4	40.12
Average healing time	37 days	71 days

No statistically significant difference between the two groups

in their retrospective analysis found that hyphate edges of the infiltrates were seen in most patients. With typical multiple linear tentacle-like infiltrates in 36 of 71 (50.7%) patients,

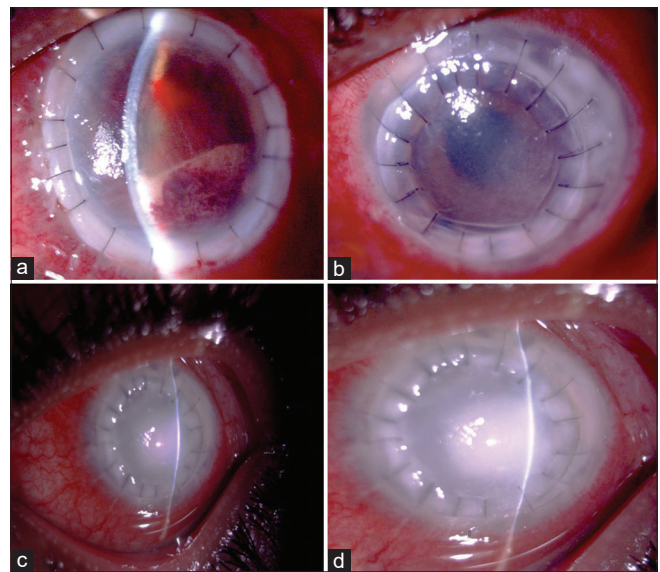


Figure 4: (a) Slit-lamp image depicting graft reinfection with anterior chamber exudates (b) Slit lamp image depicting graft reinfection with host rim margin infiltrate (c) Slit lamp image depicting graft reinfection with full thickness infiltrate of host and donor cornea (d) Another slit lamp image depicting graft reinfection with full thickness infiltrate of host and donor cornea

dot-like infiltrates at the mid-stromal level surrounding the main infiltrate in 15 (21.1%) patients and peripheral furrowing in 9 (12.7%) patients. In our case series, we found dot-like infiltrates, peripheral furrowing, and tentacle-like infiltrate margins in 7 (23.3%) patients. The other important features noted in our study were patchy scattered stromal infiltrates, with a tendency to spread towards limbus and a trace hypopyon similar to that described by Hasika *et al.*^[1] Mittal *et al.*^[18] in their analysis of 38 cases found that 5 patients had perforation and hypopyon at presentation. In our case series, thick endothelial and anterior chamber exudates were noted in 14 (46.6%)

Table 5: Review of Literature

Parameter	Bagga <i>et al.</i> BJO 2018	Hasika <i>et al.</i> IJO 2019	Aggarwal S <i>et al.</i> BJO 2018	Sharma <i>et al.</i> Cornea 2015	Our study
Study period	2014-2016	2016-2017	2014-2017	2010-2014	2017-2020
No of Eyes	114	71	46	13	30
Healed with Medical treatment	11.4%	4.2%	0	0	20%
Required TPK	85%	67.6%	100%	84.6%	63.3%
Repeat TPK	-	54.2%	56.5%	7.6%	20%
Evisceration	1.75%	4.2%	10.8%	15.3%	0%
Globe Salvage	-	43.7%	84.7%	69.2%	90%
Phthisis/No PL	0.8%	23.9%	10.8%	15.3%	10%

patients confirming the virulent nature and fast progression of the organism and perforation was noted in 4 (13.3%). This is in consonance with the published literature.^[1,5,7,8,11,12,19]

On 10% KOH wet mount, *Pythium insidiosum* is seen as long slender hyaline sparsely septate or aseptate hyphae and perpendicular lateral branches. In comparison fungal hyphae have septations with branching at various angles and is usually difficult to differentiate on KOH wet mount. Numerous vesicles within the hyphae are usually observed.^[19] In the laboratory, the combination of this with classic flat feathery colorless colony on blood agar along with zoospore formation and molecular diagnostic tools help in identification and confirmation of *Pythium* infection.^[7] The average time taken for blood agar growth is approximately 3-5 days. Increased awareness among microbiologists about these specific hyphae characteristics and blood agar growth morphologies can improve early diagnosis. The pointers of suspicion for ocular microbiologist can be clinical features like presence of tentacles, peripheral furrowing and rapidly progressive infiltrate, long slender hyaline sparsely septate and aseptate hyphae and perpendicular lateral branches. The definitive confirmation is by zoospore identifications by leaf incarnation method.

Various treatment and management options have been proposed for treatment of *Pythium* keratitis.^[1,2,7-12,16,20,21] Bagga *et al.* showed that the proportion of healed ulcers were more 35.2% with antibacterial treatment as compared to 15.3% with antifungal treatment.^[5,22] In our study, during the clinical course healing margins were seen in 7 out of 30 patients, thereby highlighting the success of medical treatment with topical Linezolid and Azithromycin which agrees with prospective analysis by Bagga *et al.*^[2] Early presentation with smaller infiltrate size was associated with a better outcome. The patients who improved with medical treatment had mild- moderate severity of ulcer, smaller ulcer size (4 × 4 mm) and less than 1/3 of stromal depth with fewer tentacular projections, whereas the patients who underwent TPK had severe ulcer on presentation, involving visual axis, larger ulcer size (>4 mm × 4 mm), mid- deep stromal infiltrates with peripheral furrowing encroaching limbus and few patients showed early perforation. Among the 19 patients who underwent TPK, 20% required a repeat TPK for recurrence of infection and among them 4 underwent tarsorrhaphy for repeat graft melt. Cyanoacrylate glue was also used to stabilize the corneal melt in 4 patients. Whether it is the virulence of the organism, subclinical response to the available medical therapy, delay in diagnosis, organism load or mixed infection which causes recurrence or worsening is yet to be understood. Though endophthalmitis is a grave complication in *Pythiosis*, our study had only 3 (10%) cases, which were less compared to other studies. The probable reason could be that, an early TPK was considered in our treatment plan whenever the diagnosis

of *Pythium* was made, in view of the existing poor prognosis. This led to lesser posterior segment involvement and improved overall outcome. Moreover, our globe salvage rate was 90%, which was comparatively higher than the published literature. Early identification of *Pythium* keratitis with usage of proper diagnostic algorithm helped us to initiate appropriate antibiotic treatment based on existing literature.^[1,2,7-12,23] This might explain the fairer outcome in our study sample.

The limitations of our study include small sample size, retrospective nature of the study, patients were not subjected to Polymerase Chain Reaction (PCR)^[24-28] non-availability of higher diagnostic modalities like confocal microscopy^[11] and few patients were lost to follow-up. Hence, early diagnosis and treatment with upcoming antibiotics like Azithromycin and Linezolid can definitely improve outcomes. If significant response is not seen in the first week, immediate TPK, before the formation of thick anterior chamber (AC) exudates can fasten the recovery. The AC exudates in the angle can remain as a constant source of infection even after successful clearance of corneal infiltrate during TPK. Development of AC exudates can be seen as a sign for poor prognosis. However, a prospective study with larger sample size would help us to arrive at better conclusions. Further large scale randomized clinical trials are needed to exactly pinpoint more appropriate and definitive medical therapy. A comparative analysis of our study with the large scale clinical studies of *Pythium* keratitis is highlighted in Table 5.

Conclusion

To conclude, *Pythium* keratitis is a devastating ocular disease which closely mimics fungal keratitis. Based on our analysis, medical treatment with Azithromycin and Linezolid can be employed as the current standard of care for *P. insidiosum*. TPK still remains the mainstay of treatment of rapidly progressive and non-responsive disease. Our paper also highlights a planned diagnostic algorithm and treatment protocol [Fig. 1] which can be employed by the ophthalmologists while managing these difficult cases with good anatomical and functional outcomes.

Acknowledgements

Aravind Eye Hospital and Post Graduate Institute of Ophthalmology, Cuddalore Main Road, Thavalukuppam, Pondicherry, India, 605007. The authors confirm the consent and thank European Journal of Ophthalmology for granting permission for use of image 3(c) which was published ahead of print.

Financial support and sponsorship

Nil.

Conflicts of interest

There are no conflicts of interest.

References

- Hasika R, Lalitha P, Radhakrishnan N, Rameshkumar G, Prajna NV, Srinivasan M. *Pythium keratitis* in South India: Incidence, clinical profile, management, and treatment recommendation. *Indian J Ophthalmol* 2019;67:42-7.
- Lelievre L, Borderie V, Garcia-Hermoso D, Brignier AC, Sterkers M, Chaumeil C, *et al.* Imported *pythium insidiosum* keratitis after a swim in Thailand by a contact lens-wearing traveler. *Am J Trop Med Hyg* 2015;92:270-3.
- Badenoch PR, Mills RA, Chang JH, Sadlon TA, Klebe S, Coster DJ. *Pythium insidiosum* keratitis in an Australian child. *Clin Exp Ophthalmol* 2009;37:806-9.
- Tanhehco TY, Stacy RC, Mendoza L, Durand ML, Jakobiec FA, Colby KA. *Pythium insidiosum* keratitis in Israel. *Eye Contact Lens* 2011;37:96-8.
- Bagga B, Sharma S, Madhuri Guda SJ, Nagpal R, Joseph J, Manjulatha K, *et al.* Leap forward in the treatment of *Pythium insidiosum* keratitis. *Br J Ophthalmol* 2018;102:1629-33.
- He H, Liu H, Chen X, Wu J, He M, Zhong X. Diagnosis and treatment of *pythium insidiosum* corneal ulcer in a Chinese child: A case report and literature review. *Am J Case Rep* 2016;17:982-8.
- Sharma S, Balne PK, Motukupally SR, Das S, Garg P, Sahu SK, *et al.* *Pythium insidiosum* keratitis: Clinical profile and role of DNA sequencing and zoospore formation in diagnosis. *Cornea* 2015;34:438-42.
- Loreto ES, Tondolo JS, Pilotto MB, Alves SH, Santurio JM. New insights into the *in vitro* susceptibility of *Pythium insidiosum*. *Antimicrob Agents Chemother* 2014;58:7534-7.
- Mendoza L, Newton JC. Immunology and immunotherapy of the infections caused by *Pythium insidiosum*. *Med Mycol* 2005;43:477-86.
- Agarwal S, Iyer G, Srinivasan B, Benurwar S, Agarwal M, Narayanan N, *et al.* Clinical profile, risk factors and outcome of medical, surgical and adjunct interventions in patients with *Pythium insidiosum* keratitis. *Br J Ophthalmol* 2019;103:296-300.
- Permpalung N, Worasilchai N, Chindamporn A. Human *Pythiosis*: Emergence of Fungal-Like Organism. *Mycopathologia* 2020;185:801-12.
- Ramappa M, Nagpal R, Sharma S, Chaurasia S. Successful medical management of presumptive *Pythium insidiosum* keratitis. *Cornea* 2017;36:511-4.
- Triscott JA, Weedon D, Cabana E. Human subcutaneous *pythiosis*. *J Cutan Pathol* 1993;20:267-71.
- Laohapensang K, Rutherford RB, Supabandhu J, Vanittanakom N. Vascular *pythiosis* in a thalassemic patient. *Vascular* 2009;17:234-8.
- Smith F. The pathology of bursattee. *Vet J* 1884;19:16-7.
- Permpalung N, Worasilchai N, Plongla R, Upala S, Sanguankeo A, Paitoonpong L, *et al.* Treatment outcomes of surgery, antifungal therapy and immunotherapy in ocular and vascular human *pythiosis*: A retrospective study of 18 patients. *J Antimicrob Chemother* 2015;70:1885-92.
- Grooters AM, Whittington A, Lopez MK, Boroughs MN, Roy AF. Evaluation of microbial culture techniques for the isolation of *Pythium insidiosum* from equine tissues. *J Vet Diagn Invest* 2002;14:288-94.
- Rathi A, Chakrabarti A, Agarwal T, Pushker N, Patil M, Kamble H, *et al.* *Pythium keratitis* leading to fatal cavernous sinus thrombophlebitis. *Cornea* 2018;37:519-22.
- Mittal R, Jena SK, Desai A, Agarwal S. *Pythium insidiosum* keratitis: Histopathology and rapid novel diagnostic staining technique. *Cornea* 2017;36:1124-32.
- Kalra P, Ahrwar LK, Mittal R, Ranjith K, Das S, Manjulatha K, *et al.* Clinical and histopathological evaluation of a rabbit model for *pythium insidiosum* keratitis. *Curr Eye Res* 2020;45:542-9.
- Gaastra W, Lipman LJ, De Cock AW, Exel TK, Pegge RB, Scheurwater J, *et al.* *Pythium insidiosum*: An overview. *Vet Microbiol* 2010;146:1-6.
- Bagga B, Kate A, Mohamed A, Sharma S, Das S, Mitra S. Successful strategic management of *Pythium insidiosum* keratitis with antibiotics. *Ophthalmology* 2020;S0161-6420 (20) 30512-1. doi: 10.1016/j.ophtha. 2020.05.046.
- Salipante SJ, Hoogestraat DR, SenGupta DJ, Murphey D, Panayides K, Hamilton E, *et al.* Molecular diagnosis of subcutaneous *Pythium insidiosum* infection by use of PCR screening and DNA sequencing. *J Clin Microbiol* 2012;50:1480-3.
- Krajaejun T, Prachartam R, Wongwaisayawan S, Rochanawutininom M, Kunakorn M, Kunavisarut S, *et al.* Ocular *pythiosis*: Is it under-diagnosed? *Am J Ophthalmol* 2004;137:370-2.
- Kosriukvongs P, Chaiprasert A, Uprasertkul M, Chongcharoen M, Banyong R, Krajaejun T, *et al.* Evaluation of nested PCR technique for detection of *Pythium insidiosum* in pathological specimens from patients with suspected fungal keratitis. *Southeast Asian J Trop Med Public Health* 2014;45:167-73.
- Thongsri Y, Wonglakorn L, Chaiprasert A, Svobodova L, Hamal P, Pakarasang M, *et al.* Evaluation for the clinical diagnosis of *Pythium insidiosum* using a single-tube nested PCR. *Mycopathologia* 2013;176:369-76.
- Keeratijarut A, Lohnoo T, Yingyong W, Rujirawat T, Srichunrusami C, Onpeaw P, *et al.* Detection of the oomycete *Pythium insidiosum* by real-time PCR targeting the gene coding for *exo-1,3-β-glucanase*. *J Med Microbiol* 2015;64:971-7.
- Vanittanakom N, Supabandhu J, Khamwan C, Preparattapan J, Thirach S, Prasertwitayakij N, *et al.* Identification of emerging human-pathogenic *Pythium insidiosum* by serological and molecular assay-based methods. *J Clin Microbiol* 2004;42:3970-4.
- Gurnani B, Narayana S, Christy J. Successful management of pediatric *pythium insidiosum* keratitis with cyanoacrylate glue, linezolid, and azithromycin: Rare case report. *Eur J Ophthalmol*. 2021 Mar 28;11206721211006564. doi: 10.1177/11206721211006564. Epub ahead of print. PMID: 33779337.