

# Expanding Indications for Flow Diverters: Distal Aneurysms, Bifurcation Aneurysms, Small Aneurysms, Previously Coiled Aneurysms and Clipped Aneurysms, and Carotid Cavernous Fistulas

**Nicola Limbucci, MD\***  
**Giuseppe Leone, MD\*\***  
**Leonardo Renieri, MD\***  
**Sergio Nappini, MD\***  
**Federico Cagnazzo, MD\***  
**Antonio Laiso, MD\***  
**Mario Muto, MD\***  
**Salvatore Mangiafico, MD\***

\*Neurovascular Interventional Unit, Careggi University Hospital, Florence, Italy; \*\*Department of Neuroradiology, Cardarelli Hospital, Naples, Italy

## Correspondence:

Nicola Limbucci, MD,  
 Neurovascular Interventional Unit,  
 Careggi University Hospital,  
 Largo Giovanni Alessandro Brambilla 3,  
 50134 Florence, Italy.  
 Email: nicolalimb@gmail.com

Received, February 24, 2019.

Accepted, June 6, 2019.

Published Online, December 16, 2019.

© Congress of Neurological Surgeons 2019.

This is an Open Access article distributed under the terms of the Creative Commons Attribution-NonCommercial-NoDerivs licence (<http://creativecommons.org/licenses/by-nc-nd/4.0/>), which permits non-commercial reproduction and distribution of the work, in any medium, provided the original work is not altered or transformed in any way, and that the work is properly cited. For commercial re-use, please contact [journals.permissions@oup.com](mailto:journals.permissions@oup.com)

Flow diverter devices have gained wide acceptance for the treatment of unruptured intracranial aneurysms. Most studies are based on the treatment of large aneurysms harboring on the carotid syphon. However, during the last years the “off-label” use of these stents has widely grown up even if not supported by randomized studies. This review examines the relevant literature concerning “off-label” indications for flow diverter devices, such as for distal aneurysms, bifurcation aneurysms, small aneurysms, recurrent aneurysms, and direct carotid cavernous fistulas.

**KEY WORDS:** Intracranial aneurysm, Flow diverter device, Distal aneurysm, Bifurcation aneurysm, Recurrent aneurysm, Carotid cavernous fistula

*Neurosurgery* 86:585–594, 2020

DOI:10.1093/neuros/nyz334

[www.neurosurgery-online.com](http://www.neurosurgery-online.com)

**F**low diverter devices (FDD) have gained wide acceptance for the treatment of unruptured intracranial aneurysms. Actually, most of the evidence is based on Pipeline Embolization Device (PED) (Medtronic) and its evolution Pipeline flex, which used to be FDA-approved only for wide-neck internal carotid artery (ICA) aneurysms, whereas only recently indication was extended to small aneurysms as well. The PUFs trial showed high efficacy and safety of PED for the treatment of complex ICA aneurysms (complete occlusion rate 86.8% at one year; major ipsilateral stroke or neurologic death in 5.6% of patients).<sup>1</sup> The 5-yr follow-up reported complete occlusion in 95.2% of the cases.<sup>2</sup>

Other FDD have European approval for use in distal anatomy. In the clinical practice, use of FDD has been extended to other kind of aneurysms and, albeit there are neither

prospective trials nor strong evidences, initial results appear to be encouraging. Our aim is to review the expanding indications for FDDs, focusing on treatment results and pitfalls. Patient consent was not required, as no identifiable individual patient characteristics were reported.

## DISTAL ANEURYSMS

Distal aneurysms may be defined as those located beyond the circle of Willis. They may be either saccular (at the level of bifurcations mainly), fusiform, or dissecting aneurysms. Indeed, delivering a FDD into distal and small vessels may be technically challenging, as these systems are stiffer and have a higher profile than conventional stents.

The PED and other FDDs require a 0.027-inch microcatheter. However, low-profile FDD, dedicated to small vessels, have been lately developed. The first has been the small-sized version of the dual layer Flow Direction Endoluminal Device (FRED) (MicroVention, Aliso Viejo, California), called FRED Jr More recently, the P48MW Flow Modulation Device (Phenox GmbH, Bochum, Germany) has been launched. Both FRED Jr and P48MW are delivered through a 0.021-inch microcatheter. The P48MW is also available in the HCP

**ABBREVIATIONS:** AComA, anterior communicating artery; CS, cavernous sinus; FDD, flow diverter device; FRED, Flow Direction Endoluminal Device; ICA, internal carotid artery; MCA, middle cerebral artery; PComA, posterior communicating artery; PCA, posterior cerebral artery; PED, Pipeline Embolization Device; SAH, subarachnoid hemorrhage

version, which is coated with a hydrophilic polymer. The coating should reduce platelet adhesion.<sup>3</sup> The device has been approved for implantation under single antiplatelet therapy in Europe, although no postmarket data have been published.

Very recently, the Silk Baby Vista (Balt Extrusion, Montmorency, France) has been launched in Europe; this is the only FDD delivered through a 0.017-inch microcatheter. The device appears safe in distal aneurysms,<sup>4</sup> but follow-up data are missing.

During PED deployment, extreme attention has to be paid not to perforate small, distal branches with the inner wire as it is pushed forward while unsheathing the stent. FRED Jr delivery wire is shorter and it remains inside the stent during its deployment, thus minimizing the risk of perforation; however, the drawback of this system probably is the inferior stability. Interestingly, the P48 inner wire can be moved independently from the implant, potentially improving safety and stability during deployment.

Overall, small vessel diameter, distal navigation, and coverage of bifurcation branches and perforator may pose challenges, increasing the risk of complications. Studies on flow diversion in distal aneurysms are difficult to compare because the definition of “distal” is not unique, and the type and location of included cases may be heterogeneous.

Investigating the literature, the rate of adequate occlusion and treatment-related complications ranges from 60% to 90% and 4% to 17%, respectively.<sup>5-9</sup> In a series of 28 anterior circulation distal aneurysms treated by PED, complete/near complete occlusion occurred in 92.6% of the patients at 6 months, with a 10.7% ischemic complication rate. In this series, most of the aneurysms were located on the middle cerebral artery (MCA), but many cases were fusiform or dissecting.<sup>5</sup> In a recent multicentric cohort of 65 aneurysms located at or beyond A2, M2, and P2 segments treated with PED, authors reported complications in 7.7% of patients. The occlusion rate was 83% (mean follow-up time: 6 mo).<sup>6</sup> In two series of distal vessel aneurysms treated with the FRED Jr or the PED complete/near complete, occlusion rate was 78%. The rate of ischemic events varied from 7% to 17.4%.<sup>7,8</sup> In the Ravindran series, the complete occlusion rate varied between anterior and posterior circulation (58.8% vs 91.7%).<sup>8</sup> A meta-analysis of 26 studies with 572 distal aneurysms, with very wide inclusion criteria, reported procedural morbidity and mortality 9% and 4%, respectively. Interestingly, the complete occlusion rate was higher in fusiform and dissecting aneurysms than in saccular aneurysms (73% vs 55%).<sup>9</sup>

Many distal aneurysms harbor on vessels smaller than 2.5 mm, which is the smallest available PED diameter. The FRED Jr is indicated for vessels from 2 mm and the P48 from 1.75 mm. Nevertheless, FDD placement in very small vessels (<2 mm) is possible in adequately selected and prepared patients, although special care must be taken (Figure 1). There is actually no uniformity in reporting ischemic complications in small vessels. Puri et al<sup>10</sup> reported a small series of patients treated with PED

with no complications. However, in the Ravindran et al.<sup>8</sup> series, in which most of vessels were <2 mm and some were <1.5 mm, immediate thrombosis after FDD placement occurred in 10.9% of cases, but it was resolved by anti-GP IIb/IIIa administration. Late in-stent stenosis is another concern of FDD in distal vessels, and it has been reported in up to 27% of cases, although it is usually asymptomatic and may improve at follow-up.<sup>8-11</sup> Probably, stenosis occurs progressively because of neointimal hyperplasia or inflammation.<sup>12</sup>

It is important to point out that many studies about flow diversion for distal aneurysms focused on lesions along the MCA, which is relatively larger than very distal arteries.<sup>5-7,9-13</sup> Few studies focused on the FDD in very distal locations and small vessels. In a literature review of 38 posterior cerebral artery (PCA) aneurysms, including very distal P2-P3, complete occlusion was observed in 88% of patients, but complication rate was 26%; interestingly, in fusiform aneurysms, usually originating from the distal PCA, occlusion occurred in all cases but the complication rate was 43%.<sup>14</sup> In a series of 17 complex pericallosal aneurysms, all treated with 0.027-inch system FDD, the complete and near complete occlusion rate was 81%, but permanent morbidity was 13%; accordingly, authors concluded that in pericallosal artery FDD is a feasible option (Figure 2), but it should be reserved for aneurysms not manageable with simple coiling.<sup>15</sup>

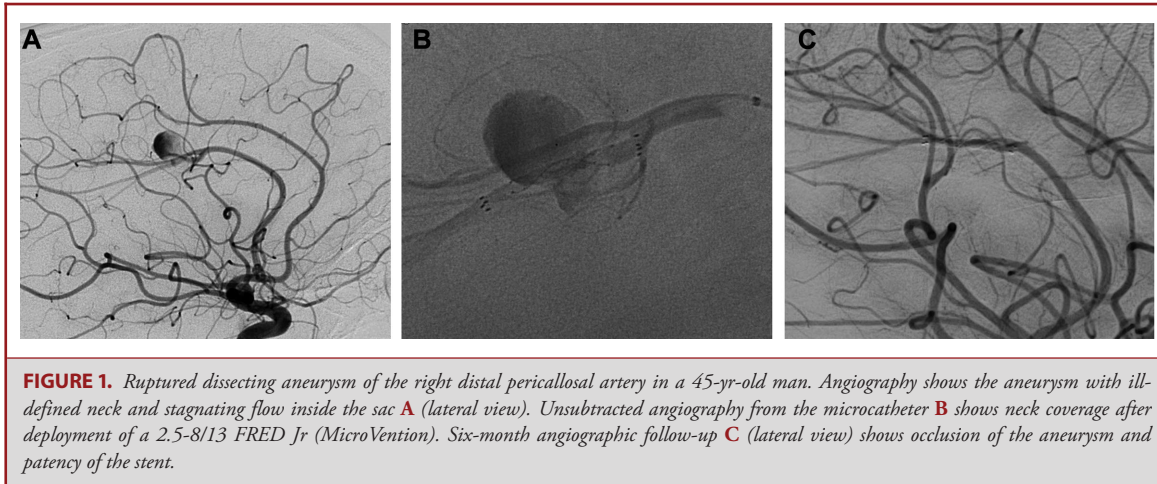
## BIFURCATION ANEURYSMS

### Safety and Outcome of FDD in Bifurcation Aneurysms

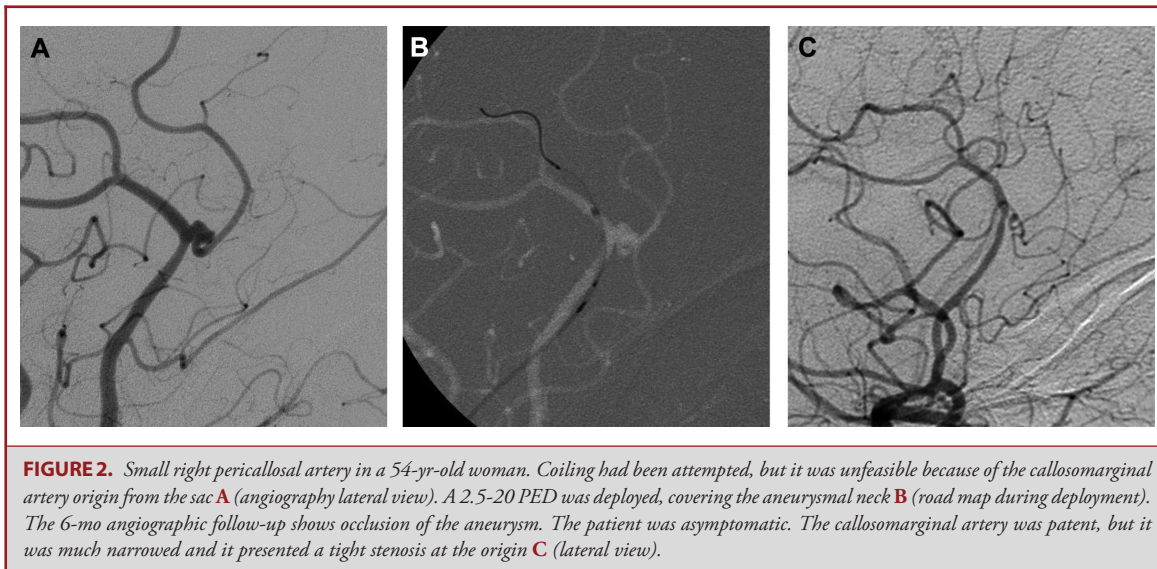
Endovascular treatment of wide-necked bifurcation aneurysms by assisted or unassisted coiling can be challenging, whereas FDD placement in bifurcation may be technically easier. Therefore, interest around FDD in bifurcation aneurysms is growing.

However, flow diversion raises its safety and efficacy concerns. The jailed bifurcation branch and perforators are at risk for periprocedural or late thromboembolic events, because the pressure gradient across the vessels is reduced and flow impairment can lead to platelet aggregation and thrombosis, especially if a very high metal coverage is achieved.

It is difficult to establish the occlusion and thromboembolic events rate after flow diversion in bifurcations, as most series are retrospective and very heterogeneous. Considering series with mixed caseload, reported acute or subacute thromboembolic events rate varies from 3.7% to 24%, and mostly transient or asymptomatic.<sup>11,16-19</sup> In the series by Michelozzi et al,<sup>19</sup> periprocedural thromboembolic complications occurred in 13.8% of patients; however, the occlusion rate was high and improved with time (82.1% at 3-6 mo, rising to 91.7% at late follow-up). In a series of 46 distal aneurysms, the occlusion rate was 78.2% with no differences between saccular and fusiform aneurysms; thromboembolic events occurred in 17.4% of patients, and they were more common in saccular aneurysms.<sup>8</sup> Hemorrhagic events are less common and are usually intraprocedural.<sup>8,16-19</sup> Perforators are usually kept patent by a “sump” effect; however,



**FIGURE 1.** Ruptured dissecting aneurysm of the right distal pericallosal artery in a 45-yr-old man. Angiography shows the aneurysm with ill-defined neck and stagnating flow inside the sac **A** (lateral view). Unsubtracted angiography from the microcatheter **B** shows neck coverage after deployment of a 2.5-8/13 FRED Jr (MicroVention). Six-month angiographic follow-up **C** (lateral view) shows occlusion of the aneurysm and patency of the stent.

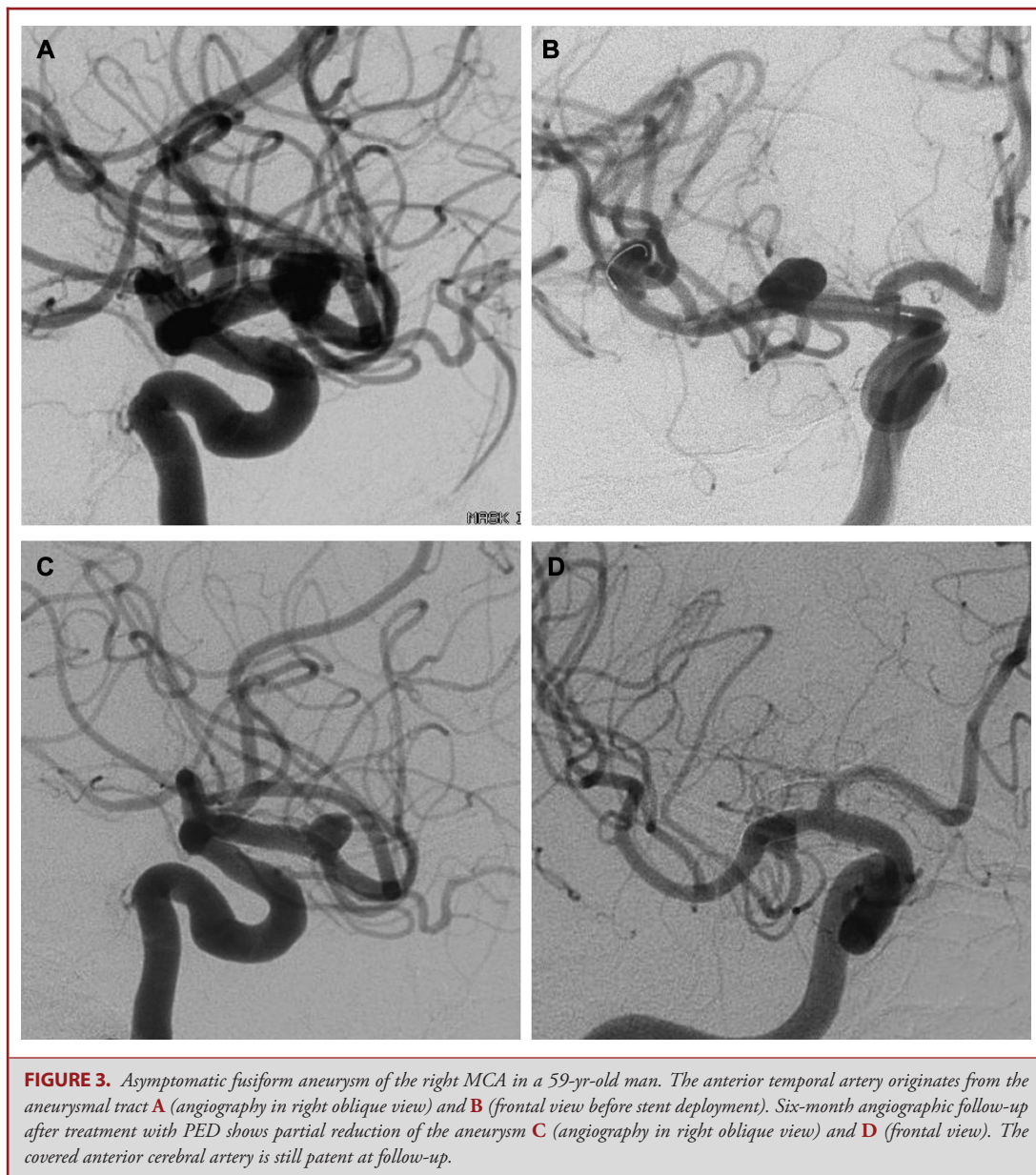


**FIGURE 2.** Small right pericallosal artery in a 54-yr-old woman. Coiling had been attempted, but it was unfeasible because of the callosomarginal artery origin from the sac **A** (angiography lateral view). A 2.5-20 PED was deployed, covering the aneurysmal neck **B** (road map during deployment). The 6-mo angiographic follow-up shows occlusion of the aneurysm. The patient was asymptomatic. The callosomarginal artery was patent, but it was much narrowed and it presented a tight stenosis at the origin **C** (lateral view).

acute or late symptomatic or asymptomatic perforator stroke is reported.<sup>6,17-19</sup> In the Saleme et al<sup>18</sup> series, permanent neurological deficits occurred in 9.4% of patients during hospitalization and transient events occurred in 17.4% of cases in the 6-mo period. Careful dual antiplatelet therapy and use of a single slightly oversized FDD, to reduce metal coverage, might be useful to decrease the risk of perforators occlusion.

Among bifurcation aneurysms, treatment-related outcomes after flow diversion are mainly influenced by anatomic factors. Discrepant data exist about flow diversion in MCA bifurcation. In the series by Briganti et al<sup>20</sup> 27% ischemic complication rate and 80% occlusion rate were reported. Caroff et al<sup>21</sup> reported 15 saccular MCA bifurcation aneurysms treated by FDD with 62% occlusion rate at 16 mo and 43% ischemic events, suggesting that FDD are not a suitable solution for this kind of aneurysms. Contrariwise, Iosif et al<sup>22</sup> in a series of 63 aneurysms, reported

68% aneurysm occlusion rate at 6 mo, improving to 95% at 12 mo, with 8.6% morbidity. Most information about safety of FDD in MCA aneurysms is provided by the meta-analysis by Cagnazzo et al,<sup>13</sup> which includes 12 studies evaluating 244 aneurysms. Complete/near complete occlusion occurred in 78.7% of patients and was more common at the bifurcation point, compared with bifurcation or more distal aneurysms (88% vs 77%). No difference was found comparing PED and other FDD. Complications occurred in 20.7% of patients (10.3% with permanent deficits), and in most of cases, they were thromboembolic (16.3%); the mortality rate was 2%. Interestingly, only one case of late rupture after treatment was reported.<sup>13</sup> Overall, these data suggest that flow diversion for MCA bifurcation aneurysms is feasible and provides good protection from subarachnoid hemorrhage (SAH). However, occlusion may take long time (Figure 3), and complication rate is relatively high, so this approach should

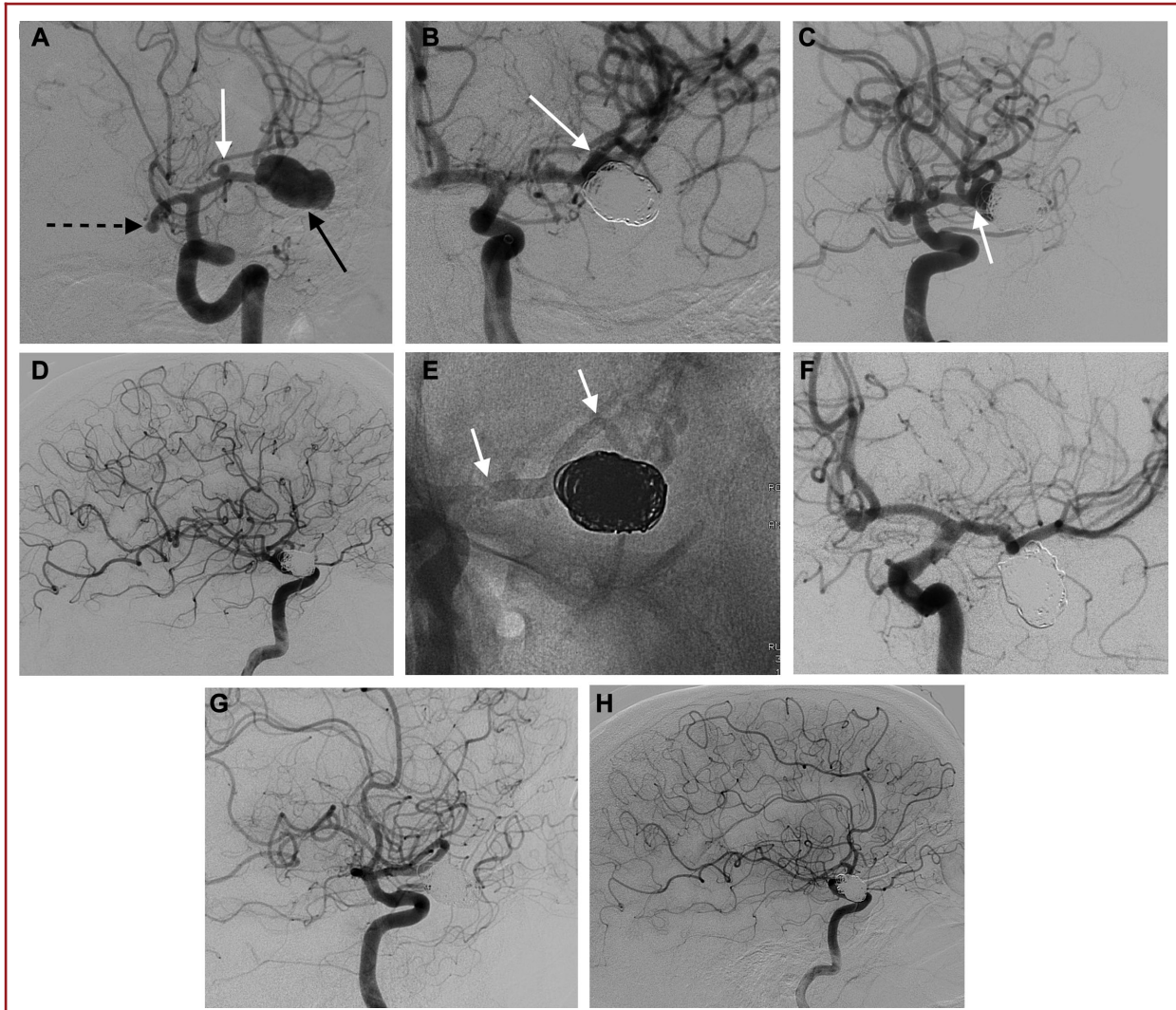


be proposed only when other endovascular or surgical approaches are considered very challenging or unfeasible.

Results of FDD in anterior communicating artery (AComA) aneurysms appear more promising, with acceptable complication rate and high occlusion rate.<sup>16,17,23</sup> A meta-analysis, including 148 aneurysms and 14 studies, revealed 87.4% complete/near complete occlusion rate, with a morbidity and mortality rate of 3.5% and 2.5%, respectively.<sup>24</sup> Coverage of A2 segment (or main branching vessels such as the artery of Heubner) may lead to ischemic complications; however, it is difficult to accurately quantify this risk.<sup>24</sup>

Carotid terminus is an uncommon location for FDD, because occlusion rate and the fate of the covered branch are unclear. In a recent series of 10 aneurysms, the complete/near complete occlusion rate was 50%; however, some aneurysms were fusiform and untreatable with other techniques. Two complications occurred.<sup>25</sup>

Very few data exist about FDD in basilar tip aneurysms. However, as this location is less accessible for clipping, FDD can be an option for complex or recurrent aneurysms, although ischemic and hemorrhagic complications are a concern.<sup>26</sup> In a multicentric series of 16 complex basilar tip aneurysms,



**FIGURE 4.** Illustrative case of a 62-yr-old woman with SAH. Angiography revealed a short M1 segment of the left MCA, harboring a small aneurysm of the superior division (white arrow), a large aneurysm of the second MCA bifurcation (black arrow), and a small ACoM aneurysm (dotted arrow) **A** (obliquefrontal view). The large aneurysm was supposed to be the ruptured one, so it was coiled with deliberate sparing of the base (white arrow) to avoid branches occlusion **B** (frontal view) and **C** (oblique view showing the remnant). Flow diversion after 1 mo was planned. The lateral view before the second intervention shows the configuration and size of the MCA candelabra vessels **D**. A single PED (white arrows) was deployed covering both MCA aneurysms **E** (unsubtracted frontal view). At 6-mo angiographic follow-up, both MCA aneurysms were occluded, but covered jailed branches were extremely narrowed **F** (left oblique view) and **G** (right oblique view). Lateral view of the 6-mo follow-up shows the diffuse narrowing of MCA branches **H**. Comparison of **H** with the preflow diversion lateral view **D** allows recognizing the significant vessels remodeling and the improvement of collateral circulation from ACA pial branches. The patient remained asymptomatic during follow-up.

complete/near complete occlusion was achieved in 68.8% of cases, with higher rates in case of adjunctive coiling. One thromboembolic event and one delayed SAH occurred.<sup>27</sup> Occlusion of jailed PCA was reported in 23.5% of patients but it was always asymptomatic because of the presence of adequate collateral circulation through the posterior communicating artery (PComA).<sup>28</sup>

### The Fate of the Jailed Branches

The fate of jailed branches is a major concern in flow diversion of bifurcation aneurysms. It appears that jailed branches patency is maintained by direct flow if collateral circulation is not adequate to provide enough compensation (Figure 3). Otherwise, if the direct or pial collateral compensation is well represented, the jailed branch will be progressively occluded (Figure 4) or narrowed

(Figure 2), usually without clinical consequences.<sup>18,19,22,29,30</sup> This observation has been confirmed by experimental models showing that patency or occlusion of the jailed bifurcation branches may be predicted on the basis of collateral circulation.<sup>31</sup> In addition, the effect of flow diversion also depends on the local stent porosity that is influenced by the stent sizing: undersized stents are associated with a shorter deployment, more condensed pores, and higher mesh density, resulting in increased risks of side branch occlusion.<sup>32</sup> Interestingly, the fate of the bifurcation branches coming from the aneurysms may also influence the aneurysm occlusion, as the jailed vessel may maintain the flow towards the aneurysm. Accordingly, in some series, aneurysms treated with FDD are less likely to be totally occluded if the jailed branch remains patent or if they have a vessel coming from the dome.<sup>33,34</sup>

Flow diversion of PComA aneurysms with normal P1 segment is usually effective and is often associated to PComA occlusion.<sup>35</sup> However, PED treatment of aneurysms incorporating the origin of a fetal PCA was largely ineffective, probably because the fetal PCA has low compensation capabilities and the residual pressure gradient might prevent the aneurysm from occluding.<sup>36,37</sup> Actually, flow diversion of aneurysms incorporating a fetal PCA should only be considered when conventional treatments are unfeasible.<sup>37</sup>

## SMALL ANEURYSMS

Recently, PED Flex received FDA approval extension for small and medium wide-necked aneurysms from the petrous segment to the tip of the ICA, based on the PREMIER trial (NCT02186561). In this trial, 141 small ICA or vertebral artery aneurysms ( $5.0 \pm 1.92$  mm) were treated. The 1-yr complete occlusion rate was 76.7% with 2.2% occurrence of major stroke or death. The retreatment rate was 2.9% and no recurrences occurred (PREMIER Clinical Study Report Medtronic FD3563 Rev B. 12-SEP-2018, unpublished data).<sup>38</sup>

However, off-label use of PED for smaller aneurysm is already common, especially in Europe. Several papers, mostly including ICA aneurysms, have reported favorable results of small aneurysms treatment with PED,<sup>10,20,39-43</sup> FRED,<sup>44,45</sup> or Silk.<sup>46,47</sup>

In a large retrospective study including both small and large aneurysms, the ischemic complication rate was lower in small aneurysms.<sup>42</sup> A recent meta-analysis (783 cases from 10 studies) reported the safety and efficacy of small aneurysms treatment with FDD. Aneurysm occlusion rate at last follow-up was 84.3%, mortality and morbidity were 0.87% and 5.2%, respectively.<sup>48</sup> In a previous meta-analysis, the 6-m occlusion rate of small (<10 mm) and large aneurysms was 80% and 74%, respectively; moreover, the SAH and ischemia rates were significantly lower in small aneurysms.<sup>49</sup> Griessenauer et al<sup>43</sup> reported a series of 149 small aneurysms ( $\leq 7$  mm), mostly paraophthalmic, with symptomatic complications and mortality in 6% and 0.9% of

cases, respectively. The complete/near complete occlusion rate was 84.8% at 6 mo and 92.2% at 12 mo.<sup>43</sup>

FDD have also been used in small complex ruptured aneurysm not treatable with other techniques, especially blood blister like aneurysms. Very small carotid<sup>50</sup> and basilar perforator<sup>51</sup> aneurysms have been successfully treated with FDD. In a meta-analysis of ruptured aneurysms treated with FDD, most of aneurysms were blister or dissecting and the median size was 4 mm. The complication rate was 17.8% (27% posterior circulation; 11.7% anterior circulation), which can be acceptable for complex aneurysms not manageable with other techniques. Long-term complete/near complete occlusion rate was 88.9% and rebleeding rate was 4%.<sup>52</sup>

## PREVIOUSLY TREATED ANEURYSMS

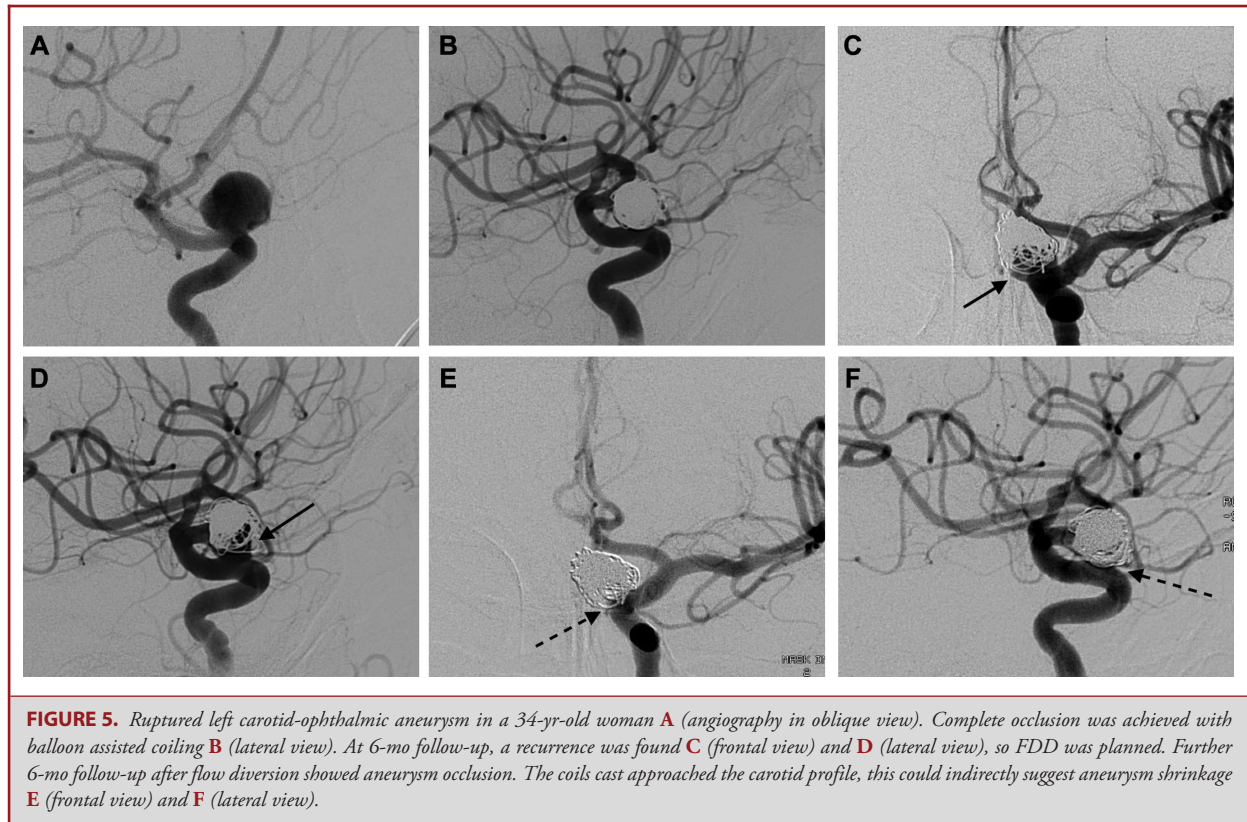
### Flow Diversion for Remnant or Recurrence after Endovascular Treatment

Some papers have specifically analyzed safety and efficacy of FDD for remnant or recurrence after endovascular treatment.<sup>53-60</sup> Because rupture risk in aneurysm recurrence is generally considered low,<sup>61</sup> retreatments with FDD should be associated with a reasonable periprocedural and postprocedural risk (Figure 5).

In some studies, patients with FDD deployed for both untreated and recurrent aneurysms were compared. In the PUFs trial only 6 retreated aneurysms were included and no differences were found.<sup>1,2</sup> In two large prospective series of aneurysms treated with PED, no significant differences were observed between recurrent aneurysms and primarily treated aneurysms.<sup>62,63</sup> These results are similar to those reported in retrospective series.<sup>42,64-66</sup> Only in a series from O'Kelly et al<sup>67</sup> multivariate analysis suggested previous aneurysm treatment as predictor of persistent aneurysm after flow diversion.

The topic of recurrent aneurysms after coiling was specifically evaluated in some retrospective series. Overall, the complete occlusion rate ranged from 60.7% to 100%, and the cumulative complete/near complete rate ranged from 82.1% to 100%, confirming the efficacy of FDD in previously coiled aneurysms.<sup>54-57</sup> As well as for primary flow diversion, time is probably a factor influencing the occlusion of retreated aneurysms. Retreatment of aneurysms treated by simple coiling appears safe, with permanent morbidity ranging from 0 to 6.9%.<sup>54-57</sup> The higher complication rate in the Benaissa et al<sup>56</sup> series might be related to the relatively high number of aneurysms not harboring on the ICA and the complexity of cases.

Positive results of FDD on recurrent coiled aneurysms suggest that ruptured complex aneurysms might be deliberately treated in 2 times: immediate subtotal coiling (with or without balloon assistance) and planned flow diversion after the acute phase (Figure 4). This strategy is supported by the good results of a series of 22 wide-necked aneurysms.<sup>68</sup> If a fetal PCA originates from the aneurysm, the efficacy of this strategy might be lower.<sup>37</sup>



**FIGURE 5.** Ruptured left carotid-ophthalmic aneurysm in a 34-yr-old woman **A** (angiography in oblique view). Complete occlusion was achieved with balloon assisted coiling **B** (lateral view). At 6-mo follow-up, a recurrence was found **C** (frontal view) and **D** (lateral view), so FDD was planned. Further 6-mo follow-up after flow diversion showed aneurysm occlusion. The coils cast approached the carotid profile, this could indirectly suggest aneurysm shrinkage **E** (frontal view) and **F** (lateral view).

Remnant or recurrent aneurysms after stent assisted coiling may be treated by FDD, but the presence of the stent seems to negatively affect the results.<sup>58-60,66</sup> In the Fischer series, adverse events occurred in 13% of patients in whom a stent was already present and in 2% of patients without a previous stent.<sup>66</sup> Overall FDD treatment results for recurrence of previously stented aneurysms are not encouraging, with occlusion rate ranging from 38% to 65% and morbidity ranging from 0 to 14.3%.<sup>58-60,66</sup> The presence of a stent raises technical challenges, as both stent catheterization and FDD deployment may be impaired. Inadvertent FDD opening across the struts of the previous stent will result in incomplete opening and possible severe complications.<sup>60</sup> Moreover, the stent reduces FDD apposition to the vessel wall, impairing the flow diversion effect. In extreme cases, malapposition may result in an “endoleak.” To avoid this problem, the FDD should cover the previous stent both proximally and distally.<sup>60</sup>

### Flow Diversion for Recurrence of Previously Clipped Aneurysms

Reoperation of previously clipped aneurysms may be challenging with high morbidity and mortality.<sup>69</sup> There are some limited series showing that flow diversion is a reasonable option for recurrent previously clipped aneurysms.<sup>70-75</sup> Complete occlusion rate varies from 50% to 100% in series, mainly

including aneurysms located along the ICA.<sup>70-72</sup> Interestingly, in a series of 9 patients with recurrent, previously clipped, AComA aneurysms, complete occlusion was achieved in 83% of cases without periprocedural complications.<sup>75</sup> Actually, studies on larger population would be necessary to validate these promising results.

### CAROTID CAVERNOUS FISTULAS

FDD are an uncommon option for direct carotid cavernous fistulas (CCFs). Conventional treatment of CCFs include transarterial or transvenous embolization with detachable balloons, coils, combination of coils, and liquid embolic agents.<sup>76-78</sup> Parent vessel sacrifice is also a valid option, after successful balloon occlusion test. Coronary stent-grafts have been proposed as a reconstructive technique for direct CCFs.<sup>79</sup> Nevertheless, stent-grafts flexibility is poor and their positioning may be challenging or result in endoleak. Recently, a balloon-expandable stent-graft specifically designed for intracranial vessels has been used in 10 CCFs, with immediate occlusion in 6 cases and occlusion after adjunctive maneuvers in 3 cases.<sup>80</sup> Use of FDD for CCFs should be considered off-label with the sole exception in Europe of P64 (Phenox GmbH, Bochum, Germany), which is approved for arteriovenous fistulas.<sup>81</sup> Contrarily to covered stents, FDD are very flexible and adapt very well to vascular tortuosity. Flow

diversion for CCFs seems effective. This approach usually requires multiple devices, because the pressure gradient of the shunt provides an aspiration effect, and occlusion often requires some months to complete.<sup>81-85</sup>

In the largest series of 14 patients by Wendt et al<sup>81</sup> complete occlusion was achieved in 21% of patients, but significant flow reduction occurred in all the remaining cases. Treatment was safe, and 71% of patients were free from ocular symptoms at follow-up. Multiple FDD were usually required and only 36% of patients were successfully treated with FDD alone, as the majority needed combined treatment with coiling.<sup>81</sup> The strategy proposed in a paper by Ogilvy et al<sup>82</sup> is endovascular coil or balloon occlusion of the fistula from either a transvenous or transarterial approach, followed by flow diversion, in order to facilitate endothelialization of the damaged ICA wall. The main drawback of CCFs treatment with FDD is the time required for fistula occlusion, which might prevent symptoms improvement in severe cases. Moreover, FDDs are expensive and require dual antiplatelet therapy. However, this approach appears safe and does not entail the risk of cranial nerve injury.

Unlike direct CCFs, dural indirect CCFs involve multiple small arterial connections. The therapeutic goal in these cases is to occlude the fistula and the cavernous sinus. A single successful case of a small Barrow B dural CCF has been reported.<sup>86</sup> FDD might find very limited application in indirect CCFs without any vascular access to the CS, but actually there is no evidence to support this indication.

## CONCLUSION

There is a growing interest regarding FDD for “off-label” indications, especially for distal and bifurcation aneurysms. Although there are no randomized studies supporting these indications, it appears reasonable that FDD may be a safe and effective alternative for selected complex aneurysms, when other techniques are judged unfeasible or too harmful. Some indications, such as small or recurrent aneurysms of the ICA, may already be considered as established indications in the clinical practice. Further studies will be necessary to better define the indication range of FDD.

## Disclosures

Outside of publication in this supplement, the authors have no personal, financial, or institutional interest in any of the drugs, materials, or devices described in this article.

## REFERENCES

1. Becske T, Kallmes DF, Saatci I, et al. Pipeline for uncoilable or failed aneurysms: results from a multicenter clinical trial. *Radiology*. 2013;267(3):858-868.
2. Becske T, Brinjikji W, Potts MB, et al. Long-Term clinical and angiographic outcomes following pipeline embolization device treatment of complex internal carotid artery aneurysms: Five-Year Results of the pipeline for uncoilable or failed aneurysms trial. *Neurosurgery*. 2017;80(1):40-48.
3. Lenz-Habijan T, Bhogal P, Peters M. Hydrophilic stent coating inhibits platelet adhesion on stent surfaces: initial results in vitro. *Cardiovasc Intervent Radiol*. 2018;41(11):1779-1785.
4. Martínez-Galdámez M, Biondi A, Kalousek V, et al. Periprocedural safety and technical outcomes of the new Silk Vista Baby flow diverter for the treatment of intracranial aneurysms: results from a multicenter experience. *J Neurointerv Surg*. published online: March 9, 2019. (doi: 10.1136/neurintsurg-2019-014770).
5. Lin N, Lanzino G, Lopes DK, et al. Treatment of distal anterior circulation aneurysms with the pipeline embolization device: A us multicenter experience. *Neurosurgery*. 2016;79(1):14-22.
6. Primiani CT, Ren Z, Kan P, et al. A2, M2, P2 aneurysms and beyond: results of treatment with pipeline embolization device in 65 patients. *J Neurointerv Surg*. published online: January 23, 2019. (doi: 10.1136/neurintsurg-2018-014631).
7. Möhlenbruch MA, Kizilkilic O, Killer-Oberpfalzer M, et al. Multicenter experience with FRED Jr Flow Re-Direction endoluminal device for intracranial aneurysms in small arteries. *AJNR Am J Neuroradiol*. 2017;38(10):1959-1965.
8. Ravindran K, Enriquez-Marulanda A, Kan PTM, et al. Use of flow diversion for the treatment of distal circulation aneurysms: A multicohort study. *World Neurosurg*. 2018;(118):e825-e833. (doi: 10.1016/j.wneu.2018.07.062).
9. Yan Y, Zhu D, Tang H, et al. Safety and efficacy of flow diverter treatment for aneurysm in small cerebral vessels: a systematic review and Meta-Analysis. *World Neurosurg*. 2018;(115):54-64.
10. Puri AS, Massari F, Asai T, et al. Safety, efficacy, and short-term follow-up of the use of Pipeline Embolization Device in small (<2.5 mm) cerebral vessels for aneurysm treatment: single institution experience. *Neuroradiology*. 2016;58(3):267-275.
11. Martínez-Galdámez M, Romance A, Vega P, et al. Pipeline endovascular device for the treatment of intracranial aneurysms at the level of the circle of Willis and beyond: multicenter experience. *J Neurointerv Surg*. 2015;7(11):816-823.
12. Patel PD, Chalouhi N, Atallah E, et al. Off-label uses of the Pipeline embolization device: a review of the literature. *Neurosurg Focus*. 2017;42(6):E4.
13. Cagnazzo F, Mantilla D, Lefevre PH, Dargazanli C, Gascou G, Costalat V. Treatment of middle cerebral artery aneurysms with Flow-Diverter stents: A Systematic review and Meta-Analysis. *AJNR Am J Neuroradiol*. 2017;38(12):2289-2294.
14. Wallace AN, Grossberg JA, Almandoz JED, et al. Endovascular treatment of posterior cerebral artery aneurysms with flow diversion: case series and systematic review. *Neurosurgery*. 2018;83(4):790-799.
15. Cagnazzo F, Cappucci M, Dargazanli C, et al. Treatment of distal anterior cerebral artery aneurysms with Flow-Diverter stents: A Single-Center experience. *AJNR Am J Neuroradiol*. 2018;39(6):1100-1106.
16. Dabus G, Grossberg JA, Cawley CM, et al. Treatment of complex anterior cerebral artery aneurysms with Pipeline flow diversion: mid-term results. *J Neurointerv Surg*. 2017;9(2):147-151.
17. Pistocchi S, Blanc R, Bartolini B, Piotin M. Flow diverters at and beyond the level of the circle of willis for the treatment of intracranial aneurysms. *Stroke*. 2012;43(4):1032-1038.
18. Saleme S, Iosif C, Ponomarjova S, et al. Flow-diverting stents for intracranial bifurcation aneurysm treatment. *Neurosurgery*. 2014;75(6):623-631.
19. Michelozzi C, Darcourt J, Guenego A, et al. Flow diversion treatment of complex bifurcation aneurysms beyond the circle of Willis: complications, aneurysm sac occlusion, reabsorption, recurrence, and jailed branch modification at follow-up. *J Neurosurg*. 2018:1-12. (doi: 10.3171/2018.7.JNS18654).
20. Briganti F, Delehay L, Leone G, et al. Flow diverter device for the treatment of small middle cerebral artery aneurysms. *J Neurointerv Surg*. 2016;8(3):287-294.
21. Caroff J, Neki H, Mihalea C, et al. Flow-Diverter stents for the treatment of saccular middle cerebral artery bifurcation aneurysms. *AJNR Am J Neuroradiol*. 2016;37(2):279-284.
22. Iosif C, Mounayer C, Yavuz K, et al. Middle cerebral artery bifurcation aneurysms treated by extrasaccular flow diverters: midterm angiographic evolution and clinical outcome. *AJNR Am J Neuroradiol*. 2017;38(2):310-316.
23. Colby GP, Bender MT, Lin LM, et al. Endovascular flow diversion for treatment of anterior communicating artery region cerebral aneurysms: a single-center cohort of 50 cases. *J Neurointerv Surg*. 2017;9(7):679-685.
24. Cagnazzo F, Limbucci N, Nappini S, et al. Flow diversion treatment of unruptured saccular anterior communicating artery aneurysms. A systematic review and meta-analysis. *AJNR Am J Neuroradiol*. 2019;40(3):497-502.
25. Pujari A, Howard BM, Madaelil TP, et al. Pipeline embolization device treatment of internal carotid artery terminus aneurysms. *J Neurointerv Surg*. 2019;11(5):485-488.
26. Da Ros V, Caroff J, Rouchaud A, et al. Large basilar apex aneurysms treated with Flow-Diverter stents. *AJNR Am J Neuroradiol*. 2017;38(6):1156-1162.



27. Dmytriw AA, Adeeb N, Kumar A, et al. Flow diversion for the treatment of basilar apex aneurysms. *Neurosurgery*. 2018;83(6):1298-1305.
28. Adeeb N, Griessenauer CJ, Dmytriw AA, et al. Risk of branch occlusion and ischemic complications with the pipeline embolization device in the treatment of posterior circulation aneurysms. *AJNR Am J Neuroradiol*. 2018;39(7):1303-1309.
29. Bhogal P, AlMatter M, Bäßner H, Ganslandt O, Henkes H, Aguilar Pérez M. Flow diversion for the treatment of MCA Bifurcation Aneurysms-A single centre experience. *Front Neurol*. February 2017;8, Article 20. (doi: 10.3389/fneur.2017.00020).
30. Nossek E, Chalif DJ, Chakraborty S, Setton A. Modifying flow in the ICA bifurcation: pipeline deployment from the supraclinoid ICA extending into the M1 segment-clinical and anatomic results. *AJNR Am J Neuroradiol*. 2014;35(11):2125-2129.
31. Shapiro M, Shapiro A, Raz E, Becske T, Riina H, Nelson PK. Toward better understanding of flow diversion in bifurcation aneurysms. *AJNR Am J Neuroradiol*. 2018;39(12):2278-2283.
32. Shapiro M, Raz E, Becske T, Nelson PK. Variable porosity of the pipeline embolization device in straight and curved vessels: a guide for optimal deployment strategy. *AJNR Am J Neuroradiol*. 2014;35(4):727-733.
33. Topcuoglu OM, Akgul E, Daglioglu E, et al. Flow diversion in middle cerebral artery aneurysms: Is it really an All-Purpose treatment? *World Neurosurg*. 2016;(87):317-27. (doi: 10.1016/j.wneu.2015.11.073).
34. Bender MT, Colby GP, Lin LM, et al. Predictors of cerebral aneurysm persistence and occlusion after flow diversion: a single-institution series of 445 cases with angiographic follow-up. *J Neurosurg*. 2018;1-9. (doi: 10.3171/2017.11.JNS171738).
35. Brinjikji W, Lanzino G, Cloft HJ, Kallmes DF. Patency of the posterior communicating artery after flow diversion treatment of internal carotid artery aneurysms. *Clin Neurol Neurosurg*. 2014;120:84-88. (doi: 10.1016/j.clineuro.2014.02.018).
36. Kan P, Duckworth E, Puri A, Velat G, Wakhloo A. Treatment failure of fetal posterior communicating artery aneurysms with the pipeline embolization device. *J Neurointerv Surg*. 2016;8(9):945-948.
37. Roy AK, Howard BM, Haussen DC, et al. Reduced efficacy of the pipeline embolization device in the treatment of posterior communicating region aneurysms with fetal posterior cerebral artery configuration. *Neurosurgery*. 2018;82(5):695-700.
38. Medtronic press release, PREMIER Clinical Study Report Medtronic FD3563 Rev B, September 12, 2018. [http://newsroom.medtronic.com/phoenix.zhtml?c=251324&p=irol-newsArticle\\_Print&ID=2386519](http://newsroom.medtronic.com/phoenix.zhtml?c=251324&p=irol-newsArticle_Print&ID=2386519). Accessed April 21, 2019.
39. Chalouhi N, Zanaty M, Whiting A, et al. Safety and efficacy of the pipeline embolization device in 100 small intracranial aneurysms. *J Neurosurg*. 2015;122(6):1498-1502.
40. Chalouhi N, Starke RM, Yang S, et al. Extending the indications of flow diversion to small, unruptured, saccular aneurysms of the anterior circulation. *Stroke*. 2014;45(1):54-58.
41. Lin LM, Colby GP, Kim JE, Huang J, Tamargo RJ, Coon AL. Immediate and follow-up results for 44 consecutive cases of small (<10 mm) internal carotid artery aneurysms treated with the pipeline embolization device. *Surg Neurol Int*. 2013;4:114. (doi: 10.4103/2152-7806.117711).
42. Kallmes DF, Hanel R, Lopes D, et al. International retrospective study of the pipeline embolization device: a multicenter aneurysm treatment study. *AJNR Am J Neuroradiol*. 2015; 36(1):108-115.
43. Griessenauer CJ, Ogilvy CS, Foreman PM, et al. Pipeline embolization device for small intracranial aneurysms: evaluation of safety and efficacy in a multicenter cohort. *Neurosurgery*. 2017;80(4):579-587.
44. Briganti F, Leone G, Ugga L, et al. Safety and efficacy of flow re-direction endoluminal device (FRED) in the treatment of cerebral aneurysms: a single center experience. *Acta Neurochir (Wien)*. 2016;158(9):1745-1755.
45. Pierot L, Spelle L, Berge J, et al. SAFE study (Safety and efficacy Analysis of FRED Embolic device in aneurysm treatment): 1-year clinical and anatomical results. *J Neurointerv Surg*. 2019;11(2):184-189.
46. Strauss I, Maimon S. Silk flow diverter in the treatment of complex intracranial aneurysms: a single-center experience with 60 patients. *Acta Neurochir (Wien)*. 2016;158(2):247-254.
47. Pumar JM, Mosqueira A, Cuellar H, et al. Expanding the use of flow diverters beyond their initial indication: treatment of small unruptured aneurysms. *J Neurointerv Surg*. 2018;10(3):245-248.
48. Yao X, Ma J, Li H, Shen H, Lu X, Chen G. Safety and efficiency of flow diverters for treating small intracranial aneurysms: A systematic review and meta-analysis. *J Int Med Res*. 2017;45(1):11-21.
49. Brinjikji W, Murad MH, Lanzino G, Cloft HJ, Kallmes DF. Endovascular treatment of intracranial aneurysms with flow diverters: a meta-analysis. *Stroke*. 2013;44(2):442-447.
50. Linfante I, Mayich M, Sonig A, Fujimoto J, Siddiqui A, Dabus G. Flow diversion with pipeline embolic device as treatment of subarachnoid hemorrhage secondary to blister aneurysms: dual-center experience and review of the literature. *J Neurointerv Surg*. 2017;9(1):29-33.
51. Bhogal P, AlMatter M, Hellstern V, et al. Basilar artery perforator aneurysms: report of 9 cases and review of the literature. *J Clin Neurosci*. 2019;63:122-129. (doi: 10.1016/j.jocn.2019.01.026).
52. Cagnazzo F, Di Carlo DT, Cappucci M, Lefevre PH, Costalat V, Perrini P. Acutely ruptured intracranial aneurysms treated with Flow-Diverter stents: a systematic review and Meta-Analysis. *AJNR Am J Neuroradiol*. 2018;39(9):1669-1675.
53. Chalouhi N, Chitale R, Starke RM, Jabbour P, Tjounmakaris S, Dumont AS, et al. Treatment of recurrent intracranial aneurysms with the Pipeline Embolization Device. *J Neurointerv Surg*. 2014;6(1):19-23.
54. Daou B, Starke RM, Chalouhi N, et al. The use of the Pipeline Embolization Device in the management of recurrent previously coiled cerebral aneurysms. *Neurosurgery*. 2015;77(5):692-697.
55. Dornbos D, 3rd, Karras CL, Wenger N, et al. Pipeline embolization device for recurrence of previously treated aneurysms. *Neurosurg Focus*. 2017;42(6):E8.
56. Benaissa A, Januel AC, Herbreteau D, et al. Endovascular treatment with flow diverters of recanalized and multitreasured aneurysms initially treated by endovascular approach. *J Neurointerv Surg*. 2015;7(1):44-9.
57. Kühn AL, de Macedo Rodrigues K, Lozano JD, et al. Use of the Pipeline embolization device for recurrent and residual cerebral aneurysms: a safety and efficacy analysis with short-term follow-up. *J Neurointerv Surg*. 2017;9(12):1208-1213.
58. Daou B, Starke RM, Chalouhi N, et al. Pipeline embolization device in the treatment of recurrent previously stented cerebral aneurysms. *AJNR Am J Neuroradiol*. 2016;37(5):849-855.
59. Heiferman DM, Billingsley JT, Kasliwal MK, et al. Use of flow-diverting stents as salvage treatment following failed stent-assisted embolization of intracranial aneurysms. *J Neurointerv Surg*. 2016;8(7):692-695.
60. Bender MT, Vo CD, Jiang B, et al. Pipeline embolization for salvage treatment of previously stented residual and recurrent cerebral aneurysms. *Interv Neurol*. 2018;7(6):359-369.
61. Naggara ON, White PM, Guilbert F, et al. Endovascular treatment of intracranial unruptured aneurysms: systematic review and meta-analysis of the literature on safety and efficacy. *Radiology*. 2010;256(3):887-897.
62. Nelson PK, Lylyk P, Szikora I, Wetzel SG, Wanke I, Fiorella D. The Pipeline embolization device for the intracranial treatment of aneurysms trial. *AJNR Am J Neuroradiol*. 2011;32(1):34-40.
63. Yu SC, Kwok CK, Cheng PW, et al. Intracranial aneurysms: midterm outcome of pipeline embolization device—a prospective study in 143 patients with 178 aneurysms. *Radiology*. 2012;265(3):893-901.
64. Lylyk P, Miranda C, Ceratto R, et al. Curative endovascular reconstruction of cerebral aneurysms with the Pipeline embolization device: the Buenos Aires experience. *Neurosurgery*. 2009;64(4):632-642.
65. Briganti F, Leone G, Cirillo L, de Divitiis O, Solari D, Cappabianca P. Postprocedural, midterm, and long-term results of cerebral aneurysms treated with flow-diverter devices: 7-year experience at a single center. *Neurosurg Focus*. 2017;42(6):E3.
66. Fischer S, Vajda Z, Aguilar Perez M, et al. Pipeline embolization device (PED) for neurovascular reconstruction: initial experience in the treatment of 101 intracranial aneurysms and dissections. *Neuroradiology*. 2012;54(4):369-382.
67. O'Kelly CJ, Spears J, Chow M, et al. Canadian experience with the Pipeline embolization device for repair of unruptured intracranial aneurysms. *AJNR Am J Neuroradiol*. 2013;34(2):381-387.
68. Howard BM, Frerich JM, Madaelil TP, et al. 'Plug and pipe' strategy for treatment of ruptured intracranial aneurysms. *J Neurointerv Surg*. 2019;11(1):43-48.
69. Drake CG, Friedman AH, Peerless SJ. Failed aneurysm surgery. Reoperation in 115 cases. *J Neurosurg*. 1984;61(5):848-856.
70. Ding D, Starke RM, Evans AJ, Jensen ME, Liu KC. Endovascular treatment of recurrent intracranial aneurysms following previous microsurgical clipping with the Pipeline Embolization Device. *J Clin Neurosci*. 2014;21(7):1241-1244.
71. Adeeb N, Griessenauer CJ, Moore J, et al. Pipeline Embolization Device for recurrent cerebral aneurysms after microsurgical clipping. *World Neurosurg*. 2016;(93):341-345. (doi: 10.1016/j.wneu.2016.06.065).

72. Gross BA, Albuquerque FC, Moon K, Ducruet AF, McDougall CG. Endovascular treatment of previously clipped aneurysms: continued evolution of hybrid neurosurgery. *J Neurointerv Surg*. 2017;9(2):169-172.
73. Kalani MY, Albuquerque FC, Levitt M, Nakaji P, Spetzler RF, McDougall C. Pipeline embolization for definitive endoluminal reconstruction of blister-type carotid aneurysms after clip wrapping. *J Neurointerv Surg*. 2016;8(5):495-500.
74. Romagna A, Ladisich B, Schwartz C, Winkler PA, Rahman AA. Flow-diverter stents in the endovascular treatment of remnants in previously clipped ruptured aneurysms: a feasibility study. *Interv Neuroradiol*. published online: October 28, 2018. (doi: 10.1177/1591019918805774).
75. Lin LM, Iyer RR, Bender MT, et al. Rescue treatment with Pipeline embolization for postsurgical clipping recurrences of anterior communicating artery region aneurysms. *Interv Neurol*. 2017;6(3-4):135-146.
76. Gemmete JJ, Ansari SA, Gandhi D. Endovascular treatment of carotid cavernous fistulas. *Neuroimaging Clin N Am*. 2009;19(2):241-255.
77. Thomas AJ, Chua M, Fusco M, et al. Proposal of venous drainage-based classification system for carotid cavernous fistulae with validity assessment in a multicenter cohort. *Neurosurgery*. 2015;77(3):380-385; discussion 385.
78. Ducruet AF, Albuquerque FC, Crowley RW, McDougall CG. The evolution of endovascular treatment of carotid cavernous fistulas: a single-center experience. *World Neurosurg*. 2013;80(5):538-548.
79. Gomez F, Escobar W, Gomez AM, Gomez JF, Anaya CA. Treatment of carotid cavernous fistulas using covered stents: midterm results in seven patients. *AJNR Am J Neuroradiol*. 2007;28(9):1762-1768.
80. Liu LX, Lim J, Zhang CW, et al. Application of the willis covered stent in the treatment of Carotid-Cavernous fistula: a Single-Center experience. *World Neurosurg*. 2019;(122):e390-e398. (doi: 10.1016/j.wneu.2018.10.060).
81. Wendl CM, Henkes H, Martinez Moreno R, Ganslandt O, Bätzner H, Aguilar Pérez M. Direct carotid cavernous sinus fistulae: vessel reconstruction using flow-diverting implants. *Clin Neuroradiol*. 2017;27(4):493-501.
82. Ogilvy CS, Motiei-Langroudi R, Ghorbani M, Griessenauer CJ, Alturki AY, Thomas AJ. Flow diverters as useful adjunct to traditional endovascular techniques in treatment of direct carotid-cavernous fistulas. *World Neurosurg*. 2017;(105):812-817. (doi: 10.1016/j.wneu.2017.06.113).
83. Nadarajah M, Power M, Barry B, Wenderoth J. Treatment of a traumatic carotid-cavernous fistula by the sole use of a flow diverting stent. *J Neurointerventional Surg*. 2012;4(3):e1.
84. Pradeep N, Nottingham R, Kam A, Gandhi D, Razack N. Treatment of post-traumatic carotid-cavernous fistulas using pipeline embolization device assistance. *J Neurointerventional Surg*. 2016;8(10):e40.
85. Lin LM, Colby GP, Jiang B, Pero G, Boccardi E, Coon AL. Transvenous approach for the treatment of direct carotid cavernous fistula following Pipeline embolization of cavernous carotid aneurysm: a report of two cases and review of the literature. *J Neurointerventional Surg*. 2015;7(8):e30.
86. Castaño C, Remollo S, García-Sort R, Domínguez C, Terceño M. Treatment of Barrow type 'B' carotid cavernous fistulas with flow diverter stent (Pipeline). *Neuroradiol J*. 2017;30(6):607-614.