



Since January 2020 Elsevier has created a COVID-19 resource centre with free information in English and Mandarin on the novel coronavirus COVID-19. The COVID-19 resource centre is hosted on Elsevier Connect, the company's public news and information website.

Elsevier hereby grants permission to make all its COVID-19-related research that is available on the COVID-19 resource centre - including this research content - immediately available in PubMed Central and other publicly funded repositories, such as the WHO COVID database with rights for unrestricted research re-use and analyses in any form or by any means with acknowledgement of the original source. These permissions are granted for free by Elsevier for as long as the COVID-19 resource centre remains active.

Mucocutaneous manifestations in children hospitalized with COVID-19



David Andina-Martinez, MD,^a Montserrat Nieto-Moro, MD,^b Jose Antonio Alonso-Cadenas, MD,^a Juan Añon-Hidalgo, MD,^c Angela Hernandez-Martin, MD,^d Esther Perez-Suarez, MD,^a Isabel Colmenero-Blanco, MD,^d Maria Isabel Iglesias-Bouza, MD,^b Julia Cano-Fernandez, MD,^c Ana Mateos-Mayo, MD,^d and Antonio Torrelo, MD^d
Madrid, Spain

Background: Cutaneous manifestations in hospitalized children with SARS-CoV-2 have not been studied systematically.

Objective: To describe the mucocutaneous involvement in pediatric patients with COVID-19 admitted to a pediatric institution in Madrid (Spain), located in a zone reporting among the highest prevalence of COVID-19 in Europe.

Methods: A descriptive, analytical study was conducted on a series of 50 children hospitalized with COVID-19 between March 1, 2020, and November 30, 2020.

Results: Twenty-one patients presented with mucocutaneous symptoms: 18 patients with macular and/or papular exanthem, 17 with conjunctival hyperemia, and 9 with red cracked lips or strawberry tongue. Eighteen patients fulfilled criteria for multisystem inflammatory syndrome in children. Patients with mucocutaneous involvement tended to be older and presented to the emergency department with poor general status and extreme tachycardia, higher C-reactive protein and D-dimer levels, and lower lymphocyte counts than patients without skin signs. Mucocutaneous manifestations pose a higher risk of admission to the pediatric intensive care unit (odds ratio, 10.24; 95% confidence interval, 2.23–46.88; $P = .003$).

Conclusions: Children hospitalized with COVID-19 frequently had mucocutaneous involvement, with most symptoms fulfilling criteria for multisystem inflammatory syndrome in children. Patients with an exanthem or conjunctival hyperemia at admission have a higher probability of pediatric intensive care admission than patients without mucocutaneous symptoms. (J Am Acad Dermatol 2021;85:88-94.)

Key words: COVID-19; pediatric dermatology; multisystem inflammatory syndrome; SARS-CoV-2.

INTRODUCTION

COVID-19 in previously healthy children is usually a mild or asymptomatic disease, practically without associated mortality.¹ Fever and respiratory symptoms were the most frequent manifestations in early pediatric series from China and Italy^{2,3}; however, the involvement of other organs and systems has been described.⁴ Gastrointestinal and

mucocutaneous manifestations are frequent in multi-system inflammatory syndrome in children (MIS-C), the most serious condition associated with SARS-CoV-2 infection in the pediatric population.^{5,6}

Based on findings in adult patients, skin manifestations of COVID-19 have been classified under 5 categories: acral pseudo-chilblain, vesicular eruptions, urticarial lesions, macular and/or papular

From the Emergency Department,^a Paediatric Intensive Care Unit,^b Paediatric Department,^c and Department of Dermatology, Hospital Infantil Universitario Niño Jesús, Madrid, Spain.^d

Funding sources: None.

IRB approval status: Approval was provided by the Ethics Committee and Board of the Hospital Infantil Universitario Niño Jesús. Standard informed consent was obtained to record images.

Accepted for publication March 24, 2021.

Correspondence and reprint requests to: David Andina-Martinez, MD, Emergency Department, Hospital Infantil Universitario Niño Jesús, Avenida Menéndez Pelayo, 65, 28009 Madrid, Spain. E-mail: david.andina@salud.madrid.org.

Published online April 2, 2021.

0190-9622/\$36.00

© 2021 by the American Academy of Dermatology, Inc.

<https://doi.org/10.1016/j.jaad.2021.03.083>

eruptions, and livedo or necrosis.⁷ Chilblain lesions in healthy children and adolescents have received much attention; these lesions resolve without complications after a few weeks.^{8,9} The other cutaneous manifestations of COVID-19 in children have been the subject of case reports or small case series.¹⁰

The mucocutaneous manifestations in hospitalized children infected with SARS-CoV-2 and the implications on the clinical course have not yet been extensively described. The objective of this study was to describe mucocutaneous manifestations in children hospitalized for COVID-19.

METHODS

Study design

We conducted a descriptive, analytical study of pediatric patients with COVID-19 admitted from March 1 to November 30, 2020, to a single pediatric institution in Madrid (Spain). Approval was obtained from the institution's Ethics Committee and Board, and standard informed consent to record images was obtained.

Inclusion criteria

Patients from zero to 18 years of age admitted to the hospital with a COVID-19 diagnosis were eligible if they met at least 1 of the following criteria:

- Positive reverse transcriptase polymerase chain reaction (RT-PCR) for SARS-CoV-2 collected from a nasopharyngeal and oropharyngeal swab; or
- Clinical suspicion (symptoms compatible with MIS-C or symptoms compatible with COVID-19 with a close contact having tested positive for COVID-19) and a positive immunoglobulin-M enzyme-linked immunosorbent assay for SARS-CoV-2.

Exclusion criteria

Patients were not eligible if they had a positive RT-PCR result in the emergency department but infection with SARS-CoV-2 was not directly related to the cause of admission. Patients with cancer and undergoing chemotherapy were also excluded.

Data collection

Each patient received an identification code to blind investigators to individual patient data and to facilitate anonymous data collection. Epidemiologic,

clinical, and testing data were retrieved from the electronic medical records of the admitted patients. Epidemiologic data included sex, age, length of hospital stay, pediatric intensive care unit (PICU) admission, and a record of close contact with suspected or confirmed cases of COVID-19. Clinical data included a history of chronic disease; previous

treatment; signs (appearance, heart rate, oxygen saturation); and symptoms (fever, rhinorrhea, cough, respiratory distress, thoracic pain, sore throat, abdominal pain, vomiting, diarrhea, rash, conjunctival hyperemia without secretion, red cracked lips, strawberry tongue, headache, irritability, drowsiness, myalgia, anosmia, or ageusia). Reason for admission was classified into 6 categories: respiratory, gastrointestinal, neurologic, MIS-C, neonates

with fever, and protracted fever. Analytical determination on admission included leukocyte, neutrophil, and lymphocyte counts; lactate dehydrogenase; D-dimer; C-reactive protein; and procalcitonin.

Definitions

We followed the case definition for MIS-C as described in the Health Advisory on MSS-C, published by the Centers for Disease Control.¹¹ The case definition for MIS-C was as follows:

- An individual younger than 21 years age, presenting with fever, laboratory evidence of inflammation, and clinical evidence of severe illness requiring hospitalization, with multisystem (>2) organ involvement (cardiac, renal, respiratory, hematologic, gastrointestinal, dermatologic, or neurologic), and
- No alternative plausible diagnoses, and
- Positive for current or recent SARS-CoV-2 infection as determined by an RT-PCR, serology, or antigen test, or exposure to a suspected or confirmed COVID-19 case no more than 4 weeks prior to the onset of symptoms.

Statistical analysis

Data were analyzed using Stata version 15.0 (StataCorp). Variables with normal distribution were reported as mean and standard deviation. Variables that did not meet the normality requirements were reported as median and interquartile

CAPSULE SUMMARY

- Macular and/or papular exanths, conjunctival hyperemia, red cracked lips, or strawberry tongue appear in 42% of children admitted for COVID-19, mostly in the context of multisystem inflammatory syndrome.
- Mucocutaneous manifestations are associated with a higher risk of admission to a pediatric intensive care unit and should warrant prompt attention.

Abbreviations used:

MIS-C:	multisystem inflammatory syndrome in children
PICU:	pediatric intensive care unit
RT-PCR:	reverse transcriptase polymerase chain reaction

range. Variables within categories were expressed as percentages. Two-tailed t tests were used to compare means between groups. Chi-squared tests were used to compare proportions. A stepwise logistic regression analysis was used to calculate the risk of admission to a PICU. A *P* value < .05 was considered statistically significant.

RESULTS

Fifty patients were included in the study (Fig 1). Forty-four (88%) had a positive RT-PCR for SARS-CoV-2 and 6 (12%) met the clinical criteria for suspicion and had a negative RT-PCR with a positive immunoglobulin serology. Thirty-four patients (68%) had a close contact with a suspected or confirmed case of COVID-19. In the remaining 16 (32%), the origin of the infection remained unknown.

The main reasons for admission were respiratory illness (40%) and MIS-C (40%). The evolution of admitted COVID-19 patients during the pandemic is shown in Fig 2.

A general description of the sample is shown in Table I. Twenty-one patients (42%) exhibited mucocutaneous symptoms, including 18 patients with exanthem, 17 with conjunctival hyperemia without secretion, and 9 with red cracked lips or strawberry tongue (Figs 3 and 4).

The exanthem was described as macular and/or papular in all 18 cases, with confluent erythematous macules and papules that might become diffuse or show a lacy or reticulated pattern. All patients had mucocutaneous symptoms at the time of diagnosis in the emergency department, with variable progression throughout hospital admission. The limbs (78%) and trunk (72%) were the most commonly involved areas, and palms and soles (55%), genitals/groins (50%), and face (33%) were affected less frequently. One patient had an isolated acral ischemic lesion with a diameter of 5 mm, which appeared on 1 finger after recovery.

Patients with mucocutaneous symptoms tended to be older than those without skin signs and presented to the emergency department with a poor general status and extreme tachycardia. Fever and gastrointestinal symptoms were more frequent

and respiratory symptoms were infrequent. Eighty-six percent of patients fulfilled the criteria for MIS-C (18 patients). An exanthem was also found in 1 patient admitted because of respiratory disease, 1 with protracted fever, and 1 febrile neonate. Of the 20 patients admitted because of MIS-C (40%), only 2 did not present mucocutaneous symptoms. Patients with mucocutaneous involvement also had higher C-reactive protein, procalcitonin, and D-dimer levels and lower lymphocyte counts in their first laboratory test on presentation to the emergency department. They were admitted to the PICU more frequently, and length of stay was longer than for patients without mucocutaneous involvement. All patients admitted to the PICU with mucocutaneous symptoms were classified as MIS-C.

Adjusted for age and sex, patients with mucocutaneous involvement had a higher risk of PICU admission (odds ratio, 10.24; 95% confidence interval, 2.23-46.88; *P* = .003). The odds ratio for conjunctival hyperemia was 30.28 (3.25-281.69; *P* = .003), and the odds ratio for rash was 6.22 (1.42-27.26; *P* = .015). None of the patients died or experienced long-term sequelae apart from 1 patient with a coronary artery ectasia, who is currently being followed up by the Cardiology Department, and 1 patient who had myopathy that lasted for 6 months.

DISCUSSION

The prevalence of COVID-19 within the 6.68 million people living in the community of Madrid is one of the highest in Europe.¹² Our institution was designated as a pediatric referral center during the peak of the pandemic and attended the largest volume of COVID-19 and regular emergencies in the area.¹³ Between March and November 2020, only 0.14% of hospital admissions were because of COVID-19, but by November 30, 2020, hospital admissions grew to 52,449 patients, with 11,369 deaths in the Madrid region.¹⁴ Several mechanisms have been proposed to explain the difference in severity of SARS-CoV-2 infections between adult and pediatric patients.¹⁵

In our series of children admitted for COVID-19, mucocutaneous symptoms were fourth in frequency, after fever, respiratory symptoms, and gastrointestinal symptoms. The presence of mucocutaneous symptoms (42%) is much higher than in other series of admitted pediatric patients, which provide figures of the presence of rash (<15% patients) or conjunctivitis (<5% patients).⁴ As our investigation was entirely focused on the cutaneous manifestations of COVID-19, we made efforts to include data on these findings that other registries may have missed. In fact, the only previous study focused on hospitalized

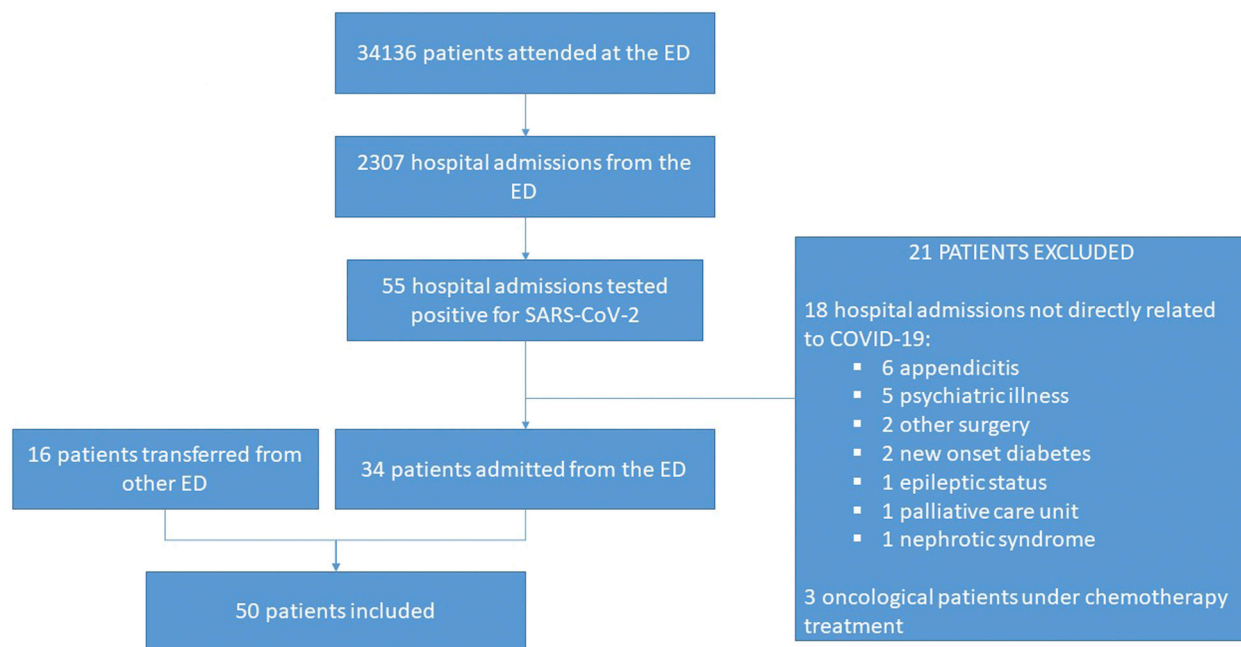


Fig 1. Flowchart of patients included in the study. *ED*, Emergency department.

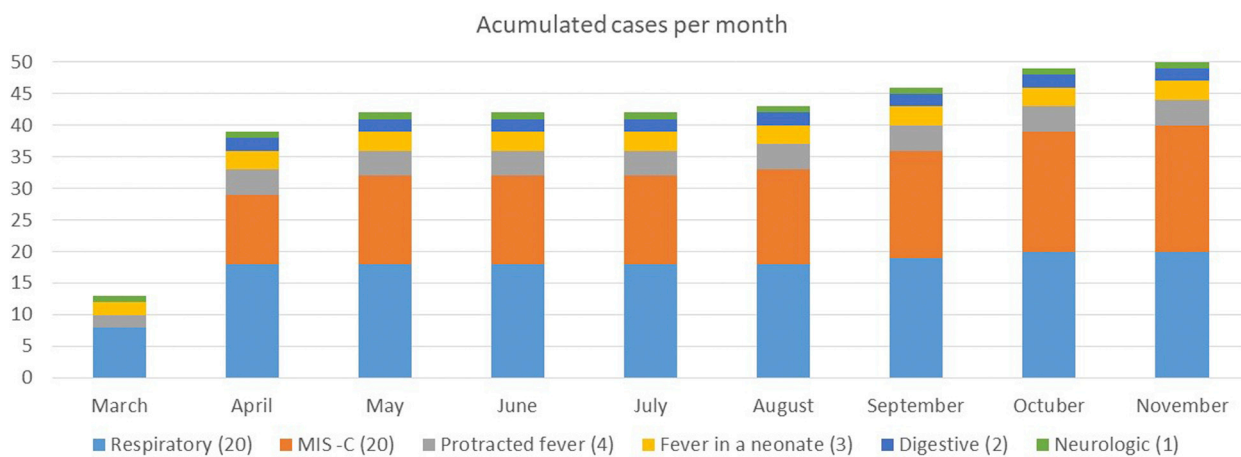


Fig 2. Evolution of children admitted to the authors' institution with COVID-19 throughout the pandemic. Respiratory disease consisted of pneumonia (9 cases), bronchiolitis (7 cases), and upper respiratory tract infection (4 cases). Gastrointestinal involvement consisted of prolonged diarrhea (1 case) and recurrent abdominal pain (1 case). Neurologic disease was due to multiple thrombosis in 1 patient. *MIS-C*, Multisystem inflammatory syndrome in children.

pediatric patients with mucocutaneous disease was by Rekhman et al,¹⁶ who described the same proportion of mucocutaneous involvement (42%).

In our institution during the first month of the outbreak, most admissions were due to respiratory diseases and skin manifestations were infrequent. Probably for that reason, in the early pediatric literature about COVID-19 manifestations in children there is either no mention of skin involvement in Chinese series or a reported rate as low as 3% in the Italian series.^{2,3} Mucocutaneous lesions have been

seen more frequently since mid-April 2020, after the first cases of MIS-C were recognized, and studies have started to reflect the presence of skin lesions.^{5,6,17}

Mucocutaneous symptoms appeared in 6 out of 10 patients who required admission to PICU. It is known that mucocutaneous symptoms are prominent in MIS-C. Up to 90% of patients diagnosed with MIS-C had some kind of mucocutaneous involvement. This is a higher rate than reported in other studies of patients with this condition, which

Table I. Characteristics of hospitalized children with COVID-19

Characteristics	All cases (n = 50)	Mucocutaneous involvement YES (n = 21)	Mucocutaneous involvement NO (n = 29)	P value
Age median (interquartile range)	9.5 (4.7-12)	9.4 (5.1-11.7)	4 (0.1-12.2)	<.001
Age group, n (%)				.024
<2 years	15 (30)	2 (9.5)	13 (44.8)	
2-10 years	16 (32)	11 (52.3)	5 (17.2)	
>10 years	19 (38)	8 (38.1)	11 (37.9)	
Sex, n (%)				.916
Male	29 (58)	12 (57.1)	17 (58.6)	
Female	21 (42)	9 (42.8)	12 (41.4)	
Underlying medical condition, n (%)	5 (10)	1 (4.7)	4 (13.7)	.293
Reason for admission, n (%)				<.001
Respiratory	20 (40)	1 (4.7)	19 (65.5)	
Digestive	2 (4)	0	2 (6.9)	
Neurologic	1 (2)	0	1 (3.4)	
Multisystem inflammatory syndrome	20 (40)	18 (85.7)	2 (6.9)	
Fever in a neonate	3 (6)	1 (4.7)	2 (6.9)	
Protracted fever	4 (8)	1 (4.7)	3 (10.3)	
PICU admission, n (%)	28 (56)	17 (80.9)	9 (31.3)	<.001
Median days of stay (interquartile range)	8 (3-10)	10 (8-12)	4 (3-8)	<.001
Symptoms at the ED, n (%)				
Fever	45 (90)	21 (100)	24 (82.7)	.044
Respiratory (rhinorrhea, cough, respiratory distress, thoracic pain, sore throat)	31 (62)	8 (38.1)	23 (79.3)	.003
Gastrointestinal (abdominal pain, vomiting, diarrhea)	32 (64)	19 (90.4)	13 (44.8)	<.001
Neurological (headache, irritability, drowsiness)	18 (36)	8 (38.1)	10 (34.5)	.792
Myalgia	7 (14)	3 (14.2)	4 (13.8)	.960
Anosmia, ageusia	3 (6)	1 (4.7)	2 (6.9)	.753
Signs at the ED, n (%)				
Altered appearance	16 (32)	12 (57)	4 (13.8)	.001
Extreme tachycardia*	18 (36)	14 (66)	4 (13.8)	.001
Oxygen saturation < 94%	7 (14)	0	7 (24.1)	.003
Laboratory values median (interquartile range)				
Leukocytes (cells/ μ L)	7940 (5510-12240)	7880 (7015-1197)	8510 (4910-13027)	.659
Neutrophils (cells/ μ L)	6200 (3340-9400)	6875 (6252-10105)	4080 (1937-7747)	.159
Lymphocytes (cells/ μ L)	870 (520-2130)	510 (362-772)	2415 (1005-3885)	<.001
D-dimer (μ g/mL)	2.22 (1.18-3.71)	4.04 (2.29-11.19)	1.39 (0.44-2.39)	<.001
Lactate dehydrogenase (UI/L)	301 (268-351)	297 (253-1197)	303 (264-486)	.419
C-reactive protein (mg/dL)	11.47 (0.77-20.68)	25.46 (12.36-34.12)	0.85 (0.20-8.69)	<.001
Procalcitonin (ng/mL)	2.06 (0.63-6.46)	2.61 (1.39-4.64)	0.14 (0.06-1.84)	<.001

ED, Emergency department; PICU, pediatric intensive care unit.

*Heart rate \geq 99th percentile for age.

described percentages from 47% to 83%.^{5,6,16,17} Because this syndrome usually requires PICU admission,¹⁶ the presence of exanthem or conjunctival hyperemia in our series is an independent predictor of PICU admission in hospitalized pediatric patients with COVID-19. A similar conclusion was reached regarding with gastrointestinal manifestations,

probably due to the same underlying explanation.¹⁸ In the subgroup of patients with MIS-C, Trevor et al¹⁷ found no association between the presence of mucocutaneous changes and the risk of PICU admission. Due to the small percentage of MIS-C patients without mucocutaneous disease in our series, this finding cannot be evaluated.

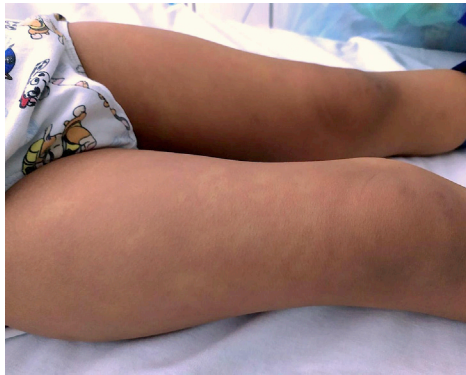

Fig 3. Multisystem inflammatory syndrome. Confluent exanthem on thighs.

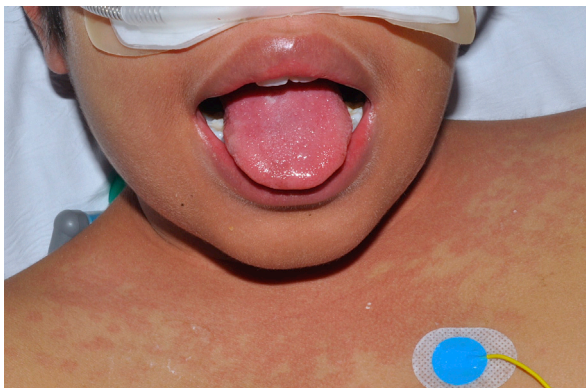

Fig 4. Multisystem inflammatory syndrome. Macular and papular eruption on the neck and strawberry tongue.

The presence of any mucocutaneous lesion in febrile children in the current epidemiologic context should prompt interrogation about close contacts with suspected or confirmed COVID-19 cases. The association of other symptoms, especially gastrointestinal complaints, should alert the pediatrician to the possibility of a severe COVID-19 case. The natural 4- to 5-week gap between SARS-CoV-2 infection and the development of MIS-C symptoms warrants monitoring of affected individuals.¹⁹ Attention to vital signs is key, because extreme tachycardia is a common early sign of shock. Initial blood tests should include full blood count, C-reactive protein, urea, creatinine, electrolytes, and liver function. If results from these tests support a diagnosis of MIS-C, additional investigation is recommended to determine the diagnosis and severity of the disease.²⁰

The exanthem in admitted patients in our institution was described as macular and/or papular in all cases. Different from adult COVID-19 patients, in that no vesicular, livedoid, or necrotic lesions were found,⁷ except in 1 patient who had an isolated acral

late ischemic lesion. At our institution, skin lesions in children with COVID-19 who did not require admission were usually located acral,⁸ whereas lesions in hospitalized patients tended to appear on the trunk and limbs, with palms and soles less frequently involved. As in other series, pernio-like lesions are infrequent in hospitalized pediatric patients.^{16,17}

Conjunctival hyperemia appeared in practically the same proportion as the exanthem in our series and was a better independent predictor of PICU admission than the exanthem itself. Although in adults, it has received little attention, it should be considered as an alarm sign in children with suspected or confirmed COVID-19, as it has been frequently described in patients with MIS-C.^{5,6,16,17}

Our center is located in one of the regions most impacted during the pandemic in Europe. Although the fact of being a single-institution study is a limitation, we think the population is representative and offers a large cohort of hospitalized pediatric patients with COVID-19 and mucocutaneous involvement. Nevertheless, more data from other centers should be obtained in an effort to conduct a meta-analysis on patients admitted with COVID-19 and on the subgroup of MIS-C cases. As another limitation, although the study project started early in the course of the pandemic in Spain, most of the data were retrieved retrospectively.

CONCLUSIONS

Mucocutaneous involvement is frequent in COVID-19 pediatric patients admitted to the hospital. Most of the patients hospitalized with mucocutaneous symptoms fulfilled MIS-C criteria. As a result, patients with an exanthem or conjunctival hyperemia at admission have a higher probability of PICU admission and a longer length of stay than those without mucocutaneous symptoms.

Conflicts of interest

None disclosed.

REFERENCES

1. Munro AP, Faust SN. COVID-19 in children: current evidence and key questions. *Curr Opin Infect Dis.* 2020;33(6):540-547.
2. Lu X, Zhang L, Du H, et al. SARS-CoV-2 infection in children. *N Engl J Med.* 2020;382(17):1663-1665.
3. Parri N, Lenge M, Buonsenso D. Children with COVID-19 in pediatric emergency departments in Italy. *N Engl J Med.* 2020; 383(2):187-190.
4. Swann OV, Holden KA, Turtle L, et al. Clinical characteristics of children and young people admitted to hospital with COVID-19 in United Kingdom: prospective multicentre observational cohort study. *BMJ.* 2020;370:m3249.
5. Feldstein LR, Rose EB, Horwitz SM, et al. Multisystem inflammatory syndrome in U.S. children and adolescents. *N Engl J Med.* 2020;383(4):334-346.

6. Whittaker E, Bamford A, Kenny J, et al. Clinical characteristics of 58 children with a pediatric inflammatory multisystem syndrome temporally associated with SARS-CoV-2. *JAMA*. 2020;324(3):259-269.
7. Galván Casas C, Català AC, Carretero Hernández G, et al. Classification of the cutaneous manifestations of COVID-19: a rapid prospective nationwide consensus study in Spain with 375 cases. *Br J Dermatol*. 2020;183(1):71-77.
8. Colmenero I, Santonja C, Alonso-Riaño M, et al. SARS-CoV-2 endothelial infection causes COVID-19 chilblains: histopathological, immunohistochemical and ultrastructural study of seven paediatric cases. *Br J Dermatol*. 2020;183(4):729-737.
9. Freeman EE, McMahon DE, Lipoff JB, et al. Pernio-like skin lesions associated with COVID-19: a case series of 318 patients from 8 countries. *J Am Acad Dermatol*. 2020;83(2):486-492.
10. Andina D, Belloni-Fortina A, Bodemer C, et al. Skin manifestations of COVID-19 in children: part 2. *Clin Exp Dermatol*. 2021;46(3):451-461.
11. Centers for Disease Control and Prevention. Multisystem inflammatory syndrome in children (MIS-C) associated with coronavirus disease 2019 (COVID-19). Accessed December 1, 2020. Available at: <https://emergency.cdc.gov/han/2020/han00432.asp>
12. Pollán M, Pérez-Gómez B, Pastor-Barriuso, et al. Prevalence of SARS-CoV-2 in Spain (ENE-COVID): a nationwide, population-based seroepidemiological study. *Lancet*. 2020;396(10250):535-544.
13. Alonso Cadenas JA, Andina Martínez D, Martín Díaz MJ, et al. In response to the article «Impact of the COVID-19 pandemic in the emergency room: first findings in a hospital in Madrid». *An Pediatr (Barc)*. 2020;94(4):270-272.
14. Actualización n° 262. Enfermedad por el coronavirus (COVID-19). Accessed December 1, 2020. Available at: https://www.mscbs.gob.es/profesionales/saludPublica/ccayes/alertasActual/nCov/documentos/Actualizacion_262_COVID-19.pdf
15. Zimmermann P, Curtis N. Why is COVID-19 less severe in children? A review of the proposed mechanisms underlying the age-related difference in severity of SARS-CoV-2 infections. *Arch Dis Child*. 2020. <https://doi.org/10.1136/archdischild-2020-320338>.
16. Rekhtman S, Tannenbaum R, Strunk A, et al. Mucocutaneous disease and related clinical characteristics in hospitalized children and adolescents with COVID-19 and multisystem inflammatory syndrome in children. *J Am Acad Dermatol*. 2021;84(2):408-414.
17. Young TK, Shaw KS, Shah JK, et al. Mucocutaneous manifestations of multisystem inflammatory syndrome in children during the COVID-19 pandemic. *JAMA Dermatol*. 2021;157(2):207-212.
18. Jimenez DG, Rodríguez-Belvis MV, Gonzalez PF, et al. COVID-19 gastrointestinal manifestations are independent predictors of PICU admission in hospitalized pediatric patients. *Pediatr Infect Dis J*. 2020;39(12):e459-e462.
19. Belot A, Antona D, Renolleau S, et al. SARS-CoV-2-related paediatric inflammatory multisystem syndrome, an epidemiological study, France, 1 March to 17 May 2020. *Euro Surveill*. 2020;25(22):2001010.
20. Harwood R, Allin B, Jones CE, et al. PIMS-TS National Consensus Management Study Group. A national consensus management pathway for paediatric inflammatory multisystem syndrome temporally associated with COVID-19 (PIMS-TS): results of a national Delphi process. *Lancet Child Adolesc Health*. 2021;5(2):133-141.