

High-dose cyclophosphamide without stem cell rescue in immune-mediated necrotizing myopathies

OPEN

Christopher A. Mecoli,
MD, MHS
Arash H. Lahouti, MD
Robert A. Brodsky, MD
Andrew L. Mammen,
MD, PhD
Lisa Christopher-Stine,
MD, MPH

Correspondence to
Dr. Christopher-Stine:
lchrist4@jhmi.edu

ABSTRACT

Objective: To describe the experience managing treatment-refractory immune-mediated necrotizing myopathies (IMNM) with high-dose cyclophosphamide (HiCy) therapy.

Methods: Five patients with severe refractory IMNM who were treated with HiCy without stem cell rescue were identified. Their medical records were reviewed to assess demographic, clinical, and histologic characteristics as well as response to therapy.

Results: Three patients with anti-signal recognition particle (SRP) and 2 patients with anti-HMG-CoA reductase autoantibodies were included. The mean follow-up time after HiCy therapy was 37 ± 28 months. Two patients demonstrated substantial response, evidenced by improved muscle strength and decreased muscle enzymes after HiCy therapy; both of these patients were anti-SRP positive. Four patients experienced febrile neutropenia after HiCy therapy, one of which required a prolonged intensive care unit stay for infectious complications, from which they eventually recovered.

Conclusions: These data suggest that HiCy therapy without stem cell rescue may be considered as an alternative for the treatment of refractory IMNM. *Neurol Neuroimmunol Neuroinflamm* 2017;4:e381; doi: 10.1212/NXI.0000000000000381

GLOSSARY

ASCT = autologous stem cell transplantation; **CK** = creatine kinase; **HiCy** = high-dose cyclophosphamide; **IG** = immunoglobulin; **IMNM** = immune-mediated necrotizing myopathy; **SRP** = signal recognition particle.

Some patients with myositis may be resistant to standard immunosuppressive regimens, including prednisone, methotrexate, azathioprine, IV immunoglobulin (IG), rituximab, and/or other medications. In such patients, especially those with a progressive clinical course, additional therapies may be required. High-dose chemotherapy followed by stem cell rescue through autologous stem cell transplantation (ASCT) has been previously used with some success in patients with refractory myositis.^{1–3} However, given the risks associated with ASCT, high-dose cyclophosphamide (HiCy) without bone marrow transplantation can also be considered. First used for treatment of severe aplastic anemia,^{4,5} HiCy has subsequently been applied to several rheumatologic and neurologic diseases.^{6–10} As HiCy seems to be better tolerated than ASCT and yet induces a high rate of remission in refractory autoimmune diseases,¹¹ we have used it to treat a number of patients with refractory myositis at the Johns Hopkins Myositis Center.¹² In this case series, we report the clinical response of 5 patients who underwent HiCy therapy for refractory immune-mediated necrotizing myopathy (IMNM), a particularly severe form of myositis that predominantly affects skeletal muscle.

METHODS This is a retrospective case series review of 5 patients with IMNM who were treated with HiCy at the Johns Hopkins Myositis Center. The Johns Hopkins Institutional Review Board approved this study. All patients had been evaluated as part of routine clinical care between 2009 and 2016. The patients were administered cyclophosphamide at a dose of 50 mg/kg of ideal body weight IV

Supplemental data
at Neurology.org/nn

From the Johns Hopkins University School of Medicine (C.A.M., A.H.L., R.A.B., A.L.M., L.C.-S.), Baltimore; and National Institute of Health (A.L.M.), Bethesda, MD.

Funding information and disclosures are provided at the end of the article. Go to Neurology.org/nn for full disclosure forms. The Article Processing Charge was funded by the authors.

This is an open access article distributed under the terms of the Creative Commons Attribution-NonCommercial-NoDerivatives License 4.0 (CC BY-NC-ND), which permits downloading and sharing the work provided it is properly cited. The work cannot be changed in any way or used commercially without permission from the journal.

Table 1 Summary of demographic, clinical features, and immunosuppressive medications in 5 patients treated with HiCy

Patient	Age at diagnosis/sex/race	Phenotype (myositis-specific antibody)	Previous treatments	Follow-up period after HiCy therapy, mo
1	53/M/AA	NM (anti-SRP)	MEP, PDN, MTX, IVIG, AZA, MMF, TAC, corticotropin injection, RTX	34
2	33/F/C	NM (anti-SRP)	PDN, AZA, IVIG, RTX	72
3	36/M/AA	NM (anti-SRP/anti-Ro)	PDN, AZA, RTX	7
4	38/M/C	NM (anti-HMGCR)	PDN, AZA, IVIG, MTX, RTX, PLEX	59
5	22/F/AA	NM (anti-HMGCR)	PDN, MTX, MMF, IVIG, RTX, PLEX	14

Abbreviations: AA = African American; AZA = azathioprine; C = Caucasian; HiCy = high-dose cyclophosphamide; IG = immunoglobulin; MEP = methylprednisolone; MMF = mycophenolate mofetil; MTX = methotrexate; NM = necrotizing myopathy; PDN = prednisone; PLEX = plasmapheresis/plasma exchange; RTX = rituximab; SRP = signal recognition particle; TAC = tacrolimus.

every day for 4 consecutive days. The method of administering HiCy and the posttreatment supportive care has been previously described.¹³ Bilateral arm abductor and hip flexor muscle strength was graded using a 0–5 modified Medical Research Council scale and subsequently transformed to the 10-point Kendall scale and summed together for a score range of 0–40 as previously described¹⁴ and included in the Supplementary Materials. This transformation has not been validated. Definite responders were defined as those who both (1) improved by at least 2 grades in either the upper or lower extremities and (2) were able to taper their prednisone dose below 10 mg/d. Nonresponders were defined as patients who received therapy without improved muscle strength or ability to taper prednisone. Follow-up for patients after HiCy administration was at the discretion of the primary treating rheumatologist and neurologist. Most patients were followed at 2–3-month intervals.

RESULTS Table 1 summarizes demographic features, clinical characteristics, and immunosuppressive therapies in 5 patients. Tables 2 and 3 summarize muscle strength, prednisone dose, and creatine kinase (CK) level before and after HiCy treatment. Figure provides the overall change in strength over the first year for each patient after receiving HiCy therapy.

Patient 1. A 53-year-old African American man presented with a 4-month history of progressive upper and lower extremity weaknesses, dyspnea on exertion, and dysphagia. His initial CK level was greater than

9,000 IU/L, and he had muscle strength grade 3/5 in proximal upper and lower extremities. Electromyography demonstrated an irritable myopathy, and muscle biopsy showed severe necrotizing myopathy. Lower extremity MRI showed atrophy and muscle edema. Antibodies against signal recognition particle (SRP) were detected in this patient's serum. He was treated with corticosteroids and methotrexate with minimal improvement. Azathioprine, mycophenolate mofetil, and IVIG treatment yielded temporary improvement in muscle strength, but worsening dysphagia and muscle pain. He was subsequently treated with ACTH gel (corticotropin injection), rituximab, and tacrolimus with no substantial improvement in his symptoms. Given the refractory nature of his disease, the patient was treated with HiCy. He tolerated the treatment well, but 9 days after discharge, he was admitted to the hospital with neutropenic fever and treated for pneumonia. In the ensuing 2 months, he experienced marked improvement in muscle strength, and his CK level decreased from 2,000 to less than 500 IU/L. The patient was completely weaned off immunosuppressive therapy, and 3 months later, his muscle strength was graded 5/5 in both upper and lower extremities and his CK level normalized.

Patient 2. A 33-year-old white woman who developed 5 months of progressive lower extremity weakness and dyspnea was evaluated in clinic in March 2007. Her evaluation was notable for proximal muscle weakness, CK of 8,000 IU/L, an irritable myopathy on electromyography, muscle biopsy showing a necrotizing myopathy, and positive anti-SRP antibodies. Her proximal upper extremities were graded as 4/5 and lower extremities 4–/5. She was initially treated with azathioprine and prednisone 60 mg daily without effect. She subsequently received methotrexate and IVIG (2 g/kg), but despite these therapies, she had persistent weakness, and her CK level remained 2,000–3,000 IU/L. She received rituximab with suppression of her CD19/CD20 cell populations, after which her CK actually increased to 6,000 IU/L.

Table 2 Summary of creatine kinase (CK) value, glucocorticoid dose, and manual muscle strength testing before high-dose cyclophosphamide therapy

Patient	Peak CK, IU/L	Max prednisone dose, mg/d	Deltoid strength, min	Hip flexor strength, min
Before therapy				
Definite responders				
1	9,000	60	3/5	3/5
2	8,495	60	4–/5	2/5
Nonresponders				
3	16,000	100	3+/5	2/5
4	18,000	100	4+/5	2/5
5	22,050	80	1–2/5	1–2/5

CK normal range (24–170 IU/L).

Table 3 Summary of creatine kinase (CK) value, glucocorticoid dose, and manual muscle strength testing after high-dose cyclophosphamide therapy

Patient	Nadir CK, IU/L	Most recent CK, IU/L	Current prednisone dose, mg/d	Deltoid strength (at last visit)	Hip flexor strength (at last visit)
After therapy					
Definite responders					
1	123	494	0	4+/5	5/5
2	100	100	0	4+/5	4+/5
Nonresponders					
3	1,058	3,594	10	4-/5	2/5
4	245	714	10	5/5	3/5
5	663	3,923	40 every other day	1-2/5	1-2/5

CK normal range (24-170 IU/L).

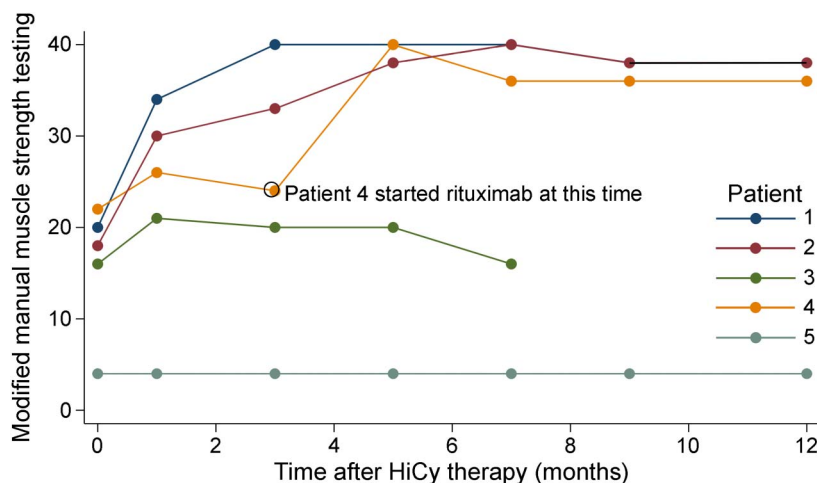
She therefore received HiCy in November 2008. She tolerated the therapy well, but 9 days after the infusion, she was admitted to the hospital for neutropenic fever and received broad-spectrum antibiotics. No infection was identified, and she subsequently recovered. In January 2009, her strength was starting to progressively improve. Over the subsequent years, she was able to taper her immunosuppressive regimen while retaining her strength and function. During her most recent follow-up appointment, her CK level trended down to 100 IU/L, her strength had improved to 4+/5 in proximal muscle groups, and she remained in clinical remission off of all immunosuppressive therapies.

Patient 3. A 36-year-old African American man presented to our clinic in February 2011 with a 7-month history of proximal muscle weakness accompanied by

a 40-lb unintentional weight loss. His evaluation revealed a CK level of 16,000 IU/L, and electromyography showed an irritable myopathy. A muscle biopsy of his right thigh by report showed minimal inflammation. He was subsequently found to have both anti-SRP and anti-Ro autoantibodies. His proximal lower extremities were graded as 2/5 in strength bilaterally. He was treated with high-dose prednisone, 100 mg/d, and azathioprine with initial improvement, but this was transient, despite this therapy, he worsened clinically with a persistently elevated CK level to ~4,000 IU/L and proximal muscle weakness graded 2/5. He was subsequently trialed on methotrexate and 4 doses of rituximab therapy with documented suppressed CD19/CD20 cell counts. However, he did not have any significant improvement. He therefore was referred for and received HiCy in May 2016. His hospital course was complicated by neutropenic fever and fungal pneumonia as well as *Clostridium difficile* colitis. He was hospitalized for a total of 25 days. Within months, his CK level had decreased to 1,000 IU/L; however, at his most recent follow-up, 7 months after HiCy, his CK level again started to rise to 3,500 IU/L with a decrease in strength to pre-HiCy levels.

Patient 4. A 38-year-old white man presented with an 11-month history of progressive muscle weakness and myalgia. His initial evaluation was notable for a CK level of 18,000 IU/L, electromyography revealing an irritable myopathy and MRI of bilateral thighs demonstrating muscle edema of all compartments. A muscle biopsy sample showed severe necrotizing myopathy. Serum test revealed antibodies to 3-hydroxy-3-methylglutaryl-CoA reductase (HMGCR antibodies), with no history of statin use. The patient was started on prednisone 60 mg daily with worsening muscle weakness in upper extremities grade 4+/5 and hip flexors grade 2/5. IVIG (2 g/kg) and azathioprine treatments were administered, but the muscle

Figure Strength over time for each patient over the first year after receiving high-dose cyclophosphamide therapy



Y-axis is 0-40, where the deltoids and hip flexors were scored on a 0-5 scale, and subsequently transformed to a scale of 0-10 for each of the 4 muscles, resulting in a maximum score of 40. HiCy = high-dose cyclophosphamide.

weakness worsened. He was prescribed 2 doses of rituximab and methotrexate, resulting in slight improvement in muscle strength, but CK levels started to rise again within 6 months. Rituximab was started again, but it was accompanied by an anaphylactic reaction. He then received 5 plasmapheresis treatments without any substantial improvement in strength. The patient was admitted and received HiCy for 4 consecutive days in September 2011. He had 1 episode of neutropenic fever 15 days after HiCy, but he recovered successfully. Within 1 month, strength remained at 4/5 in the proximal upper extremity and 3/5 in the hip flexors (weaker than the grades before HiCy therapy). The patient was started on mycophenolate mofetil without any improvement after 3 months. He underwent desensitization for rituximab and received a dose of rituximab in intensive care unit. Five months after rituximab therapy, muscle strength improved to 5/5 in the upper extremities and 4/5 in the hip flexors, and the CD19/CD20 counts remained suppressed. On his most recent visit, the patient required 10 mg prednisone daily with intermittent rituximab.

Patient 5. A 22-year-old African American woman first developed proximal muscle weakness 6 weeks after the delivery of her second child in January 2007. She was evaluated at our clinic in March 2008 and was found to have a CK level of 15,000 IU/L and an EMG showing an irritable myopathy. She underwent a muscle biopsy that revealed a necrotizing myopathy. She was treated with 80 mg/d prednisone and methotrexate without substantial benefit. She was thus transitioned to IVIG, but her CK level actually increased to over 17,000 IU/L. She then received rituximab infusions with minimal improvement and a nadir CK level of 4,800 IU/L. Mycophenolate was added with no appreciable difference. She also received 1 round of plasmapheresis, which resulted in substantial improvement in strength but only lasted a few days and was complicated by bacteremia and pneumonia. Throughout this time, she was unable to decrease her prednisone less than 20–30 mg/d. Serum test revealed antibodies to 3-hydroxy-3-methylglutaryl-CoA reductase (HMGCR antibodies), with no history of statin use. Given her refractory nature and poor functional status requiring a wheelchair and family assistance, she received HiCy in April 2015. She tolerated the infusions well and did not have any complications after hospitalization. In May, she started to observe increasing proximal muscle strength, and this continued throughout 2015 (knee flexors/extensors by dynamometry increased from 11–13 to 25–26 lbs bilaterally). Her CK level decreased to ~1,800 IU/L. However, in February 2016, she was noted to start to decline functionally.

At her last visit in May 2016, approximately 1 year after HiCy, she was noted to have persistent muscle weakness (hip flexors 2/5) and still required 40 mg/d prednisone every other day.

TOXICITY All 5 patients tolerated the HiCy regimen well. All patients experienced mild side effects including nausea and alopecia. Neutropenic fever was observed in 4 patients within 2–3 weeks after receiving HiCy, but all recovered. One patient (patient 3) experienced a prolonged hospital stay of 25 days after HiCy for treatment of *C difficile* colitis and fungal pneumonia. At the time of this report, no patient experienced hemorrhagic cystitis or malignancy. There were no fatalities.

DISCUSSION In this study, we have described our experience treating patients with severe refractory IMNM with HiCy without stem cell rescue. The 2 definite responders (patients 1 and 2) had substantial improvement in muscle strength and decreased requirement for corticosteroids after treatment. Non-responders included patients 3, 4, and 5 who had no improvement in strength or ability to taper immunosuppression. Patient 3 had initial improvement with subsequent return to pre-HiCy status. Patient 4 initially demonstrated partial response but then worsened, prompting treatment with rituximab, after which he demonstrated improvement. In all cases, the adverse effects were manageable and comparable with those observed in previous HiCy studies.^{6,15} Although 4 of the 5 patients required hospitalization for neutropenic fever and/or infection, the high risk of this side effect was anticipated and considered warranted, given the limited additional treatment options and the potential benefit of HiCy. This series suggests that HiCy may be effective in select patients with treatment-refractory IMNM.

IMNM is sometimes associated with unique autoantibodies, including anti-SRP (patients 1–3) and anti-HMGCR autoantibodies (patients 4–5), and a distinct clinical phenotype.^{16,17} Anti-HMGCR myopathy is characterized by prominent myofiber necrosis on biopsy and very high CK levels.^{16,18} Similarly, patients with anti-SRP antibodies frequently present with markedly elevated CK levels and a necrotizing myopathy without primary inflammation.^{17,19–21} Although it is interesting that both patients who responded to HiCy were anti-SRP positive, the numbers included in this study are too small to conclude whether autoantibody status can predict response to this therapy.

Regarding the 3 patients with anti-SRP antibodies, 2 experienced dramatic improvement, whereas the third had initial improvement with subsequent worsening at the time of this report. Notably, the

patient who worsened also had anti-Ro autoantibodies. Other groups have noted that in rheumatologic conditions such as systemic lupus erythematosus and scleroderma, the presence of anti-Ro autoantibodies portends a poorer prognosis^{22,23} and in myositis has been associated with earlier and more severe disease.^{24–26}

A review of the literature suggests that despite an initial response rate, most patients with severe autoimmune disease ultimately relapse following HiCy therapy with only 20% remaining disease free 5 years after treatment.¹² However, it should be noted that patients with myositis were not included in those studies. We acknowledge that this therapy carries a higher risk of infection and morbidity, especially when taking into account a potential high relapse rate as seen in other autoimmune conditions treated with this regimen. Furthermore, long-term risk regarding malignancy must be taken into account, given its association with some necrotizing myopathies.^{27,28} However, for patients who have failed conventional therapies for necrotizing myopathy (i.e., rituximab and IVIG), we believe that this therapy offers another option for the clinician to consider who otherwise has very few options.

Although follow-up of patients with myositis in the current study was limited to an average of 3 years (median 37 ± 28 months, range 7–72 months), the 2 responders have now been followed without relapse for 34 and 72 months, respectively. Additional study and follow-up time will be needed to further assess the true duration of remission.

A strength of this study is that all 5 patients underwent the same HiCy protocol at a single center. In addition, all have had longitudinal follow-up in the same center. Limitations of the study include its retrospective nature and the small number of patients. Furthermore, as this study was not protocol driven, follow-up was not uniform and at the discretion of the treating physician. Additionally, many patients were treated with concurrent medications; however, they were on stable doses for months preceding the administration of HiCy. As such, the likelihood that the patients had a delayed response to their background immunosuppressive medications is unlikely.

Although numerous therapies have been shown to be effective for the treatment of inflammatory myopathies, treatment of refractory cases, particularly IMNM, remains challenging.²⁹ The data presented here reveal that HiCy may represent a potential therapeutic alternative in IMNM patients with refractory disease.

AUTHOR CONTRIBUTIONS

C.A. Mecoli: design/conceptualization and drafting/revising manuscript. A.H. Lahouti: design/conceptualization and drafting/revising manuscript.

R.A. Brodsky: drafting/revising manuscript. A.L. Mammen: drafting/revising manuscript. L. Christopher-Stine: design/conceptualization and drafting/revising manuscript.

STUDY FUNDING

The Huayi and Siuling Zhang Discovery Fund.

DISCLOSURE

C.A. Mecoli and A.H. Lahouti report no disclosures. R.A. Brodsky served on the scientific advisory board for Alexion, Achillion, and Apellis; received research support from NIH, NHLBI, and AA/MDS Foundation; and is on the editorial board for Blood. A.L. Mammen served on the advisory board for aTYR Pharmaceuticals and Biogen; served on the scientific advisory board for Experimental Neurology and Arthritis and Rheumatism; holds patent for anti-AMGCR antibodies; and received research support from NIAMS/NIH and NIDDK/NIH. L. Christopher-Stine served on the scientific advisory board for Novartis, MedImmune, Walgreens/Option Care, Mallinckrodt, Idera Pharmaceuticals, Octapharma, and Corbus; received honoraria from Novartis, MedImmune, Walgreens/Option Care, Mallinckrodt, Idera Pharmaceuticals, and Octapharma; holds a patent for and receives royalties from detection of HMG-CoA reductase (HMGCR) antibodies in patient sera; consulted for NuFactor, Option Care, IgG America, Med-ProRx, CSL Behring, NHLBI; and participated in legal proceedings from McAloon and Friedman, P.C., Shaub, Ahmuty, Citrin, and Spratt, LLP, The Chartwell Law Offices, PK Law, and Bodie, Dolina, Hobbs, Friddell & Grenzer, P.C. Go to Neurology.org/nn for full disclosure forms.

Received February 10, 2017. Accepted in final form May 30, 2017.

REFERENCES

1. Henes JC, Heinzelmann F, Wacker A, et al. Antisignal recognition particle-positive polymyositis successfully treated with myeloablative autologous stem cell transplantation. *Ann Rheum Dis* 2009;68:447–448.
2. Holzer U, van Royen-Kerkhof A, van der Torre P, et al. Successful autologous stem cell transplantation in two patients with juvenile dermatomyositis. *Scand J Rheumatol* 2010;39:88–92.
3. Baron F, Ribbens C, Kaye O, Fillet G, Malaise M, Beguin Y. Effective treatment of Jo-1-associated polymyositis with T-cell-depleted autologous peripheral blood stem cell transplantation. *Br J Haematol* 2000;110:339–342.
4. Brodsky RA, Sensenbrenner LL, Jones RJ. Complete remission in severe aplastic anemia after high-dose cyclophosphamide without bone marrow transplantation. *Blood* 1996;87:491–494.
5. Brodsky RA, Chen AR, Dorr D, et al. High-dose cyclophosphamide for severe aplastic anemia: long-term follow-up. *Blood* 2010;115:2136–2141.
6. Moyo VM, Smith D, Brodsky I, Crilly P, Jones RJ, Brodsky RA. High-dose cyclophosphamide for refractory autoimmune hemolytic anemia. *Blood* 2002;100:704–706.
7. Petri M, Brodsky RA, Jones RJ, Gladstone D, Fillius M, Magder LS. High-dose cyclophosphamide versus monthly intravenous cyclophosphamide for systemic lupus erythematosus: a prospective randomized trial. *Arthritis Rheum* 2010;62:1487–1493.
8. Drachman DB, Adams RN, Hu R, Jones RJ, Brodsky RA. Rebooting the immune system with high-dose cyclophosphamide for treatment of refractory myasthenia gravis. *Ann NY Acad Sci* 2008;1132:305–314.
9. Henderson CF, Brodsky RA, Jones RJ, Levine SM. High-dose cyclophosphamide without stem cell rescue for the

- treatment of refractory Behcet's disease. *Semin Arthritis Rheum* 2011;41:301–304.
10. Krishnan C, Kaplin AI, Brodsky RA, et al. Reduction of disease activity and disability with high-dose cyclophosphamide in patients with aggressive multiple sclerosis. *Arch Neurol* 2008;65:1044–1051.
 11. DeZern AE, Petri M, Drachman DB, et al. High-dose cyclophosphamide without stem cell rescue in 207 patients with aplastic anemia and other autoimmune diseases. *Medicine (Baltimore)* 2011;90:89–98.
 12. Lahouti AH, Brodsky RA, Christopher-Stine L. Idiopathic inflammatory myopathy treated with high-dose immunosuppressive cyclophosphamide—a long-term follow-up study. *JAMA Neurol* 2015;72:1205–1206.
 13. Brodsky RA, Sensenbrenner LL, Smith BD, et al. Durable treatment-free remission after high-dose cyclophosphamide therapy for previously untreated severe aplastic anemia. *Ann Intern Med* 2001;135:477–483.
 14. Rider LG, Werth VP, Huber AM, et al. Measures of adult and juvenile dermatomyositis, polymyositis, and inclusion body myositis: physician and patient/parent global activity, manual muscle testing (MMT), Health Assessment Questionnaire (HAQ)/Childhood Health Assessment Questionnaire (C-HAQ), Childhood Myositis Assessment Scale (CMAS), Myositis Disease Activity Assessment Tool (MDAAT), Disease Activity Score (DAS), Short Form 36 (SF-36), Child Health Questionnaire (CHQ), Physician Global Damage, Myositis Damage Index (MDI), Quantitative Muscle Testing (QMT), Myositis Functional Index-2 (FI-2), Myositis Activities Profile (MAP), Inclusion Body Myositis Functional Rating Scale (IBMFRS), Cutaneous Dermatomyositis Disease Area and Severity Index (CDASI), Cutaneous Assessment Tool (CAT), Dermatomyositis Skin Severity Index (DSSI), Skindex, and Dermatology Life Quality Index (DLQI). *Arthritis Care Res (Hoboken)* 2011;63(suppl 11):S118–S157.
 15. Tehlirian CV, Hummers LK, White B, Brodsky RA, Wigley FM. High-dose cyclophosphamide without stem cell rescue in scleroderma. *Ann Rheum Dis* 2008;67:775–781.
 16. Christopher-Stine L, Casciola-Rosen LA, Hong G, Chung T, Corse AM, Mammen AL. A novel autoantibody recognizing 200-kd and 100-kd proteins is associated with an immune-mediated necrotizing myopathy. *Arthritis Rheum* 2010;62:2757–2766.
 17. Valiyil R, Casciola-Rosen L, Hong G, Mammen A, Christopher-Stine L. Rituximab therapy for myopathy associated with anti-signal recognition particle antibodies: a case series. *Arthritis Care Res (Hoboken)* 2010;62:1328–1334.
 18. Mammen AL, Chung T, Christopher-Stine L, et al. Autoantibodies against 3-hydroxy-3-methylglutaryl-coenzyme A reductase in patients with statin-associated autoimmune myopathy. *Arthritis Rheum* 2011;63:713–721.
 19. Miller T, Al-Lozi MT, Lopate G, Pestronk A. Myopathy with antibodies to the signal recognition particle: clinical and pathological features. *J Neurol Neurosurg Psychiatry* 2002;73:420–428.
 20. Tiniakou E, Pinal-Fernandez I, Lloyd TE, Albayda J. More severe disease and slower recovery in younger patients with anti-3-hydroxy-3-methylglutaryl-coenzyme A reductase-associated autoimmune myopathy. *Rheumatology (Oxford)* Epub 2017 Jan 17.
 21. Pinal-Fernandez I, Parks C, Werner JL, et al. Longitudinal course of disease in a large cohort of myositis patients with autoantibodies recognizing the signal recognition particle. *Arthritis Care Res (Hoboken)* 2017;69:263–270.
 22. Korbet SM, Schwartz MM, Evans J, Lewis EJ; Collaborative Study Group. Severe lupus nephritis: racial differences in presentation and outcome. *J Am Soc Nephrol* 2007;18:244–254.
 23. Wodkowski M, Hudson M, Proudman S, et al. Mono-specific anti-Ro52/TRIM21 antibodies in a tri-nation cohort of 1574 systemic sclerosis subjects: evidence of an association with interstitial lung disease and worse survival. *Clin Exp Rheumatol* 2015;33:S131–S135.
 24. Pinal-Fernandez I, Casal-Dominguez M, Huapaya JA, et al. A longitudinal cohort study of the anti-synthetase syndrome: increased severity of interstitial lung disease in black patients and patients with anti-PL7 and anti-PL12 autoantibodies. *Rheumatology (Oxford)* 2017;56:999–1007.
 25. La Corte R, Lo Mo Naco A, Locaputo A, Dolzani F, Trotta F. In patients with antisynthetase syndrome the occurrence of anti-Ro/SSA antibodies causes a more severe interstitial lung disease. *Autoimmunity* 2006;39:249–253.
 26. Marie I, Hatron PY, Dominique S, et al. Short-term and long-term outcome of anti-Jo1-positive patients with anti-Ro52 antibody. *Semin Arthritis Rheum* 2012;41:890–899.
 27. Allenbach Y, Keraen J, Bouvier AM, et al. High risk of cancer in autoimmune necrotizing myopathies: usefulness of myositis specific antibody. *Brain* 2016;139:2131–2135.
 28. Kadoya M, Hida A, Hashimoto Maeda M, et al. Cancer association as a risk factor for anti-HMGCR antibody-positive myopathy. *Neurol Neuroimmunol Neuroinflamm* 2016;3:e290. doi: 10.1212/NXI.0000000000000290.
 29. Albayda J, Christopher-Stine L. Novel approaches in the treatment of myositis and myopathies. *Ther Adv Musculoskelet Dis* 2012;4:369–377.