

## Case Report

# Clear Cell Chondrosarcoma with Rib Cage Metastasis: Case Report

Rui Caetano de Oliveira<sup>a, b</sup> John Reith<sup>c</sup> José Casanova<sup>b, d, e</sup>

<sup>a</sup>Pathology Department, Centro Hospitalar e Univeristário de Coimbra, Coimbra, Portugal;

<sup>b</sup>Coimbra Institute for Clinical and Biomedical Research (iCBR) area of Environment Genetics and Oncobiology (CIMAGO), Faculty of Medicine, University of Coimbra, Coimbra, Portugal;

<sup>c</sup>Pathology Department, Cleveland Clinic, Cleveland, OH, USA; <sup>d</sup>Orthopaedics Department, Centro Hospitalar e Univeristário de Coimbra, Coimbra, Portugal; <sup>e</sup>Faculdade de Medicina da Universidade de Coimbra, Coimbra, Portugal

## Abstract

Clear cell chondrosarcoma is a rare histological subtype of chondrosarcoma, usually with a relatively non-aggressive clinical course. However, infrequently they may relapse and metastasize. We describe a case of a male patient, 53 years old, with rib cage metastases of a clear cell chondrosarcoma 11 years after the first surgical intervention, and review the literature.

© 2021 The Author(s).  
Published by S. Karger AG, Basel

## Introduction

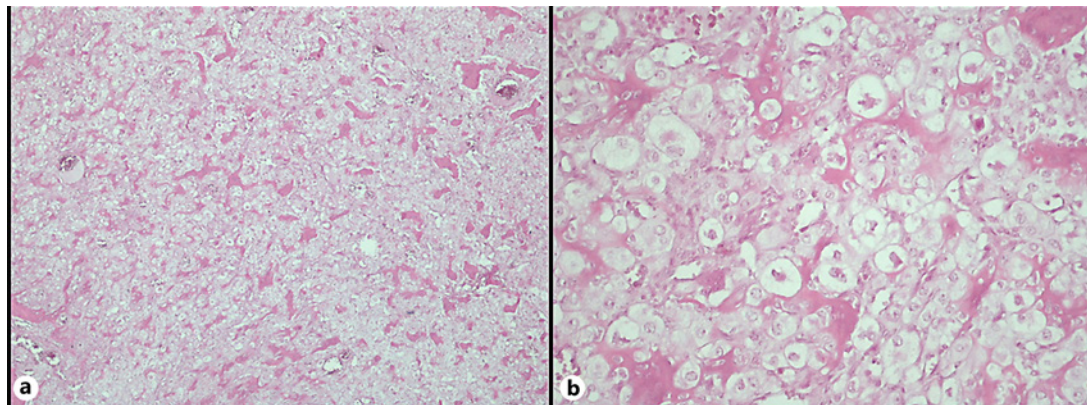
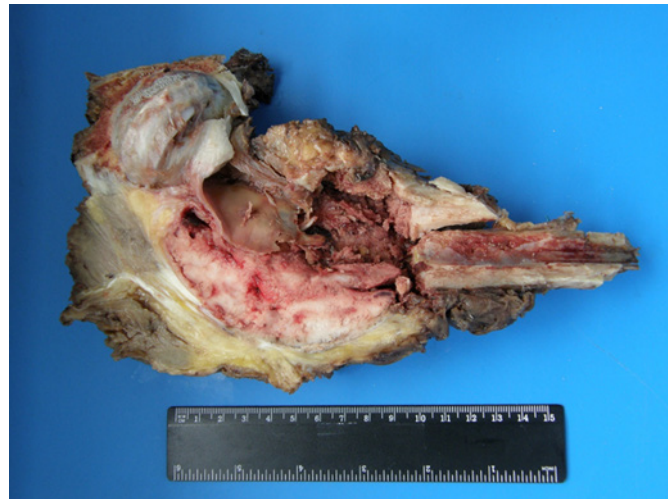Clear cell chondrosarcoma is a rare variant of chondrosarcoma characterized by cells with clear cytoplasm [1], first described in 1976 by Unni et al. [2]. Despite being a low-grade sarcoma with slow growth, clear cell chondrosarcoma is resistant to chemotherapy and radiotherapy [3], therefore exhibiting a high local recurrence rate, especially in cases with positive surgical margins [1, 4]. Surgery with curative intent is standard for these patients, but in some rare occasions, metastasis may occur [5–7]. We describe a rare case of a patient with metastasis from a clear cell chondrosarcoma.

## Case Report

The patient is a 53-year-old male patient with a previous history of clear cell chondrosarcoma of the left proximal femur, diagnosed 22 years ago. At that time, the lesion was thought to be a femoral neck cyst and was curetted and xenografted. No specimen for histology

Rui Caetano de Oliveira  
Centro Hospitalar e Univeristário de Coimbra  
Centro Hospitalar e Univeristário de Coimbra Serviço de Anatomia Patológica, piso -3  
Praceta Mota Pinto, PT-3000-075 Coimbra (Portugal)  
ruiapedrocoliveira@hotmail.com

**Fig. 1.** Gross inspection of periacetabular pelvic resection: there is a whitish lesion with hemorrhagic and necrotic areas, surrounding bone and with soft tissue component. Negative surgical margins were achieved resorting to wide resection.



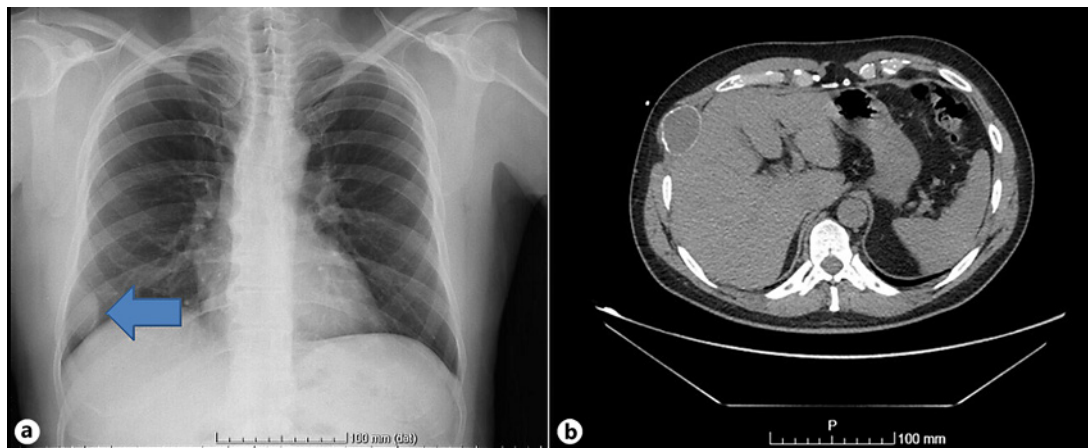
**Fig. 2. a** Tumour revealed a diffuse cell proliferation surrounding trabeculae of woven bone (H&E,  $\times 40$ ). **b** The tumour cells exhibited clear cell cytoplasm and moderate nuclear atypia (H&E,  $\times 200$ ).

was collected. Three months later the patient developed a local recurrence, which was curetted, and the histology showed clear cell chondrosarcoma.

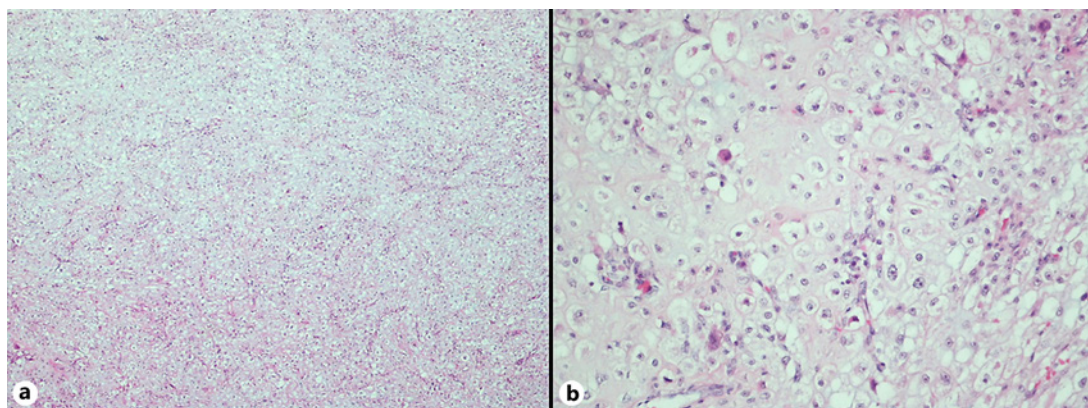
Because of the diagnosis, the patient underwent a proximal femur resection and reconstruction with modular revision total hip arthroplasty S-ROM<sup>®</sup>. All previous surgeries were performed in an outside institution.

The patient experienced a local recurrence 10 years after the proximal femoral resection. The recurrence involved the left femur region (Fig. 1; Fig. 2a, b), surrounding the hip prosthesis, and extending to the dome of the acetabulum. This was successfully treated at our institution with a periacetabular pelvic resection, Enneking-Dunham type II. Negative surgical margins were achieved by a wide resection of the femur, including the femoral prosthesis and a portion of the abductor apparatus. A resection of the capsule, surrounding tissues, and acetabulum was also performed.

An acetabular ice cone prosthesis and a proximal femur endomodular prosthesis were used for reconstruction. The postoperative period was unremarkable, and the patient regained function and was tumour free for 11 years.



**Fig. 3.** **a** Chest X-ray showed a lytic lesion of the rib cage (blue arrow). **b** Computed tomography (CT scan) confirmed the lytic lesion, on the 7th right rib, centred in the bone.



**Fig. 4.** **a** Histological evaluation revealed a diffuse cellular proliferation (H&E, ×20). **b** The cells had clear cell cytoplasm with well-defined boundaries and visible nucleoli, with areas of mature cartilage (H&E, ×200).

During follow-up in February 2018 (11 years and 1 month after the last surgery), a rib lesion was detected during radiology studies (Fig. 3a, b). A biopsy of the lesion showed a bone metastasis from the clear cell chondrosarcoma. In July 2018, a wide resection of the 7th and 8th rib was done. Grossly, there were two segments of ribs with surrounding soft tissue measuring 7.5 × 3.5 × 1.5 cm. On cut section, there was an oval lesion measuring 7 × 3 cm centred on the bone with a white-greyish cut surface. Microscopic examination revealed sheets of ovoid cells with clear or slightly eosinophilic cytoplasm, well-defined cytoplasmic borders, and large central nuclei and visible nucleoli. There were no mitoses. The lesion exhibited areas of mature hyaline cartilage and woven bone (Fig. 4a, b). Immunohistochemistry was performed on one representative block of the lesion, performed on Ventana Marker Platform Bench Mark ULTRA IHC/ISH, with an indirect multimeric detection system, biotin free, peroxidase conjugated, and showed diffuse positivity for S100 protein (4C4.9, Ventana, Arizona, USA) and absence of expression for melanoma A (A103, Ventana, Arizona, USA) and CD10 (SP67, Ventana, Arizona, USA).

At last follow-up (December 2018), the patient had no evidence of disease.

## Discussion

Clear cell chondrosarcoma, which comprises less than 2% of all chondrosarcomas, represents a unique entity [8]. It is three times more common in men, and most patients are between 25 and 50 years of age (range 12–84 years). Common sites of involvement are the epiphyses and metaphyses of long tubular bones, primarily the proximal femur and proximal humerus (up to two thirds), although they can also arise in other locations [1, 9].

Cytogenetic studies have shown that clear cell chondrosarcomas have clonal abnormalities, including loss or structural aberrations of chromosome 9 and gain of chromosome 20 [10]. However, these tumours lack the IDH1/2 mutations that many conventional chondrosarcomas have [11].

Due to slow growth, symptoms may be mild and nonspecific. Histologically, clear cell chondrosarcomas show sheets of large oval cells with clear or granular eosinophilic cytoplasm, occasional giant cells, and both chondroid matrix and woven bone [1, 9]. The combination of the characteristic morphology and radiographic findings usually prompts the correct diagnosis. However, in the setting of metastatic disease, the use of ancillary immunostains to exclude other clear cell neoplasms such as metastatic melanoma and renal cell carcinoma may be necessary. In our case, S100 protein expression and the lack of melanocytic markers (Melan-A) and CD10 (positive in renal cell carcinoma) excluded those possibilities.

From a biological standpoint, clear cell chondrosarcoma are considered low-grade tumours, especially when compared with conventional chondrosarcomas (grades 2 and 3) [12]. Although local recurrence is fairly common [1, 8, 9], up to 15% of cases may metastasize [1, 9, 13]. Metastasis, when it occurs, usually develops after a long interval following surgery [5–7, 13], and therefore patients should be followed clinically and radiographically for many years. Our patient displayed an aggressive biological behaviour with local recurrence at 10 years and developed a metastasis 12 years after primary surgery, consistent with what is described in the literature [13], namely in the recent review of 42 cases performed by Nakayama et al. [14]. Because these tumours are rare, the prognostic factors related to disease-free survival [6] are unknown. Because metastases may develop many years following initial diagnosis, some patients thought to be cured have not been followed long-term and are lost to follow-up.

## Statement of Ethics

Published research complies with the guidelines for human studies and is in accordance with the World Medical Association Declaration of Helsinki. Written informed consent was obtained from the patient for publication of this case report and any accompanying images.

## Conflict of Interest Statement

The authors have no conflicts of interest to declare.

## Funding Sources

No funding was granted to this research.

### Author Contributions

R.C.O. and J.R. provided diagnosis. R.C.O. drafted the manuscript and collected data. J.C. supervised the work and revised the document.

### References

- 1 Jo VY, Fletcher CD. WHO classification of soft tissue tumours: an update based on the 2013 (4th) edition. *Pathology*. 2014 Feb;46(2):95–104.
- 2 Unni KK, Dahlin DC, Beabout JW, Sim FH. Chondrosarcoma: clear-cell variant. A report of sixteen cases. *J Bone Joint Surg Am*. 1976 Jul;58(5):676–83.
- 3 Guder WK, Harges J, Gosheger G, Nottrott M, Streibbürger A. Osteo- und Chondrosarkome des Beckens und der unteren Extremitäten. *Chirurg*. 2015 Oct 18;86(10):993–1004.
- 4 Present D, Bacchini P, Pignatti G, Picci P, Bertoni F, Campanacci M. Clear cell chondrosarcoma of bone. A report of 8 cases. *Skeletal Radiol*. 1991;20(3):187–91.
- 5 Bjornsson J, Unni KK, Dahlin DC, Beabout JW, Sim FH. Clear cell chondrosarcoma of bone. Observations in 47 cases. *Am J Surg Pathol*. 1984 Mar;8(3):223–30.
- 6 Itälä A, Leerapun T, Inwards C, Collins M, Scully SP. An institutional review of clear cell chondrosarcoma. *Clin Orthop Relat Res*. 2005 Nov;440:209–12.
- 7 Bagley L, Kneeland JB, Dalinka MK, Bullough P, Brooks J. Unusual behavior of clear cell chondrosarcoma. *Skeletal Radiol*. 1993;22(4):279–82.
- 8 Moura DL, Fonseca R, Freitas J, Figueiredo A, Casanova J. Reconstruction with iliac pedestal cup and proximal femur tumor prosthesis after wide resection of chondrosarcoma – 10-year follow-up results. *Revista Brasileira de Ortopedia (English Edition)*. 2017 Nov;52(6):748–54.
- 9 Deyrup AT, Siegal GP. *Practical orthopedic pathology: a diagnostic approach*. Elsevier, 2015.
- 10 Nishio J, Reith JD, Ogose A, Maale G, Neff JR, Bridge JA. Cytogenetic findings in clear cell chondrosarcoma. *Cancer Genet Cytogenet*. 2005 Oct 1;162(1):74–7.
- 11 Amary MF, Bacsi K, Maggiani F, Damato S, Halai D, Berisha F, et al. IDH1 and IDH2 mutations are frequent events in central chondrosarcoma and central and periosteal chondromas but not in other mesenchymal tumours. *J Pathol*. 2011 Jul;224(3):334–43.
- 12 Andreou D, Ruppin S, Fehlberg S, Pink D, Werner M, Tunn PU. Survival and prognostic factors in chondrosarcoma: results in 115 patients with long-term follow-up. *Acta Orthop*. 2011 Dec 9;82(6):749–55.
- 13 Klein A, Tauscher F, Birkenmaier C, Baur-Melnyk A, Knösel T, Jansson V, et al. Clear cell chondrosarcoma is an underestimated tumor: Report of 7 cases and meta-analysis of the literature. *J Bone Oncol*. 2019 Oct 31;19:100267.
- 14 Nakayama R, Hayakawa K, Kobayashi E, Endo M, Asano N, Yonemoto T, et al. What Factors Are Associated with Treatment Outcomes of Japanese Patients with Clear Cell Chondrosarcoma?, *Clin Orthop Relat Res*. 2020 Nov; 478(478):2537–47.