

STRIATOCAPSULAR INFARCTION; A SINGLE INSTITUTIONAL EXPERIENCE

Osama Shukir Muhammed Amin¹, Araz Aziz Abdullah², Amanj Xaznadar², Mohammad Shaikhani²

Department of neurology, Sulaimaniya general teaching hospital, Sulaimaniya city, Iraq¹

Department of medicine, Sulaimaniya general teaching hospital, Sulaimaniya city, Iraq²

Corresponding author: Osama Shukir Muhammed Amin, MD, MRCPI, MRCPS(Glasg), FCCP, FACP Sulaimaniya Post-Office, PO BOX 196. Sulaimaniya City, Iraq. Tel: 009647703515964. Fax: 0014133047585. E-mail: dr.osama.amin@gmail.com.

Original paper

SUMMARY

Objective: Striatocapsular infarction is an uncommon form of deep hemispheric strokes. We analyzed the clinical presentation of this stroke to determine its core features and neurological outcome. **Material and methods:** This prospective, observational, short-term longitudinal study was carried out from November 1, 2009 to October 30, 2011 in the department of neurology, Sulaimaniya general teaching hospital, Iraq and involved 13 consecutive Kurdish patients who were diagnosed with striatocapsular infarction radiologically; all patients underwent routine

blood tests, resting 12-lead ECG, transthoracic echocardiography, and urgent non-contrast CT brain scanning at the time of admission. All patients were reassessed clinically after 3 months. **Results:** Nine patients (69%) were females and 7 patients (53%) were older than 50 years of age. Infarction of the right lenticular nucleus was more common than the left one. Severe flaccid hemiplegia dominated the clinical presentation. Speech and language dysfunction were found in 4 patients (30%) while inattention and neglect were detected in 8 patients (61%). At 3 months, 4 patients were bed-ridden and 4 were wheel-chair bound; dystonia and involuntary movements

did not occur. Only the patient with bilateral infarction demonstrated Parkinsonism. **Conclusion:** Striatocapsular infarction in Iraqi Kurdish patients was more common in females and at the right lenticular nucleus. Hypertension, smoking, and hypercholesterolemia were the commonest risk factors. Dense hemiplegia was the commonest presentation; the functional outcome was poor in the majority. After 3 months of the ischemic event, involuntary movements and dystonia were not seen, and Parkinsonism was found in one patient only.

Key words: stroke, basal ganglia, striatocapsular infarction, middle cerebral artery.

1. INTRODUCTION

The human corpus striatum is composed of distinct nuclear masses; caudate nucleus, putamen, and globus pallidus. These structures are closely related to each other, anatomically and functionally, and are extensively connected to the cerebral cortex, diencephalon, and brainstem. Altogether, they carry out several crucial functions; control of movements (including saccadic eye ones), cognition, learning and memory, and speech and language (1, 2, 3). Therefore, lesions of the corpus striatum are expected to result in a multitude of neurological dysfunctions.

2. MATERIAL AND METHODS

From November 1, 2009 to October 30, 2011, 13 consecutive Kurdish patients with ischemic stroke were included in this prospective, observational, short-term longitudinal

study, which was conducted at the Sulaimaniya general teaching hospital's department of neurology. To be eligible for enrolment: patients should have developed a neurological deficit(s) that had persisted for more than 24 hours (4) and therefore, transient ischemic attacks were not included; the patients' non-contrast CT brain scanning should have demonstrated infarction of the corpus striatum (which appears as a comma-shaped hypodense area) and the length of these infarcts should be no less than 3 cm and their width be greater than 1 cm (this would exclude smaller, much more common, lacunar infarcts) (5); and patients should have no previous stroke (both, ischemic and hemorrhagic; clinically and radiologically). The presence of previous neurological deficits would have definitely interfered with our neurological assessment and follow-up. All patients

were interviewed and examined by neurologists and neurology trainees of our department.

All patients (n=13) underwent thorough medical and neurological examination by internists and neurologists, and underwent a battery of blood investigations and brain imaging.

The blood tests were done within 24 hours of admission, and included routine ones in addition to thrombophilia screen in 3 patients (who were younger than 45 years). A 12-lead ECG was done immediately on admission in all patients.

Carotid arterial and lower limbs' Doppler ultrasounds were performed in all cases (n=13) within 3 days of hospital admission while transthoracic echocardiography was done within 2 days; none of the patients underwent trans-esophageal echocardiographic assessment, however.

No.*	Age	Gender	Occupation	Marital status	Residence
1	71	F	Housewife	Married	Sulaimaniya
2	48	M	Employee	Married	Sulaimaniya
3	80	F	Housewife	Married	Sulaimaniya
4	60	F	Housewife	Married	Sulaimaniya
5	72	M	Retired	Married	Sulaimaniya
6	66	F	Housewife	Married	Sulaimaniya
7	68	F	Retired	Married	Sulaimaniya
8	49	M	Employee	Married	Sulaimaniya
9	65	M	Retired	Married	Sulaimaniya
10	2	F	NA	NA	Sulaimaniya
11	21	F	Employee	Engaged	Sulaimaniya
12	22	F	Housewife	Divorced	Sulaimaniya
13	45	F	Housewife	Married	Sulaimaniya

Table 1. Patient's characteristics (n=13). *Denotes patient's number. NA=not applicable. Housewife= never employed before.

The brain imaging was in the form of non-contrast CT brain scanning and was done within half an hour of the emergency unit admission; this scan was repeated after 24 hours in patients with initial negative imaging (n=4). Brain MRI/MRA (conventional 4-vessel cerebral angiography was/is not available in our center) was performed within 5 days in all patients to delineate the infarcted area and the cerebral vasculature. Brain MRV was done for one patient only (patient 12), searching for cerebral venous thrombosis.

The length of hospital stay ranged from 5 to 13 days with an average of 9 days. Patients were followed-up and re-examined clinically at 4-week intervals and on an outpatients' basis. At 3 months, we re-assessed consciousness, language, sensory/visual inattention, and facial and limb's motor weakness. No brain imaging was done at this point. All patients/guardians/caregivers agreed and signed an informed consent for participating in the study.

3. RESULTS

Tables 1 to 5 display the various results of our study. Of the 13 patients enrolled in the study, 7 patients (53%) were older than 50 years of age and 9 patients (66%) were females. Hypertension was the most common (53%) observed risk factor for stroke and was seconded only by smoking (46%) and hypercholesterolemia (46%); 3 patients (23%) had type 2 diabetes mellitus. All patients (100%) were right-handed.

LVH, left ventricular hypertrophy; MI, myocardial infarction; RT, right; LT, left; DF, diastolic dysfunction; MS, mitral stenosis; MR, mitral regurgitation; AR, aortic regurgitation; PHT, pulmonary hypertension; GP, glopus palidus.

The onset of weakness was sudden and maximum in 3 patients (25%) with gradual improvement over several days. Four patients (33%) noticed that they have weakness after awaking from sleep in the morning. The course of weakness was fluctuating but progressive and had reached its nadir in 1-4 days in 7 patients (58%). The relatives of the two comatose patients concentrated on the im-

paired consciousness and provided conflicting histories with regard to the weakness's onset and progression.

Two patients (15%) were brought to the emergency department comatose. Patient 1 developed progressive obtundation over 5 hours and finally went into coma; the family did not report an initial weakness but a caregiver said that the patient was unable to go to the bathroom after

Risk factor	Number*	(%)*
-Hypertension	7	53
-Diabetes	3	23
-Hypercholesterolemia	6	46
-Smoking	6	46
-Alcohol drinking	1	7
-Atrial fibrillation	2	15
-Valvular heart disease**	2	15
-Ischemic heart disease	4	30
-Congestive heart failure	1	7
-Body mass index > 30	2	15
-Sedentary life style	2	15
-Personal history of ischemic stroke or TIA	zero	Zero
-Family history of ischemic stroke	4	30

Table 2. Patients' ischemic stroke risk factors and their percentages (n=13). *Approximate percentage. **Severe mitral stenosis was found in 2 patients. TIA=transient ischemic attack.

No.*	Mode of presentation to the emergency department	Additional findings on examination at the time of admission
1	Progressive obtundation over 1 day; history of limb weakness was uncertain.	Deep coma; no response to verbal or painful physical stimuli
2	Grade 1 right-sided weakness and slow slurred speech; stuttering course over 1 day	Dysarthria; moderate right facial weakness; right sensory neglect
3	Grade zero right-sided weakness and inability to speak; noticed upon awaking from sleep and steadily progressed over few hours	Severe expressive dysphasia; moderate facial weakness; right inattention (visual and sensory)
4	Grade 2 right-sided weakness; stuttering course over 2 days	Normal speech and language function; moderate facial weakness; no neglect or inattention
5	Grade 1 left-sided weakness, sleep onset; progressive over 1 day	Dysarthria; moderate facial weakness; right inattention (visual and sensory);
6	Grade 1 left-sided weakness; sudden onset; progressive over few hours	Normal speech; moderate facial weakness; left sensory inattention
7	Grade 1 left-sided weakness; sudden onset, fluctuated course over 2 days	Normal speech; moderate facial weakness; left sensory neglect
8	Grade zero right-sided weakness; noticed upon awaking from sleep	Global dysphasia; severe facial weakness
9	Grade 1 left-sided weakness; stuttering course over 1 day	Severe facial weakness; left visual and sensory neglect
10	Grade 3 left-sided weakness; progressive over 3 days	Mild facial weakness; cortical signs assessment was not applicable; the patient was 1 year and 8 months old
11	Grade 3 left-sided weakness and facial asymmetry over few hours; sudden onset	Normal speech and language; left sensory and visual neglects; mild facial weakness
12	Progressive impairment in consciousness and then coma	Deep coma; no response to external stimuli; bilateral extensor planters
13	Grade zero flaccid left-sided weakness	Severe facial weakness; normal language and speech; no neglect or inattention

Table 3. Various patients' modes of neurological deficits and their findings at the time of hospitalization (n=13). *Denotes patient's number.

No.*	ECG	Carotid Doppler	Echocardiography	CT brain scanning
1	LVH, frequent VPC	46%(RT), 51%(LT) stenosis	Concentric LVH, moderate DF	Left putamen, GP, and head of caudate
2	Normal	Normal	Normal	Left putamen and GP
3	LVH, old inferior MI	62%(RT), 34%(LT) stenosis	Concentric LVH, mild DF	Left putamen, GP, and head of caudate
4	AF, RVH, RAD,	Normal	Severe MS, mild MR, moderate AR, Severe PHT	Left putamen, GP, and head of caudate
5	Non-specific ST-T changes	74%(RT), 92%(LT) stenosis	Mild DF	Right putamen and GP
6	Anterioseptal T inversion	73%(RT), 84%(LT) stenosis	Mild DF	Right putamen and GP
7	LVH, V ₁₋₆ T inversion	30%(RT), 33%(LT) stenosis	Concentric LVH, moderate DF	Right putamen, GP, and head of caudate
8	Apical T inversion	43%(RT), 27%(LT) stenosis	Concentric LVH, severe DF	Left putamen, GP, and head of caudate
9	Lateral-apical ST depression and T inversion	34%(RT), 41%(LT)		Right putamen, GP, and head of caudate
10	Normal	Normal	Normal	Right putamen, GP
11	Normal	Normal	Normal	Right putamen, GP, and head of caudate
12	Normal	Normal	Normal	Both sides; lenticular nuclei and caudate heads
13	AF, RVH, RAD	Normal	Severe MS, Moderate MR, Mild AR, Severe PHT	Right putamen and GP

Table 4. Patients' work-up of 12-lead resting ECG, carotid Doppler ultrasound, transthoracic echocardiography, and non-contrast CT brain scanning (n=13). *Denotes patient's number.

awaking from sleep in the morning (which might well suggest a severe form of weakness). Patient 12 developed sudden drowsiness and the family reported that the patient's consciousness deteriorated rapidly over few hours and became comatose within 1 day; the family had not noticed any weakness.

Apart from the two patients who were brought to the emergency department with coma, unilateral facial weakness was present in the remaining 11 patients (91%), ranging from mild to severe degrees. Dense hemiparesis (grades zero to 2) was found in 9 patients (69%) at the time of admission while only 2 patients (15%) demonstrated a moderate weakness. Two patients were in a deep coma and their 4 limbs were flaccid.

The speech was slurred and slow in two patients (15%) patients while another patient (7%) showed severe expressive dysphasia and a further one (7%) had a global form of dysphasia. All of those patients (n=4) were right-handed and the infarction involved the left corpus striatum in 3 patient; the right side was

infarcted in patient 5, who was dysarthric.

Testing for neglect (visual and sensory) was not done in 4 patients (30%) (a young child; 2 comatose patients; and a globally dysphasic pa-

tient). Of the remaining 9 (69%) patients, a hemi-neglect was found in 8 patients.

Seven patients (53%) had infarction of the right corpus striatum and one patient (7%) presented with bilateral involvement; the remaining (n=5; 38%) had left-sided infarction. Involvement of the caudate's head was observed in 8 patients (61%); 3 were on the right, 4 were on the left, and both sides were infarcted simultaneously in one patient. The adjacent thalamus and overlying cortex were not involved in all cases.

Transthoracic echocardiography was entirely normal in 4 patients (30%); all of them were young and were neither hypertensive nor diabetic. Concentric left ventricular hypertrophy with diastolic dysfunction (mild to severe) was detected in 4 patients (30%). Two patients (15%) had severe mitral stenosis, pulmonary hypertension, and atrial fibrillation. Two patients displayed mild diastolic dysfunction only; both were hypertensive. Lower limbs' Doppler studies were unremarkable in all patients (100%). Normal flow and caliber were found on carotid Doppler study in 6 patients (46%); five patients demonstrated bilateral stenosis of less than 70%; and two patients only (15%) had bi-

No.*	Deficits	Functional status
1	Grade 1 right flaccid weakness in the arm and spastic grade 3 in the leg; mild facial weakness; severe expressive dysphasia	Bed-ridden; dependent
2	Grade 1 right flaccid weakness in the arm and spastic grade 4 in the leg; complete facial recovery; no neglect	Mild slurring of speech; useless arm; can walk with a crutch
3	Grade 2 flaccid arm and grade 3 flaccid leg weakness; mild facial weakness; mild expressive dysphasia	Wheel-chair bound; dependent
4	Grade 2 flaccid arm and leg weakness; mild facial weakness	Wheel-chair bound; dependent
5	Grade 1 flaccid arm and grade 3 flaccid leg weakness; near total facial recovery; mild dysarthria with nasal voice quality	Wheel-chair bound; dependent
6	Grade 2 flaccid arm and grade 3 leg weakness; mild facial weakness	Wheel-chair bound; dependent
7	Grade 3 flaccid arm and grade 4(minus) leg weakness; mild facial weakness	Returned to pre-stroke life activities; needed some assistance]
8	Grade 1 flaccid arm and leg weakness; global aphasia; severe facial weakness	Bed-ridden; dependent
9	Grade 3 flaccid arm and grade 4 spastic leg weakness; near total facial recovery	Returned to everyday life activities; needs some assistance
10	Grade 4 arm and leg weakness; complete facial recovery	Needed assistance with certain activities as the patient is a young child
11	Grade 4 arm and leg weakness; near total facial recovery	Returned to pre-stroke; independent
12	Moderate Parkinsonism and severe expressive dysphasia	Bed-ridden; dependent
13	Grade 1 flaccid arm and grade 2 leg weakness	Bed-ridden; dependent

Table 5. Clinical findings after 3 months of follow-up (n=13). *Denotes patient's number.

lateral stenosis of greater than 70%. Brain MRA in 5 patients (Figure 2) revealed an occlusion at the origin/main stem of the culprit middle cerebral artery and occlusion of the internal carotid T junction in 3 patients; the intracranial arteries were patent in the remaining (n=5).

At 3 months of follow-up, 4 patients were bed-ridden, couldn't sit, and were totally dependent on their care givers; 4 patients were wheelchair-bound but they were also dependents on a caregiver. Three patients showed a favorable improvement in their weakness but they needed some assistance to perform their everyday life activities (eating, dressing, toileting, etc.); the young child was able to stand and walk independent; and one patient (patient 11; a 21-year-old female) was totally independent and showed a remarkable degree of functional improvement and return to every day pre-stroke activities.

As for the speech and language dysfunction, dysarthria (n=2) improved remarkably; the patient with severe dysphasia remained as such and she was able to utter few sounds only; the globally dysphasic patient did not improve at all. However, the 2 comatose patients, upon recovery, demonstrated severe expressive dysphasia. None of the patients died during the follow-up period and none of them developed another cerebrovascular ischemic event. Apart from patient 12 (bilateral infarctions), who developed severe Parkinsonism, neither dystonia nor involuntary movements developed in the remaining patients (n=12).

4. DISCUSSION

During the past century, the Canadian neurologist C.M. Fisher published several landmark papers describing and characterizing ischemic lacunar strokes (6, 7, 8, 9, 10, 11, 12). In 1982, his work had extended and greatly expanded our knowledge of these brain lacunar infarctions (13). According to Fisher (13) and Mohr (14), occlusion of small penetrating arteries by hypertensive lipohyalinosis results in small lacunes of 3 to 20 mm in maximum diameter, deep in the brain parenchy-

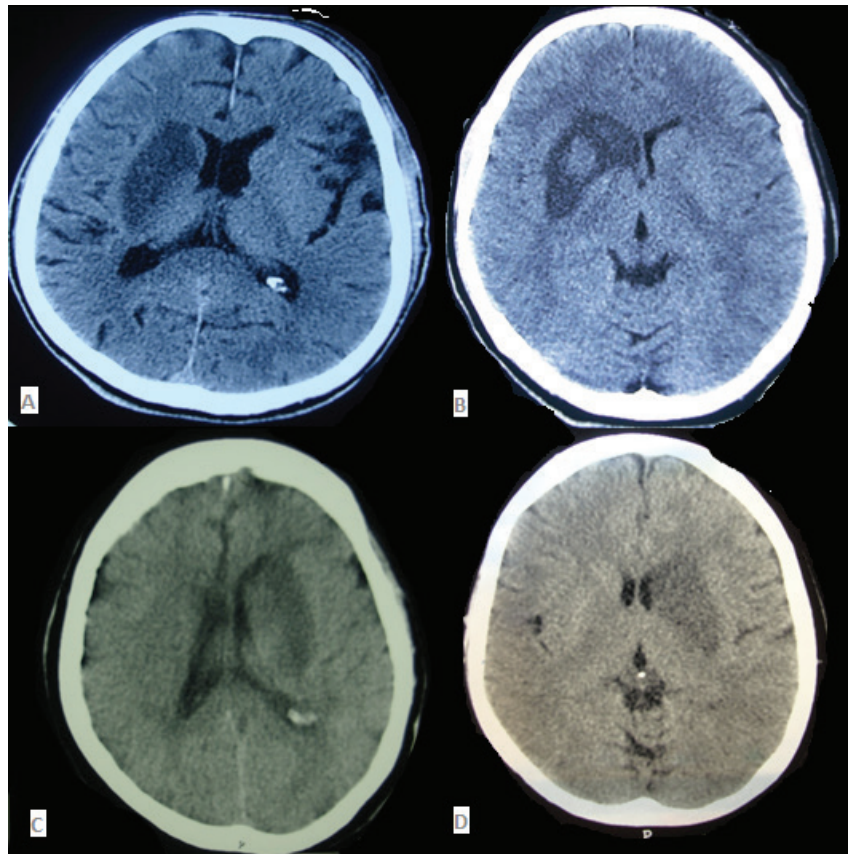


Figure 1: Non-contrast CT brain scans of our patients. (A) A 72-year-old retired male who was hypertensive, hyperlipidemic, and smoker. He presented with dense left-sided weakness and moderate facial weakness. He demonstrated normal language and speech but had left sensory inattention (patient 6). (B) An otherwise completely healthy 21-year-old single female presented with moderate left-sided weakness. She improved gradually over few weeks to a remarkable degree and returned to her pre-stroke activities. Her work-up did not uncover any cause behind this stroke (patient 11). (C) A 69-year-old female was referred to us in a coma state because of "a brain tumor and its massive surrounding edema." She developed progressive obtundation over few hours but a history of lateralized weakness was not clear. Upon recovery, she demonstrated severe expressive dysphasia (patient 1). (D) A 60-year-old woman with a history of severe mitral stenosis, atrial fibrillation, and pulmonary hypertension, presented with sudden dense right-sided weakness and slurred speech (patient 4). None of the aforementioned patients developed dystonia, involuntary movements, or Parkinsonism during a period of 3 months of follow-up. Note that the caudate is infarcted in all but patient 6 and that hemorrhagic transformation developed in patient 11.

ma. However, ischemic lesions larger than 20 mm in maximum diameter were not considered lacunes by Fisher, who used the term capsular infarcts instead (15). The human basal ganglia are supplied principally by the lenticulostriate arteries. These arteries arise from the circle of Willis and the proximal stems of the middle and anterior cerebral arteries (16). Generally they are divided into medial (having a lumen of 100-200 μ) and lateral (with a lumen of 200-400 μ) groups (15). The putamen, parts of the globus pallidus, body of caudate, claustrum, and anterior and posterior limbs of internal capsules are nourished by the lateral lenticulostriate arteries which stem of the posterior and superior aspect of the main stem of the middle cerebral artery (some minor

contribution comes from Heubner's artery and anterior choroidal arteries) (17). When these arteries are obstructed altogether, they result in the so-called striatocapsular infarction (SCI) which has been defined as a comma-shaped softening in the area of the basal ganglia of at least 3 cm in length and 1 cm in width (5). Therefore, when the aforementioned arteries are blocked, there should be no infarction of the overlying cortical areas. However, several patients with SCI demonstrate a multitude of cortical signs (dysphasia, neglect, etc.), although the maximum ischemia is found at the depth of the hemisphere. Therefore, Bladin and Berkovic suggested that there is an additional comprise of the cortical blood supply in those patients (Figure 1).

After a thorough analysis of risk factors and angiographic findings, Donann and coworkers (18) identified 4 pathophysiologic subgroups of this form of ischemic stroke: cardiac emboli to the origin of the middle cerebral artery; severe extra-cranial cranial carotid artery occlusive disease with presumed embolism to the same site and/or involvement of hemodynamic factors; proximal middle cerebral artery abnormalities causing occlusion of multiple lateral striate arteries at their origins; and normal angiography where pathogenesis was uncertain.

Furthermore, Bladin and Berkovic (5) found that when the origin of the middle cerebral artery/carotid T junction is blocked, the irrigation of the pertinent cortical areas is relatively maintained via transcortical and transdural vascular anastomoses, and that cortical signs are not found in all cases. Accordingly, Jung and colleagues (19) suggested that it is better to subcategorize those patients into cortical and non-cortical SCI. Weiller and coworkers (20) found that "persistent" occlusion of the middle cerebral arteries and a decrease of cortical regional cerebral blood flow were only found in patients with dysphasia or neglect. All patients without dysphasia or neglect showed a rapid recanalization of the middle cerebral artery occlusion or a stenosis of the M1 segment and no cortical regional cerebral blood flow decrease. Seven of our patients (54%) had occlusion of the origin the culprit middle cerebral arteries (Figure 2).

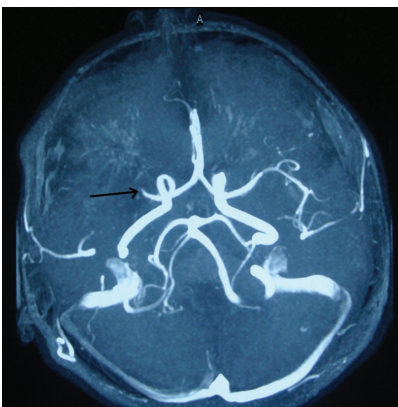


Figure 2. Brain MRA of patient 11, who was a 21-year-old female with a negative work-up for stroke. Note that the right middle cerebral artery disappears shortly beyond its origin (black arrow).

We reviewed our Stroke Registry and found that from November 1, 2009 to October 30, 2011, a total of 761 ischemic stroke patients were admitted to our neurology department at the Sulaimaniya General Teaching Hospital. We have not reviewed the diagnosis of these strokes, whether they were done clinically and/or radiologically. We have collected 13 cases during this period. Accordingly, SCI constitutes 0.01% of these cases. Russmann and colleagues (21) had found that acute infarction limited to the lenticular nucleus comprised 1.6% of all deep hemispheric ischemic strokes. On the other hand, Bladin and Berkovic (5) evaluated 1600 stroke patients between July 1977 to June 1983 and they diagnosed SCI in 11 patients only; however, the authors thought that this very low frequency might be attributed to the lower quality of CT scan machines at that time.

In our series, hypertension (53%), smoking (46%), and hypercholesterolemia (46%) were the commonest encountered risk factors; diabetes was found in 23% (3 patients) only. Atrial fibrillation was found 2 (15%) of patients; both were females and had severe mitral stenosis and pulmonary hypertension (Table 2). Deep hemispheric lacunar infarcts principally result from occlusion of a single penetrating lenticulostriate artery. According to Bejot *et al.* (22) and Jackson *et al.* (23), the commonest risk factors for this type of stroke are hypertension, smoking, and diabetes which result in micro-stenosis and lipohyalinosis of small penetrating lenticulostriate arteries; in addition, micro-embolism from the heart or great vessels also contribute, but to a much lesser degree. On the other hand, Nicolai and coworkers (24) concluded that the clinical risk factors for striatocapsular infarctions are similar to cortical infarctions but they are significantly different from the lacunar ones. Our patients' risk factors seem to comply with the aforementioned series.

Two patients (patient 1 and 12) were comatose when they already arrived into the emergency room. Their families did not give a clear

history of preceding weakness, but a state of progressive obtundation developed in both and ended into coma within 1 day. We believe that the infarction was large in patient 1 and exerted a pressure on the underlying brainstem while in patient 2, both basal ganglia were infarcted simultaneously (bi-hemispheric dysfunction and upper brainstem compression explain her coma). None of the other 11 patients showed any degree of clouding of consciousness. Two (out of 11) patients in Bladin and Berkovic series (5) were slightly drowsy on admission; none of their patients were comatose.

On admission, two patients were dysarthric while one patient demonstrated severe expressive dysphasia and one had a global form of dysphasia. In addition, patient 1 demonstrated severe expressive dysphasia on recovery. All of them were right-handed. Mega and Alexander (25) concluded that this subcortical dysarthria results from damage to the left putamen or to the descending corticobulbar pathways in either the para-ventricular white matter or in the genu of internal capsule of the left hemisphere. Patient 5 had infarction of the right putamen and he was right-handed. This patient might actually have hypophonia and hypokinesia of speech (with delayed speech initiation) resulting from this putamenal damage (25). Nadeau and Crosson (26) found that subcortical dysphasia resulting from large SCI is due to persistent hypoperfusion of the overlying cortex that is not visible on conventional imaging studies. According to Mega and Alexander (25), the core profile of this subcortical dysphasia is an impairment of generative language ability, accompanied by lexical selection anomia of varying severity. The generative - language problem produces an abnormality on verbal fluency tasks, deficient sentence generation with increased latencies, perseverations, and occasional bizarre content despite a generally grammatical and fluent conversational or responsive language output. They also proposed that the severity of the language profile reflects the extent of damage to the

frontostriatal system. On the other hand, Bhatia and Marsden (27) suggested that abulia is the commonest behavioral abnormality in patients with focal basal ganglia lesions, which might easily be considered a dysphasic component of the symptomatology.

Most patients presented with dense hemiparesis. In all patients, the arm weakness was more severe than the leg's one. Upon recovery, the same "ratio" had persisted. Moderate-severe upper motor neuron facial weakness was encountered in the majority. However, only 2 patients (a young child and a 21-year-old female, respectively) presented with moderate arm and leg weakness as well as mild facial weakness; their recovery was remarkable after 3 months. This pattern of faciobrachiorural paresis (which is more severe in the arm than in the face or leg) is thought to result from internal capsular ischemic lesions rather than the adjacent basal ganglia structures (21). However, this "highly characteristic pattern" was not considered by Bladin and Berkovic to distinguish SCI from other type of ischemic strokes (5). One should note that the speech disturbance of SCI rarely presents itself as severe dysarthria but with mild arm weakness (18).

Testing for neglect (sensory and visual) was inapplicable in 4 patients (comatose patients, the globally aphasic patient, and the young child). In all other patients (except patient 4), some degree of impairment was found, however, and all of them improved gradually, but minimally, during the following 12 weeks. Patient 4 demonstrated normal speech and language function as well as no neglect. Again, this cortical sign results from poor hypoperfusion of the overlying cortex. Hemi-neglect (particularly the visual one) was found to be present in 20-80% of strokes, regardless of the damaged side and its importance lies in the impact on the long-term recovery; it has a negative effect on functional ability and rehabilitation (28, 29, 30, 31).

Bhatia (27), Marsden (32), and Giroud (33) found that hemi-dystonia

is the commonest acute, subacute, and delayed aftermath of lenticular damage. However, Russmann and colleagues (21) noticed that none of their 13 patients with pure lenticular infarctions developed any form of movements disorder, an observation that is consistent with ours. However, only patient 12 (with the bilateral simultaneous infarctions) developed Parkinsonism upon recovery, which is an expected sequela in such bilateral basal ganglia damage (34). Her speech and language function testing, however, was suggestive of severe expressive dysphasia rather than abulia or dysarthria. She did not develop dystonia.

In terms of return to pre-stroke activities and the long-term outlook, the prognosis was poor in the majority. The prominent arm weakness combined with some degree of hemi-neglect affected patients' rehabilitation. Only patient 10 and 11 demonstrated a remarkable degree of improvement in terms of weakness, self-dependence, and ambulation. None of the patients died during the follow-up period and none of them developed another stroke or a cardiac ischemic event.

5. CONCLUSION

Striatocapsular infarction is a specific form of deep hemispheric cerebral infarction in the territory of middle cerebral artery that result in a complex constellation of subcortical and cortical signs and symptoms. In our series, it comprised 0.01% of all stroke cases admitted to our hospital within a 2-year period. The right lenticular nucleus was the target in most patients and females outnumbered males. Most of our patients were hypertensive, hyperlipidemic, and smokers; diabetes was uncommon. Dense hemiplegia was the most common presenting feature and hemi-neglect was found in the majority. The prognosis was gloomy in most patients. Dystonia and involuntary movements were not encountered after 3 months of follow-up.

Limitations of the study

1. This is a single institutional study that does not reflect the practice of stroke in the whole of Iraq.

In addition, there were no previous published papers addressing Iraqi patients with respect to the same subject to compare with. If other institutions were also involved in the study, the results might well have been different.

2. The target population of the study was residents of Sulaimaniya city. All were Kurdish; an ethnic minority that constitutes about 15-20% of the Iraqi people. It is possible that the findings might have been different if patients from other ethnic groups (such as Arabs who constitute the majority of the Iraqi people) had been enrolled in the study.

Acknowledgments

Many thanks go to our patients and their families; without their kind cooperation, this study would have not been accomplished. I'm very thankful to the medical and paramedical staff of our neurology, radiology, laboratory, and registry departments; their help and contribution were very invaluable. A special gratitude goes to Professor Jafri Malin Abdullah FACS FRCS (Edin), dead of neurology department, University Sains Malaysia for his very useful comments and notes after he had read the manuscript.

Conflict of interest: none declared.

REFERENCES

1. Chakravarthy VS, Joseph D, Bapi RS. What do the basal ganglia do? A modeling perspective. *Biol Cybern.* 2010; 103(3): 237-253.
2. Stocco A, Lebiere C, Anderson JR. Conditional routing of information to the cortex: a model of the basal ganglia's role in cognitive coordination. *Psychol Rev.* 2010; 117(2): 541-574.
3. Hikosaka O, Takikawa Y, Kawagoe R. Role of the basal ganglia in the control of purposive saccadic eye movements. *Physiol Rev.* 2000; 80(3): 953-978.
4. Adams HP Jr, del Zoppo G, Alberts MJ, Bhatt DL, Brass L, Furlan A, et al. Guidelines for the early management of adults with ischemic stroke: a guideline from the American Heart Association/American Stroke Association Stroke Council, Clinical Cardiology Council, Cardiovascular Ra-

- diology and Intervention Council, and the Atherosclerotic Peripheral Vascular Disease and Quality of Care Outcomes in Research Interdisciplinary Working Groups: the American Academy of Neurology affirms the value of this guideline as an educational tool for neurologists. *Stroke*. 2007; 38(5): 1655-1711.
5. Bladin PF, Berkovic SF. Striatocapsular infarction: large infarcts in the lenticulostriate arterial territory. *Neurology*. 1984; 34(11): 1423-1430.
 6. Fisher CM, Curry HB. Pure motor hemiplegia of vascular origin. *Arch Neurol*. 1965; 13: 30-44.
 7. Fisher CM. Lacunes: small, deep cerebral infarcts. *Neurology*. 1965; 15: 774-784.
 8. Fisher CM. The arterial lesions underlying lacunes. *Acta Neuropathol*. 1965; 12(1): 1-15.
 9. Fisher CM, Cole M. Homolateral ataxia and crural paresis; A vascular syndrome. *J Neurol Neurosurg Psychiatry*. 1965; 28(1): 48-55.
 10. Fisher CM. Pure sensory stroke involving face, arm, and leg. *Neurology*. 1965; 15: 76-80.
 11. Fisher CM. A lacunar stroke: The dysarthria-clumsy hand syndrome. *Neurology*. 1967; 17: 614-617.
 12. Fisher CM. Thalamic pure sensory stroke: A pathologic study. *Neurology*. 1978; 28: 1141-1144.
 13. Fisher CM. Lacunar strokes and infarcts: a review. *Neurology*. 1982; 32(8): 871-876.
 14. Mohr JP. Progress in cerebrovascular disease; lacunes. *Stroke*. 1982; 13(1): 3-11.
 15. Fisher CM. Capsular infarcts: The underlying vascular lesions. *Arch Neurol*. 1979; 36: 65-73.
 16. Mohr JP. Lacunes. *Stroke*. 1982; 13(1): 3-11.
 17. Amin OSM, Zangana HM, Ameen NA. The striatocapsular infarction and its aftermaths. *BMJ Case Reports*. 2010; 10: 1136/bcr.02.2010.2703.
 18. Donnan GA, Bladin PF, Berkovic SF, Longley WA, Saling MM. The stroke syndrome of striatocapsular infarction. *Brain*. 1991; 114(Pt 1A): 51-70.
 19. Jung S, Hwang SH, Lee BC. Distinct clinical expressions of striatocapsular infarction according to cortical manifestations. *Eur J Neurol*. 2004; 11(9): 627-633.
 20. Weiller C, Ringelstein EB, Reiche W, Thron A, Buell U. The large striatocapsular infarct. A clinical and pathophysiological entity. *Arch Neurol*. 1990; 47(10): 1085-1091.
 21. Russmann H, Vingerhoets F, Ghika J, Maeder P, Bogousslavsky J. Acute infarction limited to the lenticular nucleus: clinical, etiologic, and topographic features. *Arch Neurol*. 2003; 60(3): 351-355.
 22. Bejot Y, Catteau A, Caillier M, Rouaud O, Durier J, Marie C, et al. Trends in incidence, risk factors, and survival in symptomatic lacunar stroke in Dijon, France, from 1989 to 2006: a population-based study. *Stroke*. 2008; 39(7): 1945-1951.
 23. Jackson C, Sudlow C. Are lacunar strokes really different? A systematic review of differences in risk factor profiles between lacunar and nonlacunar infarcts. *Stroke*. 2005; 36(4): 891-901.
 24. Nicolai A, Lazzarino LG, Biasutti E. Large striatocapsular infarcts: clinical features and risk factors. *J Neurol*. 1996; 243(1): 44-450.
 25. Mega MS, Alexander MP. Subcortical aphasia: the core profile of capsulostriatal infarction. *Neurology*. 1994; 44(10): 1824-1829.
 26. Nadeau SE, Crosson B. Subcortical aphasia. *Brain Lang*. 1997; 58(3): 355-402; discussion: 418-23.
 27. Bhatia KP, Marsden CD. The behavioural and motor consequences of focal lesions of the basal ganglia in man. *Brain*. 1994; 117(Pt 4): 859-876.
 28. Edmans JA, Lincoln NB. The frequency of perceptual deficits after stroke. *Clin Rehabil*. 1987; 1: 273-281.
 29. Stone SP, Halligan PW, Greenwood RJ. The incidence of neglect phenomenon and related disorders in patients with an acute right or left hemispherical stroke. *Age Ageing*. 1993; 22: 46-52.
 30. Kalra L, Perez I, Gupta S, Wittink M. The influence of visual neglect on stroke rehabilitation. *Stroke*. 1997; 28(7): 1386-1391.
 31. Ween JE, Alexander MP, D'Esposito M, Roberts M. Factors predictive of stroke outcome in a rehabilitation setting. *Neurology*. 1996; 47(2): 388-392.
 32. Marsden CD, Obeso JA, Zarranz JJ, Lang AE. The anatomical basis of symptomatic hemidystonia. *Brain*. 1985; 108(Pt 2): 463-483.
 33. Giroud M, Lemesle M, Madinier G, Billiar T, Dumas R. Unilateral lenticular infarcts: radiological and clinical syndromes, aetiology, and prognosis. *J Neurol Neurosurg Psychiatry*. 1997; 63(5): 611-615.
 34. Amin OSM, Shwani SS, Zangana HM, Ameen NA. Bilateral infarction of corpus striatum in a young woman: a case report and review of the literature. *J Med Case Reports*. 2011; 5: 324.