



## There is no intraocular affection on a SARS-CoV-2 - Infected ocular surface

Peer Lauermann<sup>a,\*</sup>, Marcus Storch<sup>a</sup>, Michael Weig<sup>b</sup>, Björn Tampe<sup>d</sup>, Martin Winkler<sup>e</sup>,  
Hans Hoerauf<sup>a</sup>, Nicolas Feltgen<sup>a</sup>, Samy Hakroush<sup>c</sup>

<sup>a</sup> University Medical Center Goettingen, Department of Ophthalmology, Germany

<sup>b</sup> University Medical Center Goettingen, Institute for Medical Microbiology, Germany

<sup>c</sup> University Medical Center Goettingen, Institute for Pathology, Germany

<sup>d</sup> University Medical Center Goettingen, Department of Nephrology, Germany

<sup>e</sup> University Medical Center Goettingen, Department of Anesthesiology, Germany

### ARTICLE INFO

#### Keywords:

SARS-CoV-2

Covid-19

Ocular surgery

Infectious diseases

### ABSTRACT

**Purpose:** The presence of SARS-CoV-2 RNA in anterior chamber fluid and/or the vitreous in patients with SARS-CoV-2 RNA on the ocular surface is unclear. Knowledge about the infectious state of intraocular structures could influence the daily work of ophthalmic surgeons.

**Observations:** We analyzed ocular samples from a patient who had succumbed to COVID-19 pneumonia for the prevalence of SARS-CoV-2 RNA. We detected viral RNA in the ocular-surface samples on one swab and in one excidate from the conjunctiva. Samples from the anterior chamber and vitreous revealed no SARS-CoV-2 RNA.

**Conclusions:** SARS-CoV-2 can effectively be inactivated with standard disinfection agents. The now proven absence of SARS-CoV-2 in intraocular fluids could influence how ophthalmic surgeons work. Without having to account for the risk of a contagion via the anterior chamber and/or vitreous body, the surgical staff would require no additional, more elaborate protection.

### 1. Introduction

Since the outbreak of the novel coronavirus (SARS-CoV-2), the ocular surface has been suggested as a potential infection zone.<sup>1–4</sup> Whether the virus is also detectable in deeper eye tissues is not yet known. However, knowledge thereof could be particularly important for ophthalmic surgeons, since aqueous and vitreous fluid could act as an infectious medium while intraocular instruments are being changed, and aerosols particles containing SARS-CoV-2 could be dispersed. The lack of knowledge about SARS-CoV-2 RNA is present in the eye's deeper compartments has already led to different protective recommendations. Various professional associations have suggested wearing filtering face-piece (FFP) 3 masks and protective eye wear during surgical procedures like vitrectomies to account for possible aerosol production.<sup>5,6</sup> Below, we report on the ocular findings from a 72-year-old patient who died of CoVid-19 pneumonia.

#### 1.1. Medical history

On April 28, 2020, a 72-year-old female patient - already intubated

and ventilated - was transferred from an external hospital to the intensive care unit at the University Medical Center Goettingen. She died the following day of severe septic shock and multiple organ failure due to CoVid-19 pneumonia. There was no documentation of eye involvement in her medical records.

### 2. Material and methods

A few hours after death, samples of various eye tissues were removed from the left eye during autopsy: a conjunctival swab, two conjunctival excidates, one anterior chamber fluid sample and one vitreous sample (1 ml each). The conjunctival swab was taken with a *Copan Liquid Amies Elution Swab* (eswab™, COPAN Diagnostics, CA, USA). One conjunctival excidate was carried in a container with 0.9% saline solution, the other conjunctival excidate was fixed in glutaraldehyde. All but the sample with glutaraldehyde were tested for the presence of SARS-CoV-2 viral RNA using the Genesig COVID-19 *in vitro* Real-Time diagnostic PCR assay (Primerdesign Ltd, Chandlers Ford, UK). The sample fixed in glutaraldehyde was analyzed under an electron microscope.

\* Corresponding author. Robert-Koch-Straße 40, 37075, Göttingen, Germany.

E-mail address: [peer.lauermann@med.uni-goettingen.de](mailto:peer.lauermann@med.uni-goettingen.de) (P. Lauermann).

<https://doi.org/10.1016/j.ajoc.2020.100884>

Received 9 June 2020; Received in revised form 3 August 2020; Accepted 16 August 2020

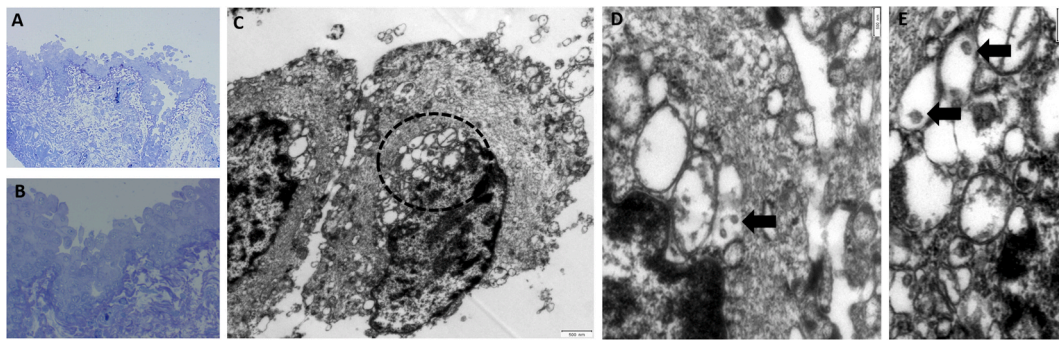
Available online 20 August 2020

2451-9936/© 2020 The Authors.

Published by Elsevier Inc.

This is an open access article under the CC BY-NC-ND license

(<http://creativecommons.org/licenses/by-nc-nd/4.0/>).



**Fig. 1.** (A,B) Conjunctival epithelium. Epithelial cells appear to be swollen and are focally detaching (Semithin Section). (C) Two swollen epithelial cells. Note the swollen bleb-like organelles adjacent to the nucleus (dotted line, TEM) (D,E). Higher Magnification reveals single virus-like particles (size: diameter 100-150 nm) within vesicles (arrows, TEM).

### 3. Results

PCR-analysis revealed SARS-CoV-2 RNA in the conjunctival swab and conjunctival excidate. Samples from the aqueous and vitreous revealed no definitive RNA. The histological, electron microscopic analysis revealed virus – like components in the conjunctival excidate (Fig. 1).

Higher Magnification reveals single virus-like particles within vesicles (arrows, TEM).

### 4. Discussion

In their letter published recently, Lu et al. already suspected that a SARS-CoV-2 infection could occur through the ocular surface.<sup>3</sup> They based their assumption on reports from Guangfa Wang, an expert on the national pneumonia committee who had become infected during an inspection in Wuhan wearing an N95 mask but no eye protection.<sup>3</sup> As angiotensin-converting enzyme 2 (ACE2) and transmembrane serine protease 2 (TMPRSS2) are the key proteins enabling SARS-CoV-2's entry into host cells,<sup>7</sup> Zhang et al. analyzed several ocular tissues of 30 mice for the prevalence of the aforementioned proteins. The largest number was identified in the conjunctiva, leading them to conclude that it might act as a target issue for SARS-CoV-2 infection.<sup>4</sup> Xie et al. analyzed the conjunctival swabs from 33 COVID-19 patients for SARS-CoV-2 positive PCR results. None of the patients in the study presented ocular symptoms, but viral RNA was detected in 2 of them.<sup>1</sup> These findings concur with our results, as we also demonstrated SARS-CoV-2 RNA in the conjunctiva. Moreover, we have shown that our patient's intraocular fluids were not infected despite the ocular surface's proven infection. In addition to the fact that standard disinfection agents suffice to inactivate SARS-CoV-2<sup>8</sup>, this information could affect how ophthalmic surgeons work. Without having to account for the risk of contagion via the anterior chamber and/or vitreous body, the surgical staff would require no additional, more elaborate protection. Regarding the histological analysis, electron microscopic imaging revealed virus - like components in the conjunctival excidate comparable to the SARS- CoV virus particles described by Goldsmith et al.<sup>9</sup> in 2004, but in a much smaller number. Further pathological analyses will be necessary to support the results reported here.

### Patient consent

Written consent to publish this case has not been obtained. This report does not contain any personal identifying information.

### Funding

We acknowledge support by the Open Access Publication Funds of the Göttingen University.

### Authorship

All authors attest that they meet the current ICMJE criteria for Authorship.

### Acknowledgements

None.

### References

- Xie H-T, Jiang S-Y, Xu K-K, et al. SARS-CoV-2 in the ocular surface of COVID-19 patients. *Eye Vis (Lond)*. 2020;7:23. <https://doi.org/10.1186/s40662-020-00189-0>.
- Napoli PE, Nioi M, d'Aloja E, Fossarello M. The ocular surface and the coronavirus disease 2019: does a dual 'ocular route' exist? *J Clin Med*. 2020;9(5). <https://doi.org/10.3390/jcm9051269>.
- Lu C-w, Liu X-f, Jia Z-f. SARS-CoV-2 transmission through the ocular surface must not be ignored. *Lancet*. 2020;395(10224):e39. [https://doi.org/10.1016/S0140-6736\(20\)30313-5](https://doi.org/10.1016/S0140-6736(20)30313-5).
- Zhang BN, Wang Q, Liu T, et al. Expression analysis of SARS-CoV-2 related ACE2 and TMPRSS2 in eye tissues. *Zhonghua Yan Ke Za Zhi*. 2020;56:E011. <https://doi.org/10.3760/cma.j.cn112142-20200310-00170>, 0.
- Chao D. asrs recommendations conducting vr surgery during covid 19 pandemic. [https://www.cosprc.ca/wp-content/uploads/2020/04/asrs\\_recommendations\\_conducting\\_vr\\_surgery\\_during\\_covid\\_19\\_pandemic.pdf](https://www.cosprc.ca/wp-content/uploads/2020/04/asrs_recommendations_conducting_vr_surgery_during_covid_19_pandemic.pdf). Accessed May 7, 2020.
- Price L. Vitreoretinal-surgery-management-guidance-070420. <https://www.rcophth.ac.uk/wp-content/uploads/2020/04/Vitreoretinal-surgery-management-guidance-070420.pdf>. Accessed May 7, 2020.
- Zhou P, Yang X-L, Wang X-G, et al. A pneumonia outbreak associated with a new coronavirus of probable bat origin. *Nature*. 2020;579(7798):270–273. <https://doi.org/10.1038/s41586-020-2012-7>.
- Fathizadeh H, Maroufi P, Momen-Heravi M, et al. Protection and disinfection policies against SARS-CoV-2 (COVID-19). *Inf Med*. 2020;28(2):185–191.
- Goldsmith CS, Tatti KM, Ksiazek TG, et al. Ultrastructural characterization of SARS coronavirus. *Emerg Infect Dis*. 2004;10(2):320–326. <https://doi.org/10.3201/eid1002.030913>.